THE

DUBLIN DISSECTOR,

OR SYSTEM OF

PRACTICAL ANATOMY.

BY

ROBERT HARRISON, M.D., M.R.I.A.,

FELLOW OF THE ROYAL COLLEGES OF SURGEONS OF IRELAND AND OF ENGLAND;
PROFESSOR OF ANATOMY AND SURGERY IN THE UNIVERSITY OF DUBLIN;
AND ONE OF THE SURGEONS OF THE JERVIS-STREET INFIRMARY, ETC., ETC.

COLL. SANCTÆ. INDIVIDUÆ. TRIN. REG. ELIZAB. JUXTA. DUBLIN

Fifth Edition,

WITH NUMEROUS ILLUSTRATIONS.

VOL. II.

DUBLIN:
HODGES AND SMITH, GRAFTON-STREET.
LONDON: SIMPKIN, MARSHALL, AND CO.
MDCCCXLVII.

DUBLIN:
PRINTED AT THE UNIVERSITY PRESS,
BY M. H. GILL.

CONTENTS.

VOLUME II.

PART II.

ANATOMY OF THE VASCULAR SYSTEM.

CHAPTER.		PAGE.
I.	ANATOMY OF THE ARTERIES,	403
	Arterial System,	ib.
	General Observations,	ib.
	Structure of Arteries,	405
	Aorta,	ib.
	Coronary Arteries,	408
	Arteria Innominata,	ib.
	Carotid Arteries,	ib.
	External Carotid,	ib.
	Superior Thyroid, lingual and labial,	409
	Muscular and Occipital,	ib.
	Posterior auricular and ascending Pharyngeal,	410
	Transverse Facial, temporal and internal Maxillary,	ib.
	Internal Carotid,	411
	Ophthalmic and posterior communicating Arteries,	412
	Anterior and middle cerebral Arteries,	413
	Subclavian Arteries,	ib.
	Vertebral, basilar, thyroid Axis, &c.,	414
	Internal mammary, superior intercostal, and cervicalis profunda,	415
	Axillary Artery, &c.,	ib.
	Brachial Artery, &c.,	416
	Ulnar Artery,	417
	Radial Artery,	418
	Thoracic Aorta,	ib.
	Bronchial and œsophageal Arteries,	ib.
	Intercostal Arteries,	419
	Abdominal Aorta,	ib.
	Phrenic Arteries,	ib.

CHAPTER. PAGE.

I. ANATOMY OF THE ARTERIES—*continued.*

Cœliac Axis, &c., ... 419
Mesenteric Arteries, ... 420
Renal, capsular, and spermatic Arteries, ... 421
Lumbar and middle sacral Arteries, ... ib.
Iliac Arteries, ... ib.
Internal iliac or hypogastric Artery, ... 422
Glutæal, obturator, pudic, sciatic, &c., ... 423
External iliac, ... 424
Femoral Artery, ... ib.
Profunda Artery, ... 425
Circumflex and perforating Arteries, ... ib.
Poplitæal Artery, ... 426
Anterior tibial Artery, ... ib.
Posterior tibial Artery, ... 427
Venous System, ... ib.
Pulmonary Veins, ... ib.
Systemic Veins, ... 428
Structure of Veins, ... 429
Veins of the Head and Face, ... ib.
External jugular Vein, ... 431
Anterior jugular Vein, ... 432
Internal jugular Vein, ... ib.
Vertebral Vein, ... 433
Venæ Innominatæ, ... ib.
Vena Cava superior, ... ib.
Vena Azygos, ... 434
Veins of the upper Extremity, ... 435
Subclavian Vein, ... 436
Veins of the Lower Extremity, ... ib.
Iliac Veins, ... 438
Vena Cava inferior, ... ib.
Spermatic, renal, hepatic, &c., ... 439
Fœtal Circulation, ... 440
Umbilical Vein, ... 442
Ductus Venosus, ... ib.
Ductus Arteriosus, ... 443
Thymus Body, ... 445
Lymphatic or Absorbent System, ... 446
Division of Absorbents, ... ib.
Structure of lymphatic Vessels and Glands, ... 447
Lymphatic Glands, ... 448
Lymphatic Vessels, ... 450
Thoracic Duct, ... 452
Receptaculum Chyli, ... ib.

PART III.

ANATOMY OF THE NERVOUS SYSTEM.

CHAPTER. PAGE.

I. DISSECTION OF THE BRAIN, ... 455

Cerebrum, Cerebellum, and Medulla Oblongata, . . ib.
Membranes of the Brain, ... ib.
Dura Mater, ... 457
Sinuses, ... 461
Arachnoid Membrane, ... 464
Pia Mater, ... 468
Cerebrum, ... 473
Convolutions, ... 474
Lobes, ... 477
Ventricles, ... 482
Cerebellum, ... 492
Lobes, ... 494
Medulla Oblongata, ... 500

II. ANATOMY OF THE MEDULLA SPINALIS, ... 504

Membranes of the Spinal Cord, ... ib.
Dura Mater, ... ib.
Arachnoid Membrane, ... 505
Pia Mater, ... 507
Spinal Cord, ... ib.
Origin of the Spinal Nerves, ... 511
Dissection of the Brain from below, ... 513
Structure of the Cerebellum, ... 515
Structure of the Cerebrum, ... 516
Vessels of the Brain, ... 519
Pathology of the Brain and its Membranes, ... 521
Origin of the Cerebral Nerves, ... 523
First, ... ib.
Second and third, ... 524
Fourth and fifth, ... 525
Sixth and seventh, ... 527
Eighth and ninth, ... 528

III. DISSECTION OF THE NERVES, ... 530

Cerebral Nerves, ... ib.
First or olfactory, ... ib.
Second or optic, ... ib.
Third, or Motor Oculi, ... 531
Fourth or Trochleator, ... 532
Fifth or Trigemini, ... ib.
Ophthalmic Nerve, ... ib.

CHAPTER. PAGE.

III. DISSECTION OF THE NERVES—*continued.*

Lachrymal, frontal, and nasal Nerves, ... 532
Sixth or Abducens Nerve, ... 533
Lenticular or Ophthalmic Ganglion, ... 534
Ciliary Nerves, ... ib.
Offices of Orbital Nerves, ... ib.
Superior Maxillary Nerve, ... 535
Meckel's Ganglion, ... ib.
Palatine and Spheno-palatine Nerves, ... ib.
Naso-palatine, or Nerve of Cotunnius, ... 536
Naso-palatine Ganglion, ... ib.
Vidian Nerve, Corda Tympani, Submaxillary Ganglion, ... ib.
Infraorbital Nerve, &c., ... 537
Inferior Maxillary Nerve, ... ib.
Inferior Dental Nerve, ... 538
Gustatory Nerve, ... 539
Otic Ganglion, ... ib.
Facial Nerve, or Portio Dura, ... 540
Auditory Nerve, or Portio Mollis, ... 543
Glosso-pharyngeal Nerve, ... ib.
Ganglion of Andersch, ... ib.
Pneumogastric Nerve, ... 544
Pharyngeal Plexus, ... 545
Laryngeal Nerves, ... ib.
Pulmonic Plexuses, ... 546
Œsophageal Plexus, or Plexus Gulæ, ... ib.
Nervus Accessorius, or Spinal Accessory Nerve, . . . ib.
Lingual Nerve, ... 547
Spinal Nerves, ... 548
Suboccipital Nerve, ... ib.
Cervical Plexus, ... 549
Phrenic or internal respiratory Nerve, ... 550
Brachial Plexus, ... 551
External respiratory or posterior thoracic Nerve, . . 552
Thoracic and Scapular Nerves, ... 553
Circumflex and internal cutaneous Nerves, ... 554
External cutaneous, and median, or brachial Nerve, . 555
Ulnar Nerve, ... 556
Paccinian Corpuscles, ... 557
Musculo-spiral or radial Nerve, ... 558
Dorsal Nerves, ... ib.
Intercosto-humeral, or Nerves of Wrisberg, ... 560
Lumbar Nerves and Plexus, ... 561
Musculo-cutaneous Nerves, ... 562
Genito-crural and anterior Crural Nerves, ... 563

CHAPTER.		PAGE.
III.	DISSECTION OF THE NERVES—*continued.*	
	Obturator, lumbo-sacral Nerves, &c.,	566
	Sacral Nerves and Plexus,	567
	Lesser sciatic, inferior glutæal, pudic Nerves, &c.,	569
	Great sciatic, or posterior Crural Nerve,	570
	Sympathetic Nerves,	574
	Cervical Ganglions,	576
	Cavernous or Carotid Plexus,	577
	Cardiac Nerves,	578
	Cardiac Plexus, Cardiac Ganglion,	579
	Thoracic Ganglions,	581
	Splanchnic Nerves,	ib.
	Semilunar Ganglions, Solar Plexus, &c.,	582
	Lumbar Ganglions,	583
	Sacral Ganglions,	584
	Ganglion Impar,	ib.
IV.	ORGANS OF SENSE,	586
	Skin, or Organ of Touch,	ib.
	Cuticle or Epidermis,	589
	Dermis, or Chorion, or Cutis Vera,	592
	Sudoriferous and Sebaceous Glands,	594
	Nails and Hairs,	595
	Areolar, or Cellular Tissue,	597
	Adipose Tissue,	598
	Nose, or Organ of Smell,	599
	Tongue, or Organ of Taste,	605
	Eye, or Organ of Vision,	612
	Orbits,	613
	Palpebræ, or Eye-lids,	616
	Conjunctiva,	620
	Lachrymal Apparatus,	622
	Muscles of the Orbit,	625
	Ocular Fascia,	628
	Globe of the Eye,	640
	Coats of the Eye,	641
	Humours of the Eye,	658
	Ear, or Organ of Hearing,	665
	Auricle, or external Ear,	666
	Muscles of the external Ear,	668
	Tympanum,	670
	Eustachian Tube,	675
	Ossicula Auditus, or Bones of the Ear,	676
	Muscles of the Tympanum,	678
	Labyrinth,	679

PART IV.

ANATOMY OF THE OSSEOUS SYSTEM.

CHAPTER. PAGE.

I. DESCRIPTION OF THE BONES, ... 688

Of the Bones, ... ib.
General Observations on the Osseous System, ... ib.
Cartilage, ... 690
Structure and Chemical Composition of Bone, . . . 693
The Vertebræ, ... 699
Sacrum, ... 709
Ossa Coccygis, ... 712
The Head, ... ib.
Occipital Bone, ... 713
Parietal, ... 716
Frontal, ... 718
Temporal, ... 722
Ethmoid, ... 726
Sphenoid, ... 729
Sutures, ... 732
The Skull in general, ... 733
Bones of the Face, ... 736
Malar or Cheek Bone, ... 737
Superior Maxillary, ... ib.
Palate Bone, ... 739
Inferior spongy or turbinated Bone, ... 741
Os Unguis or lachrymal Bone, ... ib.
Nasal Bones, ... ib.
Vomer, ... 742
Inferior Maxillary Bone, ... ib.
Teeth, ... 744
Structure and development of Teeth, ... 746
The Thorax, ... 753
Sternum, ... ib.
Ribs, ... 755
Costal Cartilages, ... 758
Pelvis, ... 761
Os Ilium, ... 762
Ischium, ... 764
Pubis, ... ib.
Os Innominatum, ... 765
Acetabulum, ... 766
Pelvis in general, ... 767
Bones of the inferior Extremities, ... 772
Femur, ... ib.
Patella or Rotula, ... 776

CHAPTER. PAGE.

I. DESCRIPTION OF THE BONES—*continued.*

Tibia, ... 776
Fibula, ... 779
Tarsal Bones, ... 780
Metatarsal, ... 784
Phalanges, ... ib.
Sesamoid Bones, ... 785
Bones of the superior Extremities, ... ib.
Clavicle, ... ib.
Scapula, ... 786
Humerus, ... 789
Ulna, ... 791
Radius, ... 792
Carpal Bones, ... 793
Metacarpal, ... 795
Phalanges, ... 797
Sesamoid Bones, ... ib.
Os Hyoides 798

II. OF THE JOINTS, ... 799

General Observations, ... ib.
Diarthrosis, ... ib.
Synarthrosis, ... ib.
Amphiarthrosis, ... 800
Temporo-maxillary Articulations, ... 801
Dislocations of the lower Jaw, ... 804
Articulation of the Occiput with the Atlas, ... 805
Articulation of the Occiput with the Axis, ... 806
Articulation between the Atlas and Axis, ... 808
Common Articulations of the Vertebræ, ... 809
Intervertebral Ligaments or Fibro-Cartilages, . . . 810
Articulations of the Ribs, ... 813
Ligaments of the superior Extremities, ... 816
Sterno-clavicular Articulation, ... ib.
Scapulo-clavicular Articulation, ... 819
Dislocations of the Clavicle, ... 820
Proper Ligaments of the Scapula, ... ib.
Humero-scapular, or Shoulder Articulation, ... 821
Dislocations of the Shoulder, ... 823
Humero-cubital Articulation, or Elbow-joint, . . . 824
Radio-ulnar Articulations, ... 826
Dislocations of the Elbow-joint, ... 827
Dislocations of the carpal extremities of the Radius or Ulna, ... 829
Radio-carpal Articulation, or the Wrist-joint, . . . ib.
Articulations of the Bones of the Carpus, ... 831

CHAPTER. PAGE.

II. OF THE JOINTS—*continued.*

Dislocations of the Bones of the Carpus, ... 834
Articulations between the Carpus and Metacarpus, . ib.
Dislocations of the metacarpal Bones from the Carpus, ib.
Articulations between the Metacarpus and the Phalanges, ... 835
Dislocations of the Thumb, ... ib.
Articulation between the Pelvis and Spine, ... 836
Articulations of the Pelvis, ... 837
Ligaments of the inferior Extremities, ... 839
Ilio-femoral Articulation, or the Hip-joint, ... 839
Dislocations of the Hip-joint, ... 843
Femoro-tibial Articulation, or the Knee-joint, ... 845
Dislocations of the Patella and Knee, ... 853
Dislocations of the semilunar Cartilages, ... 854
Superior tibio-fibular Articulation, ... 855
Dislocation of the superior tibio-fibular Articulation, . ib.
Inferior tibio-fibular Articulation, ... ib.
Articulation of the Ankle, ... 856
Dislocations, &c., of the Ankle, ... 859
Articulations of the Bones of the Tarsus, ... 860
Dislocations of the Astragalus, ... 862
Articulations between the Tarsus and Metatarsus, &c., 863

APPENDIX.

Directions for making dried Preparations of the Arteries and Veins, ... 865
Laennec's Division of the Regions of the Thorax, ... 868
Directions for opening the Cranium, Thorax, and Abdomen, . 870

TABLE OF ILLUSTRATIONS.

VOLUME II.

Fig.		Page.
66.	Great Vessels connected to the Base of the Heart,	406
67.	The Fœtal Circulation,	441
68.	Vertical Section of the Head, shewing the Processes of the Dura Mater, &c.,	459
69.	Base of the Brain,	478
70.	The Circle of Willis,	519
71.	External Wall of Nasal Fossa,	602
72.	Muscles of the Orbit,	626
73.	Longitudinal Section of the Globe of the Eye,	642
74.	A Diagram of the Ear,	667
75.	Lumbar Vertebra,	701
76.	Dorsal Vertebra,	702
77.	Cervical Vertebra,	ib.
78.	Atlas; superior surface,	703
79.	Atlas; inferior surface,	ib.
80.	Axis,	704
81.	Vertebral Column; posterior view,	707
82.	Vertebral Column; anterior view,	708
83.	Vertebral Column; lateral view,	709
84.	Sacrum,	710
85.	Skull; anterior view,	713
86.	Occipital Bone; external surface,	714
87.	Occipital Bone; internal surface,	715
88.	Parietal Bone; external surface,	717
89.	Parietal Bone; internal surface,	718
90.	Frontal Bone; external surface,	719
91.	Frontal Bone; internal surface,	720
92.	Temporal Bone; external surface,	722
93.	Temporal Bone; inferior surface,	724
94.	Temporal Bone; internal surface,	725
95.	Ethmoid Bone; postero-superior view,	727
96.	Ethmoid Bone; lateral view,	728
97.	Sphenoid Bone; anterior surface,	729

Fig.		Page.
98.	Sphenoid Bone; superior surface,	730
99.	Base of the Skull; external view,	734
100.	Base of the Skull; internal view,	735
101.	Superior Maxillary Bone,	738
102.	Palate Bone,	740
103.	Inferior Maxillary Bone,	742
104.	Sternum; posterior surface,	753
105.	Sternum; anterior surface,	ib.
106.	Ribs,	756
107.	Thorax; anterior view,	759
108.	Os Innominatum,	761
109.	Pelvis, Bones of; anterior view,	768
110.	Femur; posterior surface,	773
111.	Femur; anterior surface,	ib.
112.	Patella; anterior surface,	776
113.	Patella; posterior surface,	ib.
114.	Tibia; posterior surface,	777
115.	Tibia; anterior surface,	ib.
116.	Fibula; anterior surface,	779
117.	Fibula; posterior surface,	ib.
118.	Foot; dorsal surface,	780
119.	Foot; plantar surface,	781
120.	Foot; lateral view,	782
121.	Clavicle; superior surface,	785
122.	Clavicle; inferior surface,	ib.
123.	Scapula,	787
124.	Humerus,	789
125.	Ulna,	791
126.	Radius,	792
127.	Hand; anterior view,	794
128.	Hand; posterior view,	796
129.	Os Hyoides,	798
130.	Temporo-maxillary Articulation; external view,	802
131.	Temporo-maxillary Articulation; internal view,	ib.
132.	Temporo-maxillary Articulation; section of,	803
133.	Ligaments connecting the Occipital Bone, Atlas, and Axis; anterior view,	805
134.	Ligaments connecting the Occipital Bone to the Atlas, and the Atlas to the Axis; posterior view,	806
135.	Occipito-axoid Articulation; posterior view,	807
136.	Ligaments connecting the Occipital Bone, Atlas, and Axis; posterior view,	ib.
137.	The common Articulations of the Vertebræ; anterior view,	810
138.	The common Articulations of the Vertebræ; posterior view,	ib.
139.	Ligamenta Subflava,	812
140.	Ligaments of the Vertebræ and Ribs; lateral view,	814

Fig.		Page.
141.	Costo-vertebral Articulation, section of; shewing the middle costo-transverse Ligament,	815
142.	Sterno-clavicular and sterno-costal Articulations,	817
143.	Humero-scapular and scapulo-clavicular Articulations,	819
144.	Elbow-joint; external view,	824
145.	Elbow-joint; internal view,	825
146.	Annular Ligament of the Radius,	826
147.	Ligaments of the Wrist and Hand,	830
148.	A Diagram of the synovial Membranes of the Wrist,	832
149.	Ligaments of the Pelvis and Hip-joint; anterior view,	836
150.	Ligaments of the Pelvis and Hip-joint; lateral view,	838
151.	Vertical Section of the Hip-joint,	840
152.	Ligaments of the Knee-joint; anterior view,	845
153.	Ligaments of the Knee-joint; posterior view,	846
154.	Section of the Knee-joint, shewing the arrangement of the synovial Membrane,	848
155.	The Knee-joint laid open, shewing the interior of the Articulation,	849
156.	The superior Extremities of the Tibia and Fibula, as seen from above,	852
157.	Ligaments of the Ankle; internal view,	857
158.	Ligaments of the Ankle; external view,	ib.
159.	Ligaments of the Ankle; posterior view,	858
160.	Ligaments of the Sole of the Foot,	861

PART II.

ANATOMY OF THE VASCULAR SYSTEM.

UNDER THIS HEAD WE MAY CONSIDER THE ANATOMY OF THE ARTERIES, VEINS, AND ABSORBENTS.

CHAPTER I.

ANATOMY OF THE ARTERIES.

THE heart, the great central organ for regulating the circulation, propels the blood into the arterial tubes, which conduct this fluid through all parts of the system. Two large arteries spring from the heart, the pulmonary and the aorta; the former conveys from the right ventricle, the venous or impure blood through the lungs, and, with the pulmonary veins, constitutes the pulmonic, or the lesser circulation: the aorta conducts the red or pure blood, impelled into it from the left ventricle, through all parts of the body, and, together with the corresponding or returning veins, constitutes the great systemic or corporeal circulation. These two systems are perfectly distinct and separate in the adult, but during the fœtal life, they communicate through the foramen ovale in the auricular septum, and through the ductus arteriosus, which opens from the pulmonic trunk into the aorta. The pulmonary artery has been already described in the anatomy of the heart, page 115. The aorta and its ramifications shall now be considered: these may be compared to a tree, the aorta itself being the trunk, extending from its root in the heart, along the spinal column, to the pelvis, while the branches are the numerous divisions and sub-divisions ramifying throughout the body, and more or less pervading every texture, except the epidermis, nails, and hair: as the combined areæ of all these branches must greatly exceed the diameter of the parent tube, the entire tree resembles a cone, whose apex is in the aorta, and whose

base is expanded throughout the entire system. The several arterial divisions are named partly from their regional situation, as subclavian axillary, brachial, femoral, &c.; partly from their relative position, as superficial or deep, anterior, or posterior, &c.; and partly from their destination, as cerebral, ophthalmic, renal, spermatic, &c. The names "artery" and "aorta" have their origin in the absurd notion of the ancients, who, ignorant of the true course of the circulation of the blood, supposed that these tubes were filled with vital air or spirit; long and continued usage, however, has established these erroneous titles. The origin of the aorta from, and its connexion to the heart, have been already considered (page 118). The branches arise from this trunk, according to different plans in different situations; in some, a large vessel bifurcates into its terminal branches; this dichotomous division, which takes place at an acute angle, with an internal projecting crest, favours the current into the branches; thus the common carotids divide into internal and external, the brachial into radial and ulnar, the aorta into right and left iliac, the popliteal into anterior and posterior tibial, &c. In other places the branches arise at a right, or even an obtuse angle, as the lumbars and intercostals, &c.; this would appear unfavourable to a rapid passage, and may even be designed to retard the flow of blood, or lessen the impetus of the heart's action. Some arteries continue a long course without giving off any branches, or but a few small ones, and others terminate abruptly in a number of branches diverging in a radiated manner, as the cæliac and the thyroid axis. Arteries vary much as to their course, being straight, curved, retrograde, serpentine, tortuous, coiled, &c. Arteries terminate in anastomoses, and in the minute net-work of vessels termed the *capillary system;* this again communicates with the veins. The capillaries can seldom be filled by injection, or exposed by dissection without the aid of the microscope, except in some situations; they can be best observed and admired in the transparent textures of some animals during life, as in the web of the frog; the capillaries pervade almost all parts of the body, but vary greatly as to number and development in different tissues; they are the seat of nutrition and secretion, the ultimate objects of the circulation of the blood.

The anastomoses of arteries are numerous and on varied plans; the most common is that by inosculation, that is, when two vessels running in opposite directions meet and form one loop, as in the arteries of the mesocolon and mesentery; this plan is almost universal in the smaller arteries and in the capillaries; by it collateral circulation is maintained, a free supply of blood is secured, and protection afforded against any impediment or interruption in the course of this fluid; it is on these inosculations, and their remarkable capability of becoming so enlarged as to establish a free collateral circulation when any main artery is obstructed, that the practice of applying a ligature on even a large vessel is founded, without any apprehension as to an insufficient supply of blood to the parts beyond it. Anastomosis also occurs by two large arteries converging into one, as the two vertebrals into the

basilar; or sometimes two vessels are connected by a transverse branch, as in the case of the anterior arteries of the brain.

The arterial tubes are of a dense structure, and preserve their form when empty, when divided also after death they remain open and do not collapse; they are composed of three principal coats or tissues; the *first* or *external* is cellular or fibro-cellular, strong and resisting, connects the vessels to the surrounding parts, and contains its nutrient nerves and vessels; it is composed of a close, filamentous, areolar tissue, which never contains any adeps, and presents some glistening fibres, partly circular, partly longitudinal; it most probably possesses some organic contractility.

The *second* or *middle*, or *proper coat*, is the thickest; it consists of yellowish and rather dry fibres, elastic, but brittle; they are chiefly circular, but do not form complete rings; they are easily separated longitudinally, and, together with the inner coat, are cleanly cut through by a circular ligature; this coat is eminently elastic, particularly in the large arteries. Minute anatomists, with the aid of the microscope, divide this coat into three laminæ, an external, thin, yellow, elastic one, most distinct in the larger tubes; a middle, composed of circular fibres, similar to those of unstriped involuntary muscle; and an internal, of similar fibres but in the longitudinal direction. The *internal coat* of an artery, smooth and polished, resembles serous membrane, and is often thrown into longitudinal plicæ; it has been subdivided into two laminæ: the internal composed of tesselated epithelium; this rests on a basement membrane, the fibres of which are chiefly longitudinal and interlaced, leaving numerous openings between them: the internal and middle tunics are connected by fine cellular tissue, in which those calcareous patches, so common in the arterial system are first deposited. The arterial tunics, therefore, may be enumerated as seven in number, viz.: the external, or fibro-cellular; the three laminæ of the middle or fibrous; the intervening cellular tissue between the internal and middle coats; and lastly the epithelium and its basement layer. The arteries are supplied with nutrient vessels and nerves from the adjacent parts, the aorta and the abdominal arteries exhibit these most perfectly. Although the arterial system is devoid of exact symmetry, yet, with a few exceptions, one description will apply to either side; the principal arteries are surrounded by a cellular and fibrous tissue named their sheath, and which also usually contains the accompanying veins and nerves.

The principal blood-vessels have been already noticed in the anatomy of the different regions. In the present section the arteries shall be considered in a systematic manner, commencing with the aorta, and tracing its branches through all parts of the body.

Aorta arises from the upper part of the left ventricle, opposite the fourth or fifth dorsal vertebra (*see* pages 114 and 118), ascends obliquely forwards and to the right side, behind the second bone of the sternum, to a level with the second sterno-costal articulation; it then bends backwards and to the left side, and, corresponding to the second

dorsal vertebra, makes a second turn in a direction downwards, and thus forms the *arch*, which is said to terminate at the left side of the body of the third or fourth dorsal vertebra: the continued trunk receives the name of descending aorta, and is subdivided into the thoracic and abdominal.

The *arch* of the *aorta*, though not very accurately defined, may be

Fig. 66.*

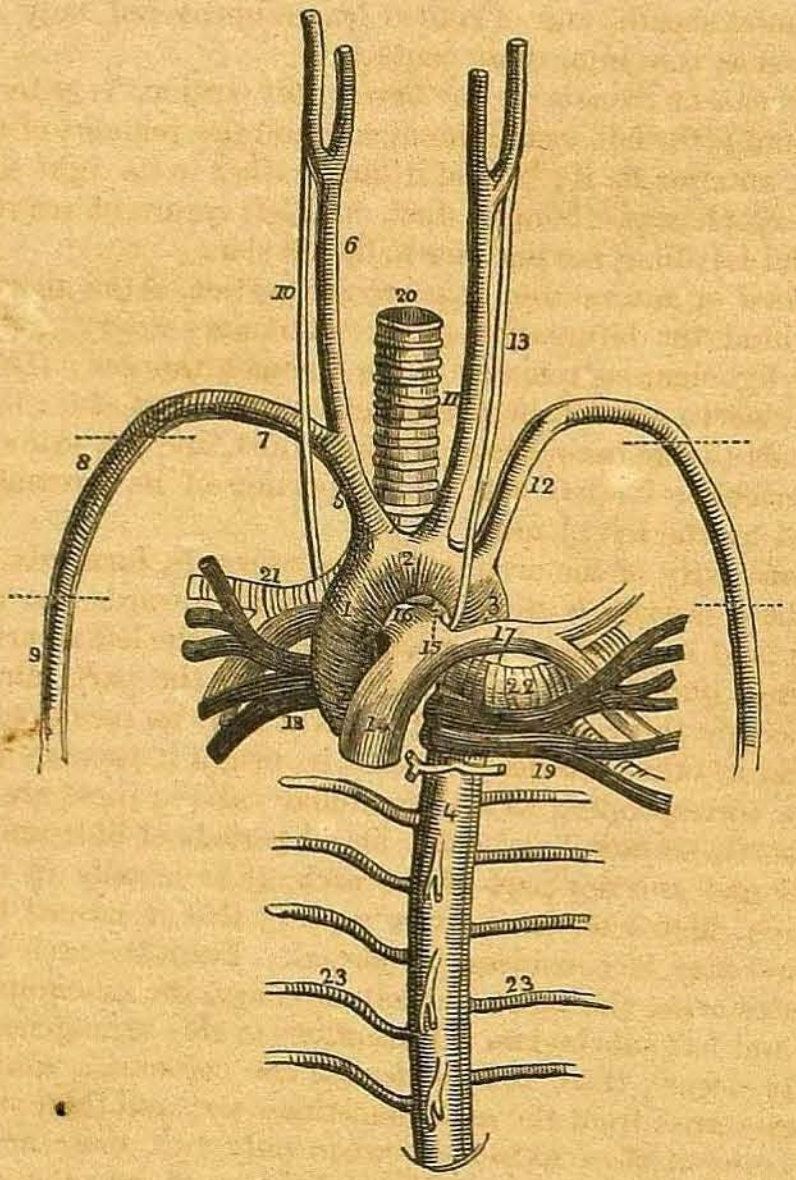

* A view of the great vessels which are connected to the base of the heart. 1. The ascending portion of the arch of the aorta. 2. Its transverse portion. 3. Its descending portion. 4. The thoracic aorta. 5. The arteria innominata. 6. The common carotid artery of right side. 7. The right subclavian artery. 8. The axillary artery. 9. The brachial artery. 10. The right pneumogastric nerve. 11. The left common carotid artery. 12. The left subclavian. 13. The left pneumogastric nerve. 14. The trunk of the pulmonary artery. 15. The obliterated ductus arteriosus. 16. The right pulmonary artery. 17. The left pulmonary artery. 18. The right pulmonary veins. 19. The left pulmonary veins. 20. The trachea. 21. The right bronchus. 22. The left bronchus. 23. 23. The intercostal arteries. The small branches, arising from the forepart of the aorta, are distributed to the pericardium and œsophagus.

considered as extending from the left ventricle to the fourth dorsal vertebra, and may be divided into three portions, the anterior or ascending, the middle or transverse, and the posterior or descending.

The *first*, or the *ascending*, is enclosed in the pericardium, and covered at first by the infundibulum and root of the pulmonary artery; as it ascends, this latter vessel lies to its left side, and the vena cava to its right; behind it are the right pulmonary artery and veins; the serous membrane attaches and encloses it and the pulmonary artery in one common sheath, and of course leaves uncovered only so much of each vessel as is in immediate contact.

The *second* or *transverse*, or *horizontal* portion, is external to the pericardium; the left vena innominata and the remains of the thymus gland are anterior to it; behind it, and rather to its right side, are the trachea, œsophagus, thoracic duct, and left recurrent nerve: the left pleura and left lung are anterior to its left side.

The *third* or *descending*, or *posterior* portion, is the shortest, is directly behind the bifurcation of the pulmonary artery, and united to it by the ligamentous remains of the ductus arteriosus; the left pneumogastric nerve and left bronchial tube are in front of it; its right side corresponds to the œsophagus, thoracic duct, and left side of the third dorsal vertebra; its left side and a portion of its circumference are enveloped by the left pleura.

The convexity of the arch is directed upwards, forwards, and to the right; the concavity is directed downwards towards the root of the left lung, and is embraced in a sort of loop by the left recurrent nerve; a number of lymphatic glands, together with the parts already mentioned, occupy this concavity. The aorta is by no means so uniformly cylindrical as other arteries; close to its origin it presents three small swellings corresponding to the semilunar valves; these are named the "lesser aortic sinuses," and exist at all periods of life; and again, at the upper and anterior part of the arch, it is usually in old persons very much dilated on its convex aspect; this is named the "great sinus," and may be considered abnormal. From the arch of the aorta five arteries arise, the right and left coronary, the innominata, the left carotid, and left subclavian. Exceptions to this arrangement not unfrequently occur; thus, independent of the coronaries, sometimes but two arteries arise from the arch, sometimes six, and there may be any number between these extremes; when only two, these are usually a right and left innominata, which subdivide each into the carotid and subclavian; when there are four or more, the additional branches may be the right carotid, the right and left vertebral. Many of these apparent anomalies are analogous to the regular order in some other class of animals, and others can be referred to the principle of an early or late origin of primary branches. The right subclavian very frequently arises from the left extremity of the transverse portion of the arch, and then it passes upwards and to the right side, crossing the spine behind the œsophagus, and rarely between it and the trachea; in such

cases there is no innominata, and the right carotid arises from the arch in its place.

The *right and left coronary arteries* are the nutrient vessels of the heart; they arise above two of the sigmoid valves; the *right* proceeds along the base towards the right side of the heart, divides into several long branches, which supply the parietes of the right auricle and ventricle, and communicate with the left coronary: the *left* descends obliquely along the left side of the heart, supplying the parietes of the left auricle and ventricle, and communicating with the former around the base and apex of the heart. These arteries have been minutely described in the Anatomy of the Heart, see page 122: their number is not uniform; sometimes there is but one common trunk, sometimes there are three, and even four, but such varieties do not affect their general distribution, and may be regarded as branches which arise from the aorta, instead of from the coronary arteries themselves.

The *arteria innominata* arises from the upper part of the arch, at the angle or junction between the ascending and horizontal portion; it is from an inch to an inch and a half in length, ascends obliquely to the right side, in front of the trachea and of the right pleura, and behind the sterno-hyoid and thyroid muscles and the left vena innominata; opposite the sternal end of the clavicle it divides into the right subclavian and right carotid arteries.

The *right and left carotid arteries.* The *right* arises from the innominata, the *left* from the arch of the aorta: these vessels ascend obliquely outwards as high as the os hyoides, opposite which each divides into the internal and external; in this course they are covered inferiorly by the sterno-mastoid, hyoid, thyroid, and omo-hyoid muscles, and superiorly only by the skin, platysma, and fascia; the left, in consequence of the obliquity of the arch of the aorta, lies much deeper at its origin than the right, and is in addition covered inferiorly by the sternum and the vena innominata, and lies on the trachea, thoracic duct, œsophagus, and left subclavian: in this lower or thoracic portion, which is nearly an inch long, it is related externally to the left pleura and phrenic nerve, and internally to the arteria innominata, from which it separates by a triangular interval, in which the trachea appears; but after this both ascend in front of the longus colli and rectus capitis muscles, the inferior thyroid artery, and the recurrent and sympathetic nerves, and are enclosed in a sheath of cellular membrane, along with and to the tracheal side of the vagus nerve and the internal jugular vein; the descendens noni nerve lies superficial to this sheath. The right carotid is sometimes larger than the left; it is also on a plane anterior to it, at least in the lower part of the neck, and is less closely connected to its accompanying vein.

The *external carotid artery* ascends obliquely backwards to the forepart of the meatus auditorius, covered by the skin, platysma, and fascia, also by the lingual nerve, digastric and stylo-hyoid muscles, the parotid gland, and portio dura nerve; it lies superficial to the in-

ternal, carotid, stylo-pharyngeus, and stylo-glossus muscles, the glosso-pharyngeal nerve, and part of the parotid gland; it gives off the ten following arteries: anteriorly, the superior thyroid, lingual, and labial; posteriorly, the muscular, auricular, and occipital; superiorly, the pharyngeal, transverse facial, temporal, and internal maxillary.

The *superior thyroid artery* arises opposite the cornu of the thyroid cartilage, descends obliquely forwards and inwards beneath the sterno-thyroid and omo-hyoid muscles, and sends off the following branches: first, the *superficial*, distributed to the integuments and superficial muscles; second, the *laryngeal*, accompanying the superior laryngeal nerve, between the os-hyoides and thyroid cartilage, and distributed to the muscles and mucous membrane of the larynx; third, *hyoidean*, small and irregular, to the lower border of the os hyoides and adjacent muscles; and, fourth, *superior thyroid*, is distributed to the thyroid gland.

The *lingual artery* arises immediately above the preceding; it ascends tortuously and obliquely forwards and inwards, above the os hyoides, to the base of the tongue, between the hyo and the genio-hyoglossi muscles, and then runs horizontally forwards towards the tip of the tongue; it gives off the following branches: first, *hyoidean*, small and irregular; second, *dorsalis linguæ*, which ascends to the dorsum of the tongue, and is lost on the mucous membrane near its base, also on the velum and fauces; third, *sublingual*, passes forwards and outwards to the sublingual gland, mylo-hyoid muscle, and mucous membrane of the mouth; and, fourth, the continued trunk named *ranine*, which continues along the lingualis muscle to the tip of the tongue.

The *labial* or *external maxillary artery* arises opposite the os-hyoides, ascends obliquely forwards behind the digastric and between the submaxillary gland and the base of the jaw, turns round the latter anterior to the masseter muscle, and then ascends obliquely forwards and inwards towards the side of the nose: in the neck it gives off, first, *inferior palatine*, which ascends along the side of the pharynx, and supplies the velum and the amygdala; the branch to the latter often arises distinctly; second, *glandular*, to the sub-maxillary and adjoining lymphatic glands; third, *submental* runs along the mylo-hyoid muscle to the chin, and supplies the surrounding muscles. On the face it gives off, fourth, *inferior labial* to the muscles and integuments between the lip and chin; fifth, the *inferior* and *superior coronary*; these run along the border of the lips, close to the mucous membrane, and directly join those from the opposite side; sixth, *lateralis nasi*, to the muscles and skin on the side and dorsum of the nose; and, seventh, *angularis*, which communicates with the ophthalmic.

The *muscular artery* descends obliquely backwards, divides into several branches, which are principally distributed to the sterno mastoid, and to the surrounding cellular tissue and glands.

The *occipital artery* arises opposite the labial, ascends obliquely backwards behind the digastric, then curves horizontally backwards between the mastoid process and the atlas, and near the mesial line it

ascends on the occiput; it gives off several muscular branches, some to the mastoid and trapezius muscles, several to the deep muscles on the side and back of the neck, and on the occiput it divides into tortuous branches, which ascend in different directions in the scalp, and inosculate with the different arteries in that region.

The *posterior auricular artery* arises above, often in common with the occipital; it ascends behind the parotid and between the meatus auditorius and the mastoid process; it divides into several branches, which are lost in the integuments of the ear and in the scalp; it gives off one branch which requires special notice, the *stylo-mastoid;* it enters by the foramen of that name into the aqueduct of Fallopius, and its terminal branches are distributed to the tympanum.

The *inferior* or *ascending pharyngeal artery* arises near the division of the common carotid, ascends vertically to the base of the skull, and sends off several pharyngeal and palatine branches, and ends in a small branch that passes through the foramen lacerum posterius, and supplies the dura mater at the base of the cranium.

The *transverse artery of the face* arises from the carotid in the parotid gland, accompanies the duct of Steno, and is distributed to the muscles and integuments of the face, and joins the branches of the facial artery.

The *temporal artery* ascends through the parotid gland between the meatus auditorius and the articulation of the maxilla, behind the zygoma, and divides on the temporal fascia into an anterior and posterior branch; it gives off, first, *branches to the gland;* second, *anterior auricular;* third, the *middle temporal;* this pierces the fascia, and is distributed to the temporal muscle; fourth, the *anterior* or *frontal* supplies the skin and muscles of the forehead, and joins the ascending branches of the ophthalmic artery; fifth, *posterior temporal* bends backwards and upwards to the scalp, and inosculates with the occipital and auricular arteries.

The *internal maxillary artery* ascends obliquely forwards behind the neck of the maxilla, between the pterygoid muscles; and, lastly, between the external pterygoid and the temporal muscle into the pterygo-maxillary fossa; to expose it, the zygomatic arch must be sawn through at each end, and depressed together with the masseter muscle; the temporal muscle raised from the coronoid process, the ramus of the jaw divided near its centre, and its articulation dislocated, a little dissection will then expose this vessel, along with the deep branches of the inferior maxillary nerve, between the pterygoid muscles. It first passes horizontally forwards, between the neck of the jaw and its internal lateral ligament, and is related to the dental and gustatory nerves; it then enters a space enclosed between the temporal, pterygoid, and buccinator muscles, winds over the external pterygoid, and then bends tortuously downwards into the pterygo-maxillary fossa. It gives off the following branches, first, while internal to the neck of the maxilla, the *middle artery of the dura mater;* this ascends to the base of the cranium, passes through the spinous hole of the sphenoid

bone, and divides into an anterior and posterior branch; the former is the larger, crosses the great wing of the sphenoid bone, enters the groove or canal in the anterior inferior angle of the parietal bone, and soon divides into numerous branches, of which one rather large ascends towards the vertex, parallel but posterior to the coronal suture. The posterior branch crosses the squamous portion of the temporal bone, and ramifies on the parietal. These vessels supply the bones of the cranium and the dura mater; small branches also pass into the internal ear through the hiatus Fallopii. Second, the *inferior dental* arises opposite the last, descends obliquely forwards between the bone and the internal lateral ligament, enters the dental foramen, and proceeds beneath the teeth, to the roots of which it sends very small arteries, and through the mental hole it sends a small branch to the muscles and mucous membrane, and to inosculate with branches of the labial artery; between the pterygoid muscles it sends off, third, the *deep temporal* branches, one posterior, the other anterior; these supply the muscle, and ascend close to the bone; fourth, *masseteric;* fifth, *pterygoid;* sixth, *buccal*, to the buccinator muscle, the fat and integuments of the cheek; seventh, *superior dental*, which winds round the maxillary tuberosity, and sends branches into the alveoli and to the gums; in the spheno-maxillary fossa it gives off, eighth, *infra-orbital*, which, from its size, would appear to be the continued trunk; it passes along the canal of that name, sends branches downwards to the antrum, and to the incisor and canine teeth, is finally distributed to the muscles of the face, and communicates with the arteries of that region; ninth, *nasal*, passes inwards through the spheno-palatine hole, and is distributed to the mucous membrane on the spongy bones and on the septum; tenth, the *superior palatine*, descends along the posterior palatine canal, and is distributed partly to the muscles and to the mucous membrane of the velum, but principally to the hard palate, on which one branch curves forwards in a bony groove internal to the alveoli, and inosculates in the anterior palatine canal with the spheno-palatine artery; eleventh, the *vidian;* this is a small branch which passes backwards, and takes the course of the first part of the vidian nerve; these terminating branches of the internal maxillary artery are entangled with the divisions of the superior maxillary nerve.

The *internal carotid artery* ascends along the vertebral column and the side of the pharynx from the common carotid, posterior and external to the external carotid, behind the digastric and styloid muscles, internal to the jugular vein and anterior to the vagus and sympathetic nerves, to the foramen caroticum in the petrous bone; it then bends tortuously forwards, upwards, and inwards, through the carotid canal, accompanied by the superior branches of the sympathetic, enters the cavernous sinus, through which it makes two remarkable turns internal to the sixth pair of nerves, and, arriving at the anterior clinoid process, it bends upwards and backwards, and a little outwards, and opposite the internal extremity of the fissure of Sylvius divides into its three terminating branches, viz., posterior communicans, anterior

cerebri, and media cerebri. This vessel, through its entire course, is remarkable for its tortuosity; in the neck it is very variable in this respect, but is generally bent into several curves, and often dilated irregularly, and of a larger calibre than when it has entered the cranium; in the carotid canal and cavernosus sinus it is always curved in the form of the Italic *S*, placed horizontally. In the neck and in the carotid canal it sends small and unimportant branches to the surrounding parts; one, named tympanic, enters a small hole in the carotid canal, and is distributed to the tympanum; one or two meningeal branches to the dura mater and adjacent bones; the first branch of any importance is the following:

The *ophthalmic artery* arises close to the anterior clinoid process, passes forwards through the optic foramen, below the optic nerve and external to it; in the orbit it rises above this nerve, and twines round it to the inner side of this cavity, along which it passes to the inner canthus, where it terminates. While on the outer side of the optic nerve it sends off, first, *centralis retinæ*, very small, pierces the sheath of the optic nerve, passes along the centre of the latter into the eye, where it divides into delicate ramifications; these spread along the internal layer of the retina, and one or two pierce the vitreous humour, and extend to the capsule of the lens; second, the *lachrymal* passes along the external rectus muscle, and supplies the lachrymal gland, and the external part of the palpebræ; while above the optic nerve it gives off, third, the *supra-orbital*, which passes forwards along the levator palpebræ, and through the superciliary notch, supplies the muscles and integuments of the eye-brow, and ascending on the forehead, divides into several branches, which are distributed to the scalp, and communicate with the temporal and occipital arteries; fourth, the *posterior ciliary*, ten or twelve in number, very small, surround the optic nerve, and pierce the back part of the sclerotic, pass between it and the choroid, and are distributed to the latter; some of their branches continue as far as the ciliary processes and the iris; fifth, *long ciliary*, one on each side; they pass horizontally forwards, between the sclerotic and choroid membranes, as far as the ciliary circle; here they divide, and form a circular inosculation round the circumference of the iris; from this several branches radiate inwards, and again unite in a circle near the pupil; sixth, *muscular arteries*, to the different muscles in the orbit; seventh, *ethmoidal*, passes through the posterior orbital foramen to the mucous membrane in the ethmoid cells; eighth, *superior and inferior palpebral*, to the palpebræ, caruncula, conjunctiva, and lachrymal sac; ninth, *nasal*, passes beneath the trochlea, along the side of the nose, and inosculates with the labial artery; tenth, *frontal*, ascends to the eye-brow and forehead.

The *posterior communicating artery* arises from the carotid, opposite the ophthalmic; passes backwards and inwards, external to the corpora mamillaria, and joins the posterior cerebral artery; this artery forms the lateral part of the circle of Willis; it sends several branches to the surrounding pia mater.

The *anterior cerebral artery*, or *arteria callosa*, passes forwards and inwards above the optic nerve; anastomoses with the opposite, by a short transverse branch (the anterior communicating artery); it then bends upwards and backwards round the corpus callosum, on which it terminates by dividing into branches for the corresponding hemisphere of the cerebrum.

The *middle cerebral artery*, very large, passes outwards in the fissure of Sylvius, and divides into two tortuous branches, which supply the anterior and middle lobes of the cerebrum; these branches are remarkably tortuous, and sink deep into the sulci between the convolutions in the island of Reil; these coils can be drawn out from the depressions, and they can be traced along the side of each hemisphere, even to the vertex; at the inner extremity of the Sylvian fissure a number of small branches arise from this vessel, and pass through the external perforated substance to supply the corpus striatum.

The *subclavian arteries*. The right and left subclavian arteries differ in diameter, length, situation, and relations. The right arises from the innominata, and is consequently shorter than the left, which springs from the back part of the middle portion of the arch of the aorta; the right is also larger and situated more anteriorly in the neck. The course of each may be divided into *three stages*, the *first* extends from the origin to the tracheal edge of the anterior scalenus muscle; this stage is much longer on the left than upon the right side; the *middle stage* is the transit of the artery between the scaleni muscles; the *third stage* extends from these muscles beneath the clavicle to the lower border of the first rib, below which the continued trunk receives the name of axillary artery; in the middle and last stages, the right and left arteries are similarly circumstanced in all respects.

The *right subclavian* in its first stage passes outwards, and a little upwards, having anterior to it, the internal jugular and subclavian veins, the pneumogastric, cardiac, and phrenic nerves; the first of these crosses it at right angles, and sends its recurrent beneath and behind it; the sterno-mastoid, hyoid, and thyroid muscles, with more or less of cellular tissue, are also anterior to it; behind it are the recurrent and sympathetic nerves, the vertebral vein, cellular tissue and lymphatic glands, which separate it from the vertebræ and correspond to a depression between the longus colli and scalenus muscle. The *left subclavian* from its origin to the scalenus is nearly vertical, and has anterior to it, the sterno-mastoid, hyoid, and thyroid muscles, the clavicle and first rib, the left vena innominata, left carotid artery, the pneumogastric, phrenic, and cardiac nerves, and also branches of the sympathetic, together with the left lung and pleura; the pneumogastric nerve does not cross it at right angles as upon the right side, but descends parallel to it, and its recurrent winds around the arch of the aorta, and then ascends behind the left subclavian. This vessel is separated from the vertebræ by the longus colli muscle and sympathetic nerve; at first it is in front of the thoracic duct, but as it ascends it lies to the left side of it and of the œsophagus. The subclavian artery in the

middle stage of its course, on each side of the neck, is covered by the sterno-mastoid and anterior scalenus muscle, and phrenic nerve, and lies upon the pleura and middle scalenus, accompanied by the brachial plexus of nerves which is superior and external to it; the subclavian vein is inferior and anterior, the anterior scalenus being interposed.

In its *third stage* it inclines downwards and outwards, and is covered only by the skin, platisma, fascia, and cellular tissue, it rests upon the middle scalenus and the first rib; the plexus of nerves and the omo-hyoid muscle are superior and external to it; the vein is anterior and inferior, concealed by the clavicle. The subclavian arteries send off the following branches, vertebral, thyroid axis, internal mammary, superior intercostal, and deep cervical.

The *vertebral artery* arises from the upper and back part of the subclavian: ascends behind the inferior thyroid artery, enters the foramen in the transverse process of the fifth or sixth cervical vertebra, and ascends through the several foramina in the superior vertebræ as high as the second; it then bends backwards and outwards in an exceedingly tortuous manner, passes through the foramen in the transverse process of the atlas, and curving backwards and inwards round the articulation of this vertebra with the condyle pierces the dura mater; it then ascends obliquely inwards and forwards between the olivary and pyramidal bodies, and at the lower edge of the pons it unites with the opposite, to form the basilar artery; in this course it gives small branches to the spinal nerves, and to the inter-vertebral muscles, at the foramen magnum it gives off, first and second, the *posterior and anterior spinal arteries*, which descend all along the spinal cord; third, the *inferior cerebral artery* (this often arises from the basilar), it runs tortuously around the medulla oblongata, below the vagus, and sends its numerous branches to the inferior surface of the cerebellum.

The *basilar artery* is formed by the confluence of the two vertebral; it ascends in the median groove on the pons varolii, sends small branches to the surrounding membrane, and at the upper edge of that body it divides into four branches, two for each side; first, the *superior cerebellar artery*, passes outwards and backwards, to the upper surface of each hemisphere of the cerebellum, on which it spreads its branches; second, the *posterior cerebral artery*, this receives the posterior branch of the internal carotid, bends backwards and outwards, and spreads its ramifications on the posterior lobe of the cerebral hemisphere. The communication between these posterior cerebral arteries and the posterior branches of the internal carotids, completes that remarkable inosculation named the "circle of Willis;" this is formed anteriorly, by the two anterior cerebral arteries with their cross uniting branch, laterally by each internal carotid and its posterior communicating branch, and posteriorly by the trunk of the basilar and the roots of the posterior cerebral arteries

The *thyroid axis* arises from the upper part of the subclavian, close

to the scalenus and phrenic nerve; it immediately divides into the four following branches:—First, the *inferior thyroid*, ascends tortuously behind the common carotid, then bends downwards and inwards, sends branches to the trachea, œsophagus, &c., and is distributed to the thyroid gland, in which it inosculates with the superior thyroid, and with the arteries of the opposite side; second, the *ascending cervical* ascends along and is distributed to the anterior scalenus, longus colli, and rectus capitis anticus major muscles; third *supra-scapular* runs obliquely outwards and downwards beneath the clavicle, passes above the notch in the superior costa of the scapula, supplies the supra-spinatus muscle, and descends beneath the acromion process to the infra-spinatus and teres minor muscles; fourth, *transversalis colli* ascends obliquely outwards round the scaleni muscles, and beneath the trapezius; it divides into two branches, one, the *cervicalis superficialis*, supplies the superficial muscles on the side and back part of the neck; the other, the *posterior scapular artery*, descends beneath the levator anguli scapulæ, and the rhomboid muscles, along the base of the scapula as far as the inferior angle, where it inosculates with the subscapular artery; the posterior artery of the scapula, as also the supra-scapular, in many subjects, arise distinctly from the subclavian artery.

The *internal mammary artery* arises opposite the thyroid axis, it descends obliquely forwards and inwards, between the cartilages of the ribs and the pleura, as far as the ensiform cartilage; it gives branches to the pleura, pericardium, and mediastinum, a long branch to the diaphragm, which accompanies the phrenic nerve, also intercostal branches, which inosculate with the aortic intercostals; it terminates by sending branches to the diaphragm, and to the abdominal muscles; the latter inosculate with the epigastric artery.

The *superior intercostal artery* arises between the scaleni, descends behind the pleura, in front of the neck of the first and second ribs, and supplies the two first pair of intercostal muscles.

The *cerrvicalis profunda* arises opposite the last, ascends obliquely backwards and outwards, between the transverse processes of the sixth and seventh cervical vertebræ, and ascending on the back of the neck, supplies the complexus and the other deep muscles in that region, and inosculates with the descending branches of the occipital artery.

The *axillary artery* descends from the lower edge of the first rib, obliquely outwards, to the tendon of the latissimus dorsi muscle, is covered by the integuments, and at first by the external border of the great pectoral muscle, and still lower down by the tendon of the great pectoral only; it passes over the first intercostal, and serratus magnus muscles, the brachial plexus, the subscapular, and the tendons of the latissimus dorsi and teres major muscles; the axillary vein descends along its inner and anterior part, and the brachial plexus lies posterior and external to it; it sends off the following arteries, the thoracica acromialis, the superior and long thoracic, the subscapular, the posterior and anterior circumflex.

The *acromial thoracic artery* arises from the front of the axillary

below the subclavian muscle, above the lesser pectoral, and opposite the fissure between the great pectoral and deltoid muscles; it divides into several branches, which pass, some to the pectoral muscles, others to the acromion process, deltoid muscle, and integuments of the shoulder and arm; one long branch accompanies the cephalic vein.

The *superior thoracic artery* arises a little below the preceding, sometimes in common with it; it passes forwards and inwards, and divides into branches which supply the cellular membrane and glands in the axilla, the pectoral muscles, the breast, and the integuments.

The *long thoracic artery* arises below the lesser pectoral, descends obliquely forwards, along the side of the chest, parallel to the lower edge of the great pectoral, to which it sends some branches; it terminates in the intercostal muscles and integuments, and inosculates with the internal mammary and the intercostal arteries.

The *subscapular artery* arises opposite to and descends along the lower edge of the subscapular muscle, and soon divides into an anterior and posterior branch; the former continues to descend along the back part of the axilla, and supplies the subscapular, serratus magnus, and latissimus dorsi muscles; the latter passes backwards round the inferior costa of the scapula, behind the long tendon of the triceps, and above the latissimus and teres major muscles; it is distributed on the dorsum of the scapula to the infra-spinatus and teres minor muscles, and inosculates with the supra-scapular artery.

The *posterior circumflex artery* arises below the last, sometimes in common with it, it passes out of the axilla between the long tendon of the triceps and the humerus, turns round this bone between it and the deltoid muscle, to which last it sends numerous branches.

The *anterior circumflex artery* is smaller than the preceding, and arises either from it or from the axillary; it passes outwards round the anterior part of the humerus, beneath the deltoid, coraco-brachialis, and biceps; to these muscles it sends its branches; it also sends one long branch along the bicipital groove to the synovial membrane of the shoulder joint.

The *brachial artery* descends obliquely outwards to the bend of the elbow, where it divides into the radial and ulnar arteries; it is covered by the skin and brachial aponeurosis, and inferiorly by the fascia of the biceps, and the median basilic vein; it lies on the inner side of the coraco-brachialis and biceps, and passes over the upper part of the triceps, the coraco-brachialis, and the brachiæus anticus; it is accompanied by a vein on either side, also by the median nerve, which above lies to its outer, and below to its inner side; it passes superficial to the artery about the middle of the arm: in addition to several muscular branches it sends off the superior and inferior profunda, and the anastomotica.

The *superior profunda* arises below the teres major, accompanies the musculo-spiral nerve obliquely downwards and outwards, between the three heads of the triceps, and in the musculo-spiral groove of the humerus; it divides into two large branches, one descends in the

triceps to the olecranon, the other accompanies the radial nerve to the outer condyle, and communicates with the radial recurrent artery.

The *inferior profunda* arises opposite the tendon of the coraco-brachialis, descends on the surface of the triceps, along with the ulnar nerve, to the inner condyle, and communicates with the ulnar recurrent.

The *anastomotica* arises about two inches above the joint, passes inwards, supplying the adjacent muscles, and inosculating with the preceding and with the ulnar recurrent arteries.

In the triangular hollow at the bend of the elbow, the brachial artery divides into the radial and ulnar.

The *ulnar artery* is the larger of the two, it descends along the ulnar side of the forearm to the palm of the hand, covered superiorly by the superficial flexors and pronators, and by the median nerve; inferiorly by the skin and fascia, overlapped, however, by the tendons of the flexor digitorum sublimis and flexor carpi ulnaris, between which it descends to the wrist; it passes over the brachiæus anticus, flexor profundus, pronator quadratus, the annular ligament of the carpus, and the flexor tendons in the palm of the hand; it is accompanied by two veins, and by the ulnar nerve, the latter descends along its ulnar side; it gives off, first, the *anterior ulnar recurrent*, which ascends in front of the inner condyle, on the brachiæus anticus, and inosculates with the anastomotica; second, the *posterior ulnar recurrent*, large and tortuous, ascends behind the inner condyle, along with the ulnar nerve, and anastomoses with the anastomotica and inferior profunda arteries; third, *interosseal artery*, passes backwards and divides into an anterior and posterior branch; the *anterior interosseal artery* descends along the forepart of the interosseal membrane, beneath the deep flexors, pierces that membrane near the pronator quadratus, and descends on the back part of the carpus, and is distributed to the carpal bones, and to the sheaths of the extensor tendons; the *posterior interosseal artery* passes backwards beneath the anconæus, and descends along the back of the forearm, sending its branches to the extensor muscles; this artery superiorly sends a very large recurrent branch in the anconæus muscle to the olecranon, to communicate with the superior profunda; fourth, *muscular branches* to the two layers of flexor muscles, and to the skin; fifth, *dorsalis carpi ulnaris* turns round the lower end of the ulna, and spreads its branches on the back part of the wrist and hand; sixth, *superficial palmar*, forms the palmar arch, bends obliquely across the palm of the hand towards the thumb, and inosculates with branches of the radial artery; seventh, *ramus profundus*, passes beneath the flexor tendons, crosses the fifth and fourth metacarpal bones, joins the deep palmar branch of the radial artery, and thus completes the deep palmar arch; from the superficial arch long digital branches pass, these divide and supply the opposite sides of all the fingers, except the radial side of the index finger and the thumb.

descend; the former inosculate with the cervical arteries, the latter with the abdominal.

The *intercostal arteries*, in general ten on the left, nine on the right side, the superior intercostal on the right side being larger than that on the left; they arise from the back part of the aorta, pass obliquely outwards behind the pleura, and enter the intercostal spaces, run along the lower edge of each rib between the layers of muscles, and about the middle of the chest divide into an inferior and superior branch; the former, smaller, runs along the superior border of the lower rib; the latter continues in the groove in the upper; they both supply the intercostal muscles, and send branches through these to the pleura and to the superficial muscles of the chest: they inosculate with the internal mammary and with the thoracic arteries. Each intercostal artery, before it enters the intercostal space, sends a large branch backwards, between the transverse processes of the vertebræ, to the muscles on the posterior part of the trunk; these *dorsal branches* of the intercostal arteries also send small branches through the intervertebral holes, along the spinal nerves, to the medulla spinalis.

The Abdominal Aorta commences below the tendinous arch, between the crura of the diaphragm in the median line, descends with a slight obliquity to the left, and divides at the lower margin of the fourth lumbar vertebra into the two iliac arteries; the middle sacral may also be considered as one of its terminal branches. The following are its principal relations; anteriorly, the solar plexus, the stomach, pancreas, and termination of the duodenum, mesentery, and small intestines, the left renal and splenic veins, and the head of the vena porta; on its right side, the right semilunar ganglion and inferior vena cava, and the commencements of the thoracic duct and vena azygos; on the left side the peritonæum, as it is about to form the left lamina of the mesentery, the left semilunar ganglion, and the sympathetic nerve; posteriorly, the left lumbar veins and the four superior lumbar vertebræ, with their anterior and their intervertebral ligaments: it sends off the following branches, the phrenic, cœliac axis, superior mesenteric, inferior mesenteric, renal, suprarenal, spermatic, lumbar, and middle sacral.

The *phrenic arteries* arise in common, or near each other, from the forepart of the aorta; they both send branches to the suprarenal capsules, and to the crura of the diaphragm; the *right* ascends behind the vena cava; the *left* behind the œsophagus: on the diaphragm each divides into an external and internal branch; the former passes towards the circumference of the muscle, and inosculates with the internal mammary and the inferior intercostals; the latter encircles the central tendon, communicates with its fellow and with the phrenic branches of the mammary.

The *cœliac axis* arises from the forepart of the aorta opposite the last dorsal vertebra; it soon divides into three branches, first, the *gastric artery* ascends obliquely to the left side, to the cardiac orifice, to which and to the œsophagus it sends several branches; it then bends

along the lesser curvature towards the right side, between the laminæ of the lesser omentum, and inosculates with the superior pyloric artery; it sends its branches to the anterior and posterior surfaces of the stomach; second, *hepatic artery* ascends obliquely towards the right side, in front and to the left side of the vena porta and ductus choledochus, and in the transverse fissure of the liver divides into right and left hepatic arteries. In this course it gives off the *superior pyloric*, which passes along the upper surface of the pylorus, and joins the gastric artery; and the *gastro-duodenalis*, which descends between the pylorus and the duodenum; this gives off *inferior pyloric* branches, and divides into *pancreatico-duodenalis* and *gastro-epiploica dextra:* the former takes a curved course between the duodenum and the pancreas, sending branches to each, and inosculates with the superior mesenteric artery; the latter turns forwards, and to the left side, along the great curvature of the stomach, between it and the laminæ of the great omentum, to which, as well as to the stomach, it sends numerous branches, and inosculates with the gastro-epiploica sinistra, a branch of the splenic artery. The right and left hepatic arteries then separate and plunge into the substance of the liver, accompanying the branches of the vena porta: the right hepatic is the larger, and before it enters the gland it gives off the *cystic artery*, which supplies the parietes of the gall-bladder; third, the *splenic artery* is the longest branch of the cœliac axis; it passes backwards and to the left side, along the upper edge of the pancreas, to which it sends several branches. Near the spleen it gives off the *gastro-epiploica sinistra;* this bends forwards, and to the right side, along the great curvature of the stomach, and between the laminæ of the great omentum it inosculates with the corresponding branch from the hepatic artery. It next sends off the *vasa brevia*, five or six small branches which pass to the great end of the stomach, and inosculate with the proper gastric arteries. The splenic artery then divides into several branches, which enter the foramen on the concave surface of the spleen, and ramify through its spongy substance.

The *superior mesenteric artery* arises below the cœliac, descends obliquely forwards and to the left behind the pancreas, and over the duodenum; it then passes between the layers of the mesentery, and takes an arched course towards the right iliac fossa; from its concave side arise three branches, the *ileo-colic*, *right colic*, and *middle colic;* these three branches proceed between the laminæ of the mesocolon to the large intestine; each divides into two branches, which unite with those on either side, and form arches, from the convexities of which branches arise, some of which subdivide and unite again in the same manner as the first branches. Near this intestine straight branches proceed on the anterior and posterior surface, and supply the muscular and mucous coats; from the convex side of the mesenteric artery eighteen or twenty branches arise; these proceed between the laminæ of the mesentery, divide, and form arches, from which new branches arise; these again divide, and again unite in an arched manner: these

divisions and subsequent inosculations occur three or four times before the arteries arrive at the intestine; near the latter each branch divides into two, which proceed in a direct course, one on the anterior, the other on the posterior surface of the intestine, and are distributed principally to the submucous tissue.

The *inferior mesenteric artery* arises about two inches below the preceding; it descends towards the left iliac fossa, and divides into three branches, left colic, sigmoid, and superior hæmorrhoidal; the *left colic* ascends in the left mesocolon, anastomoses with the middle colic branch of the superior mesenteric, and supplies the left part of the colon. The *sigmoid artery* is distributed to the sigmoid flexure of the colon. The *superior hæmorrhoidal* descends along the back part of the rectum, supplies the coats of this intestine, and inosculates with the middle and inferior hæmorrhoidal arteries.

The *renal arteries* arise from the sides of the aorta, between the superior and inferior mesenteric arteries; the right is longer than the left; it passes across the spine behind the vena cava: both pass behind their corresponding vein, and divide near the kidney into five or six branches, which ramify through the substance of this gland.

The *capsular arteries* are two or three in number; they arise either from the renal arteries or from the aorta; they supply the renal capsules.

The *spermatic arteries* arise from the forepart of the aorta; the left frequently arises from the renal artery; they are long and tortuous, descend obliquely outwards, crossing in front of the psoas muscle and the ureter. In the male they accompany the vas deferens of each side through the inguinal canal, and supply the testis and epydidymis; in the female they pass to the ovaries, and also send branches to the Fallopian tubes, and to the sides of the uterus.

The *lumbar arteries* are four or five pair; they are analogous to the intercostal arteries, and arise from the back part of the aorta, pass obliquely outwards through the psoas, send branches between the transverse processes of the lumbar vertebræ to the muscles of the back and loins, and some also into the spinal canal, along the nerves, through the intervertebral foramina; the terminating branches are distributed to the abdominal muscles, and inosculate with the other arteries which these muscles receive from the intercostals above, the ilio-lumbar and circumflex ilii below, and the epigastric and internal mammary in front.

The *middle sacral artery* arises from the back part of the aorta, a little above the bifurcation; it descends nearly in the median line close to the sacrum, sends its branches to this bone, and communicates with the lateral sacral arteries; in direction the middle sacral, or *caudal artery*, appears as the continuation of the aorta, and such it really is in fish, and in other animals when the tail is large and posterior limbs small.

The *right and left common iliac arteries* arise and diverge from the bifurcation of the aorta, which usually occurs on a level with the lower margin of the fourth lumbar vertebra. The point of division,

however, is variable, sometimes higher, sometimes lower; the angle of bifurcation varies accordingly, but it is always more open in the female, on account of the greater breadth of the sacrum; these vessels descend obliquely outwards as far as the ilio-sacral symphisis, opposite which, and resting against the psoas magnus, each divides into the internal and external iliac arteries; their length is from an inch and a half to two inches, varying of course according as the bifurcation of the aorta is high or low; in old persons they are often remarkably tortuous and irregularly dilated. As the aorta is to the left of the median line, the right iliac artery is usually considered to be a little longer than the left; the difference, however, if any, is very trifling, because the right iliac subdivides into its secondary iliac at a point somewhat nearer the vertebral column than the left does. The right and left common iliacs are covered in front and laterally by the peritonæum, which, however, is but loosely connected to them; the ureter also in general crosses them just before their subdivision, at least on the left side; but very frequently this duct has no such relation to the right, but crosses over its external iliac branch, as the trunk has subdivided nearer to the vertebral column than the line of passage of the ureter; the left iliac artery is also crossed by the inferior mesenteric. The iliac arteries in their descent pass in front of the last lumbar vertebra and its invertebral ligaments, also over the lateral branches of the middle sacral artery and the sympathetic nerve; the left is also in front of the left common iliac vein, and the right is in front of both common iliac veins. The relations, therefore, between the common iliac arteries and veins, differ materially on the right and left sides; the left vein is related to both iliac arteries, it is posterior and internal to the left, but it also passes behind the right iliac artery to join the right vein, which is posterior but external to the right artery.

The *internal iliac* or *hypogastric artery* passes downwards, in front of the ilio-sacral articulation, describing a curve concave forwards, reaches the superior part of the sacro-sciatic notch, when it usually, but not invariably, divides into a number of branches; from its termination a ligamentous cord (the obliterated umbilical artery of the fœtus) extends to the back and side of the bladder, ascends along this viscus, and from it to the posterior surface of the recti muscles as far as the umbilicus; it is covered by the peritonæum, and crossed near its commencement by the ureter, and in its ligamentous portion by the vas deferens; and it has posterior to it the lumbo-sacral nerve, the pyriform muscle; the internal iliac vein is also behind it, but to its outer side. The internal iliac artery gives off the following branches: ilio-lumbar, lateral sacral, hæmorrhoidal, vesical, uterine and vaginal, the glutæal, sciatic, obturator, and pudic. First, the *ilio-lumbar* arises from the back part of the internal iliac, passes outwards behind the external iliac vessels and the psoas muscle into the substance of the iliacus internus, in which it divides into ascending and descending branches. Second, the *lateral sacral* descends obliquely inwards in

front of the sacral holes, through which it sends branches to the spinal nerves, also to the pyriform muscle, and to communicate with the middle sacral. Third, the *hæmorrhoidal* are two or three branches of uncertain origin; they pass to the sides of the rectum, and communicate with the superior and inferior hæmorrhoidal arteries. Fourth, the *vesical arteries* arise from the iliac, or from some of its branches; they ramify on the coats of the bladder; the inferior also supply the parts about the neck of this organ. Fifth, the *uterine and vaginal arteries* either arise from the internal iliac, or from some of its branches, and are distributed as their names imply. Sixth, the *glutæal artery* passes backwards and outwards from the pelvis by the upper part of the sciatic notch, above the pyriform muscle, and divides into several branches, some of which supply the glutæus maximus, others pass forwards in a semicircular course towards the spine of the ilium, and supply the glutæus medius and minimus muscles. Seventh, the *obturator artery* passes out of the pelvis by the superior part of the thyroid hole into the upper part of the thigh, beneath the pectinæus, and divides into several branches to supply the obturator and adductor muscles. Eighth, the *sciatic artery* passes over the pyriform muscle, and escapes from the pelvis by the lower part of the sciatic notch, along with the sciatic nerve; it sends several branches to the glutæus maximus, the hamstrings, and adductor magnus; also to the small capsular muscles and to the sciatic nerve; these communicate with the circumflex and perforating arteries. Ninth, the *internal pudic artery*, smaller than the preceding, leaves the pelvis along with it below the pyriform muscle, re-enters the cavity between the sciatic ligaments, and then ascends obliquely inwards and forwards along the tuber and ramus of the ischium and ramus of the pubis, and a little below the symphysis pubis divides into two branches. In the pelvis the pudic at first gives small branches to the adjoining viscera; as it is passing round the spine of the ischium, and between the sciatic ligaments, it gives small branches to the surrounding ligaments and muscles; when it has re-entered the pelvis it gives off, First, *external hæmorrhoidal arteries*, two or three; they pass transversely to the side of the rectum and anus, and supply the integuments and muscles in that region. Second, the *perinæal artery* first descends, then turns forwards and upwards round the transversus perinæi, proceeds along the perinæum, and is distributed to the muscles and integuments in this situation, and to the scrotum. Third, *transversalis perinæi*, a small branch arising near to and often from the preceding; it takes the course of the muscle of that name, and is lost in the muscles and integuments. Fourth, *artery of the bulb* passes transversely between the layers of the triangular ligament, enters the spongy substance of the bulb, and spreads its branches through the corpus spongiosum urethræ. Fifth and sixth, *artery of the corpus cavernosum and dorsalis penis;* the former enters and extends along the corpus cavernosum, the latter along the dorsum of the penis as far as the glans. In the female the pudic artery gives off branches to the perinæum and labia,

and to the corpus cavernosum and dorsum of the clitoris, analogous to, but smaller than those in the male.

The *external iliac artery* proceeds from the common iliac downwards and outwards to Poupart's ligament, beneath which it passes, and then receives the name of femoral; it lies along the inner side of the psoas; the vein is internal and posterior, and connected to it by a thin fascia derived from the iliac. As these vessels approach the crural arch the vein advances forwards, and appears on the internal or pubic side of the artery. The external iliac artery is covered anteriorly and internally by the peritonæum, which, however, is so loosely connected to its sheath as to admit of easy separation; superiorly the ureter, and inferiorly the spermatic vessels and the genito-crural nerve, are anterior to it, and several lymphatic glands are attached to it; the termination of the ileum intestine and the vermiform appendix are in front of the right, and sigmoid coils of the colon in front of the left. This artery gives off near the groin two branches; first, *circumflexa ilii* arises from its outer side, ascends obliquely outwards as far as the crest of the ilium, where it divides into several branches, some pass to the abdominal muscles, others to the iliacus internus and quadratus lumborum, and communicate with the ilio-lumbar artery. Second, the *epigastric artery* arises from its forepart, a little above Poupart's ligament; it at first descends, then turns forwards, and ascends between the abdominal muscles and the peritonæum, crosses behind the spermatic cord, a little internal to the internal inguinal ring; about three or four inches above the pubis it enters the sheath of the rectus, divides into two branches which ascend in this muscle to the umbilicus, and which inosculate with the internal mammary artery; frequently, in place of the epigastric coming off in the manner just mentioned, a common trunk arises, which soon divides into two branches; one is the epigastric, which ascends and terminates as usual; the other, descending into the pelvis, becomes the obturator artery. The vicinity of this latter branch to the crural ring causes this irregularity to be of some importance in relation to the operation for the relief of strangulated femoral hernia.

The *femoral artery*, or the continuation of the external iliac, descends obliquely inwards from the middle of the crural arch, along the anterior and internal part of the thigh, covered superiorly by the skin, superficial fascia, inguinal glands, and fascia lata; in the middle of the thigh it is also covered by the sartorius, and beneath this by a strong aponeurosis connecting the vastus internus to the tendons of the adductor longus and magnus; at the inferior part of the middle third of the thigh, it passes obliquely backwards through a tendinous opening, bounded externally by the vastus internus, internally by the adductor magnus, superiorly by the united tendons of the adductor magnus and longus, and inferiorly by those of the adductor magnus and vastus internus; the sheath which encloses the artery and vein is very perfect, and may contribute to protect these vessels from the pressure of the surrounding muscles; the femoral artery first passes

over the psoas and iliacus, next over the pectinæus and short adductor, from which it is separated by a quantity of cellular membrane and by small vessels, it next passes over the tendon of the adductor longus; the femoral vein descends along with it, at first internal, afterwards posterior to it; the anterior crural nerve is external to it, two or three of its branches are very near it; above the middle of the thigh, one small nerve crosses the artery, and the saphenus nerve descends in its sheath along the forepart of the vessel; it sends off, first, three or four superficial branches, viz:—*inguinal branches* to the inguinal glands, &c.; the *superficial pudic*, one or two in number, which pass towards the pubis and are lost in the integuments; the *superficial epigastric*, the longest and largest of these branches, ascends obliquely inwards towards the umbilicus, parallel to the internal epigastric, and is lost in the integuments; the *external circumflex ilii* extends along Poupart's ligament to the crest of the ilium, where it terminates in the skin. Second, the *profunda* is the largest branch of the femoral, it arises about two inches below the crural arch, from the outer and back part of the femoral artery, bends a little outwards at first, then descends obliquely inwards and backwards behind the femoral artery, and the tendon of the adductor longus, passing over the psoas, cruræus, and adductor brevis; at the back part of the thigh it terminates in two branches for the hamstring muscles; in this course it gives off the two circumflex, and the three perforating branches. The *external circumflex artery* arises from the outer part of the profunda, passes transversely beneath the sartorius and rectus muscles, and divides into three fasciculi of branches, superior, middle, and inferior; the first ascend along the tensor vaginæ and glutæus medius muscles, and inosculate with the glutæal artery; the second pass round the bone to its back part, and inosculate with the glutæal, sciatic, and internal circumflex arteries; the third are the longest and largest branches, they descend towards the knee and supply the extensor muscles. The *internal circumflex artery* arises sometimes below, sometimes above the preceding, it often proceeds from the femoral itself, it passes backwards between the psoas and pectinæus, along the obturator externus tendon, to the back part of the thigh, first sending off several branches to the surrounding muscles, and through the notch in the acetabulum to the hip joint, also some to inosculate with the obturator artery; at the back of the thigh it gives several branches to the gemelli, quadratus, glutæus maximus, and the hamstrings, and inosculates with the external circumflex and sciatic arteries. The *first* or *superior perforating artery* passes backwards beneath the lesser trochanter, between the pectinæus and adductor brevis, and through the adductor magnus, its branches are distributed to the latter and to the hamstrings; the *second* or *middle perforating artery*, larger than the first, passes through the adductor brevis and magnus, and spreads its branches among the muscles on the back of the thigh; the *third* or *inferior perforating artery* descends behind the adductor longus, and through the magnus, to the hamstrings; on

the back part of the thigh the profunda ends in two branches, one passes to the biceps, the other to the semi-membranosus.

After the origin of the profunda, the femoral gives off several small muscular and cutaneous twigs, and near the opening in the triceps, through which it passes, it gives off, third, the *anastomotica magna*, this descends in front of the adductor tendon to the knee, sends several branches to the integuments, vastus internus, and to the patella; these inosculate with the long branches of the external circumflex artery above, and with the articular arteries below.

The *popliteal artery* descends from the inner side of the femur, obliquely outwards to the inferior and central part of the popliteal space; it is covered by the skin and fascia, and overlapped superiorly by the semi-membranosus, and inferiorly by the gastrocnemius and plantaris muscles; the popliteal vein lies superficial and external to it; the sciatic nerve is still more superficial and external, and it rests upon the femur, the posterior ligament of the knee joint, and the fascia of the poplitæus muscle; its branches are, first, several muscular branches to the hamstrings and to the gastrocnemius; second, *superior articular*, encircle the lower extremity of the femur, turn round the sides, to the forepart of the joint, and communicate with the anastomotica and with branches of the external circumflex; third, *azygos-articular*, passes forwards through the posterior ligament of the joint, and supplies the synovial membrane and the adipose substance in its cavity; fourth, *inferior articular arteries*, encircle the lower part of the joint; the internal passes round the head of the tibia, the external is beneath the external lateral ligament; these arteries pass round the joint to its forepart, inosculate with the preceding and with the anterior tibial recurrent; at the lower part of the ham the popliteal divides into the anterior and posterior tibial arteries.

The *anterior* perforates the inter-osseous space close to the head of the fibula, descends obliquely forwards along the interosseous membrane, and over the lower part of the tibia, the synovial membrane of the ankle, and the superior and internal part of the tarsus, to the first interosseal space; in the leg it is overlapped by the tibialis anticus internally, by the extensor communis and extensor pollicis externally; it passes beneath the annular ligament of the ankle; on the tarsus it is covered by the skin and by the internal tendon of the extensor brevis; it is accompanied by two veins; the anterior tibial nerve descends superficial and external to it; it gives off, first, the *recurrent*, which passes upwards and inwards, and is lost around the articulation of the knee; second, *muscular* branches, very numerous, to the muscles on the outer and anterior part of the leg; third, *malleolar branches*, which ramify on the external and internal malleoli; on the former they inosculate with the anterior peronæal; fourth and fifth, *tarsal* and *metatarsal*, are distributed to the bones and ligaments of the tarsus and metatarsus; between the two first metatarsal bones it divides into, sixth and seventh, the *arteria pollicis* and the *communicans;* the former supplies the integuments of the great toe; the

latter the first interosseal muscles, and inosculates with the plantar arteries.

The *posterior tibial artery* descends obliquely inwards between the superficial and deep layer of muscles on the back of the leg, to the space between the heel and inner ankle, where it divides into the internal and external plantar arteries; it is covered by the gastrocnemius and solæus, and lies on the tibialis posticus, flexor communis, and inferiorly on the tibia; it is accompanied by two veins, and by the posterior tibial nerve, which lies to its external side; it gives off, first, several muscular branches to the deep and superficial muscles; second, the *peronæal artery* arises about an inch below the popliteal, descends obliquely outwards towards the external ankle, between the fibula and flexor pollicis; sends numerous branches to the muscles of the leg, and about two inches above the ankle divides into the *anterior* and *posterior perinæal* branches; the former pierces the interosseous ligament, and inosculates with the external malleolar; the latter spreads its branches on the outer side of the heel and of the foot. Between the heel and inner ankle the posterior tibial divides into the internal and external planter; the *internal plantar* proceeds along the internal side of the sole of the foot, supplying the muscles and integuments of the great toe, and inosculating with the adjacent vessels both on the dorsum and in the sole of the foot; the *external plantar*, much larger than the preceding, passes forwards and outwards above the flexor digitorum brevis, as far as the fifth metatarsal bone; it then bends across the metatarsus, along the transversalis pedis, as far as the first metatarsal bone, where it joins the anterior tibial, and thus forms the plantar arch, from which proceed numerous muscular branches, and the digital arteries; these last arise from the anterior or convex edge of the arch, pass forwards, supplying the lumbricales and interossei muscles, and divide each into two branches to supply the opposite sides of the toes.

SECTION I.

ANATOMY OF THE VENOUS SYSTEM.

As there are two arterial systems, one for the red, the other for the black blood, so are there two venous, the pulmonary and the systemic; to these might be added as a third system, that of the vena portæ, which from its many peculiarities deserves separate consideration; it has been already described in the anatomy of the digestive organs (page 269).

The pulmonary, unlike all other veins, contain red blood; they are four in number, two for each lung; they commence in the capillaries in each pulmonary lobule, and emerge from each as a distinct branch; these successively unite with each other, and finally one vein is formed

for each lobe; that from the middle lobe of the right lung joins that from the upper; the superior vein from each lung descends obliquely inwards, the inferior passes more horizontally; the four veins perforate the pericardium, and almost immediately enter the four angles of the left auricle of the heart, their anterior surface alone being invested by the serous membrane. In the lungs the venous branches accompany those of the pulmonary artery and the bronchial tubes, the latter being in the middle, the veins behind, and the arteries in front, but in the root of each lung the veins are anterior, the air tubes posterior, and the artery in the middle; the superior vena cava crosses the right pulmonary vein at a right angle; the left veins have a longer relation to the accompanying artery; although each pulmonary artery in the root of the lung has two accompanying veins, yet each branch of the former, through the lungs themselves, has but one.

The *systemic veins* are distributed through all parts of the body, and return the blood to the right auricle of the heart by three branches, viz.: the coronary or cardiac, and the superior and inferior cava; the coronary vein has been already noticed (page 122). The veins are far more numerous than the arteries, for not only are the latter accompanied in all cases by one, and in most by two veins, but there is also a superficial or subcutaneous order of these vessels without any corresponding arteries. The veins may be compared to a tree, or rather to two trees; the trunk of each is the cava at the heart, the branches of one spread through all the superior portions of the body, and those of the other through the lower, but the cavæ also communicate through the vena azygos, and through the vertebral veins; the areæ of these numerous branches must greatly exceed that of each trunk, the blood, therefore, is always flowing from a wider into a narrower channel, and is thereby accelerated in its course. The veins commence in the capillary system, and are therefore continuous with the arteries; in some parts they appear to arise out of a cellular or spongy, intermediate structure; however it is most probable that the latter is but a venous plexus; from these origins the veins successively unite and form larger branches, until they finally end in two great trunks; both small and large are remarkable for their numerous anastomoses, not merely by inosculations which form a net-work, but by large branches converging and uniting either directly or by transverse communications; the deep and superficial also constantly anastomose, and large veins are often seen to divide and to unite again; in fact, the communications between veins are as free as possible, and present every variety as to form and mode, and are doubtless designed to establish free collateral circulation, which must serve as a protection against any interruption to the circulation, when the course of the blood is impeded in any one particular locality or direction. One peculiar form of anastomosis is by the formation of venous plexuses; these are developed in some parts where greater inflex of blood is occasionally required, as around the neck of the bladder, also around the uterus, and in the spermatic cord.

Veins are composed of the same number of *tunics* as arteries, but the middle lamina is much thinner, therefore they collapse when empty or when divided; the superficial veins are thicker than the deep, and those of the lower extremity more so than those of the upper; the *external* or *cellular coat* is similar to that of arteries, only weaker, or more loose and open, but most probably slightly contractile like it; the *middle* or *fibrous coat* wants the external elastic lamina, but possesses the two other layers of organic contractile fibres, the external circular, the internal longitudinal; the *third*, or *innermost*, or *serous coat*, is stronger, but like to, and continuous with, the arterial, through the capillaries on the one hand, and through the cavities of the heart on the other; the most striking peculiarity in this tissue is the presence of numerous *semilunar folds* or *valves;* each of these is composed of a duplicature of this membrane enclosing some fibrous cords; their concave floating edge is towards the heart, and therefore the blood in its course towards this organ meets with no obstacle from these, but if impeded above them, it will press against these folds, and be supported by them, and thus a reflux will be in some measure opposed; the vein itself is dilated external to each valve, and hence, when distended, it presents a knotted and irregular appearance; these valves are sometimes in pairs, and sometimes single, and at short distances on opposite walls of the tube; they are most numerous in the extremities and in the deep veins, and are generally found at points of confluence; they are absent in the very small veins, also in the large trunks, as the cavæ, iliacs, internal jugular and innominatæ, also in the cerebral veins, and in the whole of the portal system. Sinuses are a modification of veins, they are canals lined by the venous membrane, and surrounded either by the structure of the organ in which they run, as in the uterus, and in the osseous system, or by an unyielding fibrous tissue, as the dura mater in the cranium.

In the descriptive anatomy of the veins, we divide the whole into the deep and superficial: the former are called "venæ comites," as they generally accompany the arteries, their description is, therefore, in a great measure included in that of the latter; the superficial require special attention. From the close proximity of the deep veins to the arteries, the action of the latter may afford some assistance to the circulation through the former, aided as they are by their valves, and by their free anastomoses with other deep veins as well as with the superficial.

We shall trace the veins as proceeding from the extreme parts towards the centre or towards the heart, and we shall describe them as they appear in the different regions of the body, and first:

The *veins of the head and face;* these are superficial and deep; the superficial veins of the head, return the blood from the scalp; the deep veins of the head are those of the brain with the sinuses: these, however, together with the spinal or vertebral veins, we shall postpone until we are examining the anatomy of the nervous system, as they

are intimately connected with the membranes of the great nervous centre, or the cerebro-spinal axis.

The *superficial veins of the head* are the occipital, auricular, temporal, and frontal of each side, they are symmetrical or nearly so, and though superficial, are in a great degree "comites" to the arteries of the scalp, the superior and lateral regions of which contain a capillary net-work of vessels, especially of veins; from this plexus the occipital and auricular veins descend posteriorly, the temporal laterally, and the frontal in front.

The *occipital vein* of each side commences in numerous radicles on the back part of the scalp, accompanies the occipital artery, beneath the trapezius and splenius muscles, and joins the internal jugular vein; it receives several branches near the mastoid process, one of which communicates with the lateral sinus through the mastoid foramen.

The *auricular vein* accompanies the posterior aural artery, receives the stylo-mastoid branch, and joins the external jugular vein in the lower part of the parotid gland.

The *temporal vein* commences in a capillary net-work on the side and vertex of the head by anterior, middle, and posterior branches; these unite near the zygoma, and are joined by the middle temporal vein, which perforates the temporal fascia, and returns the blood from the temporal muscle; the temporal then descends between the articulation of the lower jaw and the meatus auditorius, sinks into the parotid gland, and is joined by the internal maxillary behind the neck and ramus of the lower jaw; this confluence forms a short trunk called temporo-maxillary, which forms or ends in the external jugular.

The *frontal vein* descends in the median line, sometimes double, sometimes single; the branches of these veins are expanded over the forehead, and inosculate with the temporal on each side. At the root of the nose they form a transverse arch, which joins at either end the angular vein, a branch of the ophthalmic, and the commencement of the facial; the frontal receives supra-orbital, palpebral, and nasal branches. All the veins of the scalp receive veins from the bones of the cranium, or from the diploe. The *diploic veins*, which were first described by Dupuytren, are canals or sinuses ramifying in an arborescent manner through the diploe; they are lined by the venous membrane, and have no other tunic; the osseous tissue surrounds them, with a little adipose or medullary matter. In the very young these canals are not visible, but a venous net-work traverses the bone: they are most developed in the old. At first each bone has its distinct sinuses, but, when the sutures are obliterated, those of one bone communicate with those of another; these sinuses open both into the external veins and into the sinuses of the dura mater: similar venous canals also exist in the long and spongy bones.

The *veins of the face* are superficial and deep; the former are *the facial* of each side: this vein commences in the angular branch of the ophthalmic, descends obliquely outwards, beneath the zygomatic mus-

cle, passes over the lower side of the lower jaw in front of the anterior edge of the masseter, then through a groove in the submaxillary gland, and joins the internal jugular vein, first receiving the lingual, pharyngeal, and superior thyroid veins; it sometimes enters the external jugular vein, and most frequently communicates with both. On the face this vein receives numerous branches from the dorsal and lateral nasal, infra-orbital, alveolar, masseteric, buccal, coronary, or labial, &c.; it is always a large vein, and in a great measure a "comes" to the facial artery, but by no means so tortuous. The principal deep veins of the face are the ophthalmic, internal maxillary, and lingual.

The *ophthalmic vein* is lodged in the orbit; it returns the blood from the eye and its appendages, commences at the inner canthus, in the small branch, called angular, proceeds backwards along with the ophthalmic artery, but not tortuous like it; it receives several branches which correspond to those of the latter, escapes through the foramen lacerum superius, and enters the forepart of the cavernous sinus: this vein maintains a free communication between the veins of the scalp and face and the cranial sinuses.

Internal maxillary vein commences in radicles corresponding to the several branches of the internal maxillary artery; returns blood from the nose, palate, superior alveoli, pterygoid, and temporal fossæ; passes backwards and outwards internal to the neck of the jaw, where it is joined by the inferior dental and the "comites" of the meningeal or spinous artery; it then enters the parotid gland, joins the temporal, and forms the external jugular, or a short trunk named *temporo-maxillary*, which descends through the gland, and either directly becomes the external jugular, or more generally divides into two, one branch joining the latter, and the other the internal jugular, or some of its branches. The temporo-maxillary vein is superficial to the external carotid artery in the gland; the facial nerve usually intervenes, but is sometimes anterior to the vein; it receives the transverse facial, anterior auricular and glandular veins.

The *lingual veins* are deep and superficial; the former accompany the muscular branches of the artery, and of the ninth pair of nerves, and join the internal jugular, or a communicating branch between this and the external jugular. The ranine, or inferior superficial vein, often ends in the facial. The dorsal superficial veins form a plexus beneath the mucous membrane, branches from which extend towards the base of the tongue, join some pharyngeal and tonsillitic veins, accompany the gustatory nerve, and end in the facial or in the external jugular. The superficial veins of the neck are the external and anterior jugular; the deep veins are the internal jugular, vertebral, deep thyroid, and innominatæ.

The *external jugular vein*, or the continued temporo-maxillary, commences opposite the angle of the jaw, descends obliquely backwards to the centre of the clavicle, then turns a little forward beneath the outer border of the sterno-mastoid muscle, and enters the subclavian to the outer side of the internal jugular vein; it crosses the sterno-

mastoid muscle, commencing in front, and ending behind it; its central portion is subcutaneous, and partially covered by the platisma, but above and below it is beneath the cervical fascia: its upper portion is accompanied by some of the ascending filaments of the cervical plexus of nerves; inferiorly it is superficial to the omo-hyoid and to the brachial plexus of nerves; it usually possesses one or two pair of imperfect valves, and often presents a knotted or slightly varicose appearance, and is sometimes dilated near the clavicle; it receives several branches from the side and back part of the neck, and near the clavicle the superior and posterior scapular veins; it almost always communicates above with the internal jugular, and in its course down the neck with the anterior jugular. This vein is very variable; is sometimes double, and sometimes very small; it returns the blood from the integuments, from the superficial muscles of the neck, and from the external parts of the head, and communicates freely with the internal jugular vein.

Anterior jugular vein, or superficial thyroid, commences about the os hyoides, descends near the median line along the anterior border of the sterno-mastoid, beneath the superficial cervical fascia; near the sternum it turns outwards beneath this muscle, and either joins the external jugular, or opens into the subclavian in front of or close to the internal jugular. These two anterior veins often anastomose by a transverse branch; they return the blood from the superficial parts in the anterior region of the neck, and often communicate above with the internal or external jugular, or with the facial veins. These also are very uncertain as to size; they are usually much larger below than above, and often exceed the external jugular.

The *internal jugular veins* are the channels whereby all the blood from the brain and its membranes is returned; it is also joined by several cervical branches; each commences by a dilatation at the end of the lateral sinus, in the foramen lacerum posticum; accompanies the internal, and afterwards the common carotid artery, to the lower part of the neck, and joins the subclavian to form the vena innominata of each side; it is a large vessel, but variable in this respect, and one is often larger than the other: at its commencement it is dilated; it then continues of uniform size to the os hyoides, where it is usually enlarged, as it receives a number of branches in that situation; at its junction with the subclavian it is often slightly contracted, and above this is dilated into an oval form; in its whole course it is to the outer side of the carotid arteries, but is also a little posterior to the internal carotid; the ninth, and three divisions of the eighth nerve, are to its inner side above, and the styloid process and its muscles are in front of it; lower down the lingual and glosso-pharyngeal nerves pass forwards from between the vein and artery, and the spinal accessory nerve runs behind the vein: in the remainder of its course it is enclosed in a sheath with the common carotid, the descendens colli nerve anterior, and the sympathetic posterior to it, the pneumogastric being enclosed between and rather behind the vessels: as it descends it is

overlapped by the mastoid muscle more than the artery is, which latter also it sometimes overhangs when distended; inferiorly, as the carotids incline inwards, particularly the left, the veins which continue vertical are not so close to them as above; on the right side the subclavian artery and recurrent nerve separate it inferiorly from the vertebral vein; in this course it receives several branches, particularly above, viz., the lingual, pharyngeal, hyoidean, superior thyroid, occipital, &c.

The *vertebral veins* accompany the vertebral arteries only in the canal formed by the chain of foramina in the transverse processes of the cervical vertebræ, but they do not enter the cranium, neither do they correspond to these arteries in function; each commences among the deep muscles beneath the occiput, often receives a branch from the posterior condyloid hole, inosculates with the occipital vein, and enters the canal in the transverse processes, between the foramen magnum and the atlas; as it descends it receives branches from the muscles before and behind the spine and from the spinal canal, it joins the subclavian vein nearly opposite to and behind the internal jugular.

Inferior thyroid or *tracheal veins* form a plexus in front of the trachea and behind the sterno-thyroid muscles; they commence about the thyroid body, communicate freely as they descend, and open, the left into the left vena innominata, and the right sometimes into it also, or into the right vena innominata, or into the cava. These veins are frequently very large, particularly if respiration be laborious or obstructed, and they sometimes cause much embarrassment in tracheotomy.

The *venæ innominatæ* are the two large veins whose confluence forms the superior cava; situated at the lower part of the neck, and partly in the thorax; formed by the union of the subclavian and jugular of each side.

The *left vena innominata*, about three inches long, commences behind the left sterno-clavicular articulation, descends with a little obliquity to the right side, convex forwards, enters the chest and joins the right vein at nearly a right angle, below the first costal cartilage at its junction with the sternum on the right side; the left sterno-clavicular joint, the upper margin of the sternum, and the muscles and fascia attached to it, are in front of it; it covers the roots of the great branches of the aortic arch and the trachea. At its commencement it receives the thoracic duct, and in its course is joined by the left vertebral, the inferior thyroid, internal mammary, superior phrenic, and mediastinal veins.

The *right vena innominata* is fully an inch long, is formed also by the confluence of the subclavian and jugular, descends almost perpendicularly, parallel to and external to the arteria innominata; it receives at its commencement the right absorbent trunk, and in its course the right vertebral vein, and sometimes the right inferior thyroid and right mammary and mediastinal veins.

Superior vena cava descends from the confluence of the venæ innominatæ almost vertically, but slightly convex to the right side; enters the pericardium, and opens into the right auricle behind its appendix.

It is about three inches long, is related on its right side to the right lung, right pleura, and phrenic nerve; the latter becomes somewhat anterior to it; on its left side is the arch of the aorta; anterior to it is cellular membrane, the remains of the thymus gland, and a fascia; behind it are some lymphatic glands, and partly the trachea; the vena azygos joins it posteriorly just before it enters the pericardium; within the latter it is invested in three-fourths of its circumference by the serous membrane, and lies to the right of the arch of the aorta, and in front of the right pulmonary vessels; it receives small branches from the pericardium and mediastinum, and sometimes the right thyroid, and internal mammary and right phrenic veins; it returns the blood from the supra-diaphragmatic portion of the body, and communicates with the inferior cava through the vena azygos and the vertebral veins.

Vena azygos, or *posterior thoracic*, or prelumbo-thoracic. This vein exists in the posterior mediastinum, on the right side of the dorsal vertebræ, but commences in the abdomen opposite the second lumbar vertebra, on the upper part of the right psoas muscle, from the confluence of small veins, branches of the superior lumbar, renal, capsular, and spermatic, which thus indirectly maintain a communication between it and the inferior cava; sometimes also a direct inosculation exists between this trunk and the azygos; in such cases it is usually much larger; it ascends in front of the right crus of the diaphragm, and enters the mediastinum by the aortic passage through or rather behind that muscle, along with and to the right side of the thoracic duct and aorta; it sometimes enters through the right crus with the splanchnic nerve, or external to it; in the mediastinum it ascends on the right side of the vertebral column, increasing in size, in front of the right intercostal arteries, covered closely by the right pleura; the aorta is to its left side, and the thoracic duct, imbedded in adipose tissue, is between them; the right splanchnic nerve is to its right side: opposite the fourth dorsal vertebra it arches forwards and to the right side, around and above the right pulmonary artery and bronchial tube, and opens into the back part of the superior cava, just above the reflection of the serous layer of the pericardium on that vessel. A rudiment of a valve exists at the junction; such folds exist lower down also, but it wants perfect valves. It receives several branches: in its abdominal and diaphragmatic portions, it is joined by one or two superior lumbar veins; in the thorax, by the eight inferior intercostals of the right side, and by the lesser azygos, which is formed by the union of the corresponding intercostals of the left side; some of these, however, occasionally open distinctly into the right azygos; it also receives bronchial, œsophageal, and mediastinal, variable in number and size; its convexity receives some of the right superior intercostals, either separately or by a common trunk. The first intercostal often joins the deep cervical, or the right subclavian, or vena innominata, or the cava; the latter also occasionally receives the second and third.

The *lesser* or *left vena azygos* arises, in the abdomen, in the same man-

ner as the right, often communicates with it, or with the inferior cava, or left renal; it enters the thorax either with and to the left side of the aorta, or through the left crus of the diaphragm, along with the left splanchnic nerve; ascends on the anterior and left aspect of the spine, crosses the seventh or eighth dorsal vertebra, behind the aorta and thoracic duct, and joins the right azygos, having received and combined into one the six or seven left inferior intercostal veins; it also receives phrenic, mediastinal, œsophageal, and bronchial branches. The intercostal veins are twelve pair, and correspond to the arteries of the same name; they commence by small branches anteriorly, where they anastomose with the mammary veins, and accompany the arteries in the groove in the lower border of each rib; near the spine they enlarge, being joined by branches from the posterior spinal muscles, which correspond to the posterior branches of the intercostal arteries; here also at each intervertebral opening they receive the spinal veins, which lead from the vertebral sinuses; the intercostal veins inosculate freely, each with that above and that below; transverse branches also pass from the right to the left, in front of the vertebræ, which, if distended by blood or injection, resemble the transverse sinuses on the back of the bodies of these bones. The left superior intercostal vein joins the subclavian, or some of its branches; the four or five succeeding either descend obliquely across the spine to join the right vena azygos, or they may unite into one trunk, called *superior vena azygos*, which may either join the right or left trunk. The varieties in these posterior thoracic veins are so many that no description can exactly conform to their condition in different individuals. The azygos veins serve to receive and return the blood from the thoracic parietes into the vena cava by a more simple and convenient arrangement than if the intercostals passed separately to the cavæ, or externally to the axillary veins; they may be considered as one very important root of the two cavæ, as they maintain numerous communications between their branches, which secure the course of the circulation, notwithstanding any local impediment in any particular vessel; they even form a loop between these two great veins, through which the blood may pass to the heart, in case the lower cava was obstructed.

The *veins of the upper extremity* are superficial and deep: the *superficial* are in general well developed, but are very variable in this respect; the principal of them are named the cephalic, basilic, and median. The superficial veins of the hand are placed on the dorsal aspect, and are thus removed from the influence of pressure; there are none of any magnitude in the palm; at the elbow they are on the anterior, or the aspect of flexion; on the back of the hand there is a venous arch, concave upwards, or rather a series of arches or loops; these receive two veins from each finger, which anastomose freely with each other and with the deep veins; from this arch branches ascend, two of which are larger and more regular, and have received distinct names, cephalic and basilic.

The *cephalic vein* commences on the outer and back part of the

carpus, ascends along the radial side of the forearm to the bend of the elbow, is there joined by the median cephalic, and continues to ascend along the outer side of the biceps; near the shoulder it turns forwards, and passes towards the clavicle, between the pectoral and deltoid muscles, and then sinks deep to join the axillary vein. In the forearm this vein is accompanied by branches of the external or the musculo-cutaneous nerve, the larger of which generally pass posterior to it, or to the median cephalic at the bend of the elbow.

The *basilic vein* commences from the dorsal arch, near the lower end of the ulna: one branch from the little finger is named *salvatella*, the others are irregular in number and size. It ascends along the ulnar side of the forearm, passes before the internal condyle, where it is joined by the median basilic vein; it then continues to ascend along the inner side of the arm, parallel to the brachial vessels, pierces the fascia, and near the axilla joins one of the venæ comites, or the axillary vein itself; it is accompanied by the internal cutaneous nerve, which is usually superficial to it.

The *median vein* arises a little above the wrist, ascends along the middle of the forearm to the bend of the elbow; it here divides into two branches, one (median basilic) joins the basilic vein, the other (median cephalic) joins the cephalic vein; sometimes a third branch joins one of the deep veins. The median basilic is more thinly covered than the other veins, is thrown forwards by the pronator teres and the biceps, which are behind it; it lies in front of the brachial artery and median nerve; the aponeurosis of the biceps partially separates it from these; it is very often, particularly in thin persons, so close to the artery that the latter is in great danger of being wounded in venesection. The arrangement of the superficial veins in the anticubital region is very variable.

The *deep* veins accompany the brachial artery and its branches in the arm and forearm, two with each, enclosed in the same sheath; these end in the

Axillary vein, ascends in front of the artery, receives the thoracic veins, passes beneath the clavicle, and opposite the lower edge of the first rib is named

Subclavian vein. This passes inwards, over the anterior scalenus and the phrenic nerve, and behind the clavicle and subclavius muscle; receives several veins from the shoulder and side of the neck, also the external and anterior jugular veins, and, opposite the sterno-clavicular articulation, unites with the internal jugular vein to form the *vena innominata*, which has been already described. The right and left subclavian veins do not differ from each other as the arteries do; they are both shorter than the latter, do not rise so high in the neck, and are not so much curved or arched, and, though "comites," are separated from them by the anterior scaleni muscles, and by the phrenic and pneumogastric nerves.

The veins of the lower extremity are superficial and deep; the *former* are the internal and external saphenæ. The superficial veins

of the foot, like those of the hand, are placed on the dorsum, where they form an arch across the metatarsus, which receives the veins from the toes; from the inner and outer sides of this proceed the internal and external saphenæ veins.

The *external* saphena vein passes from the dorsum of the foot behind the external malleolus, ascends along the back of the leg to the ham, and joins the popliteal vein; it is accompanied by the external saphenous nerve, receives several cutaneous veins in its course, pierces the fascia of the leg, and sinks into the groove between the gastrocnemii muscles.

The *internal saphena* commences on the upper and inner part of the foot, ascends in front of the inner ankle along the inner side of the leg, and behind the internal condyle of the knee; it then inclines to the internal and anterior part of the thigh, and ascends to within about two inches of Poupart's ligament, passes through the saphenic opening in the fascia lata, and joins the femoral vein. In the thigh, branches of the anterior crural nerve accompany it, and in the leg the great or internal saphenous nerve twines around it, whose branches, separating and reuniting, enclose and encircle it; it communicates frequently with the external vein, which sometimes joins it at the knee; it also inosculates with the deep veins of the leg and thigh, and receives in the groin branches from the external parts of generation, and from the abdominal parietes, the "comites" to the superficial arteries; it is also joined by some large cutaneous branches from the front and outer side of the thigh; in this region it is straight, but in the leg it is usually tortuous and divides into branches, which separate for a short distance and join again; it is furnished with several valves; its coats are very thick, and both it and its principal branches are frequently in a varicose condition.

The *deep veins* of the leg accompany the arteries, two with each; they terminate in the following:

Popliteal vein, is very closely connected to the artery, lies posterior or superficial to it, and a little to its external side; receives the posterior saphena, the articular and numerous branches from the muscles on the back of the leg; ascending obliquely inwards, it passes through the opening in the tendons of the triceps and becomes the femoral.

Femoral vein ascends in the femoral sheath, closely adhering to the artery, posterior to it below, but internal to it above; it receives muscular branches in all its course, and frequently has one or more small collateral veins which join it at intervals; in the groin it is joined by the profunda and saphena veins.

External iliac vein, or continued femoral, extends from Poupart's ligament, on each side, to the ilio-sacral symphysis, where it meets the internal iliac to form the common iliac; is closely connected to the artery, internal to it near the pubis, but posterior to it as it ascends; near Poupart's ligament it receives the trunk of the two epigastric veins, also that of the two circumflex ilii.

Internal iliac vein accompanies the artery on its inner side; is formed by the union of several veins which accompany and correspond to the branches of the internal iliac artery, viz.: obturator, pudic, sciatic, glutæal, lateral, sacral, hæmorrhoidal, vesical, prostatic, and uterine; the hæmorrhoidal veins are named the inferior and middle, and superior, the latter are branches of the inferior mesenteric vein, which is one of the radicles of the vena porta; the inferior and middle arise from the submucous venous net-work about the anus and lower third of the rectum; these branches are plexiform in their course to the internal iliac and anastomose with the superior hæmorrhoidal. Several veins return the blood from the male organs of generation: those of the scrotum join the saphena or some superficial branches of the femoral vein; those of the testis are the spermatic veins, which join the cava or the renal. The veins of the penis are deep and superficial; the deep or venæ cavernosæ accompany the arteries and end in the internal pudic veins: the superficial veins commence in the prepuce, pass backwards and sink beneath the fascia, end in two or more large veins, dorsal veins of the penis; these receive branches also from the glans and corona and corpus spongiosum urethræ, proceed beneath the pubic ligament, enter the pelvis, and end in the prostatic and vesical plexus; they communicate freely with the deep veins between the crura penis, the prostate and neck of the bladder; are covered, particularly on the sides, by a venous plexus, which is supported by the reflection of the pelvic fascia; from this plexus the vesical veins carry the blood into the internal iliacs. The vagina is surrounded by a venous plexus which communicates with the vesical in front and hæmorrhoidal behind; the uterine veins are in the walls of the uterus and in the broad ligaments; they communicate with the vaginal and vesical plexus, and join the internal iliac and spermatic or ovarian veins; in the gravid uterus, these veins are greatly enlarged, and form the uterine sinuses.

Common iliac veins, are formed by the union of the internal and external, opposite each ilio-sacral symphysis; they ascend converging, and unite at an acute angle opposite the fourth intervertebral ligament, to the right side of, and a little below the division of the aorta; these veins correspond to the common iliac arteries, and are posterior to them; the left is also internal, while the right is external to its accompanying artery; their union, or the commencement of the cava, is crossed by the right iliac artery, therefore the left iliac vein is related to both left and right arteries. The left iliac receives the middle sacral vein, which corresponds to the middle sacral artery; the right does not in general receive any branch except sometimes the ilio-lumbar of that side; the left vein is larger and more oblique, the right is more vertical.

The *inferior or ascending vena cava* ascends along the right side of the aorta, on the right psoas and right crus of the diaphragm, separated from these by the right lumbar arteries, and right emulgent vein; superiorly it inclines to the right, enters the groove in the liver between the Spigelian and the right lobe, passes through the large quadrangular opening in the tendon of the diaphragm, to the margins of which

it adheres, perforates the pericardium, bends a little towards the median line and immediately opens into the lower and back part of the right auricle; it is covered by the peritonæum, the duodenum, pancreas, and vena porta; it receives the lumbar, spermatic or ovarian, renal and phrenic, and lastly the hepatic veins; all the veins from the other abdominal viscera enter the vena porta; the renal are its largest branches, and the cava is always dilated at their junction with it; it is also dilated at the upper part of the hepatic groove, where the hepatic veins enter it; this vein has no valves except the semilunar or Eustachian at the auricular opening.

Lumbar veins are three or four pairs; each commences by the union of posterior or spinal, with external or abdominal branches; those of the left side are longer and pass behind the aorta, the first and second anastomose with the beginning of the azygos.

Spermatic veins pierce the tunic albuginea of the testis on the inside of the epididymis, receive branches from the latter, ascend, and form in the cord the spermatic or pampiniform plexus; from this five or six branches ascend, these diminish in number, and form but one or two, which, having passed through the internal ring, separate from the vas deferens, accompany the spermatic artery along the psoas, and enter either the cava or the renal vein; generally the right joins the cava, the left the renal vein. The *ovarian veins* return the blood from the ovaries and uterine appendages, partly also from the uterus, accompany the spermatic arteries, and terminate as in the male.

Renal or emulgent veins are very large, escape from the hilus of each kidney in front of the artery and ureter; the left is rather longer than the right, as it crosses the spine in front of the aorta and behind the duodenum. As the right kidney is lower down, the right vein is more oblique, the left more transverse; they each receive small branches from the surrounding cellular tissue and suprarenal bodies; the left also, frequently, the left spermatic.

The *capsular* or *suprarenal veins* open partly into the renal and partly into the cava.

The *inferior phrenic veins* follow the phrenic arteries, and open into the cava.

The *hepatic veins* commence in the portal capillary plexus; their small branches successively unite into larger, converge towards the thick edge of the liver, and escape by two sets of branches; one, small, numerous, enter the vena cava, while in the fissure; the other very large and short, only two or three, join it between the liver and the diaphragm. (*See* page 271.) The inferior cava is larger than the superior; it returns the blood from all the infra-diaphragmatic portion of the body; that is, from the inferior limbs, pelvis and abdomen, for, through the medium of the hepatic veins, it collects that which has circulated through the portal system.

This appears to me a fitting place to notice certain peculiarities in the circulatory apparatus in the fœtus; some of these have been already alluded to in the anatomy of the heart, aorta, and liver.

SECTION II.

ANATOMY OF THE FŒTAL CIRCULATION.

DURING uterine life, the heart passes through different stages of development, which are extremely interesting to the physiologist. At first, as in some of the inferior invertebrata, it is unilocular, and merely a dilated and thickened portion of a simple vessel, which is venous in the lower, arterial in the upper end. It soon becomes enlarged, bent, or looped, and subdivided into two parts, an auricular and ventricular; it is then a bilocular heart, the type of the organ in fish, the lowest of the vertebrata. By degrees the ventricle becomes divided into two by a partition or septum; it is then trilocular, and represents the type of the organ in reptilia, in the several classes of which it is differently modified. A septum auricularum is next gradually developed, and the heart is then the quadrilocular organ of birds and mammalia. At birth the heart is large in proportion to the body, and more vertical or median; the two ventricles are of equal size, and descend to the apex, which is therefore rounder, and by a little dissection is made bifid, as in some of the cetacea; there is little or no adeps on its surface, and the pericardium is semitransparent. During uterine life, the four chambers of the heart cannot act independently, and the pulmonary circulation cannot proceed through the condensed, or, as yet, non-expanded lungs; a communication, therefore, must necessarily exist between the right and left cavities of the heart, to counterbalance this obstruction; accordingly, there are two peculiarities which are beautifully contrived, not only to suit the previous condition of existence, but also to meet the exigencies of the moment when independent life is to commence: these are, the foramen ovale, with its valve in the septum auricularum, and the ductus arteriosus or communicans between the pulmonary artery and aorta: through the former the auricles communicate, so as to form as it were but one chamber, and to constitute the heart trilocular; while the ductus arteriosus answers the same purpose as an opening in the septum ventriculorum, so that, in reality, the fœtal heart is a bilocular organ. As soon as respiration has commenced, the blood from the right ventricle is carried by the right and left branches of the pulmonary artery, which are now enlarged, into the expanding lung; the ductus arteriosus or middle branch is thereby diminished or closed, the pulmonary circulation is established, and the blood returns to the left auricle; the valve of the oval hole now closes it, and being pressed against its circumference, it soon adheres, and thus, almost in a moment, the trilocular or essentially bilocular heart is changed into the perfect quadrilocular organ. There are some other arrangements in this piece of exquisite machinery equally worthy of notice, and which will be better understood when the course of the umbilical vessels shall have been examined. The fœtus is connected to the placenta by the umbilical cord, which consists of one vein (umbilical) and two arteries (hypogastric or umbi-

lical); as respects function, however, these names are ill applied, for the vein performs the office of an artery, and conveys pure or nutrient blood from the mother into the body of the child, while the arteries return from the latter to the placenta the blood which has circulated through it; the first, however, is called "vein," because it joins the venous system in the child, and the latter "arteries," because they arise from the aorta.

Fig. 67.*

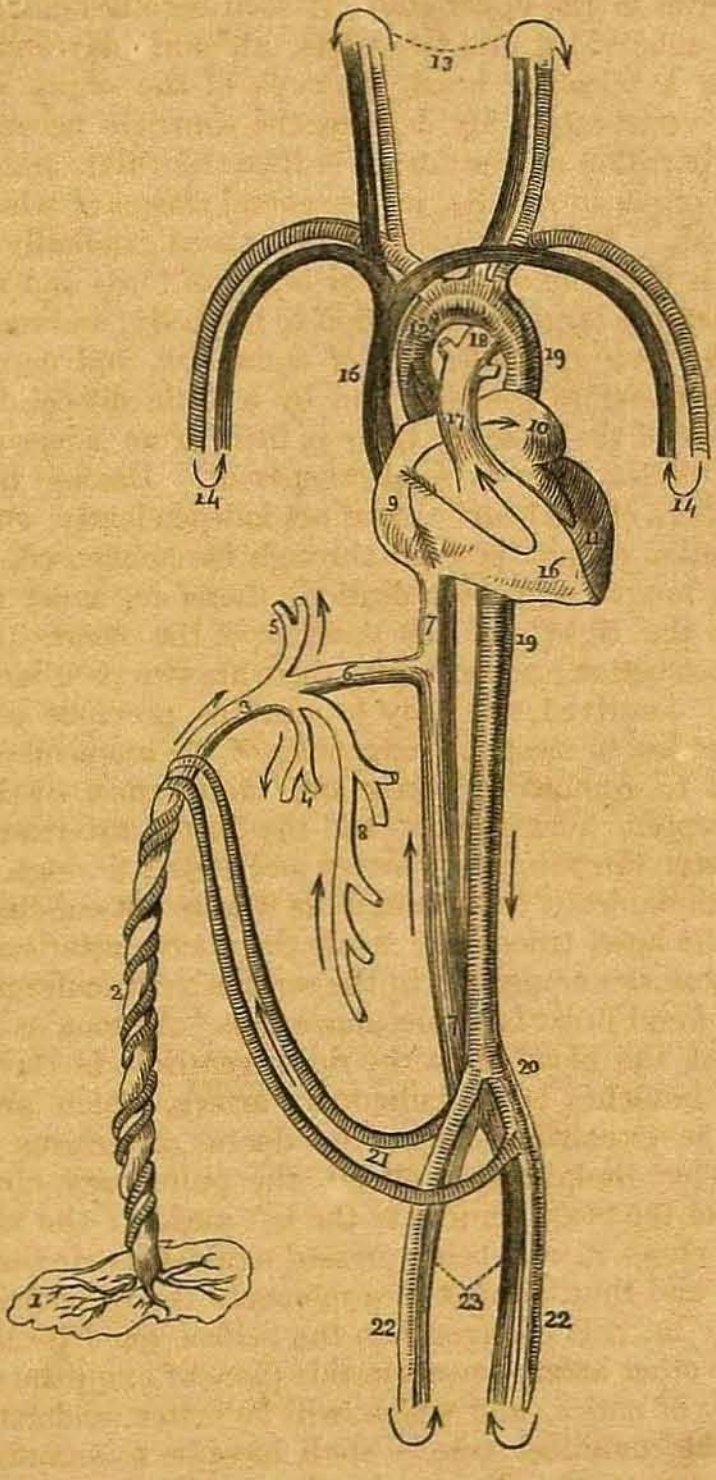

* The fœtal circulation. 1. The placenta. 2. The funis or umbilical cord, consisting of the umbilical vein and two umbilical arteries. 3. The umbilical

The *umbilical vein* arises by numerous branches from the placenta, extends along the umbilical cord, twisted round the arteries, enters at the umbilicus, ascends obliquely backwards, enclosed in the duplicature of the falciform fold, behind the linea alba and right rectus muscle; arrives at the notch in the anterior edge of the liver, proceeds backwards along the horizontal fissure, sending branches to either side, particularly to the left lobe, which at this period of life is of considerable size. Having arrived near the transverse fissure, it divides into two branches, the right or communicating, the left or the ductus venosus: the *right* is the larger, passes transversely for about an inch, and joins the trunk of the vena porta; the *left*, or the *ductus venosus*, ascends and passes backwards between the left and Spigelian lobes towards the diaphragm, and joins the middle hepatic vein just as it is about to join the vena cava. Within the latter this stream of pure blood becomes mingled with that which is returning from the lower part of the body: the lower cava then opens into the right auricle, close to and opposite the foramen ovale, and pours its blood through this into the left auricle; the Eustachian valve is in front of it, and serves not only to direct its current towards that opening, but also, in some measure, to separate or shut it off from the general cavity of the right auricle, and thus to prevent the blood of the inferior from intermingling freely with that from the superior cava; from the left auricle the blood descends into the left ventricle, is then propelled into the arch of the aorta and into its carotid and subclavian branches, to supply the neck, head, and upper extremities. As this portion of blood contains the fresh supply from the mother, it is supposed by some to account for the superior development of the head, neck, and arms, the two former containing the organs of sense and of deglutition, which are necessary to life, and the latter also are important as agents for prehension. The blood which supplies these parts is returned by corresponding veins to the superior cava, and by it to the right auricle; in this chamber it is supposed, as was already mentioned, to be kept

vein dividing into its branches, namely, one (14) to the right lobe of the liver, one (5) to its left lobe, and one (6) the ductus venosus, which joins (7) the inferior vena cava. 7. 8. The vena porta uniting with the right hepatic branch. 9. The right auricle. 10. The left auricle; the arrow extending from 9 to 10 points out the course of blood from the inferior cava, through the foramen ovale, into the left auricle. 11. The left ventricle. 12. The arch of the aorta, from which are given off the great branches to the head and upper extremities, the blood following the course of the arrow from the left ventricle into the aorta. 13. and 14. 14. Arrows to indicate the return of the blood from the head and upper extremities, through the jugular and subclavian veins, to (15) the superior vena cava; thence into (9) the right auricle, and in the course of the arrow into (16) the right ventricle, by which it is propelled into (17) the pulmonary artery, and through (18) the ductus arteriosus into (19 19) the descending aorta. The right and left pulmonary are of small size at this period of life; they are represented cut off immediately before the commencement of the ductus arteriosus. 20. The division of the aorta into the two common iliacs. 21. The two internal iliac or hypogastric arteries becoming the umbilical arteries, by which the blood is returned from the fœtus to the placenta. 22. 22. The external iliacs, by which the lower extremities are supplied with blood. 23. The external iliac veins, which return the blood to (7) the inferior cava.

distinct by the Eustachian valve from the blood of the inferior cava, which was directed through the foramen ovale into the left auricle; the right auricle then impels the blood of the superior cava into the right ventricle, and this into the pulmonary artery; this vessel now divides into three branches, viz., the right and left pulmonary, which are very small, and pass off laterally to each lung; and a central branch, the *ductus arteriosus*, which is very large, and about half an inch long; it arches backwards and downwards in the direction of the trunk of the pulmonary artery, and joins the descending aorta, just below the arch; through this middle branch the greater portion of the blood from the right ventricle passes directly into the aorta, and there mingles with so much of the purer blood of the left auricle and ventricle as did not enter into the carotids and subclavians; the small quantity which the right and left pulmonary branches circulate through the lungs will be returned, as in future, to the left auricle. The descending aorta proceeds as in the adult, distributes its branches to the abdominal viscera and parietes, and divides into the common iliacs; each of these again subdivides into external and internal iliacs; the external iliacs or femorals are small, and supply the lower extremities, which are by no means so fully developed as the upper, locomotion being a function only in prospect. The internal iliac, or hypogastric or umbilical arteries, are very large; they curve forwards and upwards along the sides of the bladder to the abdominal muscles; converge, and sometimes anastomose; ascend behind the linea alba, escape by the umbilicus, enter the cord, twine round the vein, arrive at the placenta, often communicate, and then divide into numerous branches, ramify through that organ.

When birth has taken place, and the umbilical cord has been divided, and its vessels tied, the blood coagulates in these and in the ductus venosus; they become gradually contracted and impervious, and, in process of time, appear as mere fibrous cords; the right or communicating branch of the umbilical vein, however, is not closed, but continues pervious, enlarges, and becomes the left branch of the vena porta. The foramen ovale is shut by its valve, which soon adheres to the edges; a fossa, surrounded by an annulus, always remains on its right aspect; in many cases the valve does not adhere above, but still the passage is so narrow and so oblique that no communication between the auricles exists; the ductus arteriosus also soon becomes closed and impervious, the blood being directed into each enlarged lateral channel, and the left bronchus pressing on it from below; it remains in after-life a mere ligamentous band, between the aorta and the root of the left pulmonary artery; the umbilical vein assumes the same appearance, and is named the round ligament of the liver; the obliterated umbilical arteries are called the superior ligaments of the bladder, and the remains of the ductus venosus still continue in its fissure in the liver; it is, however, often nearly removed, or rendered cellular by absorption.

The course of the fœtal circulation is considered by many to be in

two distinct currents, which cross each other in the heart without intermingling there, and then branch off through the upper and lower parts of the body; these currents are likened to the figure of 8, and may be described as superior and inferior. The *superior* commences in the inferior cava, passes through the foramen ovale, the left auricle and ventricle, into the arch of the aorta, and along its carotid and subclavian branches to the neck, head, and arms, and returns by the corresponding veins to the superior cava. Here the other, or *inferior current*, commences, and descends through the right auricle, right ventricle, pulmonary trunk, and ductus arteriosus, into the descending aorta, to the iliac arteries, through the internal of which a large and important offset passes out of the system, while the remainder descends along the femorals to the lower extremities, and returns by the corresponding veins to the inferior cava, which receives the abdominal and hepatic veins with the ductus venosus, and ascends to the diaphragm, where this current may be supposed to end and the other to commence; or these two currents might be described as commencing and ending in the capillary systems of the upper and lower regions of the body. This theory is supported by the anatomical facts of the inferior cava facing the foramen ovale, and being connected to it by the Eustachian valve; and it is also adduced to account for the superior development of the upper parts of the body, as they are supplied from that current which is supposed to contain the fresh maternal blood. Plausible and pleasing, however, as this theory appears, some objections may be offered to it. The existence of such distinct currents is not proved, and the possibility of it may be questioned; the Eustachian valve is not competent in all cases, or during the whole of uterine life, to effect the supposed separation in the right auricle; neither is the foramen ovale as large as the inferior caval opening; it is, therefore, by no means certain that the streams from the two cavæ can be kept perfectly distinct in the right auricle. Again, to maintain the theory and the use of these separate currents, we must suppose that the arteries empty themselves at every systole, but this is certainly not the case; these vessels are always more or less full, and each ventricular contraction only urges on a fresh wave, whose impetus extends through the whole, even through the capillary system; the arterial systole only recoils so as to restore the vessels to their former state, but not to empty them. How, then, can distinct currents be conducted, or how can one portion of blood in the arterial system be separated or selected for one particular region? As to the superior development of the upper parts of the body, a fact which is adduced in support of this theory, it may be observed that nutrition and growth are under the influence of the nervous system, and of other and higher laws than any mechanical arrangement in the supply of blood; these functions commence and proceed on a certain and preordained scale of proportion in each part, long before any such distinct currents could have been established; and we even see in the fœtus some organs highly developed in comparison with contiguous ones, where no such explanation as difference in vas-

cular arrangement can apply ; the thymus, for example, and the suprarenal bodies. I shall not pursue this argument further by instituting any comparison between the quality of the blood in these two supposed currents, as all that has been advanced on that head is merely hypothetical. Without adopting this theory, I have always regarded the ductus arteriosus, and the foramen ovale with its valve, as simple but beautiful arrangements, not merely suited to uterine existence, but ingeniously and prospectively designed to meet the sudden change and sudden emergency that must occur at the commencement of extra-uterine or independent life. In apposition with the pericardium in the infant is the thymus body, which may next be noticed.

SECTION III.

ANATOMY OF THE THYMUS BODY.

THIS body is usually termed "gland," although it possesses no excretory duct, unless we consider the lymphatic vessels, which pass out of it, as answering that office, according to the opinion of Sir A. Cooper, who has published a beautiful and excellent monograph of this organ. It occupies the greater part of the anterior mediastinum, descends nearly to the diaphragm, in front of the pericardium, and ascends in the neck anterior to the great vessels, and on either side of the trachea as high as the thyroid body, is covered by the sternum, and sterno-hyoid and thyroid muscles : it is symmetrical, or composed of two oblong lobes, connected together by cellular tissue, but not by glandular structure, as in the thyroid body. It enlarges towards the latter periods of uterine life, and even during the first year afterwards; it then gradually decreases, and about puberty has nearly disappeared; a cellulo-adipose tissue occupies its place. It consists of a number of grains or lobules of various sizes, held together by cellular tissue, which also forms a general capsule ; each contains a small cell ; these cells communicate with a central reservoir in each lobe, lined by a soft, vascular membrane, on which the pores of the cells are visible ; the cavity is filled with a milky, chylous fluid : its nutrient arteries are derived from the mammary and thyroid, and the veins enter the innominatæ and thyroid ; the lymphatics join the large absorbent trunks near their termination in the great veins. Its function, Sir A. Cooper ingeniously supposes, is to prepare a fluid, which is like chyle, and fitted for fœtal growth before birth, and before chyle can be formed from food, and that this continues for a short period even after birth, but gradually declines as digestion becomes fully established.

SECTION IV.

ANATOMY OF THE LYMPHATIC OR ABSORBENT SYSTEM.

THE function of absorption is indispensable to nutrition: its agents are, the numerous minute vessels named the "absorbents," and the small, reddish bodies, through which these vessels pass, the "absorbent or conglobate lymphatic glands." The *absorbents* are divided into two classes, each named from their contents, lacteals and lymphatics. The LACTEALS are only found in the abdomen, and are so called from the milky appearance of the chyle, which they absorb from the intestinal villi, and which is conveyed by their trunk, the thoracic duct, into the general circulation, and which vessel is, therefore, the inlet for the fresh nutritive materials derived from the digestive process. The LYMPHATICS are so named from the clear fluid or lymph they contain; they are distributed through all parts of the body, and their office is to absorb in every tissue all matters that have become effete and useless; these, being first reduced to a state of solution, are conveyed into the general circulation, either to be discharged from the system by some of the excretory organs, or to undergo certain changes which will fit them again for the purposes of the economy. The lacteals and lymphatics are so similar, that they are justly regarded as forming but one system. The absorbents have been by some considered as an appendage to or extension of the venous system, and, no doubt, a close resemblance exists between veins and lymphatics: the trunks of the latter also terminate in the large veins, and the structure of each is continuous and similar; like veins, too, they have numerous valves, and, therefore, when distended, present a beaded or knotted appearance; they always accompany these vessels, both deep and superficial, and their currents are in the same direction: on the other hand, they differ from veins in passing through glands, and they continue of small size through their whole course, except in the terminating trunk, and they are less tortuous, and their valves are more numerous and perfect; except at their reticular commencement, and in their passage through the glands, they do not inosculate so freely with each other as the veins do. The exact origin of the absorbent vessels is involved in obscurity: some suppose that they commence in the several tissues, and upon all surfaces, by free open mouths; others that they are continuous with one set of terminating arteries, as the veins are with another, and that while the latter only carry black or impure blood, the former convey the colourless part of that fluid. It is most probable that in the several tissues, whether deep or superficial, they commence in a fine, reticular net-work of vessels, which communicate freely with each other, and that they do not commence in any part by open extremities. Neither have the lacteals open mouths, as formerly supposed, but commence by cæca in the interior of each villus; from these extremely minute origins the branches unite succes-

sively into large vessels, but with very little increase in size until they terminate in the thoracic duct. The lymphatics are arranged, like the veins, into superficial and deep: the former accompany the subcutaneous veins, the latter the deep vessels; they run very parallel to each other, often bifurcate, and either soon re-unite, or join similar adjacent branches; as they approach any of the glands, they converge, each divides into two, which enclose its extremity, and soon enter through its surfaces; these are the *vasa inferentia.* Within the gland they subdivide and inosculate, so as to form an inextricable plexus; from this branches again issue, and leave the gland by its opposite end; these are the *vasa efferentia;* they are fewer, but larger, than the inferentia. All absorbents pass through one gland at least, and some through more, before they terminate in either of the absorbent trunks, which open into the venæ innominatæ. It has been affirmed by many that the lymphatics communicate with the veins in other situations as well as at these terminations; and this opinion is encouraged by considering the very general distribution of the absorbent system, and the importance of its function; also the great number of absorbent vessels compared with the small size of the two thoracic ducts. It has also been affirmed by some that the extreme radicles of the veins and lymphatics anastomose, or are continuous; and, by others, that they communicate in the lymphatic glands; also that in some situations the absorbents join large veins, such as the porta, renal, or lower cava. These statements, however, are at such variance with those of many other writers, that we must consider the question as still undetermined, and one whose true decision requires much patient investigation. The structure of absorbent vessels is very similar to, but more delicate than that of veins: they have three coats, but the middle, as in the veins, is thin, and wants the elastic lamina. The parietes of the thoracic duct are thinner than those of a vein of the same magnitude. The lymphatic or conglobate glands are very numerous both in the extremities and in the trunk; their size varies from that of a small currant to an almond; the largest are in the groin and in the roots of the lungs; in general of a pale reddish or grey colour, but the bronchial are blackish, and those in the lesser or hepatic omentum are often yellowish; the colour, therefore, depends on that of the matter passing through them; their form is round or oval, but many are very irregular and lobulated; they are surrounded by loose and vascular cellular tissue; each has a smooth, fibrous capsule, which is partly prolonged into it; blood-vessels penetrate it irregularly; the vasa inferentia enter at one end, and the efferentia escape at the other; within it the lymphatics subdivide, and form an intricate plexus. A section of a gland presents a cellular appearance; and some describe distinct cells into which blood-vessels and lymphatics open: this, however, is by no means certain, for such an appearance may depend merely on the divided vessels. These glands are better developed in the child; they appear redder, rounder, and more numerous, than in the adult or aged; probably in course of time, in some situations, they have become atro-

phied, and have been absorbed, and in others two or three have become consolidated into one.

In the descriptive anatomy of this system we shall first notice the *glands*, briefly, as they have been already spoken of in each particular region, and next the absorbent vessels. The former may be arranged into the external, and the internal or those of the cavities; the latter into the superficial and deep. In the ordinary course of dissection, few parts of the absorbent system can be demonstrated, except the two great trunks, particularly the left thoracic duct, the glands, and the larger vessels leading to and from these; but the lymphatics and lacteals generally are so small and transparent, that it is difficult to distinguish them from the surrounding tissue, unless injected, and this is by no means easy to effect; indeed to inject the lymphatic system is one of the nicest operations in anatomy; the valves will not permit the fluid being urged from trunks into branches, and the latter are so minute as almost to elude observation, and even when exposed, it is often extremely difficult and tedious to introduce and secure a pipe in them; introducing a fine pointed glass tube containing mercury into the subcutaneous or subserous tissue may occasionally fill some of these vessels, but this coarse experiment often fails. The most certain mode is to dissect carefully beneath the skin upon the dorsum of the foot or over the inner ankle, and, having exposed one of these small vessels, to open it carefully, and introduce a fine tube; this may be repeated on several vessels; a thin and slightly anasarcous subject is the best for this purpose. Lymphatic or conglobate glands exist in the extremities, and in the trunk.

Lymphatic glands of the upper extremity.—There are none in the hand or forearm, one or two are sometimes to be found deep-seated in the hollow at the elbow joint, and the same number also, but more superficial, above the inner condyle, near the basilic vein; a chain of separate and distinct glands accompanies the brachial vessels; in the axilla they are very numerous; several are attached to the vessels, some are scattered through the region; a small chain extends behind the lower border of the great pectoral muscle, towards the mammary gland, and another along the posterior fold of the axilla; a small group beneath the clavicle connects the brachial glands with the cervical.

Cervical lymphatic glands are superficial and deep: the former are close to the external jugular vein, along the posterior border of the streno-mastoid muscle, and inferiorly in the space between this muscle and the trapezius, and above the clavicle; there is also in general one upon or near to the hyo-thyroid ligament. The deep cervical glands accompany the carotid arteries, are large and many, and form a chain from the angle of the jaw to the thorax; they partly surround the great vessels, and are connected to the larynx, pharynx, œsophagus, and thyroid body, and communicate with the facial glands above and thoracic below.

Lymphatic glands of the head and face.—On the scalp there are

but very few and very small; one or two behind the ear and along with the occipital artery behind the posterior border of the insertion of the sterno-mastoid muscles; there are none within the cranium; there is no reason for considering the pituitary body as of this class. On the face there are but few; one or two on the parotid gland or imbedded in it, in front of the auditory meatus; a small one in the zygomatic fossa, three or four on the buccinator muscle, a small chain along and beneath the side of the lower jaw, and a few larger attached to the lower part and deep surface of the parotid gland; often one or two lie along the facial artery on the side of the jaw.

Lymphatic glands of the lower extremity.—There are none in the foot, and but seldom any in the leg; a small one like a currant is sometimes to be found at the upper part of the interosseous ligament, and occasionally in the child a very small one exists on the tibia, a little above the inner ankle. In the popliteal space are three or four, small and round, near the vessels, enveloped in adeps, and thus obscured from view. The inguinal are numerous and clustered into three groups, two superficial and one deep; the superior superficial are small, parallel to Poupart's ligament, receive the absorbents from the external parts of generation and from the abdominal parietes; the inferior superficial are large, only two or three in number, close to the saphena vein, they receive the superficial absorbents of the extremity. The deep inguinal glands are beneath the fascia lata and close to the vessels; this chain extends upwards and inwards, beneath the crural arch, to join the external iliac glands, and one of them often occupies the femoral ring. The lymphatic glands of the trunk are those of the pelvis, abdomen, and thorax.

Lymphatic glands of the pelvis are the external and internal iliac; the external iliac form a chain along the iliac vessels, from the inguinal to the lumbar glands; the internal iliac are attached to the internal iliac vessels, extended in an imperfect chain backwards and downwards to some sacral glands, and upwards to the lumbar.

The *abdominal glands* are the most numerous: they are lumbar and visceral. The lumbar form a close chain, commencing at the common iliac vessels, and ascending around the aorta to the diaphragm; the visceral glands are those of the stomach, spleen, small and large intestine. The lymphatic glands of the stomach are small and round, situated along each curvature and around the cardia and pylorus; those of the spleen and pancreas are attached to the splenic vein, and extend from the hilus of the former along the upper border of the latter. The glands of the small intestine form the most numerous group in the body, and are enclosed in the mesentery in the meshes of the blood-vessels; a considerable cluster exists near the duodenum, where they are often so close as to appear like a distinct gland, or a prolongation from the pancreas; they are also again connected into a cluster near the end of the ileum; the glands of the large intestine are enclosed in the mesocolon, and are few and scattered.

The *lymphatic glands of the thorax* are parietal and visceral: the

parietal are, one in the posterior part of each intercostal space, near the head of each rib, and attached to the intercostal vessels; there is another set anteriorly behind the sternum, and attached to the internal mammary vessels, one for each intercostal space; there are also a few scattered through the anterior mediastinum, extending from the diaphragm, in front of the pericardium, to the root of the neck; a chain also extends through the posterior mediastinum along the œsophagus and aorta, communicating with the abdominal glands below, the cervical above, the intercostal on either side. The visceral lymphatic glands of the thorax, or the pulmonary or bronchial, are large and numerous, situated upon and below the division of the trachea, and extend along the bronchi into the pulmonary structure for some distance, and gradually diminish in size and number; those in the angle of the tracheal division are the largest, and are often blended together into one mass. In the adult and old they are almost always of a dark, or even a black colour; are soft, and easily broken down by slight pressure: the colouring matter is then seen to be diffused in numerous particles through their interior, and much of it, but not all, can be removed by maceration. In the fœtus and infant they are small, round, and separate, and of the same red colour as glands in other situations. They have been supposed by some to be secreting glands communicating with the trachea, and the source of the dark-coloured sputa so often expectorated; this opinion, however, is unfounded, as they no doubt belong to the absorbent system, and their peculiar colour depends on the accumulation of the dark, carbonaceous matter brought to them by the pulmonary lymphatics. It is uncertain whether this matter consists merely of impurities from the air collected in the pulmonary cells, or whether it is a part of the excretion of the mucous surface; in either case it is taken up by the absorbents, and carried to the glands. The bronchial glands are very liable to strumous enlargement and softening, also to chronic induration, and to a deposition of calcareous matter; they may enlarge to such a degree as to interfere with the passage of the air into the lungs, or with some of the large vessels, and compress the cardiac and pneumogastric nerves. The absorbent vessels may be divided into those of the extremities and trunk; the lymphatics and lacteals of the latter we shall consider together.

Lymphatic vessels of the lower extremity are superficial and deep: the superficial commence from the toes, rise along the dorsum of the foot, and pass up the leg into two divisions, which, however, frequently communicate: one, the internal group, passes in front of the inner ankle, and keeps parallel and close to the great saphena vein; these branches ascend to the groin, enter the inferior superficial glands, and then pass through the deeper set, and through the femoral ring, into the external iliac glands. The external set of superficial lymphatics ascend behind the inner ankle, accompany the external saphena vein to the ham, pass through the glands there, and join the deep lymphatics of the limb. The deep lymphatic

vessels accompany each of the deep vessels of the leg, and continue along the femoral vein to the deep inguinal glands; the inguinal lymphatics, both superficial and deep, are joined by several others, from the perinæum, from the abdominal parietes, and from the gluteal and iliac regions; all these converge to the external iliac glands. The lymphatic vessels of the testis and ovary follow the spermatic vessels, and enter the lumbar glands, but those of the scrotum and labia pass into the inguinal glands. The lymphatics of the pelvis accompany each of the branches of the internal iliac vessels from their respective viscera, and from the sacral and internal iliac glands, converge towards the last lumbar vertebra, are joined by the femoral and external iliac lymphatics, then ascend through the lumbar glands, receiving the parietal, renal, and spermatic branches, and finally end by several large vessels in the receptaculum chyli, the beginning of the thoracic duct. The lymphatics of the abdominal viscera are very numerous, and some are very obvious. Those of the LIVER are superficial and deep. The superficial are seen all over the convex surface, through the peritonæum, and pass off in different directions; some on the upper surface of the right lobe, enter the folds of the suspensory ligament, and, conducted to the diaphragm, pass through it into the anterior mediastinum, and enter the glands there; others turn round the thin edge, enter the horizontal fissure, pass backwards to the transverse, and into the lesser omentum, and the glands situated there around the pylorus; others from the convex surface extend along the vena cava into the chest, and reach the thoracic duct; on the inferior surface of the liver also, they are very numerous, and form around the gall bladder an obvious plexus; from this surface some vessels pass to the lesser omentum, others pass round more deeply, and join some of the lower intercostal or superior lumbar glands. The deep hepatic lymphatics accompany the divisions of the porta and biliary ducts, reach the lesser omentum, pass through glands there in their course towards the spine to join the thoracic duct. The lymphatics of the stomach are in the subserous and submucous tissue; the former or superficial present a plexiform appearance beneath the peritonæum; they pass from the organ in different directions, accompanying the coronary and epiploic vessels; some pass through the glands in the lesser omentum and around the pylorus to the spine, others extend from the great curvature and extremity towards the splenic glands, and to the thoracic duct. The splenic and pancreatic vessels accompany their respective veins, and pass through the lymphatic glands before they reach the spine. The absorbent vessels of the small intestines are lymphatics and lacteals: the lymphatics arise in the subserous tissue, and the lacteals in the submucous and in the villi; the former proceed at first for some way along the tube and parallel to it, and then backwards into the mesentery and enter the glands; the lacteals at once proceed from the intestine into the mesentery and its glands; there is no reason, however, to suppose that these two orders of vessels continue distinct any longer, they enter the same glands together; neither is it certain that

they are perfectly distinct even in the walls of the intestine. No doubt when the lacteals are distended with chyle, as they are occasionally found like white-beaded or knotted lines, a distinction appears, as the lymphatics are then empty, or only contain a transparent fluid, hence the latter are supposed by some to be merely connected with structural absorption or nutrition, and the former with chylous absorption alone, while the radicles of the vena porta effect the miscellaneous absorption of fluids by the simple process of endosmose; it is right, however, to add, and which I have verified by my own experience, that a successful mercurial injection of any of the intestinal absorbents equally fills the the lymphatics and the lacteals. From the mesenteric glands, a fasciculus of absorbents pass in the root of the mesentery to the spine, and joins the thoracic duct. The lymphatics of the large intestine are conducted by the mesocolon through glands towards the spine; those of the cæcum and right colon join the mesenteric absorbents; those of the rectum and left colon enter the lumbar glands before they reach the thoracic duct.

Thoracic duct, great or left, is the common recipient of the absorbents, not only of all the infra-diaphragmatic portion of the body, but also of those of the left side of the chest, head, and neck, and left arm; it commences by the confluence of a variable number of branches in a common reservoir or dilatation, called *receptaculum chyli*, which is placed to the right side and somewhat behind the aorta, between it and the right crus of the diaphragm, on the body of the second lumbar vertebra; from this the duct passes into the thorax, between the aorta and the vena azygos, and ascends the posterior mediastinum in these relations, resting on the spine and imbedded in adeps as far as the fourth dorsal vertebra; it then ascends obliquely to the left, behind the aorta and to the left of the œsophagus, behind and to the inner side of the left subclavian artery; thus inferiorly it lies to the right of the aorta, but superiorly to the left; it then rises into the neck, behind the left internal jugular, and, opposite the seventh cervical vertebra, arches forwards, downwards, and a little outwards, and opens into the angle between the left subclavian and jugular veins; or a little external to this point; a pair of perfect valves protect its orifice against regurgitation from these vessels; it sometimes opens by two distinct branches, and sometimes a branch passes from it across the neck to the right subclavian vein, or to the right lymphatic duct. It is very variable as to many of these characters; sometimes there is no receptaculum, or perceptible dilatation at its origin; in its mediastinal course it is often alternately dilated and contracted, and it frequently divides into two branches, which soon reunite, or into several, which are tortuous and plexiform: in its ascending course it receives some hepatic, also the phrenic, intercostal, and pulmonic, or the thoracic lymphatics; and in the convex portion of its cervical arch it is joined by the cervical and left brachial lymphatics.

The lymphatics of the thorax are parietal and visceral: the parietal are superficial and intercostal; the former pass to the axillary and in-

ferior cervical glands; those from the mammary glands chiefly follow the lower border of the great pectoral muscle. The intercostal lymphatics follow the intercostal veins to the posterior mediastinum, and the internal mammary veins and arteries are accompanied by the superior phrenic and anterior mediastinal lymphatics.

The pulmonary lymphatics are superficial and deep; the former appear as a net-work beneath the pleuræ, spread all over the surface; the vessels converge to the roots of the lungs, and enter the bronchial glands; the deep lymphatics accompany the bronchial tubes, also reach the same glands, join the posterior mediastinal absorbents, and enter the thoracic duct; some from the right lung occasionally join the right lymphatic duct at the root of the neck. The lymphatics of the heart accompany the coronary vessels to the arch of the aorta, and thence proceed to the bronchial glands and to the root of the neck.

Lymphatics of the head and face are superficial and deep; those of the scalp are occipital, auricular, temporal, and frontal, and accompany the corresponding blood-vessels; the two first set traverse the occipital lymphatic glands in their descent to the neck, the latter the parotidean, and the other the facial glands. The lymphatics, from the interior of the cranium, are but very few, at least but few have been discovered as yet; these vessels have been detected on the membranes of the brain, but have not been traced into the organ itself; it is, therefore, conjectured by some that the veins are the absorbing agents in the nervous centre. The cranial lymphatics that have been observed, pass out through the spinous, carotid, and posterior lacerated holes, and join the cervical system. The lymphatics of the face, both deep and superficial, accompany the several blood-vessels of this region.

The *lymphatics of the neck.*—The superficial and deep are continuous with those of the head and face, accompany the superficial and deep blood-vessels, pass through the chains of glands, at the lower part of the neck, join the absorbents from each upper extremity, and, on the left side, end in the great, and on the right side in the lesser, lymphatic trunk.

Lymphatics of the upper extremity.—The superficial commence from the fingers and back of the hand, accompany the subcutaneous veins, are easily exposed by dissection, and, when inflamed during life, are rendered obvious by the red lines which appear through the skin; they accompany the subcutaneous veins; some follow the cephalic on the outer side of the arm, as high as the clavicle, and then sink between the pectoral and deltoid muscles to join the deep fasciculus; the others follow the basilic vein through the different glands to the axilla. The deep lymphatics of the arm follow the individual blood-vessels, reach the axillary glands, receive branches from the back part of the trunk and neck, from the mammary gland, and from the parietes of the chest. These vessels, on the left side, accompany the subclavian vein, and join the descending portion of the thoracic duct. On the right side, the axillary or subclavian lymphatics, joined by the right

cervical, form a short trunk, named the *right lymphatic duct* (right thoracic duct is an incorrect term); this is scarcely an inch long; it opens into the angle between the right jugular and subclavian veins; it is the termination of the lymphatics of the right arm, right side of the thorax, and of the head and neck. This vessel is often absent, three or four branches supplying its place, and opening into the right jugular and subclavian and innominata veins.

PART III.

ANATOMY OF THE NERVOUS SYSTEM.

THIS SYSTEM MAY BE DIVIDED INTO FOUR PRINCIPAL PARTS, THE BRAIN, THE SPINAL CORD, THE NERVES, AND THE GANGLIONS.

CHAPTER I.

DISSECTION OF THE BRAIN.

SECTION I.

MEMBRANES OF THE BRAIN.

THE *nervous system* forms a very important and interesting constituent of the animal body. Upon it depend sensation, perception, and volition, as well as the effects of the latter upon the muscular system, and probably, in a great degree, muscular action generally. It is the medium through which the organs of sense make us acquainted with the external world, so as to enable us to appreciate the physical characters and properties of the various bodies that surround us. Upon it, or upon some special portion of it, depend the operations of the mind, and all those instincts, feelings, passions, and propensities, which characterize the animal creation; moreover, the organic or vital functions, digestion, absorption, respiration, circulation, secretion, nutrition, and growth, are all influenced by its agency, which regulates each, ordains their due succession, and combines these various processes into that state of harmonious action which is necessary to the manifestation and to the continuance of life. The study of these topics is the principal object of *neurology*, which implies that division of anatomical science that treats of the apparatus of *innervation* and *sensation:* this apparatus includes the organs of the senses, touch, taste, smell, sight,

and hearing; the nerves, with their ganglions, and the spinal cord and brain. We shall not, however, study these individually in this order, but shall defer the consideration of the organs of sense until we shall have examined the nervous system, properly so called.

The *nervous system* may be divided into two sections: one is the external or peripheral portion, and includes the numerous nerves, with their ganglions; the other is the central portion, or the cerebro-spinal axis, and consists of the spinal cord and the encephalon or brain, which is partially divided into four ganglionic masses, viz., medulla oblongata, cerebral protuberance, or mesocephale, cerebellum, and cerebrum. We shall commence with the great nervous centre, or cerebro-spinal axis, which is enclosed in the cranium and spinal canal, and wonderfully protected from direct injury, or general concussion, by the mechanical arrangements of the osseous and ligamentous framework with which it is surrounded, and within which it is more closely invested by three membranous tunics.

The *membranes*, or *meninges of the brain and spinal cord*, are three, the dura mater, the arachnoid, and the pia mater; the first is fibrous, the second serous, and the third vascular. Although the cranial and spinal portions of these are continuous, yet, as they present peculiarities in each region, they should be examined in each distinctly.

Divide the scalp from one ear across the vertex to the other; reflect one flap over the face, the other over the back of the neck; make a circular cut with the saw through the cranium, on a level with the cartilage of the ear on each side, anteriorly about an inch above the superciliary arches, and posteriorly a little below the tubercle of the os occipitis. It is only necessary to saw through the outer table of the bones; the elevator, or a few smart strokes with the claw of the hammer, will then suffice to crack the internal table (indeed the cranium may be opened by the hammer alone; this plan, however, injures the bones so much as to leave them of little use to the student). The calvarium being now forcibly torn away, the dura mater is exposed; the latter, in some subjects, adheres so closely to the bone as to be torn along with it. This accident will injure the brain, and may be avoided by introducing the handle of the knife, or any blunt instrument, between the membrane and the bone as you gradually raise off the latter. If the student can procure two subjects, it will facilitate his study to examine the brain of both at the same time; in one dissect the parts *in situ*, and from the other remove the brain in the following manner: commencing anteriorly, gently raise it from the base of the skull, divide each nerve and vessel in succession from before backwards close to the bone, dislocate the pituitary gland from the sella Turcica, and cut through the tentorium; next divide the spinal cord as low down in the neck as you can pass the knife through the foramen magnum; then place the brain, its base upwards, in a shallow basin. Thus the different surfaces and structures of the brain, as also the several processes and sinuses of the dura mater, can be examined in continuation with each other.

The *cranial portion of the dura mater* is a fibro-serous membrane, of great strength, white, and sometimes of a bluish tint; adheres accurately to the inner surface of the skull, and effects five important purposes: first, it serves as the internal periosteum; second, as a strong covering to the brain, one very essential in early life, when the bones are separate and imperfect; third, it sends inwards folds or processes, which separate and support the principal divisions of the encephalic mass, lessen the force, and prevent the free transmission of concussions; fourth, it forms, by the separation and reunion of its laminæ, channels or sinuses with unyielding walls, lined by the venous membrane to receive the blood from the brain, and conduct it to the two internal jugular veins in the neck; and fifth, it furnishes fibrous sheaths for the several nerves as they leave the base of the cranium. Its external surface adheres so intimately to the bones, that when the latter are detached, it appears rough from the rupture of the connecting vessels and fibres; the adhesion is very close in the course of the principal sutures, and particularly in the base, where it is impossible to separate it without maceration or boiling; it also adheres to the posterior margins of the orbits, or the lesser sphenoidal wings; sends a sheath round the optic nerve to join the sclerotic coat of the eye, and is continuous with the orbital periosteum through the lacerated holes: it is firmly connected to the edge of each petrous bone, and of the foramen magnum; through the latter it is prolonged down the entire spinal canal, and it also sends processes through the several openings in the base of the skull, which become continuous with the external periosteum. In some situations the connexion is feeble, as in the four occipital fossæ, and to the squamous and parietal bones; a blow during life occasionally detaches it from the latter, and blood may be extensively diffused upon its external surface. The degree and the mode of connexion differ at different periods of life: in the aged it is so intimate that it often tears into shreds, or the bones split into laminæ, in the attempt at separation; the membrane itself becomes very thin, particularly in the base of the skull, and the attachment chiefly depends on fibres passing from the dura mater into the osseous structure, and but few vessels or red dots are seen upon its surface: in middle age the connexion is partly vascular, partly fibrous, and is more easily broken; but in the very young they adhere so intimately in the lines of the sutures, that separation cannot be effected by concussion with the hammer, strong scissors or cutting forceps are required; the membrane adheres to the cartilaginous edges of the bones, and is continuous through these with the pericranium; in the base it adheres to all the temporary cartilages and sinks into all the depressions, particularly those in the petrous bones, and can only be detached by maceration. When the bones have been raised, the surface of the dura mater is found studded with numerous bloody points, the ends of the vessels that have been ruptured, and which at this age form the chief bond of union. As the cranial dura mater serves as a periosteum, it receives a more full supply of arterial blood than the spinal; its arteries

ramify between it and the bone, nourish the latter, and send fine colourless capillaries to the serous lamina of the former. The anterior arteries are derived from the ophthalmic and internal carotid; the middle or spinal artery is a branch of the internal maxillary, which, passing through the spinous hole of the sphenoid, first runs upwards and outwards, indenting the temporal and sphenoid bones, then entering a groove on the inferior angle of the parietal, which is sometimes a complete bony tube, it branches upwards and backwards on the side of the membrane between it and the bone; its posterior vessels are derived from the occipital and vertebral, and its basilar portion from the pharyngeal, vertebral, internal carotid, and from the vessels of the bones to which it adheres. The superior veins of the dura mater enter the longitudinal and lateral sinuses, the inferior into those at the base of the skull; some communicate with the diploic veins, and those of the scalp and the middle artery have their venæ comites. This membrane in its normal state possesses but little sensibility; its nerves are small, few, and indistinct; the ganglion of the fifth pair at the base decidedly sends some filaments to it; the meningeal artery is also accompanied by fine branches from the sympathetic; the fourth and vidian, also, are thought by some to assist in its supply. The dura mater, near the vertex, and in elderly subjects, often presents a cribriform appearance, with small, pale, granular bodies projecting from it, or rather through it, and often indenting the bone; these are named glandulæ, or, more properly, corpora Pacchioni; they shall be alluded to more particularly hereafter. Cut through the dura mater on each side, raise it towards the vertex, leaving the narrow medial portion undivided; its inner surface, smooth, polished, and lubricated with serous exhalation, will now be seen; it is composed of the reflected or parietal layer of the arachnoid, adhering most closely to the fibrous membrane; this surface is always opposed to the serous surface of the brain. A portion of the dura mater may be next removed to examine its structure; this will be found to be very strong, resisting, and inelastic, not unlike the sclerotic of the eye; it is fibro-serous, as the pericardium and albuginea testis; in the latter, however, the serous tissue is external; the fibrous layer consists of white fibres variously and intricately interwoven, in some situations arranged into two laminæ, as at the superior longitudinal and two lateral sinuses, the external or periosteal adhering to the bone, while the internal separates at each side, and then reuniting encloses a triangular canal which is lined and rounded off by the venous membrane; in various other places, also, dissection may partially separate it into two laminæ, particularly in the young subject, where the external layer is more decidedly periosteal in function.

The internal folds or processes of the dura mater are the falx cerebri, falx cerebelli, tentorium cerebelli, and sphenoidal folds.

The *falx cerebri* occupies the median line, is exposed by gently separating the hemispheres of the cerebrum, or by removing one on a level with the corpus callosum; its apex commences narrow from the foramen cœcum from around the crista galli which it encloses, and

*Fig. 68.**

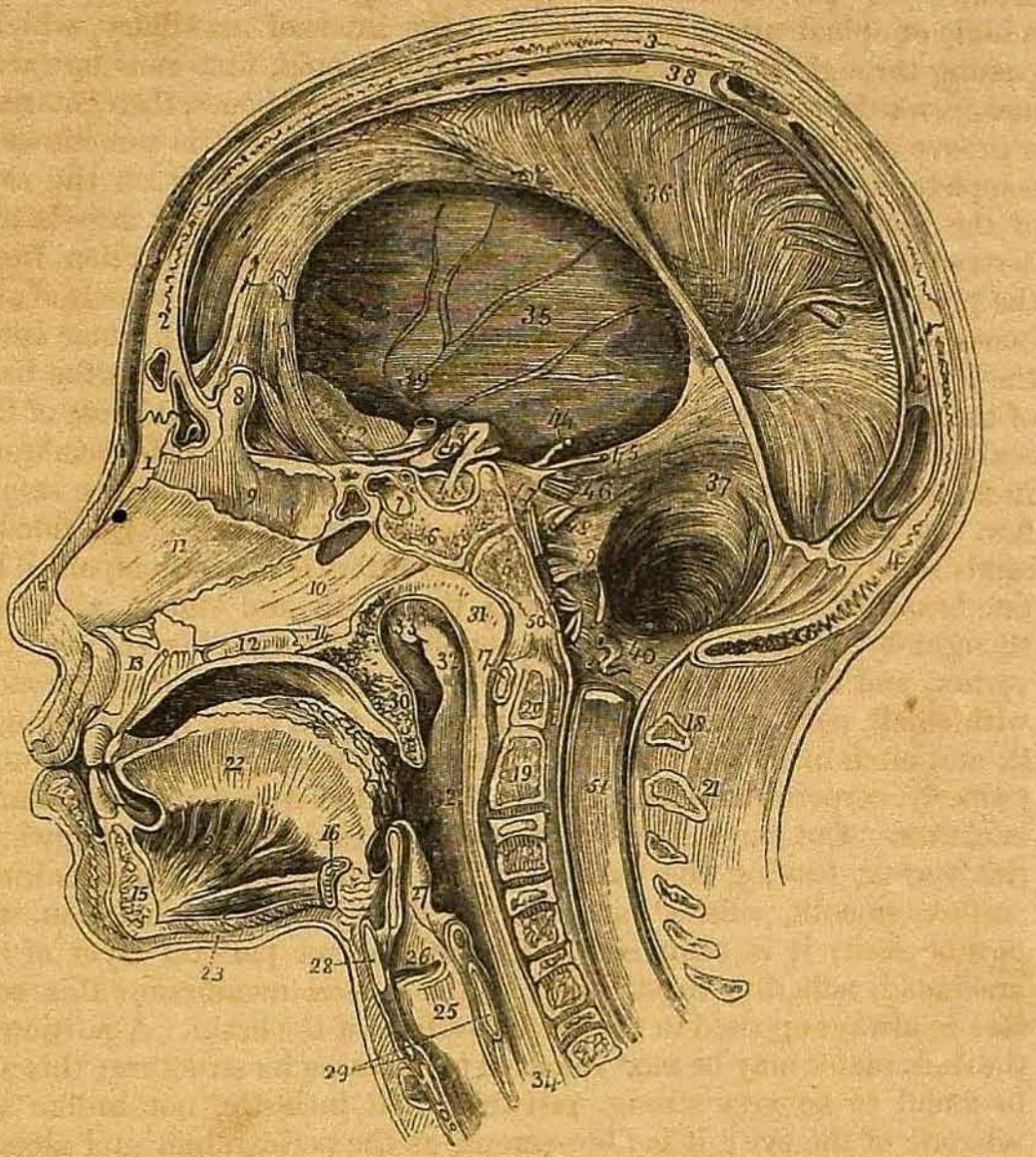

* A vertical section of the head through the median line. 1. The os nasi. 2. The frontal bone. 3. The parietal. 4. The occipital. 5. Basilar process of the occipital. 6. Body of the sphenoid. 7. Sphenoidal sinus. 8. Crista galli of the ethmoid bone. 9. Nasal lamella of the ethmoid. 10. The vomer. 11. The median cartilage of the nose. 12. The palate plate of the superior maxillary bone. 13. The anterior palatine canal. 14. The palate bone. 15. The inferior maxillary bone. 16. Section of the body of the os hyoides. 17. Section of the anterior ring of the atlas. 18. Posterior part of same bone. 19. Body of the axis. 20. Its odontoid process. 21. Its spinous process. 22. Section of the tongue. 23. Genio-hyoid muscle. 24. Genio-hyo-glossus muscle. 25. Section of the larynx. 26. Ventricle of the larynx and vocal cords. 27. Section of the epiglottis. 28. Thyroid cartilage. 29. Cricoid cartilage. 30. The velum pendulum palati. 31. Cellular tissue behind the pharynx. 32. 32. The pharynx. 33. Orifice of the Eustachian tube. 34. The œsophagus. 35. The cavity of the cranium. 36. The falx cerebri. 37. The tentorium cerebelli. 38. The superior longitudinal sinus. 39. The internal carotid artery. 40. The vertebral artery. 41. The pituitary body. 42. The olfactory nerve. 43. The optic nerve. 44. The third or motor oculi. 45. The fourth nerve. 46. The fifth or trifacial nerve. 47. The sixth nerve. 48. The two portions of the seventh nerve. 49. The three portions of the eighth nerve. 50. The ninth or lingual nerve. 51. The medulla spinalis.

from the middle ridge of the ethmoid bone, as it curves backwards, it gradually increases in depth, and its base ends in the median line of the tentorium cerebelli with which it is continuous, and which it suspends in a state of tension; its convex border corresponds to the middle ridge or groove of the frontal bone, to the sagittal margin of the two parietals, and to the upper half of the perpendicular ridge of the occipital, and encloses the superior longitudinal sinus: the inferior or concave border corresponds to the raphe of the corpus callosum, is thicker behind, and nearly in contact with it; it encloses the inferior or lesser longitudinal sinus, which resembles an ordinary vein more than the true cranial sinuses; the base is thick and strong, and encloses the straight sinus between its laminæ and the tentorium; the course of the sinus, however, is not straight, but obliquely downwards and backwards; unlike the other sinuses it is bounded on all sides by the fibrous tissue. The falx cerebri bisects the upper part of the cranium, separates the cerebral hemispheres, supports each in the lateral recumbent position of the body, lessens the force, and checks the transmission of lateral concussion, assists in the formation of three venous sinuses, and suspends the tentorium in the centre: it is most perfect in the young, it often becomes cribriform with age, and occasionally in the very old is partially ossified.

The *tentorium cerebelli* extends somewhat horizontally, but is higher in the centre, across the inferior part of the cranium; is exposed by raising the posterior lobes of the cerebral hemispheres; attached by its convex edge to the central tubercle of the occipital bone, and on either side to the margins of the groove on its transverse ridge, and on the inferior angle of the parietal, also to the superior internal angular ridge of the petrous bone, which is slightly grooved, and to the clinoid processes of the sphenoid: this last attachment is peculiar; the external or convex border passes like an arch over the point of the petrous bone, bounding a smooth, oval passage for the fifth pair of nerves into the middle cranial fossæ, to expand into its ganglion; the internal or concave edge, or cornu, crosses over the external like the letter X, passes forwards, is inserted into the anterior clinoid process, covers the cavernous sinus, and bounds the pituitary fossa laterally; the tentorium is raised in the centre like an arch or tent, is slightly convex above at either side, and concave below, adapted to the corresponding surfaces of the cerebrum and cerebellum; it is firmly maintained in this form by the attachment of the falx cerebri to its middle line. That these processes sustain their mutual tension may be proved by the fact that the division of either immediately causes the relaxation of both. Enclosed in its convex border are two sinuses on each side, namely, posteriorly, the superior or horizontal portion of the lateral, which leaves it at the angle of the parietal bone, and anteriorly the superior petrosal, which extends along it in the groove on the angle of each petrous bone; in the median line it also forms the base of the straight sinus, the sides of which are completed by the laminæ of the falx. Anteriorly it presents a large oval opening, bounded in

front by the sphenoid bone; the superior vermiform process of the cerebellum, the upper end of the pons Varolii, the crura cerebri, and the quadrigeminal bodies, occupy this foramen, which lies on a plane anterior to that of the foramen magnum, and is the only communication between the upper region of the cranium and the small compartment behind and below, which is bounded by the inferior occipital fossæ, the petrous bones, the cuneiform process, and the body of the sphenoid. This compartment leads to the spinal canal through the foramen magnum. The tentorium covers the cerebellum, supports the superincumbent cerebrum, and assists in forming five sinuses, viz., two lateral, two superior petrous, and the straight: it is found perfect at all ages, never cribriform, or ossified, although in some animals it is normally a plate of bone.

The *falx cerebelli* is seen when the cerebrum is removed and the tentorium divided; a small but thick vertical process, the base above attached to the tentorium, the apex bifid to each side of the foramen magnum; its convex edge adheres to the inferior occipital spine, and encloses the two occipital sinuses; its concave edge, thick, and sometimes double, is received into the groove between the hemispheres of the cerebellum.

The *sphenoidal folds* are attached to the lesser wings of the sphenoid bone; they serve to extend the surface of the anterior fossæ in the base of the cranium, and correspond to the fissure of Sylvius. Although the cranial sinuses are a portion of the venous system, yet it is better to examine them in connexion with the dura mater, which is so instrumental in their formation; they return the blood from all parts of the brain and its membranes, also from the eye, and from the bones of the cranium; they are all fibrous canals, formed externally by the dura mater, and internally by the same membrane as lines the veins generally; they communicate freely with each other, and they all terminate in the lateral sinuses, which lead into the internal jugular veins, the great channels whereby all the blood from the head is returned to the heart. There are fifteen sinuses, five of which are in pairs, and five are single or mesial; the symmetrical are, two lateral, two superior petrosal, two inferior petrosal, two occipital, and two cavernous; the azygos are, the superior longitudinal, inferior longitudinal, straight, circular, and transverse.

The *superior longitudinal sinus* commences at the crista galli, either in a *cul de sac*, or by a small vein from the nose; it extends upwards and backwards in the median line, increasing in size, and divides opposite the occipital tubercle into the right and left lateral sinuses, the right being in general the larger. With the scissors open the sinus through its whole length; its triangular form is then seen, the base towards the bone, the apex in the falx, but the angles are rounded off by the fine membrane continued from the numerous veins that open into it; it is usually dilated near the vertex; small, white, fibrous bands cross it in many places, variable in size and direction; they bear an imperfect resemblance to the valves in the veins, but

cannot act as such; they may serve to resist dilatation; they have been named *cordæ Willisii*. About the middle of the sinus some of the corpora or glandulæ Pacchioni, or cerebral granulations, are generally to be observed in the adult or aged; sometimes scattered singly, often in clusters, and near the openings of the veins; in size, number, and appearance, they vary considerably; in the very young there are few, if any; in the old they are often numerous, and so large as to cause depressions in the parietal bones; they are found in three situations in the immediate vicinity of the sinus, external to the dura mater (glandulæ externæ), in the sinus (glandulæ mediæ), and internal to it about the terminations of the veins (glandulæ internæ). There is no reason for considering them as glands of any sort, neither can they act as ball-valves; we have always regarded them as abnormal, most probably the result of chronic subacute inflammation in the fine subserous tissue beneath the dura mater. As they increase, they project in different directions, some into the sinus, others separate the fibres of the dura mater, and then protrude externally; when much developed, the arachnoid around is usually thick and opaque, with cream-coloured deposit; they are also sometimes found around the venæ Galeni, entering the straight sinus, also around the pineal body; and I have frequently noticed them, though of a different form, on the base of the brain, near the infundibulum and the inner extremities of the Sylvian fissures: I have not found them in the lower animals. The longitudinal sinus receives many small veins from the diploe, dura mater, and pericranium; the latter pass through the suture, or join the diploic veins, but its principal branches are the internal and superior, or external cerebral veins. The *internal*, four or five on each side, return the blood from the convolutions of the opposed surfaces of the hemispheres, and join the superior veins before they enter the sinus; some open into it distinctly. The *superior* or *external* are larger, and six or seven in number: the anterior are smaller than the posterior; one or two occasionally present a considerable size; one in particular, which commences on the outer side of the brain, above the fissure of Sylvius: they all ascend at first obliquely backwards, then curve in an arch concave forwards; others also run in this curved manner, first backwards, then forwards, and towards the median line; the largest attach themselves to the sides of the falx, beneath the reflected arachnoid, and run in the fibrous tissue for near an inch before they open into the sinus; some open free upon the sides, the orifices looking inwards; others are partially concealed by the cordæ Willisii, the greater number in a direction from before backwards, but some in the very opposite; neither the cords of Willis, nor the corpora Pacchioni, can answer as valves; neither have the veins themselves any valves. Whether the curves on the principal vessels, and their long, oblique course in the walls of the sinus before they open, together with the internal cords, may serve as some check to the reflux of the blood, are questions that have not been determined.

The *inferior longitudinal sinus* is not always present; it resembles

a small vein enclosed in the lower edge of the falx near its base, receives small veins from it, and sometimes from the corpus callosum; it opens into the following:

The *straight sinus*, enclosed between the laminæ of the base of the falx and the tentorium, proceeds backwards and downwards, slightly arched, convex above, triangular, the base below; it receives the veins from the ventricles, or the venæ Galeni, which pass between the corpus callosum and tubercula quadrigemina; also inferior cerebral and superior cerebellar branches; and it ends in the confluence of the lateral and longitudinal sinuses by one, and sometimes by two openings, separated by a fibrous band; internally it presents the same fibrous or areolar appearance as the great longitudinal.

The two *lateral sinuses* are the largest of the system, and the right is usually the larger of the two; they commence opposite the occipital tubercle, from the confluence of the longitudinal and straight; each passes outwards and forwards, at first horizontally in the convexity of the tentorium, and in the horizontal groove in the occipital bone; it next indents the inferior angle of the parietal, and then bends downwards and inwards, deeply indenting the mastoid portion of the temporal bone; it then again grooves the inferior part of the occipital, and, turning forwards and rising a little, passes through the foramen lacerum posterius, and ends in the internal jugular vein: its horizontal portion is triangular, and projects beyond the bone into the tentorium; its oblique or descending portion is larger and more elliptical, but more sunk in the osseous groove; it is generally dilated at its termination; it receives inferior cerebral and cerebellar veins; many of these enter the sinus from without inwards, or contrary to the current; on the parietal angle it receives the superior petrosal sinus, also a considerable branch (mastoid vein) which passes from the scalp through a foramen near the mastoid process, or in the adjacent suture; near its termination it is joined by the inferior petrous sinus; internally these canals are smooth, and free from fibrous bands and corpora Pacchioni; they are the channels through which all the blood is returned from the brain into the general system. The following sinuses are situated at the base of the cranium:

The *cavernous sinus* on each side extends from the anterior clinoid process to the point of the petrous bone, along the side of the body of the sphenoid. The dura mater in this region divides into two layers; one is very thin, and adheres to the irregular, bony surface which bounds this space; the other is more dense, is continued across it, and contains between its fibres the third and fourth nerves, and first part of the fifth. The ophthalmic vein, having passed through the foramen lacerum orbitale superius, opens into the forepart of this sinus, and the two petrosal sinuses lead from it posteriorly to the lateral sinus; it is intersected by tendinous and membraneous bands, and presents a spongy or cellular appearance like the corpus cavernosum penis; the internal carotid artery, and the sixth or abducens nerve, pass through it, and the lining venous membrane is reflected around these, and se-

parates them from the blood. These sinuses inosculate through the following:

The *circular sinus*, or *sinuses*, are two small channels leading from the right to the left cavernous; one is beneath the optic commissure and before the pituitary body, the other is posterior to it, and larger; both these and the cavernous sinuses receive veins from the bones and membranes, from the pituitary body, and adjacent parts of the brain.

The *petrosal sinuses* are four in number, two on each side, a superior and inferior; they lead from the cavernous sinus backwards; the superior between the tentorium and the grooved ridge of the petrous bone, and opens into the lateral opposite the inferior angle of the parietal bone; the inferior leads backwards and downwards over the suture, between the petrous and occipital bones, and ends in the lateral sinus near its termination.

The *transverse* or *basilar sinus* leads from one inferior petrosal sinus to the other, across the cuneiform process, and maintains a communication between the cavernous, petrous, and lateral sinuses of opposite sides.

The *occipital sinuses* are two small canals contained in the falx cerebelli, receive veins from the cerebellum and adjacent bone and membrane, also from the vertebral canal; they sometimes extend along the sides of the foramen magnum; the blood ascends in these, as they open above into the general confluence; they are often wanting.

The *torcular Herophili* is a sort of reservoir or confluence of several sinuses, opposite the occipital tubercle, and enclosed between the laminæ of the falx and tentorium; it is somewhat oval, and presents six openings internally, viz., the lateral sinus on each side, the longitudinal above, the straight before, and the two occipital below.

The *cranial sinuses* may be regarded as veins enclosed between the laminæ of the dura mater, whereby they are not only fixed in their situation, but are also enabled to resist distention, and thus the brain is protected from any sudden or undue compression that may arise from such a cause. The free and numerous inosculations between them are also well adapted to obviate congestion of blood from any local interruption in any particular sinus, or in the veins at either side of the neck.

The second covering of the nervous centre is the arachnoid or serous membrane, which, like all membranes of this class, is a shut sac, covering the organ by one surface or lamina (the visceral), and lining the cavity or the dura mater by the other (the parietal); it is continued from the cranium through the spinal canal, and is closed inferiorly by a *cul de sac* analogous to that of the peritonæum in the pelvis; like the dura mater, it presents peculiarities in its cranial and spinal portions, which must, therefore, be examined distinctly.

Cranial arachnoid membrane presents the ordinary smooth and glistening appearance, and is of extreme delicacy; the parietal layer adheres too closely to the dura mater to admit of extensive separation by dissection; it is so transparent that the fibres of the latter shine

through it; chronic inflammation thickens, and causes a deposit beneath it which renders it more evident and easy of separation; bony growths in like manner, and sometimes external injury cause ecchymosis between them; it adheres to all parts of the dura mater, except through a small space opposite the sella Turcica, where the pituitary body intervenes; the parietal layer is reflected into, or becomes continuous with the visceral at many points; thus on each side of the longitudinal sinus every vein is accompanied by a tubular prolongation of the arachnoid, which is continuous on one side with the parietal, and on the other with the cerebral lamina; in like manner each nerve is accompanied from the brain to the point of exit by a tubular process, which forms a *cul de sac* at the foramen, and is then reflected from the nerve to the dura mater. The visceral or cerebral layer adheres very intimately in some parts, and loosely in others to the surface of the encephalic mass, or rather to the vascular membrane which covers it. On the surface of the cerebrum and cerebellum it covers all the eminences, and passes like a tense flat bridge from one to another, but does not penetrate into any of the intervening depressions or sulci; in each of these and beneath the membrane is a loose tissue, which never contains any adeps, but is often filled with serous effusion, and is easily rendered emphysematous, whereby the arachnoid can be raised distinctly, but from the surface of the eminences, it cannot be separated from the pia mater; having covered the upper part of the cerebrum, it sinks into the median fissure, and is continued from one hemisphere to the other beneath the falx; below this reflection, the opposite vascular surfaces of the hemispheres are in contact; anterior to the corpus callosum, it sinks to the under surface of the anterior lobes, beneath the olfactory lobules, which are thus confined in their sulci, covers the lower surface of the optic nerves and their commissure, passes over the pituitary body, and around the infundibulum, then over the tuber cinereum, corpora albicantia, to the pons Varolii, thus covering the depression, beneath the middle ventricle, which contains some loose and watery reddish cellular tissue traversed by fibrous bands, this is named the *anterior sub-arachnoid space;* on either side, it passes from the anterior to the middle lobes, across the Sylvian fissures, where again a space occurs beneath it at each side, *lateral sub-arachnoid space;* if we next trace it from the upper and back part of the corpus callosum, we see it passing from this to the superior vermiform process of the cerebellum, and thence over the upper surface of this organ; another loose, cellular, fibrous space exists beneath it, between the corpus callosum and the cerebellum, *superior sub-arachnoid space;* in this situation it meets the venæ Galeni, or ventricular veins, is folded around them, and becomes continuous with the serous lining of the ventricles, as will be more fully explained hereafter; having extended over the upper surface of the cerebellum, binding its sulci close together, it passes round its circumference to its inferior aspect, and extends like a flat, tense, and strong bridge across the posterior and inferior notch between its hemispheres, and thence to the back part

of the medulla oblongata, around which it is constricted; it leaves beneath it in this situation a considerable interstice (*posterior sub-arachnoid space*); from the medulla oblongata it is continued down the spinal canal, where we shall examine it hereafter; as this membrane thus covers the general outline of the encephalic mass, it leaves numerous interstices beneath it, filled by a loose, fine, areolar tissue; not merely those which are so well marked as to have received distinct names, viz., the anterior, the two lateral, the superior and posterior sub-arachnoid spaces, but also similar, only smaller ones in each of the sulci between the convolutions; the cerebral sub-arachnoid spaces communicate with each other, but not very freely, as they are filled with areolar tissue, and traversed by fibrous bands, which interrupt the transmission of the fluid; they also communicate with the spinal sub-arachnoid space, but a certain constriction in the arachnoid around the medulla oblongata restricts this also; hence, although the fluid may pass from one region to another, it does so, slowly, and a certain quantity is normally confined to each. We have already stated that the serous membrane not only covers the surface of the brain, but that it also lines the ventricles, being continued into them from the general surface. To see this process of the arachnoid membrane, separate gently the posterior lobes of the cerebrum, divide the falx, and at the anterior edge of the tentorium the two venæ Galeni will be seen entering the straight sinus; these veins are surrounded by the serous membrane; press these gently to one side, and underneath them a small round hole or canal may be observed, leading forwards below these veins, and above the pineal body, and opening into the back part of the third ventricle; this canal is lined by the arachnoid membrane, which is continued from that on the surface of the brain, and expands within the ventricles, so as to cover all the inequalities observed within them; this arrangement bears some analogy to the omental *cul de sac*, which leads into the peritonæal cavity by the foramen of Winslow; this canal is best seen in the fœtus, it is very generally partially or wholly obliterated by adhesion in the adult. That these cavities are really lined by a serous membrane is undoubted; by carefully removing the white, fibrous neurine from the roof of either lateral ventricle we may see this fine, delicate, transparent pellicle, but sufficiently strong to retain the fluid or air, when agitated against it; so exquisitely delicate, however, is this texture, that we cannot, when these cavities are opened, raise it from their parietes to any extent; it completely lines the two lateral ventricles, being continued from one to the other beneath the fornix, through the foramen commune anterius; one *cul de sac* extends into the third ventricle and infundibulum, and another through the iter ad quartum ventriculum, which lines the latter, and closes it below; this latter *cul de sac* is so delicate, that it is often, nay usually, broken by the violence used in the dissection; some anatomists have denied its existence, and have affirmed that the ventricular fluid may always escape through the bottom of this chamber, and communicate with the

sub-arachnoid space and fluid in the spinal canal, and *vice versa;* with great deference, however, to these authorities, I feel convinced that the fourth ventricle is closed inferiorly, not only by the external arachnoid, passing like a bridge from the cerebellum to the spinal cord, but also internally, and at the lower end of the calamus scriptorius, by a fine membrane with white neurine adhering to it; and I have frequently found this, particularly in children, competent to sustain water or mercury which I had dropped into the cavity from the iter or aqueduct of Sylvius above. That the internal or ventricular arachnoid is continuous with the external around the veins of Galen, or by the canal of Bichat, has been denied by some; however, repeated and careful examinations in young subjects have satisfied me that such is the case; and it is no valid objection to this account of it, that we so frequently find the canal closed or partly obliterated; an analogous change occurs in the tubular processes, between the scrotal serous membranes and the peritonæum; these were once open, serous canals, but at a very early period their sides adhere, and the original characters disappear.

As in other serous membranes, the opposed surfaces of the arachnoid are always lubricated by a fine fluid or halitus, which facilitates their gliding motion, and obviates friction; but there is also a clear fluid at all times effused beneath the arachnoid in the subserous tissue, and this is remarkably the case in the spinal region; there is more or less of this effusion in all the sulci between the convolutions of the brain, but in some instances it is scarcely to be observed; it is more abundant in the sub-arachnoid spaces at the base around the vessels, and in the sheath of the nerves, and can be well seen in a very recent brain; the superior and posterior sub-arachnoid spaces seldom retain any, probably because, as they communicate with the spinal sub-arachnoid, the fluid gravitates to it. The arachnoid and sub-arachnoid fluids are not to be confounded with each other; the former is in the arachnoid cavity, and, as in other serous cavities, is exhaled and removed by the vessels of the membrane; but the subarachnoid is in the subserous tissue, does not communicate with the former, and depends on the vessels of the pia mater for secretion and absorption; this appears a more reasonable explanation, than to suppose that the cerebral layer of the arachnoid is truly serous, or exhalent and absorbent on both its surfaces: some have conjectured that the arachnoid fluid may be derived from the sub-arachnoid, by permeating from the cellular tissue through the arachnoid membrane, on the principle of hygrometrical moisture, or by endosmose and exosmose; arachnoid fluid may often be effused in abundance, and there may be little or no sub-arachnoid, and on the contrary, the arachnoid surfaces may be almost dry, and yet all the sub-arachnoid spaces gorged with fluid; lymph and purulent looking fluid are also often effused in the latter, but rarely in the former; to explain or account for this peculiarity in the cranial and spinal serous membrane, that is, for the existence of fluid both in its serous cavity and beneath its visceral layer, we

must bear in mind that the brain does not entirely fill the cranium, and also that it undergoes a constant motion; the latter is two-fold, one is synchronous with the pulse, or with the systole of the ventricles of the heart, the other is an elevation and subsidence corresponding to exspiration and inspiration; in exspiration the veins of the neck, spinal cord, and brain are filled, and they compress the sub-arachnoid fluid, and raise the brain; in inspiration they collapse, and the organ subsides in proportion; the fluid or halitus in the serous cavity facilitates these motions by obviating friction and adhesion, while the sub-arachnoid fluid surrounds and supports the nerves and large vessels at the base of the brain, and the vessels of the pia mater over the entire surface; and as the latter is very uneven, it renders the whole smooth and regular by filling up the sulci and depressions, and thus secures and maintains uniform apposition between the parietal and visceral surfaces of the arachnoid; it must also contribute to lessen concussion or vibration from the parietes, and at the base, where it always abounds, it may be of essential service in protecting the large vessels and the nerves from the surrounding pressure. I pass over the hypothesis, that as this fluid has been found to hold in solution the nutrient elements of neurine, it may minister to the nourishment of the nervous centre.

The quantity of fluid in the sulci and sub-arachnoid spaces bears a constant ratio to the state of the organ, as if it were designed to regulate the size of the entire mass; in the very young and healthy there is little or none, except at the base; also, if the brain be hypertrophied, and its vessels full; but, whenever it becomes anemic, shrunk, small, and atrophied in whole or in parts, as sometimes occurs in very advanced age, or in idiots and lunatics, it is in considerable quantity, and often gives to the surface of the organ an anasarcous appearance; this condition is sometimes, but by no means uniformly, coincident with general anasarca; I have seen it in the anasarca that follows scarlatina; it is often sudden, and the result of inflammation. If fluid accumulate in the general arachnoid cavity, it constitutes the disease called hydrocephalus externus, and the brain is compressed; this form of dropsy is rare, though analogous to that of other serous cavities: if it collect in the ventricles, it constitutes hydrocephalus internus, a disease of more frequent occurrence, and in early life; the brain then becomes expanded, but also compressed from within by the enlargement of the cavities; in neither of these forms of dropsy, in general, is there sub-arachnoid effusion.

The *pia mater* is the next, or the third tunic of the nervous centre; it forms its immediate covering; like the two preceding membranes, it presents peculiarities in its cranial and spinal divisions.

The *cranial pia mater* is a vascular tissue of great extent and delicacy; in many parts it cannot be raised as a distinct membrane, independent of the arachnoid, which is inseparably joined to it, as on the surface of the several convolutions; but in the sulci between these, at the different fissures, and in the depressions on the base of the brain,

they are perfectly distinct; it adheres to the whole surface of the brain, following every involution; it also extends into its ventricular cavities; it is intimately connected to the grey structure, by being prolonged into it; and numerous fine capillaries pass through this into the white substance, which often admit of being drawn out to a considerable length; it appears to be almost wholly composed of the nutrient vessels of the brain, which divide upon it with extreme minuteness. The capillary arteries are remarkable for their free and obvious inosculation, and, though extremely small, admit the coloured globules of the blood; from the vascular net-work the delicate vessels are seen to pass into the nervous substance; the capillary veins escape from it, and also ramify in this membrane, and unite into larger vessels, which finally reach some of the sinuses. All these vessels are connected together by the most delicate cellular or subserous tissue; in some situations this is strengthened by scattered fibrous bands, as at the base of the cerebrum, in the fissures of Sylvius, and below and behind the cerebellum. In the spinal portion, as we shall see hereafter, this fibrous element abounds. In the sulci, between the convolutions, by injecting air or any fine fluid beneath the arachnoid, we can separate these membranes to some extent; the serous will then be seen to pass from one eminence to another, while the vascular sinks to the lowest part of the fissure, descending on one side and ascending on the other; by a little care it may be drawn out and unfolded. We may thus infer the vast extent of its surface; how much greater than that of the arachnoid, and how it exactly represents the superficies of the grey coating of the cerebrum, supposing it were possible to unfold the latter, and expand its involuted surface into a level plane. On the cerebellum it is arranged in a similar manner; it not only covers its whole surface, as the arachnoid does, but it sinks in between its numerous plates, and its double laminæ line all the grooves and fissures, primary and secondary, which penetrate that organ; it is even more delicate, and, therefore, more difficult to separate from the arachnoid, and from the nervous tissue on it, than upon the cerebrum; from the latter it may be torn, or jerked off with the forceps, without injury to the surface, but on the latter it is too fine and weak to admit of this experiment.

In each Sylvian fissure, and in the central cerebral depression, as well as in the other sub-arachnoid spaces, the pia mater may be easily detached from both surfaces, and affords a good opportunity for the examination of its capillaries. From the surface of the brain it is prolonged into the ventricles, and forms remarkable processes in these cavities; these may be considered as only two in number, but, according to some, as five: thus, at the back of the medulla oblongata, between it and the inferior vermiform process of the cerebellum, a fold of pia mater is pushed into the fourth ventricle, from below upwards. This is considered by some as double, one on either side, but they are really united in the median line; this is the choroid plexus of the fourth ventricle; the other, the great internal prolongation, enters the transverse

fissure in the cerebrum, and is divided by anatomists into three parts; its middle portion is called the velum interpositum, because it is interposed between the third ventricle, which is beneath it, and the fornix and corpus callosum, which are above it; its lateral portions are named the choroid plexuses; but these are united by the velum, and really constitute but one fold. The transverse fissure extends from the inferior and internal part of the middle lobe of the cerebrum on one side to the same point on the opposite; commencing between the middle lobe and the crus cerebri, it leads upwards and backwards external to the tractus opticus and optic thalamus, then bends transversely across the median line, in front of the cerebellum and of the tubercula quadrigemina, and behind and beneath the fornix and the posterior bent end of the corpus callosum, and then inclines downwards and forwards on the opposite side. In the lower and anterior part of this fissure, on each side, the choroid fold or plexus enters into the inferior portion of the lateral ventricle, passes first upwards and backwards, then bends forwards and inwards through the middle portion or body of each ventricle, and those of opposite sides, converging in front, become continuous in the foramen commune anterius, beneath the anterior pillars of the fornix; both are also united in the median line, beneath this body, with the velum. Each plexus appears to be a compressed fold of the vascular membrane, which frequently admits of being expanded into a beautiful, delicate, vascular web, with numerous tortuous capillary arteries, and one or two veins bordering it, which it receives from the corpora striata; these veins finally end in the venæ Galeni; each plexus hangs loose into the cavity, and can be pushed to either side, but is attached to the margin of the fissure by the fine serous membrane of the cavity being reflected over it; this adhesion is very distinct in the line of the fissure, but the reflected membrane is too delicate to admit of demonstration over the web itself. When the plexus is removed, and carefully examined, it is found to present projections or folds like the placental tufts or the villous processes of the chorion—these are plexuses of small vessels; the whole surface is covered with a fine epithelium like that of serous membranes. There is every reason, therefore, to suppose that each plexus is but a fold of pia mater pushed into the ventricles through the cerebral fissure, and carrying before it an inflection of the lining serous membrane of the cavity. The fissure is thus closed internally, while externally the arachnoid membrane, in passing from one eminence to another, also attaches its margins. The velum interpositum connects one plexus with the other, is thin and transparent, and in some parts so weak as to give way under examination; of a triangular form, its base is posteriorly, in the fissure between the quadrigeminal bodies and the corpus callosum; to its lateral borders the choroid plexuses are attached; its apex is in the foramen commune anterius. A number of veins from the corpora striata, optic thalami, and septum lucidum, join it at this point, and commence the venæ Galeni; these proceed backwards in the median line of the velum to the straight sinus; its

upper surface is covered by the fornix and corpus callosum, and it lies over the optic thalami and the third or median ventricle; on raising it anteriorly, and drawing it gently backwards, we rupture numerous vessels passing to and from the optic thalami, and near its base two laminæ descend to form a capsule for the pineal body; between these laminæ, and above this body, is the anterior extremity of that tubular prolongation of the serous membrane which is continued from the external surface, around the venæ Galeni, into the upper and back part of the third ventricle, and is thence expanded and continued over the whole of the ventricular surface. The velum and choroid plexuses will be again alluded to in the dissection of the lateral ventricles; it will be then seen that these three are but one vasculo-membraneous expansion or fold prolonged from the external surface to cover and convey blood-vessels to and from the internal; this fold carries before it the serous membrane of the cavities; it must, therefore, be composed of four laminæ, viz., the two serous, enclosing the double vascular fold, while again the whole extent of the transverse cerebral fissure is closed externally by the arachnoid passing from one side or eminence to the other, except around the venæ Galeni, where it is prolonged inwards in the tubular manner described. A simple mode of regarding the transverse fissure, velum, and choroid plexuses, is to suppose that the floor of the lateral ventricle was, in an early stage of development, the surface or summit of the brain, and was then covered by the vascular and serous membranes; but as the crura cerebri extend upwards, and the hemispheres enlarge, the latter come to conceal what was the surface, and to overlap it both before and behind, as well as internally, externally, and inferiorly, and the margins of this overlapping portion are attached to the root, or to the crus cerebri, by the arachnoid membrane passing across the fissure, and adhering to either side.

There are two modes of dissecting the encephalic mass; one consists in examining it from above downwards, by removing it in successive slices; the other proceeds from below upwards, and consists in unravelling its structure by tracing the columns or fasciculi of the spinal cord as they radiate, expand, and enlarge in the cranium. We shall commence with the first, whereby the student can become acquainted with the descriptive anatomy of each part, its situation, relation, and form, which knowledge is necessary before he can pursue the other course, or that from below upwards, whereby he can unravel the structure, and trace the connexion, relation, and dependence between one part and another, though at a distance. This latter mode is the most physiological or natural, because it attempts to follow the order of succession, in which the several divisions of the encephalon are first developed in the embryo, as also to explain the relative importance of each as they are first found in the different classes of vertebral animals, what parts are primary or essential, and what are superadded. Thus the spinal cord exists in all vertebrata, but the other parts are only gradually added as we rise in the animal scale from the lowest to the

highest. In the lowest some parts are totally absent, or only rudimentary; but as we ascend from fish through reptiles, birds, and mammals, either new organs are superadded at every stage, or the original become more complex in structure. With a view to pathological investigation, the first-mentioned course of dissection is indispensable.

Before we enter on the minute examination of the nervous centre, we should consider the nature of the materials of which it is principally composed. A section of almost any portion of the cerebro-spinal axis exhibits two species of nervous matter, or neurine, one grey, the other white; the grey neurine covers the cerebrum and cerebellum, and has, therefore, been termed "cortical," but incorrectly, for it is also placed internally in many situations, as in the corpora striata, optic thalami, and tubercula quadrigemina, and in the spinal cord it is altogether enclosed in the white. The white neurine, also called "medullary substance," is not only a large constituent of the nervous centre, but is also the chief element of the nerves, and always presents a fibrous structure, much more distinct, however, in some parts than in others: these two substances differ essentially.

The *grey neurine* appears in two forms, first, as a thin lamina, about the eighth of an inch in thickness, over the entire surface of the cerebrum and cerebellum, convoluted or involuted on the former, and folded into laminæ or plaits upon the latter; and, secondly, as distinct ganglionic masses, such as the corpora striata and optic thalami; it is very soft, and breaks down, under slight pressure, into minute granules, which are entangled in vascular shreds from the pia mater. The microscope has revealed that these granules are vesicles or cells with nuclei and nucleoli; that they are imbedded in a granular substance, and that they differ in form and size in different situations; in general they are globular, and composed of a transparent, membranous covering, filled with soft, granular matter, on which the colour depends. Adhering to some part of this vesicle is the nucleus, and apparently similar in structure; within the latter is the small, transparent nucleolus: among the vesicles, in different situations, are pigmentary particles, on which, as well, probably, as on varying degrees of vascularity, depends the peculiar shade of colour in certain parts: though the vesicles are usually globular, yet some deviate from this form, and have projections or caudate processes of variable length. Among the globules in the grey neurine we also find a number of the white nervous fibres. Grey neurine is the most vascular portion of the nervous system, and is regarded by the physiologist as the source of nervous power, or the great dynamic agent in the function of innervation.

The *white neurine* always presents a fibrous appearance, both in the nerves and in the nervous centre; in the former it is alone, but in the latter is combined more or less with the grey. The fibres are tubes disposed in fasciculi, which are usually straight; some occasionally appear varicose, but this probably is owing to accidental pressure; the diameter of a tube is said to vary from $\frac{1}{5000}$ to $\frac{1}{14000}$ part of an inch;

each consists of a fine, transparent membrane or neurilemma, containing a soft or semifluid substance. After death this soon becomes more compact, and then presents an opaque, white appearance. In the nerves these fibres are bound together by areolar tissue, but in the nervous centre none of this can be observed, excepting, that most minute portion which accompanies the fine blood-vessels that are scattered through it. The white neurine greatly exceeds in quantity the grey, as the greater portion of the brain and spinal cord, and all the nerves, are composed of it. The mode in which the two extremities of the white fibres terminate is not perfectly ascertained in every texture; in some it is obvious, and, resting on analogy, it is very generally admitted that, in the grey neurine in the centre, they end in loops or in plexuses, and at their peripheral extremities in loops also. White neurine is considered to differ from grey in function, and to be only internuncial or conducting, the medium for transmitting impressions to the sensorium, and of conveying from the latter the stimulus of volition to the muscles, as also of uniting different and distant nerves, and different portions of the nervous centre; the fibres which minister to the first of these offices are termed *afferent*, to the second *efferent*, and the third are *commissural* or uniting. The encephalic mass consists of four portions, which are not, however, perfectly separate; first, the cerebrum, which occupies all the upper, lateral, and anterior regions of the cranium; second, the cerebellum, lodged in the inferior occipital fossæ; third, the cerebral protuberance, or mesocephale, resting on the cuneiform process and body of the sphenoid bone, nearly in the centre of the base of the skull; and, fourth, the medulla oblongata, which corresponds to the foramen magnum and atlanto-occipital space. No accurate line distinguishes this from the spinal cord.

SECTION II.

DISSECTION OF THE CEREBRUM.

THE cerebrum is the largest part of the brain, and larger in man than in any other animal; of an oval figure, the larger end posteriorly, the longest transverse diameter corresponds to a line from one mastoid process to the other; a little flattened on the sides, convex above, and divided into two symmetrical portions, the right and left hemispheres, by a deep median fissure; this fissure is continued before and behind through the entire depth of the cerebrum; descends anteriorly to the base of the cranium, and posteriorly to the tentorium, but in the middle is interrupted by the corpus callosum; it contains the anterior cerebral arteries and veins, and the falx, beneath which the inner surfaces of the hemispheres are in contact; each hemisphere is convex superiorly and externally, flat internally, or towards the falx; inferiorly

very irregular and uneven; the surface, smooth and polished from the arachnoid covering, is everywhere marked by a number of eminences, termed *the convolutions of the brain*, from being convoluted somewhat like the intestines; these are of various size and shape; their round edges are separated by fissures or sulci, which take different directions, serpentine, longitudinal, and oblique.

The convolutions are so varied as almost to defy individual description, indeed neither their form nor number can be accurately defined, for each runs into the other at some one part, and though at first view distinct, they really are not so; there is a close, but not in all cases a perfect, symmetry between those of opposite hemispheres; each is nearly surrounded by a narrow sulcus or sub-arachnoid space; this becomes very distinct in cases of atrophy of the convolutions or of subserous effusion; some are depressed, others marked by lines or subdivisions; the sulci also vary, some are an inch and a half, and some only a quarter of an inch in depth. A convolution is a convex fold of superficial grey neurine, covered all round to its base by pia mater; a sulcus is a depression or involution between any two or more convolutions, and is lined by a continuation of the grey lamina; in the structure or thickness of the latter, there appears no difference either in the sulcus or on the convolution; the grey neurine, therefore, forms, all over the cerebrum, two series of folds or processes, one are convolutions, convex externally, and concave internally; the other are involutions, concave externally, and convex internally; the white fibres are inserted into every point of the internal surface of the grey coating; some fibres, therefore, must be longer than others, those, for instance, which are inserted into the concavity of an eminence, than those which only reach the convexity of a sulcus: we may suppose that the white fasciculi radiating from within are, some long, others short, some thick, others thin, and that all are to be capped or coated over by a lamina of grey neurine of nearly uniform thickness; the latter, therefore, must present a convexity where it is expanded over long or thick fasciculi, and a concavity where it is involuted or depressed in order to reach shorter or smaller bundles.

Some convolutions are more uniformly present than others, and exist in the lower animals; such are named primary: others are in a great measure offsets from these, and are called secondary. The direction of both is variable, but the latter are mostly transverse, and the former from before backwards. Of the primary convolutions one of the most regular is that long curved one on the inner side of each hemisphere, above the corpus callosum, from which it is separated by a narrow sulcus; this, having some resemblance to a hem or selvidge around the edge of the hemisphere, has been named the "ourlet" or hem-like convolution. Smaller convolutions branch upwards from its central portion. Anteriorly it bends down like the corpus callosum, and is lost in some of the inferior convolutions near the Sylvian fissure; posteriorly it also follows the corpus callosum, is connected to some posterior convolutions, and then bends downwards and forwards in the

middle lobe, external to the tranverse fissure, and forms the hippocampus major and its foot-like expansion. The fissure of Sylvius separates its extremities; it contains a fasciculus of white fibres which take a peculiar direction, that is, parallel to the convolution, and is named *superior longitudinal commissure.* On the under surface of each anterior lobe are two long but small convolutions bounding the sulcus which lodges the olfactory lobe. A large convolution bounds the Sylvian fissure, and is connected to those before and behind, and at the bottom of this fissure is that very remarkable cluster of radiated convolutions, known by the name of the "island of Reil;" the fissure itself is a great involution of the grey lamina, and its whole surface is wonderfully extended by complex convolutions and indentations. The convex surface of each hemisphere presents several convolutions: those on the occipital lobe are the smallest, the largest correspond to the parietal bones, and the anterior are of a median size; the sulci are principally vertical, and obliquely transverse; a convolution on the inner side of the posterior lobes extending backwards, corresponds to the hippocampus minor in the posterior crus of each lateral ventricle. There are no convolutions in the brain of fish, reptiles, or birds; they first appear in the rodentia among mammalia, and only in certain members of that class, and in them are merely rudimental; they are decidedly developed in the carnivora, and still more so in the ruminantia; in the elephant, and in some of the cetacea, they are very numerous; in the porpoise and dolphin they are small, and as numerous as in man, but I find the sulci and involutions are very shallow, so that the vesicular lamina is not at all so extended as might be at first supposed; in the quadrumana the convolutions are inferior in number and size to those in the elephant or porpoise, but the sulci and involutions are deeper, and the whole organ, especially the occipital lobes, bears a greater resemblance to that in man, except in point of size. In man they are more symmetrical and uniform, and the sulci and involutions are better marked, than in any other animal, therefore, in him the vesicular layer is most extensive. In the fœtus at birth, and more so previously, the convolutions, though all present, are not so distinct, the sulci are not so deep, and the involutions are scarcely developed. If the brain of the fœtus and that of the adult be contrasted, a striking difference will be observed, not only in respect to the convolutions, sulci, and involutions, but also in the investing grey lamina, which is much thinner and paler in the former than in the latter.

A section of either hemisphere clearly displays this convoluted and involuted arrangement of the vesicular or grey neurine, the mechanical effect of which must be threefold; first, to increase the superficial extent of the vesicular or grey lamina; second, to extend that of the pia mater, or vascular nutrient tissue, in the same degree; and third, to enable a greater quantity and number of white or conducting fibres to come into contact with the vesicular matter than could possibly be the case, if the latter, in the confined area of the skull, presented one

smooth, uniform expansion, as is the case in the more simple brain of the inferior animals. The physiological design of this formation is a problem still involved in mystery; different opinions are entertained respecting it; some maintain that as the grey neurine is the most highly organized portion of the nervous system, it is the most influential in the function of innervation, that it is, in fact, the principal dynamic agent in this function, and that the greater the extent of this substance, *cæteris paribus*, the greater will be the capability of manifesting nervous power. Now this convoluted arrangement of this material has the obvious effect of collecting into a small space a great superficial extent, whereby the greatest possible number of white fibres are brought into contact and communication with it. Others, who maintain the analogy between the phenomena of electricity and those of the nervous system, consider that, as the electric force is proportioned, not to the quantity of the mass concerned in its production, but rather to the extent of its surface, so the energy of nervous action will be in proportion to the superficial extent of the grey or dynamic neurine, and to the number of connecting points between it and the white or the conducting fibres. It is very generally believed, and certainly with great reason, that, as the convolutions and the hemispheres are more highly developed in man than in any other animal, his mental and intellectual superiority is connected with their existence; that, in fact, the convoluted surface of cerebral grey neurine is the seat of intellectual action. This opinion is confirmed by comparative anatomy, by contrasting this surface in the male and female, in the child, in the adult, and, again, in the very aged, and in different persons whose intellectual powers had been known, and could have been compared during life; also in the idiot, the lunatic, or diseased; also by observing that inflammation of this surface, or of its vascular membrane, disturbs all mental operations, and even induces delirium. This opinion is carried still further by the phrenological school, whose supporters insist on two distinct propositions: first, that there exists a plurality of mental functions, or certain distinct fundamental faculties, moral feelings, and propensities; and secondly, that the cerebral convolutions are the organs or material instruments by which those functions are performed; and they accordingly mark upon the skull numbers corresponding to certain convolutions or mental organs within. The first proposition is purely metaphysical, and may or may not be true; its consideration does not fall within our province: the second rests not merely on the universally admitted opinion that the convoluted surface is the seat of intellectual operation, but mainly on the frequently observed and very remarkable coincidences between certain high mental manifestations and great development of the corresponding convolutions. To this theory it has been objected, first, that not only is the grey neurine one continuous and unbroken surface, without any structural distinction or division between its various eminences and depressions, but the white fibres also appear combined into one uniform mass; secondly, that several convolutions are not recognized,

though in point of size and uniformity of existence they would appear superior to those which have been stamped with numbers, for example, the "ourlet," the "Sylvian," the convolutions of Reil, and many at the base; thirdly, that the apparent fulness or obvious prominence of some eminences may depend, not on any superior development in them, but rather on a protrusion of others which are contiguous or deeper seated; thus a highly developed "ourlet" might account for an elevation of the vertical and parietal convolutions, &c. &c.; fourthly, no precise function can be assigned to the involuted or depressed convolutions, whereas if the dynamic power of the whole organ, or of individual portions, be in a ratio to the superficies of the grey lamina, then this series of involutions, or depressed convolutions, must be equal in function and importance to the convex eminences, inasmuch as the combined areæ of the former exceed that of the latter; neither are convolutions and involutions always in the same ratio; the latter may be deep, and even expanded below, when the convolutions are by no means prominent, and *vice versa*. Therefore, mere inspection of the convex surface of the cerebrum cannot enable us to judge of the superficial extent of the grey or vesicular lamina. We may see a large brain, with full and well-developed convolutions, but with shallow involutions, and, on the other hand, we may see a small brain, with moderately developed convolutions, but deeply prolonged involutions; in the latter case we shall probably have an equal extent of superficial area of vesicular neurine, and, therefore, an equally dynamic organ and energetic brain, as in the former, all other conditions as to temperament, health, &c., being supposed equal; fifthly, in the fully formed skull the internal surface of the bones is marked by depressions which correspond to the convolutions, and by intervening ridges or prominences corresponding to the sulci; so that from an internal mould of the cranium a very accurate representation of all the surface of the cerebrum may be taken, except the inferior portion of the occipital lobes which rest on the tentorium. At the base of the cranium the bony ridges are more prominent, but in the superior regions the depressions are more developed, and the intervening lines are softer and less projecting. On account of the frontal sinuses, and of the diploe, the external surface of the skull does not by any means exactly represent the internal, but is more smooth and even, and never accurately presents eminences and depressions inversely corresponding to those within; to some extent, however, and only to some, does the external surface of the bones indicate the projections on the surface of the brain; when a certain portion of the latter, or a certain group of convolutions, are very prominent, the skull in that region will be prominent also, and *vice versa;* but we very seldom find distinct external elevations corresponding to individual convolutions.

The cerebrum, on its inferior surface, also, is divided into the two hemispheres by the great median fissure at each extremity, and in the centre by a remarkable depression; each hemisphere inferiorly is very uneven, and divided into three lobes, the anterior or frontal, small,

triangular, flat, or a little concave, rests on the roof of the orbit, presents a deep groove which lodges the olfactory lobe and bulb, and is separated from the opposite one by the median fissure, the falx and crista galli. The *middle* or *temporal*, or *parietal lobe*, is prominent, convex, and deep, fills the middle fossa in the base of the cranium, and is separated from the anterior by a deep fissure (*fissura Sylvii*); this proceeds from the anterior and lateral part of the median depression, in front of the anterior inferior extremity of the great transverse

*Fig. 69.**

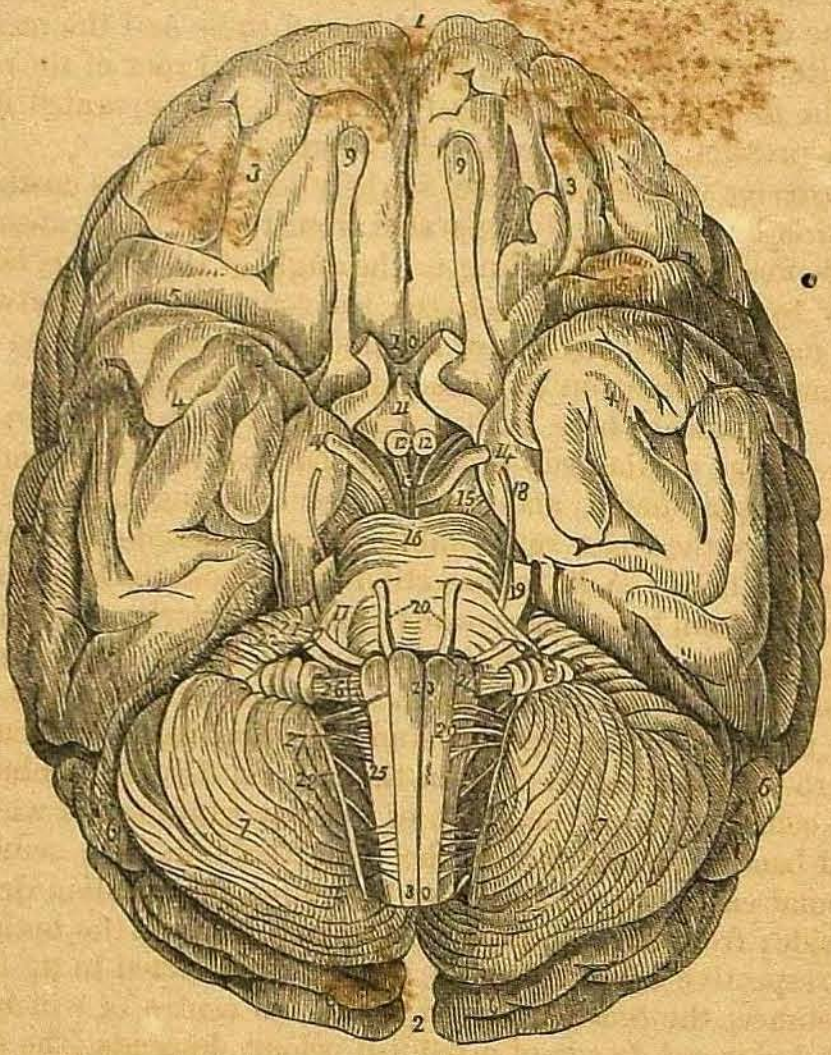

* The inferior surface, or base of the brain. 1. The anterior extremity of the great median fissure. 2. Its posterior extremity. 3.3. Anterior lobe of each hemisphere. 4.4. The middle lobe. 5. The fissure of Sylvius. 6.6. The posterior lobes of the cerebrum partly concealed by, 7.7. The lateral lobes of the cerebellum. 8. The pneumogastric lobule. 9. The olfactory lobes. 10. The commissure of the optic nerves. 11. The tuber cinereum and infundibulum projecting from it. 12. The corpora mamillaria or pisiform tubercles of the fornix. 13. The locus perforatus medius. 14. The third nerve. 15. The crus cerebri. 16. The pons Varolii. 17. The crus cerebelli. 18. The fourth nerve. 19. The fifth or trifacial nerve. 20. The sixth pair of nerves. 21. The portio dura, and 22. The portio mollis of the seventh nerve. 23. The corpora pyramidalia of the medulla oblongata. 24. The corpus olivare. 25. The corpus restiforme 26 The glosso-pharyngeal division of the eighth nerve. 27. The pneumogastric division, or par vagum. 28. The spinal accessory nerve. 29. The roots of the ninth, or lingual nerve. 30. Superior portion of the medulla spinalis.

fissure it ascends obliquely upwards, and backwards, is a little convex forwards, and divides into two minor fissures, which end in adjoining sulci; its margins are held together by the arachnoid, above which is the lateral sub-arachnoid space which communicates with the median. On opening it we see the middle cerebral artery large and tortuous; the entire surface is much convoluted, and between the lesser divisions of the fissure is a remarkable group of convolutions, known by the name of the "island of Reil;" at the inner end of the fissure, there is a small portion of brain perforated with many small holes (*pas perforee externe*), through which tufts of vessels from the pia mater pass to supply the corpus striatum; on plucking off these and the membrane, a fine white line an inch long is seen, the external root of the olfactory lobe. The middle lobe is bounded internally, and separated from the median depression, by the transverse fissure.

The *posterior* or *occipital* lobe, slightly concave, rests on the tentorium, and is but indistinctly separated from the middle, externally by a slight depression corresponding to the angle of the petrous bone, and internally by a deep sulcus between the convolutions. Between the round or mammillary surfaces of the middle lobes of opposite sides, is the median depression on the base of the cerebrum, over or beneath which the arachnoid (here rather strong), is tensely drawn; above this is the great median sub-arachnoid space traversed by shreds and fibres of the pia mater, and areolar tissue entangling more or less fluid, which bathes the remarkable arterial inosculation (circle of Willis) seated here. A little dissection will expose the following parts in this region, from before backwards: most anteriorly, directly behind the median fissure, is the anterior extremity of the corpus callosum, very thin, and reflected backwards: it expands somewhat, and is attached mesially to the optic commissure and tuber cinereum, and laterally to each perforated plate in the Sylvian fissure; behind this is the optic commissure, or the union of two flat white tracts which may be traced backwards as far as the optic thalami, in a semicircular course round each crus cerebri, and bounding this median depression on each side; from the commissure anteriorly diverge the optic nerves to their respective orbits; behind this, and connected to it, is a soft, grey substance, the *tuber cinereum*, from the centre of which a thin, conical, tubular *cul de sac* of a reddish colour descends (the *infundibulum*), behind and rather beneath the commissure of the optic nerves, and terminates on the surface of the pituitary body, surrounded by arachnoid and pia mater; is not pervious inferiorly, but communicates above with the third ventricle. The *pituitary* body is placed in the sella Turcica, between the dura mater and arachnoid membrane; transversely oval, composed anteriorly of a yellowish substance, which is notched before, and convex behind like a kidney, and posteriorly of a whitish, semi-fluid, or pulpy substance; its connexion to the brain is so slight as to give way in raising the latter from the base of the skull, and it is difficult to dislocate it out of the sella Turcica, as the dura mater covers it, leaving only a circular deficiency for the attach-

ment of the infundibulum. Behind the infundibulum and tuber cinereum, and connected to the latter, are two small white bodies termed the *corpora mammillaria* or *albicantia* or *pisiformia ;* these are about the size of small peas, they are grey internally, white externally; the anterior pillars of the fornix terminate in these; though separate below, they are joined above by the tuber cinereum; they assist in closing the third ventricles, and are probably of a ganglionic character. Behind the corpora albicantia is a small triangular depression, closed above by a thin plate which forms the posterior part of the floor of the third ventricle; this is the *middle perforated plate of the brain*, also called the *intercrural lamina*, as it joins the crus cerebri on each side; it is also named "pons Tarini"; tufts of small arteries pass through it, to supply the crura cerebri and optic thalami; the third pair of nerves is partly connected to it; immediately behind this is the upper and anterior border of the pons Varolii, with its median groove lodging the basilar artery, and on either side of it are the *crura cerebri*, or the peduncles of the cerebral hemispheres; these appear as two short, round, and thick fibrous cords, attached below to the pons Varolii, ascend and diverge, and are continued upwards into the optic thalami and corpora striata in each hemisphere; the third pair of nerves is connected to them internally, and the optic tracts wind round them externally. Below the pons is the medulla oblongata, which we shall not further notice at present; and above and behind the pons are the tubercula quadrigemina, above which is the posterior, thick, doubled-like end of the corpus callosum; and between these is the median, or transverse portion of the great cerebral fissure, which thence extends on each side downwards and forwards, as far as the inner end of the Sylvian fissure, internal to the middle lobe, and external to the crus cerebri and optic tract; through this descending portion, the choroid plexus enters the lateral ventricle, and in the middle or transverse portion are situated the pineal body, the venæ Galeni, the velum, and the arachnoid canal; the fourth pair of nerves is nearly parallel to this fissure; behind the middle or transverse portion of it the tentorium is seen, and above this is the continuation of the median fissure between the occipital lobe of each cerebral hemisphere.

Cut off the upper part of one hemisphere nearly on a level with the corpus callosum, the appearance presented is termed the *centrum minus ovale* that is, a mass of white fibrous substance surrounded by an irregularly undulating line of grey; the small cavity or fissure may also be observed between the corpus callosum and the lower and internal margin of each hemisphere: next slice off both hemispheres on a level with the corpus callosum, and the *centrum magnum ovale* is presented, that is, a line of grey substance surrounding the central mass of white; in this section the continuous marginal line of grey neurine is well seen, with its convoluted and tortuous windings and map-like indentations, and this view explains how the superficies of this lamina is thereby extended, so as to present numerous points of contact to the white fibres radiating from the centre; to these convolutions and in-

volutions we shall again allude, when we have concluded the dissection of the organ. The white centre in many parts appears distinctly fibrous, and dotted with red spots, divided vessels, which vary in number and in size in different subjects; in a very fresh brain, when this section has been made, the white substance will often by its elasticity force the blood to exude for some little time in small drops.

The *corpus callosum*, or *great* or *superior cerebral commissure*, is now seen in the median line of the cerebrum, nearer the frontal than the occipital bone, between three or four inches long, convex, white, marked by two or three raised longitudinal lines closely and nearly parallel to each other (*the raphe*), from these several transverse lines pass to either side; its posterior end, thick, broad, round, and a little concave, is bent downward above the transverse fissure, and is continuous with the fornix and the hippocampi; its anterior end is also round, is bent downwards and backwards, and continued on each side into the anterior lobes; in the middle it joins the tuber cinereum, and the optic commissure: the corpus callosum connects the white fibrous substance of the hemispheres, and is therefore properly called the great commissure of the cerebrum; some portion of it also curves downwards external to the lateral ventricles, and joins the optic thalami and corpora striata, between which bodies of opposite sides it may also serve as a commissure; it bears a ratio in size to the hemispheres, and is wanting in fish and reptiles, and is only rudimental in birds; the longitudinal fibres of the raphe are probably commissural between the transverse; the fibrous structure, both in the transverse and longitudinal direction, is often as distinct as that in any nerve; it covers like an arch the lateral ventricles, the septum lucidum, and the fornix, and curves downwards and forwards in front of, and then beneath these parts; the under surface of its posterior extremity is identified with the fornix, and assists in forming with the latter that appearance called *lyra* or *psalterium;* on either side of this it is continuous with the hippocampi or the fibres of the adjacent convolutions in the posterior and middle lobes. Divide it at a little distance from either side of the raphe; and the lateral ventricles will be opened; press the middle portion of the corpus callosum to one side, and the septum lucidum may be seen descending in the median line from it to the upper surface of the fornix.

The *septum lucidum* separates the two lateral ventricles, triangular, the apex behind, the base before, the upper edge connected to the corpus callosum, the lower to the fornix posteriorly, and anteriorly to the inferior curved portion of the corpus callosum; a vein is often seen on either side of it. It consists of four laminæ on each side: the first is the lining membrane of the ventricle; the second is a thin grey layer; the third a compact, white, fibrous one; and lastly a mostde licate membrane which lines the small cavity which exists in it, termed the *fifth ventricle*. The cavity is naturally closed, but when the corpus callosum is divided transversely, and its anterior portion raised forwards, the laminæ of the septum separate, and this space usually appears; it

is larger in the child, but is very irregular in size, and even in existence, in different subjects; in some it is very distinct, and contains a fluid; it may be regarded as a portion of the third ventricle shut off by the fornix; Tiedeman states, that in the early period of uterine life it communicates with that cavity. The septum lucidum appears to be formed by a white lamina descending from each side of the inferior surface of the raphe of the corpus callosum to the fornix, some grey matter being superadded; in function it is probably commissural. Divide transversely the septum lucidum and corpus callosum, raise forwards the anterior portion of the latter, and backwards its posterior part; it will now be seen that the corpus callosum is united to the fornix posteriorly, but is nearly an inch above it anteriorly; the septum lucidum is generally so soft, that in this stage of the dissection it will have nearly broke down into the surrounding fluid.

The *lateral ventricles* extend from the middle of the brain into the anterior and posterior lobes, also into the inferior part of the middle lobe; hence they are named *tricorne.* The *anterior cornua* diverge a little, as each passes forwards and outwards; the middle portion, or *the body* passes horizontally backwards; both this and the former are separated from the opposite by the septum lucidum; near the posterior part of the corpus callosum the posterior and inferior cornua pass off in different directions. The *posterior* proceeds into the posterior lobe, at first outwards, and then curves inwards, the concavity towards the median line. The *inferior cornu* descends obliquely forwards and outwards into the middle lobe, and is then also curved a little inwards; it terminates behind the fissure of Sylvius, and beneath the anterior cornu. The anterior is bounded superiorly and laterally by the corpus callosum, and inferiorly by the large extremity of the corpus striatum; the middle, or body of each, is bounded superiorly and externally by the corpus callosum; internally by the septum lucidum, and inferiorly by the posterior extremity of the corpus striatum, the lamina cornea, the tænia semicircularis, the optic thalamus, the choroid plexus, and the fornix. The posterior cornu, or digital cavity, is bounded superiorly and laterally by white substance, and inferiorly by the hippocampus minor. The inferior cornu is bounded superiorly by the optic thalamus and corpus striatum, externally by white substance; internally it is deficient of cerebral substance, and presents the transverse or great cerebral fissure, which is closed by the arachnoid membrane only; inferiorly by the hippocampus major and corpus fimbriatum, or tænia hippocampi, over which the choroid plexus is folded.

These several bodies, observed in the different regions of these cavities, must next be examined individually; and, first, the *corpora striata.* These pyriform bodies are anterior and external to the thalami, their larger ends are directed forwards and inwards, their posterior small and pointed extremities backwards and outwards, and then curve downwards and forwards in the inferior cornua; smooth and unattached superiorly and internally, covered only by the soft and deli-

cate lining membrane, with two or three considerable veins; on all other sides they are continuous with the white substance; vascular, soft, and cineritious on their surface, they will be found, when cut into, to consist of grey substance, intermingled with white striæ or fasciculi; the latter may be traced from the anterior or motor portion of the crura cerebri through these bodies to the upper and anterior part of the cerebrum, hence they are named the *anterior* or *superior ganglions* of the cerebrum, and are said to bear a ratio in size to that of the anterior and middle lobes; the corpora striata are also regarded by some as the centres of volition, as the fibres which traverse them are the motor tracts of the spinal cord. To expose these white striæ, an incision should be made obliquely through either, from the crus cerebri below, upwards and outwards, parallel to the fibres, which, as they ascend, diverge and radiate in every direction; if the section be horizontal, the surface will only present white spots, intermingled with grey substance; the fibres in passing through it subdivide very minutely, the interstices being filled with grey neurine; of the fibres, which can be traced into it from the crus cerebri, some only can be traced through it into the hemisphere; others appear to terminate in it, while many other fasciculi, not continuous with the preceding, emerge from it and pass, some upwards into the hemispheres and into the great commissure, and others inwards into the thalamus; the fasciculus, which forms the anterior commissure, passes through the anterior part of each of these bodies, and thus connects them to each other. The corpora striata, therefore, are connected to several parts of the brain; first, through the crura cerebri to the pons, medulla oblongata, and spinal cord; second, to the optic thalami; third, to the hemispheres; and, lastly, to each other, by the anterior commissure and by the corpus callosum.

The *lamina cornea* is a narrow, semi-transparent band, of a horny appearance, but very variable; it occupies the angle between the corpus striatum and thalamus, and covers a vein which passes from the former to the choroid plexus. Many consider it as only a thickening of the lining membrane; it often, however, presents a fibrous appearance, and may be a mere separation by the vein of a portion of the following:

Tænia semicircularis is a narrow band, white and fibrous, placed in the groove between the optic thalamus and corpus striatum. It *arises* narrow from a tubercle on the back part of the optic thalamus (corpus geniculatum externum), and from the fibres of the middle lobe at the upper part of the inferior cornu; passes forwards and inwards, becomes broader, and joins the descending pillar of the fornix: in function it is probably commissural, like the fornix.

The *choroid plexus* is a fold of thin and very red vascular membrane, derived from the pia mater, broad below, narrow above; it enters the inferior cornu by the great cerebral fissure, between the optic thalamus and the tænia hippocampi; loose and floating it ascends obliquely backwards over the hippocampus major, then curves forwards, covering the thalamus, and overlapped by the fornix, beneath

2 I 2

which it is connected to the velum interpositum; it ends by uniting with its fellow in the foramen commune anterius, behind and beneath the anterior pillars of the fornix. Each choroid plexus is covered by the arachnoid membrane; they receive a number of veins from the parietes of the ventricles, particularly from the corpora striata; these veins join the venæ Galeni, which will be noticed presently. Very frequently small vesicles, hydatids, and even small, hard tumours, may be found in these membranes; also sandy or calcareous matter, such as is frequently seen in the pineal body; they always present a number of small vascular tufts or villi, covered by a fine epithelium, on which the microscopical anatomists affirm that cilia exist, and that these have been seen in motion in the fœtus. The surface of each plexus is free, also the outer margin, but the inner is attached above to the velum, and below to the pia mater, between the margins of the fissure; to the latter the lining membrane of the ventricle also adheres, and closes the cavity so as to prevent the escape of fluid into the sub-arachnoid space. If any such escape ever take place, as some have supposed, it can only be by exosmose.

The *fornix* is a white, fibrous, triangular arch or vault, convex above, situated horizontally beneath the corpus callosum and septum lucidum, continuous with the former posteriorly, attached to the latter anteriorly and in the median line; it lies on the velum interpositum and choroid plexuses, and over the third ventricle; the base, posteriorly, *arises* by two long, flat bands (the *posterior pillars* or *crura*) one from either side, by three roots, from the hippocampus minor and major, and from the tænia hippocampi; these crura pass forwards and inwards, and unite (the *body of the fornix*); this bends forwards and downwards, over the foramen commune anterius, and divides into two short, round, white cords (the *anterior pillars of the fornix*); these descend behind the anterior commissure, and end in the corpora mamillaria; the grey substance of the tuber cinereum is also connected to and continued upwards upon them for some distance. The superior surface, on each side of the septum lucidum, and its margins, are smooth and free, and form part of the floor of the bodies of the lateral ventricles, and rest on the velum interpositum; the edges are very thin, and sometimes overlapped by the choroid plexuses. The inferior surface of the fornix, together with the intervening portion of the corpus callosum, which rests on the velum, is marked posteriorly by several fine oblique lines (*lyra*, or *corpus psalloides*). The fornix maintains several and very distant communications, commencing in the inferior or middle and posterior cerebral lobes, its two crura soon become connected to the corpus callosum and septum lucidum, and through these to each other, and, as its anterior crura descend, they are connected to the forepart of the optic thalami, to the pedunculi of the pineal body, to the tæniæ semicirculares, to the anterior commissure, tuber cinereum, corpora albicantia, optic commissure, and anterior extremity of the corpus callosum; its structure is evidently fibrous, and the fibres pass from behind forwards; it is considered as

an important and extended commissure, connecting the several parts enumerated, not only on each, but also on opposite sides; hence it may be named the *great inferior commissure of the cerebrum*, in distinction to the corpus callosum; the latter, however, is chiefly a transverse commissure, while the fornix is a longitudinal or antero-posterior bond of union. Though described as a single organ, it is really double or symmetrical, and perfectly divisible throughout, except where the lyra unites the opposite sides. Although the septum lucidum is a partition between the lateral ventricles, yet these cavities communicate together, as also with the third or middle ventricle, through an opening termed *foramen commune anterius;* this is situated in the median line at the anterior part of the body of each ventricle; it is bounded superiorly and anteriorly by the fornix, posteriorly by the optic thalami; laterally it leads from one lateral ventricle to the other, and inferiorly it opens into the third. The apex of each choroid plexus turns into this opening to join the velum. The optic thalami cannot be fully examined at present.

In the posterior cornu, or digital cavity of each ventricle, is a small eminence, the *hippocampus minor*, large anteriorly, small and pointed behind, white on the surface, grey within; it corresponds to a sulcus or longitudinal involution on the inferior surface of the posterior lobe. In the inferior cornu we see the *hippocampus major*, or cornu Ammonis, a large, white substance, convex externally, concave internally, smooth and white on the surface, grey within, extending all along the floor of the cavity, and ending in a tuberculated expansion, the *pes hippocampi.* This well-marked eminence is but the internal surface of the lower and posterior extremity of the great internal or "ourlet" convolution, which forms the inner border of each hemisphere, above the commissura magna, and extends downwards and backwards, both before and behind, to the base of the brain, as far as the fissure of Sylvius. The posterior inflection of this convolution, on the lower surface of the middle lobe, appears bent inwards upon itself like a horn, external to the cerebral fissure; a deep depression on the lower surface corresponds to this curved eminence in the lower cornu of the ventricle; along its internal or concave edge, and connected to it, is a narrow white band, the *tænia hippocampi*, or *corpus fimbriatum*, the concave edge of which is loose. This latter substance is directly continuous with the posterior pillar of the fornix; beneath the tænia hippocampi a narrow, cineritious line may be observed shorter than the tænia, its edge is serrated; this is the *corpus denticulatum*, or fascia dentata. Divide the fornix about its centre, draw forwards its anterior portion, and the foramen commune anterius will be seen; throw the posterior portion, or the lyra, backwards, and the *choroid membrane*, or the *velum interpositum*, will be exposed; this is of a triangular form, beneath the fornix, and above the arachnoid canal, the optic thalami, the pineal gland, and the third ventricle; the choroid plexuses are united to it laterally and in front; the *venæ Galeni* extend along its median line; these veins receive the blood from each plexus, and from the different

eminences in the ventricles; they pass backwards, and end in the straight sinus; they sometimes first unite into one trunk. The velum is formed of the pia mater, continued from the surface of the brain through the great transverse fissure, which is beneath the corpus callosum and the fornix, and above the tubercula quadrigemina and the pineal gland; it is also covered by the arachnoid membrane, which is of extreme delicacy; its apex is in the foramen commune anterius, arched, and a little bifid, and is joined by the two choroid plexuses; from its upper surfaces fine vessels pass into the fornix. Raise it carefully from before backwards, dividing as you proceed the many small vessels which pass to it from the optic thalami; these bodies will be now exposed, and posterior to these the pineal gland, and the superior surface of the tubercula quadrigemina; the anterior extremity of the arachnoid canal also is seen; this small orifice is beneath the veins of Galen and above the gland; it is in general surrounded by small granulations, and is often closed. If the velum be not raised gently and carefully, the pineal body will be disturbed, and its other connexions broken, as it is intimately attached to the velum by a fine membrane, which descends from it on either side of the venæ Galeni, to invest this organ in a sort of capsule. Along the inferior surface of the velum, in the median line, are two small fringed or granular lines, connected by vessels to the optic thalami; these are analogous to the lateral choroid plexuses, and are named the *choroid plexuses of the third ventricle;* remove the velum.

The *pineal body* is situated above the tubercula quadrigemina, behind and between the thalami, about the size of a pea, cineritious, heart-shaped, the base, looking forwards and upwards, contains in general some small sandy particles (the *acervulus*); the posterior inferior part or apex is soft and pulpy (the *conarium*), and surrounded by and adherent to a very vascular membrane derived from the velum; it rests upon the nates and posterior commissure, but unconnected to the brain in every situation, except anteriorly, whence a small transverse medullary band proceeds, which has a slight connexion to the posterior commissure, and then divides into two long delicate processes (*pedunculi*, or *habenæ*); these pass forwards, adhering to the inner margins of the optic thalami, and join the descending pillars of the fornix and the tæniæ semicirculares at the foramen commune anterius. The pineal body exists in all mammalia, but is absent in birds, fish, and reptiles, except in some of the chelonia. Various theories have been entertained as to its function. Descartes considered it to be the seat of the soul, and the great source of nervous power; Majendie that it stops the aqueduct of Sylvius, and thus prevents the passage of fluid from the third into the fourth ventricle. It is most reasonable to suppose it is connected with the system of commissural fibres, which extend from the quadrigeminal mass and posterior commissure, along the optic thalami, to the descending crura of the fornix, and through these to the corpora albicantia and optic commissure. The earthy matter it contains is usually but not constantly confined to the

base, or, as it is termed, acervulus ; it is composed principally of phosphate and carbonate of lime in minute crystals, similar to what is less frequently met with in the choroid plexuses.

The *optic thalami* are two large, firm, gangliform bodies, about an inch and a half long, and three quarters of an inch in depth and breadth, placed obliquely, diverging behind, converging before, behind and between the corpora striata, to which they are intimately connected, though distinguished from them superficially by the groove which contains the tænia semicircularis and lamina cornea ; the upper surface of each is smooth and free, of a greyish tint, but much whiter than that of the corpus striatum, and appears on the floor of the lateral ventricles, overlapped by the velum and fornix ; externally, it is continuous, partly with the fibres of the hemisphere, and partly with the corpus striatum, but behind this it is free and smooth also, and enters into the surface of the inferior cornu of the ventricle ; posteriorly it is connected to the quadrigeminal bodies, and to the processus a cerebello ad testes ; inferiorly it rests upon the crus cerebri ; internally it is grey, smooth, and free, except where it touches its fellow in the soft commissure, and forms the side of the third ventricle ; the white band or peduncle of the pineal body marks its superior and internal border, arching over the soft commissure ; its anterior extremity bounds the foramen commune anterius behind ; beneath its posterior free end, and above the crus cerebri, is a rounded greyish eminence, perforated with small foramina, named *corpus geniculatum internum ;* this is connected to the natis by a fibrous band ; a little lower down and more anterior is another smaller and paler eminence, named *geniculatum externum*, a fibrous band connects this to the testis ; the optic nerves are connected to these two eminences, and to the tubercula quadrigemina, and but slightly to the thalamus ; anteriorly and inferiorly the optic thalamus is connected to the descending crus of the fornix, corpus albicans and tuber cinereum ; when cut into, it presents a reddish grey colour ; numerous small, white fibres are seen passing through it, not in such large and distinctly radiating fasciculi as in the corpus striatum, but more reticulated or plexiform, as in the ganglions, the interstices being filled with grey neurine ; the superficial fibres appear to radiate into the hemisphere ; the fibres in each are continued from the olivary or the sentient tract, and from the processus a cerebello ad testem, also from the upper and posterior part of the crus cerebri, with which it is directly continuous, appearing as a ganglion swelling out from it, like the corpus striatum in front, hence it is named the *great posterior cerebral ganglion*, and has been observed to bear a ratio in size to the posterior cerebral lobes, but not to the optic nerves, which are connected to the corpora geniculata ; a section of these latter tubercles presents a distinct line between them and the thalamus ; from these the tractus opticus proceeds on each side, forwards, downwards and inwards, adhering to the thalamus, and to the crus cerebri. The thalami are regarded by some as the centres of sensation, as the corpora striata are of motion.

The *commissura mollis* is a broad, soft, and cineritious union between the internal surfaces of the thalami anterior to their centre; before this commissure is the *foramen commune anterius*, and behind it is the *foramen commune posterius;* this last-named opening is between the peduncles of the pineal gland, but is so closed by the velum and the fornix, that no communication can occur through it between the third and the two lateral ventricles, as through the anterior.

The *commissura mollis* is of a very variable extent and consistence, is composed of grey neurine, and thus differs from the general system of commissures, which are white; but is similar to the intercrural or perforated lamina between the crura cerebri, which is also probably commissural to those bodies. When the soft commissure is broken we see the following space:

The *third ventricle* is a narrow cavity placed in the median line, bounded on each side by the optic thalami, above by the velum and the fornix, below by the locus perforatus and tuber cinereum, before by the descending pillars of the fornix and the anterior commissure, behind by the posterior commissure and pineal gland, by its pedunculi and by the tubercula quadrigemina; its whole surface is coated over with grey neurine, which forms one continuous connexion between its parietes. The foramen commune anterius opens into the upper and anterior part of this cavity; the infundibulum leads from the lower, anterior, and deepest part, downwards and forwards, between the pillars of the fornix and below the anterior commissure, to the pituitary body; this canal is large above, but it is generally impervious below. From the posterior part of the third ventricle, which is much contracted in size, a small canal leads backwards and downwards, above and behind the pons Varolii, and below the tubercula quadrigemina, this is the *aqueduct of Sylvius*, or the *iter ad quartum ventriculum*. The third ventricle is but the median line of separation between the roots of the two hemispheres; this line may be considered as extending from the upper margin of the pons Varolii, and between the crura cerebri, to the convex surface of the hemispheres, and dividing the cerebrum into two symmetrical portions. It is crossed by several commissures: viz. the corpus callosum, fornix, commissura mollis, anterior and posterior commissures, middle perforated plate or intercrural lamina, and tuber cinereum; the iter ad quartum is only the continuation of the same line covered over by the tubercula quadrigemina, and upper part of the cerebellum, and accordingly during the early stages of development it is open, until the lateral boundaries meet over it in the middle line; the fifth ventricle between the laminæ of the septum lucidum, may, in like manner, be considered as part of the same median division. The two lateral ventricles, and the third or middle, now that the corpus callosum and fornix are removed, and the commissura mollis is broken, obviously present one surface covered by the vascular choroid membrane, continuous with, or an extension of the external cerebral surface; and the eminences which we have noticed upon it, namely, the corpora striata, the thalami and hippo-

campi, may be regarded as masses of grey neurine, or internal convolutions to which the white fibres are connected, as the latter are to the superficial convolutions of the hemispheres, which may be considered as one great hemispherical ganglion on each side, or as a series of ganglions connected to each other.

The *anterior commissure* is a distinct round cord, extending from one hemisphere to the other, immediately before the anterior pillars of the fornix, bent like an arch, convex anteriorly, unattached and cylindrical in its central portion, but on each side it is flattened and imbedded in the corpus striatum, through which it descends obliquely backwards and outwards, and then terminates in rays near the fissure of Sylvius, and the inferior cornu of the lateral ventricle: it is enclosed in a delicate sheath of pia mater, like a nerve; it is a true commissure between the corpora striata, and the convolutions of the middle lobes of each side.

The *posterior commissure* is shorter and smaller than the anterior, but white, round, and fibrous like it; it extends transversely behind the third ventricle, above the aqueduct of Sylvius, below the peduncoli of the pineal gland to which it is connected, and anterior to the tubercula quadrigemina; its extremities are connected to the optic thalami.

The *crura cerebri* are the last parts to notice in the dissection of the cerebrum from above downwards, and may be seen either by dividing the floor of the third ventricle and divaricating the thalami, or still better, by a little dissection on the base of the brain above the pons. They are two thick fibrous cords descending from the optic thalami and striata, about half an inch long, and converging they enter the pons, in which they are continuous with the ascending columns of the medulla oblongata; near the pons they are in contact and nearly cylindrical; as they ascend, they diverge and pass a little forwards, become enlarged and flattened, and enter the two great cerebral ganglions on each side; the optic tracts surround them externally and in front; their white fasciculi are very distinct, and blood-vessels enter foramina between these; white bands from the tubercula quadrigemina, or from some part of themselves, often cross their surface at right angles; as they diverge from the pons, they are united by the intercrural lamina, or middle perforated plate; connected to them superiorly and posteriorly are the tubercula quadrigemina; they form the lower wall of the iter a tertio ad quartum ventriculum. An oblique groove on the inner and anterior aspect of each, points out a division into two portions: one is small, anterior, and inferior to the other, and can be traced upwards into the corpus striatum, and is found to be continuous inferiorly with the anterior pyramidal tracts in the pons; the other, or larger portion, is the continuation of the olivary tracts, and can be followed into the optic thalamus. If a section of the crus be made, the surface will present, near its centre, a semilunar mass of grey neurine of a very dark shade, and, therefore, named "locus niger;" in it the neurine vesicles are found by the microscope to be of a caudate form, and intermingled

with many pigmentary particles; this appearance is confined to the crus, but does not end abruptly; beneath this mass the inferior small fasciculus of the crus is placed, and above it is the superior or larger one. The crura cerebri are said to bear a ratio in size to that of each hemisphere; the third pair of nerves is connected to their inner surface. The next division of the encephalon is the *mesocephale*, the limits of which cannot be accurately defined, as it is continuous with the crura cerebri above, with the crura cerebelli on either side, with the medulla oblongata below, and above and behind with the cerebellum itself. Many, without any impropriety, consider it and the medulla oblongata as one mass. We shall speak of them, however, distinctly, and consider the mesocephale as consisting of the tubercula quadrigemina, and of the cerebral protuberance or pons Varolii. We have already mentioned the pineal body as a portion of the cerebrum, though some connect it with the mesocephale.

Tubercula quadrigemina.—As we are pursuing the dissection from above these first are met with, forming the upper and anterior part of this division; they are situated below and behind the posterior commissure and the pineal gland; they are four round, gangliform tubercles, all connected by their bases into one mass on an oblique plain, but separated from each other superficially by two grooves, a transverse and a vertical or median; the two superior and anterior are the larger, and called the *nates*, the two inferior and posterior are smaller, and named the *testes*. They all lie above and behind the crura cerebri and the olivary tracts, which ascend from the medulla oblongata, through the pons and crura, to the optic thalami; they are also above the aqueduct of Sylvius, which separates them from the pons Varolii. The nates are connected to the optic thalami; the testes to the cerebellum, by two thin white plates, which descend obliquely backwards and outwards, and end in the substance of the cerebellum; these are the *processus a cerebello ad testes;* they diverge towards the cerebellum, and are continuous externally and inferiorly with a thick, round, white chord, the crus cerebelli. Between the two processus a cerebello there is a thin lamina extended, named the *valve of Vieussens*, or of the *fourth ventricle;* triangular, the apex is between the testes, the base is attached to the cerebellum, and the sides to the two processes just described; this valve forms the roof of the fourth ventricle, it is overlapped by the superior vermiform process, and is very delicate, being composed of a white lamina, with a thin stratum of grey neurine, which is marked with transverse indentations and eminences like the laminæ of the cerebellum, of which it is evidently a continuation; and, therefore, this valve or process is rather a portion of this organ than of the mesocephale. The fourth pair of nerves are seen to arise from it, and from the lateral processes, by one or two fine filaments. If a probe be passed along the aqueduct of Sylvius, and the valve of Vieussens divided, the cavity of the *fourth ventricle* will be exposed. The four tubercles are covered by a very vascular membrane from the velum, from which numerous vessels are seen to pass into their substance;

they are white on the surface, but the nates are of a greyer tint than the testes; when divided, the section resembles that of the thalami, and presents white fibres intermingled with grey neurine, like other ganglionic bodies. In fish, reptiles, and birds, there are only two tubercles corresponding to these four, and are decidedly the optic lobes; in birds they are very large; in mammalia we find the four eminences; the nates are large in the herbivoræ, and the testes in the carnivoræ, and are all better developed than in man. The next and principal portion of the mesocephale is the following:

The *pons Varolii*, or *great commissure of the cerebellum*, or cerebral protuberance, can be better examined when the brain is removed from the subject, and the base placed uppermost. It is somewhat square, is placed obliquely on the cuneiform process, between the cerebrum and cerebellum; the fourth ventricle, the aqueduct of Sylvius, and the tubercula quadrigemina, are on its superior and posterior surface; its inferior and anterior surface rests on the bone, and is grooved longitudinally by the basilar artery, numerous branches from which enter its structure between the transverse fasciculi. Its superior extremity receives the crura cerebri, which it surrounds like a ring, hence it is sometimes called the annular protuberance; the crura cerebelli are attached to its sides, and the medulla oblongata to its lower extremity, from which it is distinguished by a deep groove. The pons is of a more firm structure than any part of the brain; its surface is white and fibrous; the superficial layer of fibres on its inferior surface runs transversely from the inferior surface of one crus cerebelli to the other, hence this lamina has been very properly named the commissure of the cerebellum. These fasciculi are large and coarse, with intervals between them for the entrance of vessels; they are more separate towards the centre than at either side, where they are compressed; hence the pons appears deeper in the former than in the latter situations. In the median groove the fibres are condensed, and some are found to pass inwards and interlace with those in the interior; these superficial fasciculi can be raised off in layers, and grey neurine is intermingled with the deeper fibres; they constitute about one-third of the thickness of the organ, and are always found to bear a ratio in size to that of the hemispheres of the cerebellum, as may be proved by inspecting it in birds, reptiles, and fish, where these portions are absent, or only rudimental, and these transverse fasciculi are nearly absent also. Beneath these transverse fibres a quantity of cineritious substance exists, through which white fibres may be seen to ascend obliquely outwards, in the direction of the crura cerebri; these are the tracts from the medulla oblongata and spinal cord, named the pyramidal columns; they ascend on either side of the median depression, and contribute to the lateral convexities on the surface; these fibres are separated by and intermingled with grey neurine, and interlace at right angles with the white, transverse, commissural fasciculi; they enter each crus cerebri, hence the pons Varolii is described by some authors as a portion of the medulla oblongata; it is, however, so connected with it, as well as

with the cerebrum and cerebellum, that it may be considered as equally common to all, and is truly a compound body, its inferior or anterior portion being commissural to the cerebellum, and the remainder a ganglionic mass receiving and transmitting the ascending nervous columns to the crura cerebri.

SECTION III.

DISSECTION OF THE CEREBELLUM, OR LESSER BRAIN.

REMOVE the posterior lobes of the cerebrum, divide the tentorium, and the cerebellum will be exposed. This organ, like the cerebrum, is larger in man than in any other animal, and is believed by many to be larger in proportion in the male than in the female. In size and weight it bears a ratio to the cerebrum of about one to eight, the average weight of the latter being two pounds and a half, and that of the cerebellum four ounces and a half. It is securely lodged in the inferior occipital fossæ, and is covered by the tense tentorium, which supports above it the weight of the posterior cerebral lobes; it is above and behind the medulla oblongata and the mesocephale. In form it contrasts with that of the cerebrum, being oval in the transverse direction, and raised in the centre, where, contrary to the cerebrum, its right and left hemispheres are united. It is composed, like the cerebrum, of white substance internally, and of grey upon its surface, but the latter is marked by a great number of narrow parallel lines, which run semicircularly, convex posteriorly; these are fissures to the bottom of which the pia mater descends, the arachnoid membrane passing over them. They are in some measure analogous to the sulci on the cerebrum, that is, they are involutions of the grey substance, the superficial extent of which is thus considerably augmented; the same appearance is also observable inferiorly, but the lines there are not so numerous or regular as above; some lines pass in very deep into the cerebellum, and divide it into lobes, and are called *primary;* others are only superficial, and divide it into lobules, and are called *secondary.* The deep lines or sulci, unlike those on the cerebrum, are closed below by white substance, and, therefore, the grey neurine does not form one continuous surface over the cerebellum as it does over the cerebrum. The cerebellum presents for our observation two surfaces, superior and inferior, a convex border or circumference, which separates these from each other, and a median notch behind and before. The *posterior notch* is very deep; it receives the falx cerebelli and the inferior occipital crest, and extends mesially along the under surface as far as the back of the medulla oblongata; this extension is very deep, and is called the *valley, or purse-like fissure.* The *anterior notch* is broad, overlaps the fourth ventricle, and embraces the cere-

bral protuberance and tubercula quadrigemina. These two median notches mark a division of the cerebellum into right and left hemispheres; the circumference of each of these is deeply indented by the *horizontal fissure;* this penetrates to a great depth, is lined by pia mater, and is bounded below by white substance; this fissure extends on each side as far forwards as the side of the pons, parallel to each petrous bone; posteriorly it leads into the valley; it forms the bounding line between the upper and lower surfaces. The white neurine of its floor will be seen hereafter to be continued into the fibrous band, called crus cerebelli.

The *upper surface of the cerebellum* presents on either side an inclined plane, marked by concentric lines and laminæ, and in the middle line a ridge or process, very prominent in front, where it overlaps the valve of Vieussens and the quadrigeminal mass; this is named the superior vermiform process, or the middle superior lobe. The *inferior surface* of the cerebellum is very convex on each side, but deeply depressed by the valley in the median line; the sides of this space are held together by the arachnoid membrane tensely extended from one to the other; when this is divided, and the space expanded, it has somewhat a lozenge form, and is occupied by a portion of cerebellum, which is laminated, and shaped into different small masses by fissures and plaits; this is the inferior vermiform process, but it may be seen that this is continuous with the lower part of the superior vermiform process.

These two processes, which have received these distinct names, improperly, but now sanctioned by long practice, are really but one, and ought to be named the median lobe, or the primitive lobe of the cerebellum. Comparative anatomy justifies this remark: in fish and reptiles this median lobe alone exists; in birds, the lateral portions first appear as small offsets; but in mammalia these enlarge in a greater ratio than the central or fundamental portion. The cerebellum, therefore, is divisible, first, into two lateral hemispheres, and the middle or primitive lobe; this division is marked by the anterior and posterior notches, by the prominence of the median lobe above, and by the valley or great median longitudinal fissure below; and, secondly, into a superior and inferior surface, the distinction between which is evident from their different aspects and from the deep horizontal fissure in the circumference, which on each side connects the anterior and posterior notch.

The *right and left hemispheres* may be considered symmetrical, though a difference in size has been more frequently remarked than between the cerebral hemispheres. Each presents on its superior surface the lines or sulci, and laminæ, already noticed, forming large curves, concave forwards, parallel, and concentric; most of those of one side are continuous with those of the other, through the superior vermiform process, in which, however, their direction is altered, being convex forwards. When the pia mater is detached, the sulci can be opened, and the distinction between the primary and secondary lines becomes

obvious; one deep or primary sulcus marks two lobes on the upper surface of each hemisphere, one posterior, the other anterior.

The *superior posterior lobe* is semilunar, extends to the convex border, is separated by the horizontal groove from the inferior posterior lobe, and by the posterior median notch from its fellow, to which, however, it is connected by transverse lines, which cross and bound the floor of that fissure.

The *superior anterior lobe* is an irregular square, it extends as far forwards as the anterior notch, is distinguished from its fellow and connected to it by the several transverse laminæ of the superior vermiform process. Both these superior lobes consist of numerous lobules, and these again of smaller laminæ or leaflets, distinguished by the secondary lines, and placed in close apposition, like the leaves of a book. Each lobule and lamella consists of a delicate white centre, which, like a root or stalk, adheres to the white central nucleus of the hemisphere, and is covered on its convex edge and its two lateral surfaces by grey or vesicular neurine and by pia mater. When the section of the cerebellum shall have been made, as will be directed presently, this structure of the lobes, lobules, and laminæ, or leaflets, will be more distinctly displayed; but even in the present stage of the dissection it may be partially exposed by opening the deep sulcus, and scraping off some of the grey coating from the lamellæ between the secondary fissures.

The *inferior surface* of each hemisphere is very convex, and also marked by concentric sulci, primary and secondary; the primary lines mark out five lobes on each, viz., the posterior or semilunar, the middle or gracilis, the anterior or digastric, the anterior or internal, or the amygdaloid or tonsillitic, and the anterior inferior, or the floculus or pneumogastric lobe or tuft.

The *inferior posterior lobe* is semilunar, extends to the convex border below the horizontal groove, and is separated from its fellow by the posterior inferior median fissure, though connected to it by the transverse laminæ on its floor.

The *gracilis* or *middle lobe* is placed transversely between the last and the following.

The *digastric lobe* is a large mass, extends to the anterior and external border of the hemisphere, narrow internally, wide and bifid externally; the inner extremities both of this and of the thin lobe are connected to those of the opposite side across the valley by transverse laminæ, which project into a process called the pyramid, from the inferior median lobe or vermiform process.

The *amygdaloid*, or *almond-shaped*, or *tonsillitic lobe*, is anterior and internal to the last, is overlapped by the medulla oblongata, and projects into the posterior and lateral part of the fourth ventricle; these two lobes bound the sides of the valley anteriorly, and are connected to each other by the transverse laminæ of a lobule of the inferior vermiform process, called the spigot or the uvula.

The *flocculus*, or *pneumogastric lobe*, is situated anterior to and

distinct from the hemisphere, by the side of the valley, and is connected by a delicate white stalk to the crus cerebelli. Close to and behind the par vagum, and below the facial and auditory nerves, it is marked with many transverse striæ, and can be detached all around except at its root. It is connected to its fellow by the *inferior* or *posterior medullary velum* (so called in contradistinction to the valve of Vieussens, or superior medullary velum); this is an exquisitely delicate membrane, composed of transverse fibres of white neurine, of a semilunar form, not unlike that of one of the venous or arterial valves; its convex edge is attached to the crus cerebelli, just below the origin of the valve of Vieussens; its concave edge is loose in the fourth ventricle, which cavity it assists in closing inferiorly; it extends to the flocculus lobe externally, thence it leads backwards, inwards, and downwards, in front of the pointed extremity or lobulus of the inferior vermiform process, which is called the nodulus; it passes in front of this, adhering to it behind the ventricle, and is continuous with the velum of the opposite side. This fine and semi-transparent nervous membrane is a sort of commissure between the two flock lobes and between each of these and the nodulus in the centre. If the fourth ventricle be opened either from above, or, what is better, by a vertical section through the middle lobe of the cerebellum, the nodule, of its dark red colour and with transverse striæ, will be seen at the bottom of the cavity projecting upwards and forwards into it; also on either side are two small vascular folds or choroid plexuses. If we gently push these to one side, we obtain a view of this inferior medullary velum, loose and floating; it can be placed on any black substance, or the handle of the knife, and presents a beautiful example of white nervous membrane, semi-opaque like the retina, and, though not so strong, very similar to the valve of Vieussens. These two semilunar folds, with the nodule in the centre and the amygdalæ at the side, bear some resemblance in form to the velum and uvula palati.

The *middle lobe of the cerebellum* presents a superior and inferior surface, which are named the superior and inferior vermiform process or lobe. Some consider this portion of the cerebellum as a commissure between the right and left hemispheres, analogous to the corpus callosum in the cerebrum; I would rather view it as the primitive or fundamental element of the whole organ, and the hemispheres as lateral additions to or expansions from it, and that the true commissural fibres in the cerebellum are, first, the arched fibres, forming the anterior layer of the pons, analogous to the great cerebral commissure; second, the processes a cerebello ad testes, with the valve of Vieussens, or superior medullary velum; and, third, the inferior medullary velum. The first is the analogue of the corpus callosum, the second and third of the anterior and posterior commissures, while the second may also serve as an intercerebral commissure between the cerebellum and cerebrum. The *superior median lobe*, or vermiform process, extends from the anterior to the posterior notch, is very prominent before, but bevelled off behind nearly on a level with the hemispheres. The anterior

eminence overlaps the valve of Vieussens, and is in contact with the quadrigeminal mass. It is marked by transverse lines, continuous with but fewer in number than those of the anterior square lobes on either side. These lines and laminæ appear longer than the space they have to cross, and, being bent in a tortuous manner, have been likened unto the segments of the annulosa, and hence the name of vermiform process. They seem to be curved or drawn forward, and are concave posteriorly, and this may account for the prominence in front. The laminæ of the posterior or semilunar lateral lobes meet behind this process in the transverse bands at the bottom of the posterior notch, and which some consider as the posterior commissure of the cerebellum. This superior lobe consists of a white stem, continuous with the central nucleus of the cerebellum; this branches out into numerous fine lines, one for each lamina, in which it is covered by the grey neurine.

The *inferior median lobe*, or *vermiform process*, is deeply sunk in the valley. At first view the latter would appear to separate completely the two hemispheres, but, when it has been expanded, we shall perceive that the laminæ of opposite sides are continuous through the transverse but tortuous lines on this lobe in the same manner as above. This lobe appears much compressed in the valley, and pushed downwards and forwards against the medulla oblongata, so as to enclose the space between both, named fourth ventricle. When fully exposed, it presents a cruciform shape, one point is superior and posterior in the posterior notch; the opposite or the anterior inferior one is in the ventricle, and its lateral broader extremities are connected with the inferior lobes of the hemispheres; the entire is marked by tortuous, transverse lines; the anterior are convex forwards and concave behind, and the posterior are concave forwards and convex behind. The posterior part of this lobe is in the posterior notch, and is continuous with the superior median lobe and with the posterior semilunar lobes of each side. In front of this it presents a series of prominences or lobules, one before the other: the first or most posterior is named the *pyramid*, thick and prominent, pointed downwards and backwards, marked by several curved transverse lines, which are continuous with those of the gracilis and digastric lobes of either side. Anterior to this is the second lobule, named the *uvula* or *spigot*, pointed downwards and forwards; it assists in forming the back of the ventricle, between the tonsillitic lobes, with whose laminæ it is continuous. Anterior to this is the *nodulus*, the terminating point of the inferior median lobe; it is a pointed, furrowed lobule, extending into the ventricle, and closing it inferiorly; it is connected to the flock lobes by the inferior medullary velum, which extends in front of it; on either side it pushes into the cavity a small fold of pia mater, called the choroid plexuses of the fourth ventricle; these are frequently studded with small cerebral granulations or corpora Pacchioni, and with fine calcareous particles.

The cerebellum then presents the following divisions and subdivisions: first, it is divided into three parts, viz., right and left hemisphere and middle or primary portion; second, each of these is subdi-

vided by the horizontal groove into superior and inferior; third, the upper surface of each hemisphere presents two lobes, the anterior or square, the posterior or semilunar; the two former are connected by the tortuous, transverse laminæ of the superior vermiform process, and the two posterior by those forming the floor of the posterior notch; fourth, the median portion presents the single or azygos superior median lobe or vermiform process; fifth, the inferior surface of each hemisphere presents five lobes: most anterior and distinct from the hemisphere is 1, the flocculus or pneumogastric lobule, connected to its fellow and to the nodule by the inferior medullary velum; 2, the tonsillitic lobe or amygdala, on the side of the ventricle, and connected to the opposite through the uvula or spigot; 3, the digastric; 4, the gracilis; both of these are continuous with the opposite through the pyramid; 5, the semilunar, which is joined to its fellow by the convex transverse laminæ at the bottom of the posterior notch. The inferior median lobe, or vermiform process, presents from before backwards three lobules: the nodule, most anterior; next is the uvula or spigot; and most posterior is the pyramid. The valley, with the posterior notch leading into it, has been named by some the purse-like fissure; and the fossa behind the inferior velum, and in front of the nodule and uvula, has received the fanciful title of "nidus hirundinis."

The *fourth ventricle* is usually described in connexion with the cerebellum, though in reality it does not properly belong to it; it is rather a space between it and the back of the medulla oblongata, closed in by the apposition and approximation of the surrounding parts, which gradually takes place through the successive stages of development and growth; it is situated between the pons and medulla oblongata in front, and the median lobe of the cerebellum behind, and its hemispheres on either side; it may be opened into from above by dividing the velum or valve of Vieussens, or more fully displayed by a vertical section through the median lobe, or it may be examined from below without any injury to the surrounding organ by merely dividing the arachnoid as it passes from the cerebellum to the posterior surface of the spinal cord, and raising the nodule and uvula, and divaricating the tonsillitic lobes. When fully displayed it appears an extensive space, about an inch and a half in length, and nearly the same in breadth in its widest portion; it is of a lozenge or diamond form, being much expanded laterally about its centre; this figure, however, is only well seen on its anterior wall; the superior point or angle is in the iter or aqueduct of Sylvius; the inferior point is between the posterior columns of the spinal cord, or the commencements of the corpora restiformia; this point or groove is closed by membrane, but is really the continuation of the posterior median fissure of the cord; the lateral points or angles are much elongated, and extend into a depression in the cerebellum, which will be found, when a vertical section of either hemisphere has been made, to correspond to the internal point of the corpus dentatum, or the cerebellar ganglion; the whole chamber is curved, convex upwards and backwards; its anterior wall, which is also infe-

rior, is the posterior surface of the medulla oblongata and of the pons, the ascending columns of the former causing lateral projections or convexities in the latter; between these is a median groove, sharp and very distinct; this is the posterior median fissure of the spinal cord, which is continued upwards through the iter or aqueduct of Sylvius, then through the third and fifth ventricles, and becomes the great fissure between the cerebral hemispheres; this groove being closed below into a narrow point, has been resembled to a writing pen, and is named *calamus scriptorius;* on either side of it, in its lower half, white striæ are visible through a thin coating of grey matter, these are the origins of the portio mollis nerve; the posterior wall is arched, and is formed from above downwards by, first, the valve of Vieussens, and the processus a cerebello ad testes; second, by the median lobe of the cerebellum; third, by the uvula and nodulus, and partly by the tonsils, which rather lie on either side; and lastly, by the inferior medullary velum, which extends on either side from the nodule to the flocks; inferiorly it is closed, partly by the apposition of the nodule and velum, and choroid plexus, to the back part of the medulla oblongata, partly by the lining membrane of the cavity, and externally by the tense and constricted arachnoid, beneath which is the pia mater, which in this situation, after having sent inwards its choroid processes, assumes much of a fibrous character, and adheres closely round the top of the spinal cord, so that no communication normally exists between the ventricles and the spinal sub-arachnoid space; the sides of the ventricle are but the lines of junction between the anterior and posterior walls, and are formed by the white central nuclei of the hemispheres; the interior is lined by an exquisitely delicate membrane, which can be demonstrated by carefully scraping off the valve of Vieussens. The greater portion of the cavity is coated over with grey neurine like the third ventricle, and a larger quantity of this exists about the striæ, on each side of the calamus, and is probably ganglionic to the auditory nerves

Although the surface of the cerebellum is wholly cineritious, except at the bottom of the horizontal and of the primary sulci, yet internally it consists of one mass of white substance, continuous from one hemisphere to the other, but more abundant in the lateral regions than in the middle; if the whole of the upper surface be sliced horizontally, as in the dissection of the cerebrum, we shall soon expose this central white nucleus, surrounded by a laminated line, broken and interrupted, and very unlike the undulating border around the cerebral centrum ovale. Such a section, however, gives no correct notion of the course of the white fibres to the laminated cineritious coating; to acquire this, make two vertical sections, one through the median lobe and directly in the middle line, and one through either hemisphere, carrying it obliquely through from before backwards and outwards; it may be made through its axis, but in order to expose one peculiar substance, called the corpus dentatum, it is better to make this oblique vertical section in the line of union of the internal, and of the middle thirds, so that two-thirds of the hemisphere will be to the

outer side. The surfaces of the vertical section of the middle lobe present a very beautiful and delicate arborescent appearance, which has received the name of the *middle arbor vitæ*, a white central stem dividing into numerous fibrils which are distributed to the lobules, and laminæ, corresponding to the lines upon the surface; the section of either hemisphere presents the same beautiful and elaborate appearance, but on a larger scale; the central white trunk of this *lateral arbor vitæ* is short and thick, and sends off large branches to the primary lobes, each of these subdivides again and again into smaller twigs, which like leaf-stalks enter each a separate lamella, and are all coated over on their extremities and sides by grey neurine and vascular membrane. Such a section exhibits, not only the quantity, but also the wonderful superficial extent of the grey matter; also, how it covers three sides of every lamina, and lines every sulcus. If the incision through the hemisphere have been made as directed, there will be seen in the inner third of the central white nucleus in each hemisphere, and nearer the upper than the lower surface, a small, yellowish substance, named the corpus rhomboideum, or *dentatum*, or the ganglion of the cerebellum; it is the colour of box-wood, and is surrounded by many blood-vessels; it is composed of a capsule of grey neurine, curiously involuted, or folded and plaited in and out, not unlike the convoluted surface of the cerebrum; the capsule is filled with white fibres, plexiform, and intermingled with grey matter prolonged from its surface; the capsule is convex posteriorly, but is open inferiorly and anteriorly, and the greater portion of the corpus restiforme enters it; the course of the fibres is then altered, they become confused and intermingled with the grey matter, and from all other points of the capsule the white fibres mingle in the central stem. The central white nucleus of the cerebellum is connected to the medulla oblongata, mesocephale, and cerebrum by three processes or peduncles on each side: one is the superior peduncle, or processus a cerebello ad testem; the second is the anterior peduncle, or the crus cerebelli; and the third is the inferior peduncle, or corpus restiforme, or processus a medulla oblongata ad cerebellum.

The *processes a cerebello ad testes*, are two thick, white, fibrous bands commencing in the central white nucleus of each hemisphere of the cerebellum; thence they ascend obliquely inwards, attached to and above the crus cerebelli, they join the testes, also the optic thalami, and the olivary tracts, passing through these; the valve of Vieussens, or the superior medullary velum, extends from one process to the other, is of a triangular form, the base is continuous with the white central nucleus of the middle lobe, its apex is attached to the angle between the testes, a narrow transverse band crosses and strengthens the attachment; the valve of Vieussens, and the process on either side may be considered as commissures, not only between the two hemispheres and the median lobe, but also between the cerebellum and cerebrum, and might be named the intercerebral or cerebro-cerebellar commissure.

The second or anterior peduncle of each side is the *crus cerebelli;* this is a thick cord, larger than either of the other peduncles, it commences in the floor of the horizontal groove, passes forwards and inwards, and is continuous with that of the opposite side in the anterior layer of the pons or mesocephale; the two crura by this junction form what has been named the great commissure of the cerebellum.

The third or inferior peduncle is the *corpus restiforme*, which is continued from the posterior column of the medulla oblongata, to the cerebellum; these three peduncles are all combined in the central nucleus, from which the several branches proceed to the different lobes and lobules; these three constituents of each crus cerebelli must establish intimate relations between the cerebellum and the spinal cord, the medulla oblongata, the quadrigeminal mass, and the optic thalami, and, through the latter, the cerebral hemisphere. As to the mode of connexion between the white fibres and the grey matter nothing more is known than in the cerebrum; the grey substance is of a darker hue, and apparently more vascular, than in the cerebrum; a section of it presents different shades, the external layer is the darkest, the middle the lightest, and the internal, of a median colour, the thickest. The next and last division of the encephalon is the following.

SECTION IV.

DISSECTION OF THE MEDULLA OBLONGATA.

THE *medulla oblongata*, or *spinal bulb*, is that conical portion of white substance which extends from the lower margin of the pons to the spinal cord, on a level with the ring of the atlas; its upper end or base, though apparently limited by the pons, is prolonged upwards through it to the crus cerebri of each side; inferiorly, there is no distinction between it and the spinal cord, posteriorly or laterally; but anteriorly, some decussating fibres have been fixed on, perhaps rather arbitrarily, as the bounding line; it is flattened before, and more so behind, it is round or convex upon the sides, is placed obliquely and a little curved, the base being anterior and superior, the apex inferior and posterior, it corresponds to the basilar process, the foramen magnum, and atlanto-occipital ligaments, and is embraced and partially concealed posteriorly and laterally by the anterior notch, and by the inferior median and lateral lobes of the cerebellum; the latter must be removed or held aside to expose its posterior surface; anteriorly no dissection is necessary except the careful removal of the loose arachnoid, and of the closely adhering pia mater: it presents an anterior and posterior me-

dian fissure which divides it into two symmetrical portions, each of which is marked by three grooves and four convex eminences, viz., the anterior pyramids; on either side of these are the olivary bodies; still more laterally and posteriorly are the restiform bodies; and the posterior pyramids are on either side of the posterior fissure. The *posterior fissure* is continuous with that of the spinal cord below, and with the calamus scriptorius above; it is narrow, and sinks in deep to the anterior commissural fibres; the pia mater lines it. The *anterior fissure*, the continuation of the spinal, is broader, but not so deep, and is closed by transverse, cribriform, commissural fibres; nearly an inch below the pons this fissure is interrupted by those remarkable fibres called the *decussating fasciculi;* to see these, remove the pia mater, and gently separate the pyramids; they consist of three or four fasciculi which ascend obliquely inwards from the lower end of each pyramid to the opposite one, interlacing or indigitating with each other; this apparently trifling anatomical fact is of much physiological and practical interest, as it serves to explain the frequently observed phenomenon of injury or disease, in one side of the brain, being attended with loss of nervous power of some portion of the opposite side of the body; it should be observed too, that as the whole of the pyramids do not decussate, we can thus account for exceptions to this statement.

The *anterior pyramids* are two narrow, convex, white bands, about an inch long, small inferiorly, in contact and partially united by the decussating fasciculi. Each arises narrow and rather abruptly at the seat of decussation, by two sets of fibres, one from the inner side of the opposite anterior column of the spinal cord, the other from that of its own side; as they ascend they become convex and prominent in the centre, and a little divergent, round, and constricted by the pons at their upper end, and separated by a central depression in the median fissure, called foramen cæcum; through the pons they can be traced upwards, intermingling with its grey neurine, and crossing its white at right angles, into each corresponding crus cerebri. The anterior pyramids appear to be the direct, as well as crossed medium of connexion between the anterior fibres of the cord, the mesocephale, crura cerebri, corpora striata, and cerebral hemispheres, and partly also with the optic thalami.

The *corpora olivaria*, or *olive-shaped bodies*, are smaller and shorter than the pyramids, are external and a little posterior to them, and separated by a groove both from them and the restiform; they only exist in man and quadrumana; they are white and fibrous on the surface, but when divided they present a mass of grey neurine, called *olivary ganglion* or *corpus dentatum;* the latter name is from its resemblance to the so-called substance in each hemisphere of the cerebellum; it is an oval capsule of grey neurine, plaited or convolnted all around, except on its inner side, where it is open and continuous with the central grey neurine of the medulla oblongata; it is not perfectly insulated either above or below, but is continuous with the grey

matter of the pons, and with that of the medulla spinalis; the fibres of these bodies are named the olivary tracts, and, though apparently insulated, yet are continuous with the central portion of the medulla oblongata, and united with each other, as may be seen if the pyramids be dissected out and removed, the olivary tracts will then be found to ascend beneath or behind these bodies, and may be traced upwards through the pons, to the posterior part of the crura cerebri, and then to the optic thalami and tubercula quadrigemina; in this course they form a projection posteriorly on the floor of the fourth ventricle, on each side of the calamus scriptorius, and present a grey surface from which the auditory nerves arise. Beneath, and partly enclosing each olive are some curved fibres, concave upwards, termed *arciform;* they are very variable in number and size; they appear to arise from the pyramid, then pass round the olive, and are lost upon the restiform body, sometimes they are expanded over a great portion of each olivary body, and in some cases are highly developed, and would appear like some of the lower transverse fibres of the pons drawn downwards; they are probably commissural between the three eminences to which they are connected.

Corpora restiformia, or the *ropes*, or *inferior peduncles of the cerebellum.* These are two thick, longitudinal, white cords, on each lateral and posterior aspect of the medulla, separated from the olives by a groove in which the roots of the eighth pair of nerves are lodged, and from each other by the posterior median fissure of the cord inferiorly, and by the fourth ventricle superiorly, which space they in some measure form by their divergence; they are best seen from behind, the inferior median lobe of the cerebellum having been removed; each is perfectly continuous inferiorly with the posterior and antero-lateral columns of the cord; as they ascend they diverge, and thus increase the breadth of the medulla, and, bending a little backwards, enter the hemisphere of the cerebellum, and join the inner surface of its crus at the lateral angle of the ventricle, and just below the ganglion dentatum, which they enter; they are crossed by the choroid plexus, the auditory nerve, and the pneumogastric lobule: their outer margin is a little concave: their inner margins are separated by the calamus, the olivary column, and the posterior pyramids; superiorly each is entirely expended in the cerebellum, inferiorly its fibres descend in two fasciculi, one to the posterior, the other to the antero-lateral column of the cord; the continued line of the posterior spinal nerves separate these tracts; each restiform body connects the spinal cord and medulla oblongata to the cerebellum.

Posterior pyramids are two long, narrow columns, which extend on each side of the posterior fissure of the cord to its lower extremity; they are seen on each side of the calamus scriptorius in the lower part of the ventricle, and terminate abruptly; by their deep surface they appear continuous with the posterior part of the olivary tracts.

The medulla oblongata would appear to be a very important seg-

ment of the cerebro-spinal axis, it is in itself a sort of ganglionic centre communicating with all other parts; several nerves also are connected to it; the ninth pair arise between the olives and anterior pyramids; the eighth between the olives and the ropes; the auditory by the side of the calamus from the olivary columns; the sixth between the anterior pyramids and the pons; and the roots of the fifth also can be traced into the olivary tracts. The last division of the nervous centre is the spinal cord; this we may now examine, and then from it return to the encephalon, and unravel its structure from below upwards.

CHAPTER II.

DISSECTION OF THE MEDULLA SPINALIS, OR SPINAL CORD.

SECTION I.

DISSECTION OF THE MEMBRANES OF THE SPINAL CORD.

THE spinal cord is enclosed or rather suspended in a cavity or canal much larger than itself, bounded by the bodies and processes of the vertebræ, and by their connecting ligaments; this organ, like the brain, is surrounded by three membranes, which are continuous with those in the cranium. Place the subject on the forepart, remove the soft parts covering the spine, and with the saw divide the crura of the spinous processes of all the vertebræ close to their articulating processes; then with the elevator raise the posterior arch of the spinal canal; a quantity of soft adipose and loose reddish cellular tissue, not unlike the marrow in long bones, and numerous venous plexuses intervene between the bones and the dura mater, which membrane is loosely connected to them, and cannot therefore serve the office of periosteum as in the cranium, but is closely attached anteriorly to the posterior ligament of the bodies of the vertebræ.

The *spinal dura mater* is termed the theca vertebralis; it is continued from the cranium through the foramen magnum, as a tubular process, down the spinal canal, as far as the sacrum, where it divides into several processes, which are continued on the sacral nerves; superiorly it adheres to the foramen magnum, and to the occipito-vertebral ligaments, inferiorly a delicate fibrous band connects it to the sacrum and coccyx; the sacral canal is chiefly occupied by the fatty matter before alluded to; its external surface is smooth and shining; throughout this extent it regularly sends off a tubular process along each of the spinal nerves, but when opened, it will be seen that each nerve escapes by two foramina, or small vertical slits, only separated by a narrow fibrous slip. The theca vertebralis is larger and longer than the cord it encloses, and is very loose below, where fluid is generally collected; it is dilated in the cervical and lower dorsal regions, and contracted in the middle dorsal, thus conforming to the shape of the cord; it is fixed and re-

tained in a certain state of tension, by its attachment to the vertebral ligaments in front, to the foramen magnum above, to the sacrum below, and on either side by the sheaths which are prolonged on the nerves, and which are gradually lost externally; it is not exactly in the centre of the canal, but is nearer to the bodies of the vertebræ than to the posterior arches, therefore nearer the axis or centre of motion of the column. Its arteries are derived from the occipital, deep cervical, vertebral, intercostal, lumbar, and sacral; its veins partly accompany these through the intervertebral foramina, and partly join the two *long vertebral sinuses;* these extend from the occiput to the sacrum, are placed on the lateral and back part of the bodies, and parallel, covered by the thin external margin of the anterior ligament, subject to alternate enlargements and contractions, and communicating regularly with each other by the *transverse branches* or *sinuses*, which lie between the ligament and the body of each vertebra; these transverse sinuses are dilated in the centre, they may be seen very distinctly in the cervical and dorsal regions; they cover the foramen or the fossa in the bone, and each receives from it two or three branches which traverse the spongy texture of the bodies of the vertebræ, and which are very similar to the diploic veins in the cranium; these have been named the *basi-vertebral veins* by Breschet. Each of these longitudinal sinuses in the vertebral canal bears an analogy to the inferior petrosal and cavernous sinuses in the cranium; and the transverse in the former, to the circular and transverse occipital in the latter; the longitudinal inosculate superiorly with each lateral sinus near its termination, and through their whole extent with the external spinal veins, through the intervertebral and sacral foramina. With the scissors divide this membrane along its whole length; its internal surface is smooth and lined by the reflected layer of the arachnoid or serous membrane; on expanding its sides, we see the spinal nerves on each side passing through it by the double row of holes, also the series of pointed or tooth-like processes of the ligamenta dentata inserted into it laterally between each pair in the neck and back, also, the semilunar fold of the arachnoid passing from one to the other, so as to form one continuous festooned border on each side from the occipital foramen to the commencement of the cauda equina.

The *arachnoid* or the *serous membrane* in this region has a corresponding appearance to that in the cranium, with which it is continuous; it is, however, rather stronger, at least in some situations, and is more loosely connected to the pia mater, so that air or any fine fluid may be impelled between them; a quantity of serous fluid is also at all times interposed, and occupies this extensive sub-arachnoid space; so that either the arachnoid membrane must possess two exhalent and absorbent surfaces, or, as is most probable, this sub-arachnoid fluid must be derived from the pia mater or from the connecting sub-arachnoid cellular tissue. The parietal lamina adheres intimately to the dura mater, and is continuous with the visceral layer at the exit of

every spinal nerve, and at the point of attachment of the ligamentum dentatum; as each nerve escapes, the membrane which accompanies it from the cord forms a small *cul de sac* at the orifice in the theca, and is then continued on the latter; inferiorly it extends to the cauda equina, ends in a *cul de sac*, or rather in several small ones on the nerves; in this situation it is very fine, and among the lower nerves it often appears as thin and transparent as soap bubbles. The interval between its two laminæ is the arachnoid cavity; this is a confined space, and the opposed surfaces are often in contact, and even agglutinated; we seldom find any fluid in it if the body be recently dead. Beneath the visceral lamina is the sub-arachnoid cavity or space, this always contains some fluid, and, if examined immediately after death, or if the canal be opened in a living animal, and the membranes punctured, it flows out in a clear stream, and at first with a jet; this space contains a cellulo-filamentous tissue, in which the fluid is entangled, attached to the pia mater and arachnoid, more dense in the median line posteriorly, where it forms a sort of imperfect or pectiniform septum; this is most distinct in the dorsal region; the cellulo-fibrous tissue is most abundant in the cervical region, there is little or none inferiorly, and there the arachnoid can be detached with great ease; this space also contains the *ligamentum denticulatum* of either side; this delicate and elaborate structure is a narrow, membrano-fibrous band extending along each side of the whole spinal cord; its superior pointed extremity is attached to the dura mater at the foramen magnum, in front of the posterior root of the suboccipital nerve, and of the spinal accessory, and behind the vertebral artery and lingual nerve; it has a glistening appearance, and appears composed of a white fibrous band, which becomes enveloped by the arachnoid; each tooth-like process also contains a fibrous thread which is inserted into the dura mater; in the cervical region it often presents a yellowish appearance, like elastic tissue; its internal edge is straight, and connected to the pia mater along the side of the spinal cord in the space between the anterior and posterior roots of the nerves; its external edge is serrated and attached by several pointed processes, about twenty-two in number, to the internal surface of the dura mater, near the foramina for the passage of the nerves, and nearer the lower than the upper; the intervals between these processes increase as we descend; inferiorly it ends in a fine filament which joins the filiform termination of the pia mater, and is inserted into the dura mater, covering the sacrum and coccyx. The ligamentum denticulatum serves to separate the roots of the spinal nerves, also to connect or fix the spinal cord laterally, and so guard it against lateral concussion or displacement.

The sub-arachnoid fluid answers the same purposes as in the cranium; it supports and bathes the roots of the nerves and the blood-vessels, fills up all inequalities on the surface, and sustains the visceral arachnoid lamina in contact with the parietal, and thus keeps the theca distended, and maintains a gentle and a yielding pressure over the

whole organ; and, at the same time, by separating it from immediate contact with the parietes, effectually guards it against concussion or vibration in the ordinary motions of the body.

The *pia mater* in the spinal canal is more dense and fibrous, but less vascular, than in the cranium. It adheres so closely to the spinal cord as to appear to compress it, which is evident when the cord is cut across, or if pricked with a point, the neurine protrudes. Though not so uniformly vascular as it is on the brain, very large and tortuous vessels extend along its whole length. When very recent, it can be easily detached from the medulla, or if the latter be hardened by immersion in alcohol, it can be peeled off, when numerous shreds and vessels may be observed to pass from one to the other. It not only invests the cord, but it also sends a duplicature into it along the anterior median line; this is very distinct, as it supports the anterior spinal artery, and a longitudinal white fibrous band; posteriorly, a very delicate vascular lamina or tissue is also prolonged from it into the median fissure; it also forms a neurilemma for each nerve, more delicate than the spinal investment. The pia mater contracts inferiorly, and ends in a filiform process, at first tubular, which descends together with the ligamenta dentata to be attached to the sacrum; the external surface of this membrane is covered by the cellulo-vascular sub-arachnoid tissue, which is more like the cranial pia mater than the immediate investment of the cord itself, for the latter partakes much more of the fibrous character, and is compact, dense, and pearly; this distinction is better seen in some animals, where this fibrous envelope is even of a different shade of colour; the peculiar dense or fibrous structure is very marked about the upper end of the cord, and is even prolonged upon the medulla oblongata and crura cerebri, but is totally absent on the cerebrum and cerebellum; this membrane in the spine serves the office rather of a closely fitting capsule for the organ than that of a vascular membrane as in the cranium; in the latter the grey neurine is superficial and the vascular membrane expanded upon it; in the cord the white matter is superficial, enclosing the grey, and the vessels penetrate to the latter through the fissures, chiefly through the posterior.

SECTION II.

DISSECTION OF THE SPINAL CORD.

THE MEDULLA SPINALIS is about a foot and a half long, extends from the atlas, where it is continuous with the medulla oblongata, as far as the first or second lumbar vertebra, and ends in a lash of nerves called *cauda equina*; this organ is almost cylindrical, but the transverse diameter exceeds the antero-posterior, and the whole is much

smaller than the osseous and membranous tube in which it is enclosed. A deep narrow fissure extends along the median line posteriorly, and a broad superficial groove anteriorly; at first the medulla spinalis is rather contracted or smaller than the medulla oblongata; but from the fourth or fifth cervical to the first dorsal vertebra it is larger than in any other situation; it then contracts, and is nearly circular through the upper and middle dorsal regions, and again swells out about the tenth dorsal vertebra into an oval bulbous expansion, which terminates in a point below, from which the filiform process of the pia mater, and the remains of the ligamenta dentata, with one or two veins, extend: this lower extremity of the spinal cord is sometimes round, sometimes bifid. The two enlargements of the spinal cord correspond to the origins of the largest nerves, viz. those to supply the upper and the lower extremities. The superior enlargement is greater than the inferior, no doubt because the sensibility of the upper extremity is greater than that of the lower, and its motor power more delicate and varied. The medulla spinalis consists of two symmetrical portions or columns united at the bottom of the two fissures by commissures.

The *anterior fissure* penetrates to nearly one-third of its thickness, into it a fold of pia mater enters, on this the anterior spinal artery runs in a tortuous manner, superficial to which is a distinct white, fibrous, longitudinal band extending from one end of the cord to the other, and attached to the edges of the groove; the floor of this fissure is closed by transverse white fibres with interstices for vessels; this is the *anterior* or *white spinal commissure*, analogous to the corpus callosum in the cerebrum; this fissure is more distinct above than below.

The *posterior median fissure* is very narrow, and unless the cord be very fresh, or hardened, is difficult to be seen; it sinks in very deep, nearly one-half, and a fine, imperfect lamina of the vascular membrane enters it; it is closed below by the meeting of the grey central neurine of each side, this is called the *posterior* or *grey spinal commissure*, and is analogous to the commissura mollis and intercrural lamina; this fissure, also, is more distinct above than below. On each column, or half of the cord, two lines may be observed corresponding to the anterior and posterior roots of the nerves; the anterior is so faintly marked as almost to escape notice, but the posterior presents a greyish tint derived from the internal grey neurine; this line is fixed upon for dividing each column into two smaller ones: all in front of this line is named *antero-lateral*, and all behind it *posterior column* The first then is bounded by the anterior median fissure in front, by this postero-lateral groove behind; the second is between this line and the posterior-median fissure; on each side also of the latter, superiorly, is a slight groove or line which bounds the small columns, called posterior pyramids; these are distinct in the fourth ventricle, on each side of the calamus, but inferiorly they gradually taper off into the posterior tracts. Some anatomists consider those portions between the roots of the nerves as distinct columns, under the name of *lateral columns*,

and Sir Charles Bell designated them "respiratory tracts." This name, however, is not now retained. According to some writers, then, the medulla spinalis is composed of eight tracts or cords, or four pair, viz. first, the anterior, between the median fissure and anterior nerves; second, the lateral, between the roots of the nerves; third, the posterior, between the posterior nerves and the posterior fissure; and fourth, the posterior pyramids, close to this fissure, but only in the upper part of the organ. This arrangement, however, does not appear necessary. The lateral grooves are very superficial, and there is no internal corresponding distinction or separation; it appears to me sufficient to consider the cord as divided, first, into two symmetrical portions, connected by the white commissure in front, and the grey behind; and second, each portion subdivided by the grey line corresponding to the roots of the posterior nerves, into two, the antero-lateral, or larger portion, extending from this grey line to the anterior median fissure, and the posterior smaller portion between this grey line and the posterior median fissure. It is to the antero-lateral columns, and to the grey neurine within them, that the nerves appear to be most connected, and they cannot be traced distinctly into either the posterior or anterior tracts; for this reason, also, there appears no good ground for calling the anterior tracts of the cord, "motor tracts," or the posterior, "sensitive tracts," although the terms "motor" and "sensitive" may be correctly applied to the anterior and posterior nerves, which do possess these special endowments.

The *spinal cord*, being a great nervous centre, is composed of grey neurine and white fibrous substance; it is the latter only which forms the superficial longitudinal tracts alluded to. If the organ be rendered hard by immersion in alcohol, these bands can be peeled off and separated, or split up into very long fasciculi, though very frequently shorter fibres bend into the central grey substance; superiorly these decussate, not only those of opposite sides, but also those of each side, with those before and behind, so that a perfect interlacement takes place in the medulla oblongata, through which, however, they are continued, partly into the laminæ of the cerebellum, and partly through the crura cerebri into the ganglions of the cerebrum.

The office or function of these longitudinal fibres is internuncial: they transmit on the one hand the impression made on the nerves from without to the brain, or percipient organ within, where sensation exists, and on the other they carry from the brain the stimulus of volition to the various muscles of the body. These fibres, therefore, are either sensitive or sensiferous, and volitive or motiferous: their function is at once suspended if their continuity be broken or interrupted. The cord, however, besides being the mere transmitting medium of sensations from without, and of volition from within, is also an independent centre of nervous energy, and is capable itself of receiving and of retaining impressions, without the mind or the brain being conscious of, or sensitive to them; and it can also excite certain motions and muscular actions independent of volition, and even in

opposition to it. These functions the cord can exhibit when all communication between it and the brain is interrupted or cut off. The capability or power of receiving impressions, without consciousness, has been termed its organic sensibility, but more properly its excitability; and its power of causing corresponding muscular actions without volition has been named its *reflex power*. The two phenomena taken together constitute the *excito-motor function*. We shall allude to it again directly when speaking of the spinal nerves, and shall now only add, that inasmuch as experiments and pathology have proved that this function may and does persist, even vigorously, below the division of the longitudinal fibres, that is below the seat of interruption between them and the brain, it is plain that it must depend upon the grey or ganglionic neurine of the cord together with the nerves which are inserted into it.

A transverse section of the cord will not only exhibit its symmetrical structure, but also the *grey neurine* in each column; this is of a lunated form, the concavity outwards, the convexity inwards, and connected to the opposite one by the grey commissure; the anterior cornu is thick, round, and short; the posterior is thin, sharp, and long, and reaches to the surface, forming the grey line along the posterior roots of the nerves. This grey neurine forms one continued track through each column, and extends upwards to the corpora striata and optic thalami, beyond which it cannot be traced; it, therefore, has no direct connexion with the peripheral neurine in the cerebral and cerebellar convolutions; it is to be regarded as the ganglionic centre of each spinal cord or column. Transverse sections of the cord, in different regions, exhibit the relative proportion of the grey and white matter in each, as has been well represented in Arnold's beautiful Icones. In the dorsal region there is less grey than elsewhere; the cervical expansion presents the greatest amount of white substance, particularly in the antero-lateral columns; in this region also the posterior white pyramids are seen. In the lumbar, the anterior white columns are diminished, but not the posterior, and the grey substance is considerably augmented; the lumbar enlargement chiefly depends on this material, while the cervical is owing to the increase in the white. The small size of the dorsal portion is in conformity with the limited nervous endowments of the trunk; and the preponderance of grey neurine below most probably bears a relation to the excito-motory actions of the rectum and urino-genital organs, and even of the lower limbs, which actions are more remarkable in them than in the upper, where sensibility and voluntary motor power are more highly developed. The relative proportion of grey neurine is much greater in the infant, the very opposite to what has been remarked in the cerebral convolutions, the seat of the intellectual functions, which at that age are comparatively dormant, while the excito-motor, or reflex functions of the cord, are in full activity. In the spinal cord of fish, reptiles, and birds, there is a regular canal extending through the entire length, and partially closed in some places into a tube. The fourth ventricle is typical of this; in

birds this canal is expanded into a rhomboidal space, like the fourth ventricle in the lumbar region; this can be well seen in the common fowl; in the human embryo this canal also exists, but in the progress of development it becomes closed by the approximation of the lateral columns, and the only permanent remains of it are the posterior median fissure and the fourth ventricle. If any arrest of growth occur, it will remain open and imperfect, of which condition spina bifida may be considered an example.

In addition to the spinal accessory nerves, which may now be seen to arise from each side of the medulla spinalis in the upper half of the neck by twelve or fourteen small filaments, and to ascend behind the ligamenta denticulata, the spinal cord gives origin to thirty-one pair.

SECTION III.

ORIGIN OF THE SPINAL NERVES.

The spinal nerves are symmetrical; there are thirty-one pair (some anatomists enumerate thirty, some thirty-two), which are divided into eight cervical, twelve dorsal, five lumbar, and six sacral. All these nerves arise and terminate nearly in a similar manner; each is a compound nerve, composed of two roots, an anterior and posterior, each consisting of several filaments. The *anterior spinal nerves* arise from the antero-lateral columns in the narrow groove which subdivides these into anterior and lateral tracts. The *posterior* arise in the posterior lateral groove or grey line formed by the posterior cornu of the central ganglion; the filaments of each unite into converging fasciculi, which again unite to form each root; those composing the posterior root are larger than those in the anterior, excepting in the case of the first or suboccipital, whose anterior is larger than the posterior, the latter is sometimes wanting, or it may join the spinal accessory nerve: these two fasciculi or roots are separated from each other by the side of the spinal cord, and by the ligamentum dentatum; they then converge and proceed obliquely outwards and downwards to the dura mater, which they perforate distinctly by two small openings, which, however, are so close as to appear but one; each fasciculus receives a sheath from the dura mater; a small oval ganglion is then formed upon the posterior root; to the surface of this ganglion the anterior root is only connected; immediately on the outer side of this ganglion the two roots unite and intermingle, and form a single cord; this is the proper or compound spinal nerve. After a short course outwards this passes through the intervertebral foramen, and immediately divides into two branches, a posterior and anterior; the former is almost universally the smaller, except in the first and second cervical, and is distributed to the mus-

cles and integuments posterior to the vertebral column; the posterior branch of the second is very large, is named occipital, and is the sensitive nerve for the back part of the scalp. The anterior branches of the spinal nerves are much larger; they enter into the several plexuses, cervical, brachial, lumbar, and sacral, and supply the muscles anterior to the spinal column, as also the extremities. The first cervical nerves ascend a little, the second are nearly transverse; the succeeding nerves are more oblique, and the lumbar and sacral are vertical, and form the cauda equina; the three or four last have their ganglions and subsequent divisions within the sacral canal; the roots of the cervical nerves are the largest, particularly the posterior; the dorsal nerves, except the first, are much smaller than the cervical, and more distant from each other; the anterior and posterior roots are nearly equal; the lumbar again increase in size, and are very close to each other, so as almost to conceal the cord; their anterior roots converge below, and nearly meet.

The connexion of all the spinal nerves to the cord is mainly depending on the pia mater; in separating this the nerves are usually detached also, and under commencing decomposition they separate along with it; if, however, the examination be made with great care in a very recent specimen, the nervous filaments appear to be partly connected with the superficial fibres of the cord, and partly with the grey neurine within; the filaments, however, are of such exquisite delicacy and minuteness as to elude observation. Mr. Grainger, in his ingenious treatise on the spinal cord, describes the fibres of each root, when in contact with the cord, as separating into two sets; one ascend, and are lost in the white fibres of the antero-lateral columns of the cord; the other set sink into the sulcus, and bend at a right angle into the grey neurine, and terminate in it in a mode that cannot be ascertained exactly, but which appears analogous to the connexion elsewhere between grey and white neurine. I have not yet had the satisfaction of proving the entire accuracy of this statement, which, however, is rendered extremely probable, and is strongly supported by the physiological explanation it affords of the functions of the spinal cord and spinal nerves.

We have already alluded to the double office of this organ, the first that of merely transmitting or propagating sensation and volition, the second that of an independent nervous centre, presiding over the excito-motor function, in which impressions are made upon the cord, which excite or give rise to corresponding muscular actions, the former without consciousness, the latter without volition. This twofold origin, then, of each root of the spinal nerves is in perfect conformity with this twofold function, and beautifully harmonizes with the excito-motor theory; for as the cord is to be considered partly cerebral and partly spinal, so are the nerves which are attached to it partly cerebral and partly spinal; each nerve, therefore, instead of two roots, really has four, two anterior and two posterior; of the two posterior one set join the ascending fibres, and may be named the sensiferous or cerebro-sentient fibres; these transmit sensations to the brain, the seat

of consciousness and perception ; the other set sink into the postero-lateral sulcus, and join the grey neurine ; these are named the incident or excitor fibres, or true posterior spinal nerves. Of the two anterior roots, in like manner, one set join the longitudinal fibres, and are named the volition or cerebro-motor fibres ; the other set sink into the antero-lateral groove, and join the grey neurine opposite to the posterior or incident fibres, with which, probably, they unite ; these anterior fibres are named the reflex or spino-motor fibres ; these, with the incident fibres behind, constitute the excito-motor system, or true and independent spinal system, while the anterior and posterior ascending or descending fibres form the cerebral portion of the cord, and constitute it so far only an appendix to the brain.

All the spinal nerves, therefore, are compound nerves ; their roots also are compound, the posterior being composed of sensitive and incident fibres, and the anterior of volition or cerebro-motor, and of spinal or reflex motor fibres.

The course and distribution of the spinal nerves shall be examined individually afterwards. The student may next dissect the brain from below.

SECTION IV.

DISSECTION OF THE BRAIN FROM BELOW.

THE brain, medulla oblongata, and the upper part of the spinal cord, should be carefully removed from the subject ; the brain, with the base uppermost, should then be placed in a shallow basin ; the cerebellum and medulla oblongata will now fall a little backwards, and all the parts of the base of the brain will be exposed. Raise the pia mater from the forepart and sides of the medulla oblongata. The several eminences on this organ may be traced upwards to the cerebrum and cerebellum. To follow these the dissector should rather scrape and break the surrounding substance with the handle or with the back of the knife, than cut it with the edge. In the description of the brain already given, certain differences between the cineritious and the white substances have been stated ; it is necessary to recollect that the former is soft and very vascular, and that the latter is fibrous. It was an opinion maintained by Gall and Spurzheim that the grey is the origin or matrix of the white substance, and that the former is a secreting organ, and that the latter consists only of fine conducting vessels or filaments. This opinion, however, can only be adopted with modification ; it is incorrect to say that the grey forms the white, inasmuch as the origin of both in general is coeval, and their growth concurrent; in some situations the grey precedes the white, but in others *vice versa;* the grey, therefore, can no more be said to form the white than the latter does the former, but both are created by the vessels of the vas-

cular membrane in their appropriate situations. This remark, however, does not lessen the value of the other statements propounded by these distinguished writers, to whom science is more indebted for correct notions of the cerebral structure than to any preceding or subsequent anatomists, namely, that the grey substance is the source of power, and that the white fibres are mere conductors. The great vascularity of the former implies superior functional importance; it is always found augmented in quantity or extended in surface where nervous energy is exalted; and wherever white fibres enter it, they appear on leaving it to be increased in size, if not in number. The grey or ganglionic masses, then, though not strictly "formative," in the language of Gall, yet may, according to him, be termed "ganglions of nutrition or reinforcement, or supply." In the dissection of the encephalon from below we speak of fasciculi ascending from the spinal cord to the different parts above; this language suits the desired brevity in description, yet is not, perhaps, strictly correct; at least if we are to name the connecting fasciculi according to the direction in which their supposed properties are transmitted, we ought then to consider and designate the "sentient" fasciculi "ascending," and the "motor" "descending," and the "commissural" "converging." Such distinctions, however, though perhaps theoretically true, cannot be practically demonstrated, except in a few instances; one set of fibres cannot be distinguished from another, neither can the exact commencement or ending of any be ascertained. Those who set out on the principle of one part succeeding to another in the process of development, have considered all the white fibres as arranged in two orders, one called "formative or diverging fibres," the other "uniting or converging;" the fasciculi, ascending through the medulla oblongata, form the concentrated root of the former; the several commissures are the resultants of the latter. The fasciculi, in their ascending and diverging progress, pass through ganglionic masses at various stages; in each of these they separate into fibres, which again divide into minute fibrillæ, the intervals being occupied by the vascular, grey neurine; in these bodies some fibres appear to end, others to continue their course uninterruptedly through, while in some a new order of fibres, commencing in these, are superadded. The principal masses of this order are, first, the corpora dentata, in the olivary bodies, and the vesicular matter diffused in the upper part of the olivary tracts; second, the corpora rhomboidea, or internal cerebellar ganglions; third, the mesocephale, including the pons and quadrigeminal bodies; fourth, the locus niger in each crus cerebri; fifth, the optic thalami; sixth, the corpora striata; and seventh, the superficial laminæ or hemispherical ganglions of the cerebrum and cerebellum, convoluted on the former, laminated on the latter; each of these has been already noticed in the dissection from above. We shall now trace the spinal fasciculi through these upwards, and point out, as far as can be determined, the connexion and termination of each. The medulla spinalis has been described as a symmetrical organ, each half consisting of the great

antero-lateral cord and of a small posterior cord, and superiorly and posteriorly of two smaller fasciculi, named *posterior pyramids*. Proceed now to trace the columns; and, first—

The posterior pyramids.—These are two white fasciculi, commencing small in the dorsal region, and, increasing in size, they ascend on each side of the posterior median fissure as high as the fourth ventricle or calamus scriptorius, when they disappear rather abruptly, partly joining the restiform bodies and partly sinking into the central substance or the olivary tracts. They cannot be traced isolated any further, and may be regarded as commissural between the spinal cord and the medulla oblongata.

The restiform bodies.—These white ropes are continuous with the posterior columns and with the posterior portions of the antero-lateral cords, and are joined by the arciform fibres from the anterior pyramids; each rope then ascends obliquely outwards, diverging from its fellow, enters the hemisphere of the cerebellum, and joins the under surface of the crus cerebelli. Divide the latter by a vertical incision, the rope may then be seen continued into the mass of grey substance named corpus dentatum, or the ganglion of the cerebellum; from the inner edge of this a narrow white fasciculus may be traced inwards towards the median line; it there unites with a similar process from the opposite side, and both divide into several fine branches, which radiate and form the vermiform process, or the primary lobe of the cerebellum; the peripheral extremities of these fibres are covered by cineritious substance, and present, when cut vertically, an arborescent appearance (middle arbor vitæ). The remainder, or principal portion of the restiform body, passes upwards and outwards through the corpus dentatum, and then divides into several processes or stalks, which diverge through each hemisphere and subdivide into finer branches, each of which is covered by the grey substance on the surface. A vertical section of either hemisphere presents also that arborescent appearance known by the name of lateral arbor vitæ. The converging or commissural fibres of the cerebellum are inferior and superior; the latter are very delicate and rather indistinct in their course; they consist of several fibres, which issue from the superficial grey neurine of the vermiform processes or median lobe, and unite in one broad lamina, which is thin in the centre (the valve of Vieussens) and thick at each side (processus a cerebello ad testem). These superior converging fibres form not only the superior or lesser commissure of the cerebellum, but also the intercerebral commissure, or that between the cerebellum and the quadrigeminal bodies. The inferior converging fibres are more distinct; they proceed from the superficial grey neurine on either hemisphere forwards and inwards, and form the principal portion of each crus cerebelli; they then pass transversely across the pons Varolii, and unite with those from the opposite side; thus the superficial laminæ, or transverse fibres of the pons, constitute the great or inferior commissure between the hemispheres of the cerebellum.

Anterior pyramids are continuous with the anterior columns of the

cord, each partly with that of its own side, but principally, through the decussating fibres, with that of the opposite; as they approach the pons they are somewhat contracted. On entering this ganglion they separate into fasciculi, which intermix with its grey substance, and become considerably increased in size and number in passing through it; they then form the anterior and external two-thirds of the crura cerebri.

The *olivary tracts* may be well seen by dissecting off one or both pyramids, commencing from the decussating fibres and raising them through the pons to the crus cerebri; the olivary columns are continuous with the central part of the medulla oblongata, and extend to its posterior surface in the upper part of the fourth ventricle; inferiorly they are prolonged into the antero-lateral column; the projecting portion of each between the anterior pyramid and the restiform body is named the olive, and contains the small ganglion, or corpus dentatum; after passing the sulcus below the pons, each tract ascends through this body, above and behind the anterior pyramids, and separated from them by grey neurine, and some deep, transverse, white fibres; in this course their fasciculi open and divide minutely, intermingling with grey matter, so that their vertical direction is not so obvious as that of the pyramids; they can, however, be traced upwards into the superior, posterior, and internal part of the crura cerebri, and are continued thence partly to the corpora quadrigemina, and partly into the optic thalamus and corpus striatum; in these ganglions it is difficult to determine their exact course, or to display the radiated arrangement as represented in the engravings of different authors. If the parts be very well hardened, we perceive a great quantity of white substance to pass from the thalamus, partly to the posterior lobes of the cerebrum, partly upwards and inwards towards the corpus callosum, but principally upwards and outwards into the posterior lobes of the cerebrum; the exact course and termination of the fibres then become very indistinct, it is, however, most probable that they extend to the convoluted grey neurine upon the surface.

Crura cerebri are the two short, thick, white fibrous cords extending upwards and outwards from the mesocephale or the pons to the two cerebral ganglions, the thalamus, and the striatum; they are connected to each other by the grey intercrural perforated lamina, are encompassed by the optic tracts, and are perforated by many blood-vessels; they are composed of three planes, two are superficial and one is deep-seated; the anterior inferior plane is directly continuous with the anterior pyramids, the posterior superior with the olivary tracts. Between these planes, which with a little care can be separated by following a sulcus which appears on their inner and back part, the third component stratum is placed. This is a mass of grey or rather very dark neurine (locus niger), of a semilunar form, like that in each spinal cord, the cornua pointed, looking backwards and forwards, and the convexity inwards, and feebly connected to the opposite by the intercrural lamina. The locus niger, or ganglion of

the crus, is continuous superiorly with the grey neurine of the striatum and thalamus, and inferiorly with that in the pons, medulla oblongata, and in the lateral spinal cord, so that the grey or vesicular matter forms a continuous track on each side from the lumbar extremity of the cord to the cerebral ganglions or corpus striatum and optic thalamus; and this long tract, which is differently shaped in different parts, in some diminished, in others augmented, has no connexion with the superficial or cerebellar ganglions, except through the medium of the white or conducting fibres. Each crus cerebri is capped by the striatum and thalamus, which are ganglionic masses; into these the white fibres enter, and, although these bodies appear on the surfaces as two distinct organs, they are really blended together into one mass, and may be compared to that in any segment of the spinal cord. These two organs are but one great ganglion, swollen before and behind, and, like those in the spinal columns, are connected on opposite sides by their grey commissure (commissura mollis), and by their white (anterior and posterior commissures). The white fibres, on entering these cerebral ganglions, become separated and intermingled with the grey substance; in these some appear to terminate, or perhaps to commence, others appear plexiform, others can be followed through them; from their peripheral surface numerous fasciculi pass off, many of which appear to commence in it; the fasciculi then radiate in all directions, and constitute the greater portion of each hemisphere; one portion can be traced upwards, to form the inferior lamina of the corpus callosum. The anterior portion of each crus runs more directly through the striated body, and the radiation of its fibres is more evident than that of the posterior, which first enters the thalamus, and then partly passes through the striatum also. The inferior and anterior part of each crus is more directly in continuation with the anterior pyramids, which are the prolongations of the anterior fibres of the cord, or the motor tract. Along this line it is presumed that volition is principally, if not solely, transmitted; these fibres, then, might be considered as descending; along them volition, emanating either in the hemisphere or in the corpus striatum, descends through the pyramids and through the decussating bands, principally to the opposite spinal motor track, and thence to the anterior or motor nerves of the opposite side of the system. The posterior segment of each crus, which passes through the thalamus and corpus striatum, is much larger than the anterior, and, being in direct continuity with the posterior portion of each spinal column, that is, the sentient or sensiferous tract, may be regarded as ascending fibres, along which impressions are conveyed to the brain, where perception and sensation are manifested. But to what part of the brain do these fibres extend? Do they end in the cerebral ganglions, or do they pass through these to the hemispherical or superficial ganglions, and do they end then in loops or plexuses with each other; or are they united to, or continuous with, the descending motor fibres? These are questions to which anatomy affords no answer; they prove a fertile source for speculation and hypothesis, which, however, we shall not pursue on the present

occasion. Although we stated, in conformity with the generally received opinion, that the crus cerebri, like each half of the spinal cord, contains a motor and a sensitive column, with intervening grey neurine; yet it is by no means certain, either from anatomical examination or from experiment, that this statement is perfectly true; it is even questionable whether the anterior and posterior tracts in the spinal cord are motor and sensitive in a distinct and isolated manner, although the nervous roots are so: it is certainly probable that motor filaments may preponderate in one and sensitive in the other, but that these continue isolated up to the brain must be questioned by the anatomist who in vain tries to insulate each tract in the medulla oblongata, and finds it still more difficult to do so in the pons Varolii, and totally impossible in the thalami and corpora striata. I consider, therefore, both divisions of the crura cerebri to be compound cords, and to contain motor and sentient fasciculi, while I admit that the anterior portion is more directly derived from the pyramids and anterior spinal or motor tracts, and the posterior from the back part of each antero-lateral or sentient tracts. As the corpora restiformia are derived from the posterior and antero-posterior columns, and are also connected with the olivary and anterior pyramidal tracts, they must be regarded as compound bodies, that is, as consisting of motor and sentient fasciculi. A most intimate connexion exists between the cerebellum and the other parts of the nervous centre, viz., the pons, tubercula quadrigemina, optic thalami, and spinal cord. These anatomical relations, as well as the results of experiments on living animals, lead to the conclusion that the function of the cerebellum is intimately connected with the muscular system; and that, according to Flourens, it has the power of coordinating the voluntary motions, which originate in other parts of the cerebro-spinal centre: there appears no good reason for adopting the opinion of Gall, that the cerebellum is the organ of amativeness or sexual instinct. As the white fibres diverge and radiate through each hemisphere from the corpus striatum and optic thalamus, they appear to be of different lengths, and thus partly afford a mechanical explanation for the uneven or convoluted surface which the investing grey lamina presents; the physiological design of which, however, has been already explained. If all the fibres were of equal extent, the surface of the cerebrum would be smooth; but, as some fall short of others, and all are covered by the grey substance, an uneven or convoluted surface is the result. From this grey substance, which covers the surface of each convolution, and lines the intermediate sulcus, the converging or descending and commissural fibres are described as arising, and thence passing towards the mesial line; the corpus callosum and the anterior and posterior commissures are supposed to be thus formed. In addition to these transverse processes there are several other parts which may serve as media of communication between different parts in each hemisphere of the brain, viz., the ourlet, the fornix, the tænia semicircularis, the pineal gland, and its pedunculi, the infundibulum, the septum lucidum, &c. &c., all of which have been already alluded to.

SECTION V.

VESSELS OF THE BRAIN.

THE brain receives a large supply of blood almost direct from the aorta, through the two vertebral and the two internal carotid arteries. The *vertebral arteries* are the first branches of the subclavians, and not unfrequently they proceed from the aorta itself; they ascend through the series of foramina in the transverse processes of the cervical vertebræ,

Fig. 68.*

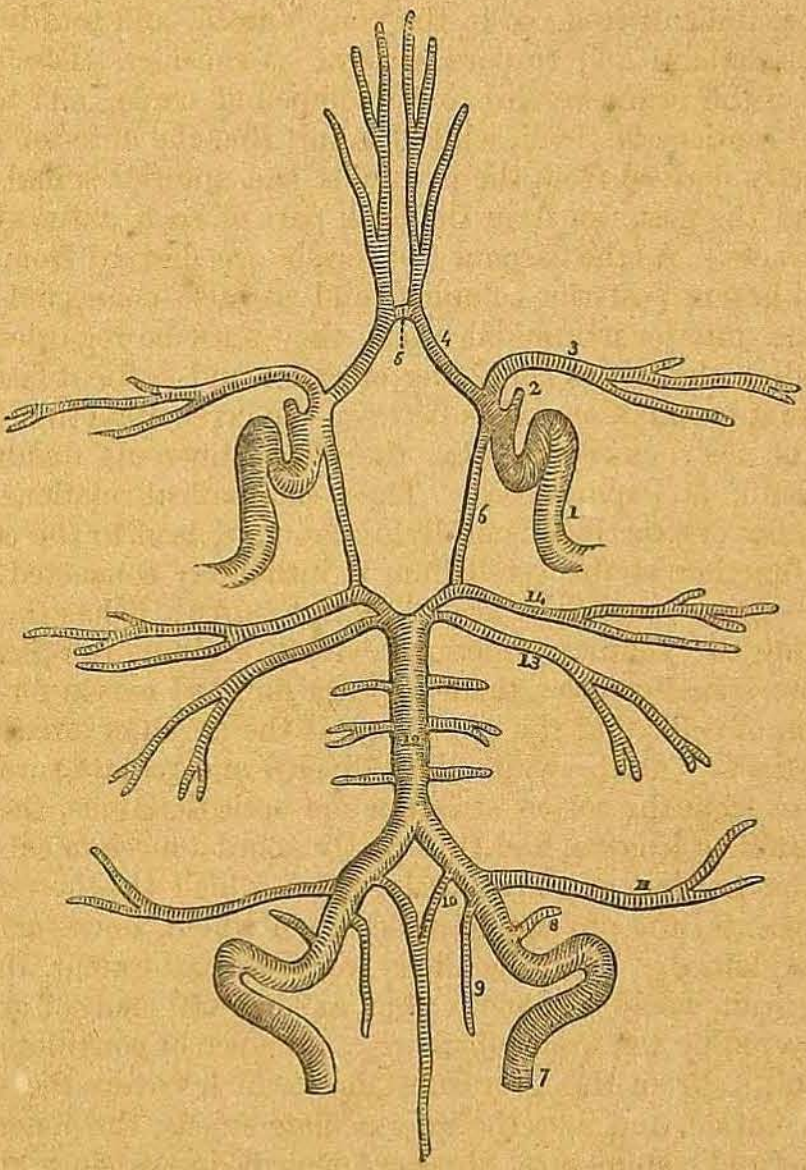

* The arteries of the brain and the circle of Willis. 1. The internal carotid artery. 2. The ophthalmic artery cut across. 3. The middle artery of the cerebrum. 4. The anterior artery of the cerebrum. 5. The anterior communicating artery. 6. The posterior communicating artery. 7. The vertebral artery. 8. One of the posterior meningeal arteries. 9. The posterior artery of the medulla spinalis. 10. The anterior artery of the medulla spinalis. 11. The inferior artery of the cerebellum. 12. The basilar artery, formed by the union of the two vertebral arteries. 13. The superior artery of the cerebellum. 14. The posterior artery of the cerebrum.

anterior to the cervical nerves, winding around the superior articulating processes of the atlas, pierce the dura mater, and pass through the foramen magnum into the cranium ; they then proceed obliquely forwards and inwards, and end in the common trunk called the *basilar artery*. Each vertebral first sends off two long and delicate branches, one on the anterior, the other on the posterior surface of the spinal cord ; these extend the whole length of this organ, supplying it with blood, and sending out small branches along the several spinal nerves ; next to these branches each vertebral gives off the inferior artery of the cerebellum ; this turns backwards between the pneumogastric and spinal accessory nerves, and is distributed to the inferior surface of the cerebellum. The basilar artery ascends along the median groove in the pons, sending numerous branches into its substance, and at its superior edge divides into four branches, two for each side, viz., the superior cerebellar artery and the posterior cerebral ; the superior cerebellar winds round the crus cerebri, parallel to the trochleator nerve, sends a branch with the seventh nerve into the internal auditory foramen, and is finally distributed to the upper surface of the cerebellum, and anastomoses with the inferior. The posterior cerebral arteries are much larger than the last, and separated from them at their root by the third pair of nerves ; they are soon joined by the posterior branches of the carotids, and then wind round the crus cerebri parallel to the fourth nerves, send branches to the intercrural lamina, also into the crura cerebri, and are lost in the posterior cerebral lobes. Each *internal carotid artery* winds obliquely forwards, upwards, and inwards, through the tortuous canal in the temporal bone, and through the cavernous sinus ; beneath the anterior clinoid process it perforates the dura mater, and rises perpendicularly to the base of the brain, between the second and third nerves, and then divides into three branches, the anterior, middle, and posterior, having first given off small branches to the cavernous sinus and to the dura mater, also the ophthalmic artery which enters the orbit through the optic hole, and is distributed to the eye and its appendages. The anterior branch of the carotid is also named the anterior cerebral artery, or the artery of the corpus callosum : this passes forwards and inwards, and is joined to the corresponding artery of the opposite side by a short branch (the anterior communicating artery) ; it then ascends, and runs along the upper surface of the corpus callosum, distributing its branches to the inner surface of each hemisphere. The middle branch of the carotid is the largest, passes upwards and outwards deep in the fissure of Sylvius, and is distributed to the anterior and middle lobes of the cerebrum ; it sends branches through the perforated plate into the corpus striatum. The posterior branch of the carotid is named the posterior communicating artery ; it is small, passes backwards, and joins the posterior cerebral artery ; this forms the side of the circle of Willis. (*See* Anatomy of Vascular System.) The vessels of the brain are accompanied by numerous fine filaments of the sympathetic nerves ; these pass into its substance either to supply its intimate structure, or the minute vessels which permeate every part of it. The vertebral arteries receive their atten-

dant nerves from the inferior cervical ganglions of the sympathetic, and the internal carotids from the superior; the branches on the carotids are more numerous and distinct. In the petrous canal and cavernous sinus they form a ganglionic plexus, which communicates with the cranial nerves of the orbit; from this the filaments can be traced along the trunk of the artery and its principal branches to the brain; on the anterior communicating branch the filaments of opposite sides unite in a small ganglion (the ganglion of Ribes). The arteries of the brain are remarkable for the freedom of inosculation, not only in their small branches, but in the trunks; the design of which is, doubtless, to secure a constant supply, notwithstanding any accidental interruption in any one particular channel. On the pia mater the arteries subdivide very minutely and inosculate most freely; the larger branches are lodged in the sulci, and the grey neurine is covered by a capillary net-work, branches from which enter into its tissue in infinite number and of exquisite minuteness. Intermingled with these capillaries are the grey vesicles and the fine fibrillæ of the white or tubular nervous matter, and there can be no doubt that the development of the nervous power is connected with the combination of these three elements, all of which are in a state of most minute division and intimate union. That the development and continuance of nervous energy greatly depends on the blood, may not only be inferred from these anatomical arrangements, but is proved by the actual experiment of completely cutting off the supply of blood from the brain being followed by a cessation of the force; an analogous result attends syncope. While a large supply of blood is indispensable to the brain, care has been taken to protect its delicate structure from the too strong impetus of the heart and large arteries; with this view, no doubt, have the curious contortions of the carotids and vertebrals been designed; the subarachnoid fluid also is well adapted to sustain, support, and compress the vessels, and to regulate the degree of vascular fulness; its importance in this respect is not merely theoretical, but has been fully proved by the experiment of withdrawing it from the spinal canal in living animals, when the functions of the brain have become disturbed, and even syncope has ensued.

The veins of the brain join the sinuses, which have been already described; the principal veins are on the superior surface of the brain, whereas the large arteries are below.

The brain and its membranes exhibit many *morbid* appearances. The *dura mater* is sometimes found in a state of inflammation: to an inexperienced eye this appearance is difficult of detection, as in this condition very few more vessels appear carrying florid blood than in the natural state. In injuries from external violence, where inflammation follows, suppuration often occurs, and the pus is found sometimes on its external surface, between it and the bone, sometimes internally, covering the arachnoid coat. *Scrofulous and fungoid*, or *fibrous tumours*, growing from the dura mater, producing absorption of the bone, or pressure on the brain, are occasionally found; also deposition

of bony laminæ, particularly in the falciform process, or near the superior longitudinal sinus.

The arachnoid membrane is sometimes inflamed. *Arachnitis*, when chronic, presents an opaque, or in some instances a thickened, state of the membrane, which gives it a tolerably firm consistence: serous fluid, sometimes of a gelatinous nature and creamy appearance, is found between it and the pia mater, and, although these appearances are said to depend on inflammation, still no vessels holding red blood are found ramifying on its surface, the redness which is sometimes present being owing to the vessels of the pia mater appearing through it. Adhesions between the parietal and visceral laminæ of this membrane seldom occur, as in other serous cavities. In acute arachnitis, pus, or sero-purulent fluid, or serum with lymphy flakes and of a sanguineous colour, are occasionally effused.

Hydrocephalus is a disease of this membrane of frequent occurrence; it consists in an effusion of clear serous fluid; it may be acute or chronic, and the fluid, which may amount to a few ounces, or to as many pounds, may be collected either within the ventricles (hydrocephalus internus), or it may be on the surface of the brain (hydrocephalus externus); in the latter the brain will be found compressed towards the base of the cranium; in the former, which is the more common form, the hemispheres will be found expanded. In both the cranium will be enlarged, and in young persons the sagittal and coronal sutures will be expanded, and the fluid, in passing from one lateral ventricle to the other, raises up the fornix, expands the foramen commune anterius, and so passes into the third, and thence into the fourth ventricle. In hydrocephalus, scrofulous disease is frequently to be found at the base of the brain, as also small tubercles on the pleura and peritonæum. We often find fluid also between the arachnoid coat and the pia mater, sometimes effused in small patches between these two membranes, and at others over a large extent. When this subarachnoid, anasarcous-like effusion takes place, the vessels of the pia mater are found more distended with blood than usual, and the arachnoid membrane is often thick and opaque; it is not uncommon at the base of the cerebrum, and in the spinal canal; sometimes, but not always, there is effusion of water also in the lateral ventricles.

There is some difficulty experienced in distinguishing inflammation of the *pia mater*, on account of the great number of small vessels which naturally ramify on it. In the inflamed state these become much more numerous, and, by their anastomoses, make a beautiful reticulated appearance, not, however, causing such a general redness as may be observed in the inflammation of some other membranes; and, when the injury runs high, pus is formed, which is effused on the whole upper surface of the brain. A common morbid appearance, found in the pia mater, is the formation of small cysts, containing water, which are generally called hydatids; these are found more usually on the choroid plexus, and in the velum interpositum. *Inflammation of the substance* of the brain is occasionally observed arising from external

injury; the redness, which is generally slight, is confined to one particular part. In this state, when cut into, the colour appears to arise from a great many small vessels, which are filled with red blood; the inflamed part is softer and more yielding than natural, giving rise to an appearance which has been described as "ramollissement." When the inflammation proceeds further, abscesses holding pus are sometimes formed, which, if of a large size, break down the substance of the brain, and present a very jagged appearance on their internal surface, though in some instances they have a regular cyst. *Apoplexy*, or an effusion of blood or serum either on the surface or in the substance of the brain, and occasionally into some of the ventricles, is also met with. The blood found in those situations is almost always black and coagulated; the substance of the brain is torn. When the person survives the attack, and recovers the energy of the organ, the blood becomes absorbed in part, a regular cyst or cell encloses the remainder, and in some cases no trace remains of the original disease, except some condensed or cicatrized appearance. *Deposition* of *caseous* and even of *earthy matter* in the arteries of the brain may also be looked for. This appearance is by no means rare, particularly in old subjects. Arising from this state of arteries, aneurisms of the internal carotids are described by some authors, but they are not of common occurrence.

SECTION VI.

ORIGIN OF THE CEREBRAL NERVES.

THERE are nine pair of cerebral nerves; their connexion to the brain is named their origin; they are distinguished by the terms, first, second, third, &c. &c: in every respect those of the opposite sides are symmetrical, and they are all, except the olfactory, connected directly or indirectly with the medulla oblongata and mesocephale.

The FIRST PAIR, or OLFACTORY, are situated beneath the anterior lobes of the brain; each *arises* by three filaments; the *external*, very long and white, from the fissure of Sylvius, below the corpus striatum; the *internal*, also white, from the grey substance at the extremity of the corpus callosum; the *middle* is cineritious, and *arises* from one of the posterior convolutions of the anterior lobe. The three filaments soon unite, and form a triangular swelling, from which the nerve proceeds forwards and inwards for about two inches, in a groove between two convolutions on the under surface of the anterior lobe, in which it is confined by the arachnoid membrane, and protected from pressure; it then ends in a soft, grey, oval bulb, which is placed over the cribriform plate of the ethmoid bone, close to the crista galli; from this the

several filaments descend through the foramina in this bone, and are distributed to the mucous membrane of the nose: these filaments, which are the proper olfactory nerves, are very fine and soft; they descend through the two rows of foramina in the cribriform plate; the internal set are distributed to the septum; the external to the superior and middle spongy bones. The olfactory differ from the other cerebral nerves in figure, course, and structure; in form they are prismatic or triangular, the apex being imbedded in the groove in the cerebrum; they converge as they leave the cranium; they consist of several striæ, some white, others grey, all very soft; they are not surrounded by arachnoid membrane, but lie above it; they have no distinct sheath, and each ends in a soft, grey swelling, from which the ultimate filaments proceed, or truly arise, and then leave the cranium by a number of foramina. It would be more correct to consider the origin of these nerves to be from the bulbs at each side of the crista galli, and to regard these bulbs and their connecting stalks as appendages of the brain or *olfactory lobes;* these are composed of grey and white neurine; in the peduncle the grey is superior and the white inferior; the bulb is principally cineritious, but contains some white substance internally. In the sheep these organs are very large, and in each bulb there is a distinct cavity, with polished surface, communicating by a small canal with the lateral ventricle.

The SECOND PAIR, or OPTIC, are large, soft, and flat posteriorly, round and enclosed in a dense neurilemma anteriorly; each *arises* from the tubercula quadrigemina, from the optic thalamus, and from the corpora geniculata; the roots unite into a soft, flat band, which turns forwards in a semicircular course (*tractus opticus*) around the crus cerebri, to which it has but a slight attachment, and from which it receives a few fibres; the optic nerves then converge, and unite before the sella turcica in the *optic commissure*, or *chiasma*. In this flat, white, square substance, which is connected to and receives additional fibres from the tuber cinereum, the two nerves are so confounded that the direction of each is indistinct, but it appears as if the inner fibres of each decussate, while the outer fibres proceed on to the eye of the same side; from the commissure each nerve passes forwards and outwards on the inner side of the carotid and above the ophthalmic artery, through the optic foramen, into the orbit; it is there surrounded by a process of dura mater, which splits at the orbital surface of this foramen; its outer layer joins the periosteum of the orbit; the inner encloses the nerve as far as the sclerotic coat, with which it becomes continuous; the nerve proceeds to the back part of the eye, and perforates the choroid and sclerotic coats of this organ, and terminates in the retina.

The THIRD, or MOTORES OCULORUM, are smaller than the optic; each *arises* from the inner side of the crus cerebri, close to the pons, behind the floor of the third ventricle, and between the posterior artery of the cerebrum and the anterior artery of the cerebellum; the fibres can be traced into the crus to the mass of grey neurine named "locus

niger;" this round nerve passes forwards and outwards external to the cavernous sinus, through the foramen lacerum orbitale, then divides into two branches, which are distributed to five of the seven muscles contained in the orbit.

The FOURTH, or TROCHLEATORES, or PATHETICI, are the smallest of the cerebral nerves; each *arises* by two or three delicate filaments from the valve of Vieussens and from the processus a cerebello ad testem, or from the olivary tract; it takes a long course forwards and outwards between the cerebrum and cerebellum, enters a small canal between the layers of the tentorium, behind the posterior clinoid process, and continues its course along the outer side of the cavernous sinus, at first below the third, but it afterwards rises above all the orbital nerves, passes through the foramen lacerum orbitale, and is distributed exclusively to the superior oblique muscle.

The FIFTH, or TRIFACIAL, or TRIGEMINI, are the largest of the cerebral nerves; each consists of nearly one hundred fine filaments, but loosely connected to each other, and very easily detached from the brain, leaving a small nipple-like projection, which, however, is only the cerebral portion of the ruptured nerve. This large fasciculus obviously consists of two packets, one very large and inferior, the other much smaller and superior; the latter is motor in function, the former is sentient, and will be found to expand into a large ganglion (*Casserian*). Both portions issue from the crus cerebelli near its junction with the pons through transverse slits in the former; they are attached to the anterior inferior surface of the crus near its centre, but nearer to the upper than the lower margin; the motor or smaller portion is at first superior to the sensitive, but it gradually winds round it, so that when the latter expands into the ganglion on the petrous bone, the former is beneath it, and can be easily separated from it. The fifth nerve is considered analogous to the spinal system of nerves; like these it is compound in function, and consists of two portions or roots which spring from the spinal bulb; the posterior root or nerve also forms a ganglion in the middle fossa of the base of the cranium, and the anterior nerve is only connected to it, but does not enter into its structure. This ganglion divides into branches, which are extensively distributed to the head and face, and are the sentient nerves to these regions; the other, or anterior or motor root, is exclusively distributed to the group of muscles engaged in mastication. The point of attachment of this nerve to the crus cerebelli is the point of escape, but not of origin, as it can be traced downwards and inwards to a considerable depth, the two portions continuing distinct. In tracing it in this direction the fasciculi are found to become flat and soft, from having little or no neurilemma, as they have externally, and are, therefore, difficult to insulate or pursue, unless the parts have been previously hardened in alcohol, and even then considerable care is requisite; indeed it is by no means easy to determine the exact point or origin of the root; this accounts for the discrepancy in the description and representations in different anatomical works. Doctor Alcock has given the most ela-

borate and accurate description of all parts of this nerve in a very able article ("Fifth Pair of Nerves") in the *Encyclopædia of Anatomy*, from which the following is an extract: "The *larger packet* can be more easily traced; it descends beneath and before the smaller, inwards and backwards, towards the spinal bulb; it first traverses the middle crus of the cerebellum from before backwards and from above downwards; it is then situated in the angle formed by the three peduncles of the cerebellum at their junction with the hemisphere, behind the middle, beneath the superior, and above the inferior, and before or beneath the floor of the fourth ventricle. At this point it is attached to the medulla oblongata, very close to the interior of the ventricle, only separated from it by a fine lamina of epithelium, and superior to the auditory nerve, and separated from it by an interval of a few lines. The *lesser packet* is divisible into two roots, a superior and inferior; both traverse the crus as the greater does; the inferior in company with and close to it, the superior is nearer the superior surface of that part, and is often so near the surface of the crus that it can be traced by the eye without dissection. In some cases the two fasciculi are separated from each other, and even intermingled with those of the crus; in such their pursuit is difficult and intricate, in others they pass as two distinct packets, and are more easily followed. As they proceed they approach the larger packet, and, having traversed the crus, are attached below and behind it to the same part as the great packet is. When the adjacent matter has been cleared away carefully, this part appears as a yellowish, longitudinal tract of fibres, which can be traced upwards and downwards; upwards it is continued beneath the superior peduncle of the cerebellum, downwards it descends from behind the pons into the spinal bulb, and soon divides into two cords, one for each column of the medulla spinalis. As this tract enters the spinal bulb it is situated deep before the floor of the ventricle and behind the superior attachment of the seventh pair; externally this tract corresponds to the peduncles of the cerebellum, and is united internally to the cineritious matter in the ventricle. At the point of attachment of the nerve, this tract presents an eminence which may be considered the origin of the nerve, although cords can be traced from this to more remote parts. The two parts or cords into which this tract separates have a remarkable course; the anterior is large, and descends to the inferior peduncle of the cerebellum, and joins the posterior spinal column external to the olivary body, but unconnected to it; the posterior smaller cord descends behind the inferior peduncle, on the posterior aspect of the spinal bulb, enters the posterior fissure between the posterior pyramids, descends along it for some way, and joins the back part of the anterior spinal columns." From this statement, then, it would appear that the apparent origin of both roots of this nerve is from the eminence on the longitudinal tract, in front of the floor of the fourth ventricle and of the auditory nerve, and that this tract is connected inferiorly by two fasciculi to the anterior and posterior spinal columns. From this origin the two

portions of the nerve may be traced upwards to the surface of the cerebellum, through the transverse slits in which they escape; the inferior or larger portion appears constricted by the fibres of the crus, and a transverse fasciculus separates it from the smaller portion. The entire nerve then passes outwards and forwards beneath the inner border of the tentorium, also beneath the superior petrosal sinus, and over a depression on the internal and anterior part of the petrous bone, through a large oval hole or canal in the dura mater, formed by the separation of that membrane into two layers; the nerve then expands on the surface of the petrous bone in the middle fossa of the base of the cranium into the Casserian ganglion: the nerve between the brain and the edge of the petrous bone is loosely enveloped by the arachnoid membrane, which also lines the foramen and fossa as far as the inner edge of the ganglion; it is then reflected on the parietes; each filament of the nerve possesses a distinct neurilemma of pia mater.

The *Casserian ganglion* is of a semilunar or triangular form, the apex internally in the nerve, the base is convex, and directed forwards and outwards; the superficial lamina of the dura mater adheres very intimately to it, and most probably receives some filaments from it. When this has been removed the ganglion appears flat and dark-coloured, of a very plexiform structure, and the interstices filled with firm, dark neurine; if it be raised from the bone, the small white motor fasciculus will be seen attached to it so loosely as easily to admit of separation. From the ganglion three large branches proceed; the first, or ophthalmic, passes upwards and forwards, and enters the orbit through the foramen lacerum; it supplies the eye and its appendages with sentient filaments; the second, or superior maxillary, passes directly forwards through the foramen rotundum, and is distributed to the face, supplying it also with sentient nerves. The inferior maxillary is the largest branch, and is joined by the motor; this nerve, therefore, is a compound nerve; it descends directly through the foramen ovale; its motor portion is distributed to the muscles of mastication, and its sensitive to the tongue, lower jaw, lip, chin, &c.

The SIXTH, or ABDUCENTES, are of a middle size between the third and fourth; each *arises* from the outer side of the corpus pyramidale a little below the pons, passes forwards and outwards, pierces the dura mater behind the body of the sphenoid bone, traverses the cavernous sinus on the outer side of the carotid artery, and is there joined by two or three small filaments from the superior cervical ganglion of the sympathetic nerve; it then enters the orbit through the foramen lacerum, and is distributed to the external rectus muscle; the root of this nerve may be traced through the pyramids into the grey neurine and olivary tracts; the basilar artery is between the nerve of the right and left side.

The SEVENTH PAIR consists of two portions, the PORTIO DURA, or the FACIAL NERVE, and the PORTIO MOLLIS, or the AUDITORY NERVE. The *facial* nerve is the smaller of the two, and is anterior and internal to the auditory; it *arises* from the lower edge of the side

of the pons below the crus cerebelli, behind and above the corpus olivare, and in front of the restiform, through which its fibres sink into grey neurine, which probably brings it into communication with the roots of the fifth pair.

The *auditory nerve*, or portio mollis, is the posterior and the larger; it *arises* by several striæ from the side of the calamus scriptorius and from a small mass of grey substance on the back of the corpus restiforme; these unite into one soft, white cord, which passes forwards and outwards round the restiform body, and joins the portio dura: the two nerves then pass outwards, the mollis being larger than the dura; the latter is contained in a groove in the former, and a small blood-vessel runs between them; they both enter the meatus auditorius internus, where they soon separate. The facial nerve runs along the aqueduct of Fallopius, which opens inferiorly at the stylo-mastoid foramen; the nerve then turns forwards, and is distributed to the side of the face. The auditory nerve descends obliquely forwards, and is distributed to the cochlea and semicircular canals.

The EIGHTH PAIR, or PAR VAGUM, consists of three portions, the GLOSSO-PHARYNGEAL, the smallest; the PNEUMOGASTRIC, the largest; and the SPINAL ACCESSORY, which is of a medium size.

The *glosso-pharyngeal arises* by four or five delicate filaments between the corpus olivare and restiforme; these unite into one small nerve.

The *pneumogastric*, or the vagus, *arises* by ten or twelve filaments below the last, but in the same groove; these also unite into one nerve, which, with the glosso-pharyngeal, passes forwards and outwards to the foramen lacerum posterius or jugulare, where they are joined by the third portion.

The *spinal accessory nerve arises* from the side of the medulla spinalis, between the roots of the spinal nerves, by several delicate fibres, which commence a little above the middle of the cervical portion of this nerve; from this origin it ascends behind the ligamentum denticulatum, and very near the posterior roots of the spinal nerves; it frequently receives filaments from the roots of these nerves: having passed through the foramen magnum, it joins the other divisions of the eighth pair, the inferior artery of the cerebellum having previously passed between them. The eighth pair of nerves passes through the jugular foramen anterior to the vein, and immediately separates into its three portions, the particular course of each of which shall be considered afterwards. The spinal accessory is distributed to the muscles on the side of the neck; the glosso-pharyngeal to the pharynx and the tongue, and the pneumogastric to the lungs and stomach.

The NINTH or LINGUAL NERVE *arises* by six or eight fine filaments between the corpus olivare and pyramidale, and behind the vertebral artery; these unite and pass through the lingual or anterior condyloid hole in the occipital bone. The ninth pair of nerves are distributed to some of the inferior muscles of the neck, also to those of the tongue.

Nerves are either *simple* or *compound*. By simple, is meant a nerve

possessed of but one property; by compound, a nerve possessed of two properties. The properties with which nerves are endowed, so far as we are positively informed, are two, viz., *sensation* and *volition:* nerves endowed with the former are called *sensitive nerves;* those with the latter are named *motor*.

Of the nine pair of cerebral nerves, some are simple, some compound; the simple are the first, second, third, fourth, sixth, and ninth; the first and second are simple nerves of sense; the third, fourth, sixth, and ninth, are simple nerves of motion. The fifth, seventh, and most probably the eighth, are all compound nerves; thus the ganglionic portions of the fifth are sensitive, while the non-ganglionic are motor; the portio mollis of the seventh is a nerve of sense, but the portio dura is motor. The peculiar position of the origin of the eighth from the side of the medulla oblongata and spinal cord would imply that it partook of the double properties of these organs, that is, of their anterior and posterior surface, and that it is a compound nerve; accordingly, in experiments on living and on recently killed animals, irritation applied to the divisions of the eighth pair has in the former state of the animal produced pain, and in the latter muscular contraction.

CHAPTER III.

DISSECTION OF THE NERVES.

The course and ultimate distribution of most of the nerves have been already mentioned in the description of the muscles, and of the several regions of the body; in the present chapter they shall be considered in a systematic manner, commencing with the cerebral nerves, the origins of which have been already described.

SECTION I.

DISSECTION OF THE CEREBRAL NERVES.

I. Olfactory Nerves.—From the bulb, which each of these nerves forms at the side of the crista galli, several branches descend into the nose, through the foramina in the cribriform plate; they may be divided into the internal, middle, and external. The *internal branches*, about ten in number, descend in grooves along the septum, subdivide into many filaments, which form a plexus with each other in the mucous membrane; some of these can be traced nearly to the floor of the nose. The *middle branches* are distributed to the mucous membrane lining the roof of each nostril. The *external branches* descend along the grooves on the turbinated bones, dividing and communicating frequently with each other, so as to form numerous plexuses, which are lost in the pituitary membrane. All the branches of the olfactory nerves are very soft in the cranium, but, in passing through the ethmoid bone, they each receive a sheath from the dura mater, which is ultimately lost in the external layer of the mucous membrane.—(*See* the Anatomy of the Nose.)

II. Optic Nerves.—Each optic nerve, on passing through the optic foramen, becomes round, having previously been of a flattened form, and is surrounded by a strong sheath derived from the dura mater. It is next encircled by a tendinous ring, formed by the origin of the four recti muscles which surround it, from the fleshy portions of which it is separated by a considerable quantity of soft fat, in which several nerves and vessels are lodged. From the optic foramen this nerve proceeds forwards and a little inwards, so as to be slightly curved, the convexity outwards; at the back part of the eye it is very much con-

stricted; it then pierces the sclerotic and choroid membranes, and terminates in the retina.—(*See* Anatomy of the Eye.) The ophthalmic artery accompanies this nerve; in the optic foramen it lies beneath it; it afterwards twines around it to its internal side. Near the sclerotic a small branch, named arteria centralis retinæ, pierces the sheath, and runs in the axis of the nerve to the internal surface of the retina, and to the hyaloid membrane. This will be seen in the dissection of the eye. In addition to the dura mater, this nerve possesses a fine but dense neurilemma, which sends in numerous processes to form small canals or tubes, in which the nervous substance is contained; so that this nerve is not composed, like the motor nerves, of several filaments placed parallel to each other. If the white substance be removed by maceration in an alkali, its tubular structure will become obvious.

At the side of the body of the sphenoid bone the following four nerves of the orbit lie, according to their numerical order, viz., most superiorly the third nerve, then the fourth, next the ophthalmic branch of the fifth, and most inferiorly the sixth, or the abducens nerve. They are here closely united to each other, and form what may be termed the *orbital plexus;* when they have arrived at the anterior clinoid process they separate, and, as they are entering the foramen lacerum orbitale, are related in the following manner: most superior is the fourth, then the frontal branch of the ophthalmic, next the superior division of the third, external to which, and near to the outer wall of the orbit, is the lachrymal nerve of the ophthalmic; below these are the nasal nerve and the inferior division of the third; and, lastly, lying inferior to all, and holding the same relation to them as it did at the cavernous sinus, is the sixth nerve; to this last the ascending branches of the superior cervical ganglion of the sympathetic nerve, which form the carotid plexus, are intimately connected, and several filaments from these can also be traced to the other nerves of the orbital plexus.

To expose these four nerves the orbit should be opened, which is to be done by dividing the orbital plate of the os frontis by two cuts with the saw; these should unite in the optic foramen; the internal is to be carried forward to the superciliary arch, about half an inch external to the internal angular process; the external incision is to be carried deeply through the malar bone; a slight blow of the hammer will then throw forwards the roof of the orbit, and the bone will separate easily from the periosteum, which is then to be carefully dissected off.

III. The THIRD NERVE, or motor oculi, in passing through the foramen lacerum orbitale, divides into two branches, a superior and inferior. The *superior*, or the *smaller*, passes between the heads of the external rectus muscle, above the optic and nasal nerves, and divides into two branches, the smaller and shorter one of which supplies the superior rectus, the other the levator palpebræ muscle. The *inferior*, or the *larger branch*, passes below and to the outside of the optic nerve, and divides into three branches, an internal, middle, and ex-

ternal. The *internal* is the largest; it passes obliquely downwards forwards, and inwards, beneath the optic nerve, and, getting to its internal side, is distributed to the internal rectus; the *middle* to the inferior rectus; and the *external*, which is the longest, passes downwards and forwards on the surface of the inferior rectus, between it and the globe of the eye (it gives no filaments to this muscle), and is lost in the inferior oblique muscle. This last branch gives off from its root a small, short filament to the ophthalmic ganglion. All the branches of the third pair are distributed to the ocular surfaces of the five muscles they supply.

IV. The Trochleator, or fourth nerve, having entered the orbit by the foramen lacerum, ascends obliquely forwards and inwards above the levator palpebræ and the superior rectus, and immediately beneath the periosteum; it is distributed by four or five fine branches to the upper or orbital surface of the superior oblique muscle. As this delicate nerve is passing along the outer side of the cavernous sinus, it lies between the third pair and the ophthalmic branch of the fifth, below the former and above the latter and the sixth; as it enters the orbit it mounts above the third and fifth; a fine filament usually connects it to the lachrymal branch of the latter; it is then the highest nerve in the orbit, both it and the frontal being immediately beneath the periosteum; previous to entering the oblique muscle its size is somewhat increased; while along the cavernous sinus it communicates with the ophthalmic nerve and with the carotid plexus of the sympathetic; from this latter communication some recurrent branches pass to the surrounding dura mater and to the tentorium.

V. The Trigemini, or the fifth pair, having formed the semilunar or Casserian ganglion, divides into three large nerves, viz., the ophthalmic, the superior, and inferior maxillary.

The Ophthalmic Nerve passes along the outer side of the cavernous sinus, below the third and fourth, and above the sixth. In this situation it receives some filaments from the fourth and from the sympathetic nerve. As it approaches the foramen lacerum orbitale, it divides into three branches, the lachrymal, frontal, and nasal, which are situated with respect to the other nerves as above described.

The *lachrymal nerve*, the smallest and most external of the three, usually anastomoses with the trochleator in the foramen lacerum; it passes forwards and outwards to the lachrymal gland, above the external rectus muscle, and beneath the periosteum, but gives no branches to the former; it is surrounded by fat, and accompanied by the lachrymal artery; it sends off, in this course, two small branches, one through the spheno-maxillary fissure, to communicate with the superior maxillary nerve, and the other through the malar bone, to communicate with the facial nerve. Near the gland the lachrymal nerve enlarges, and sends four or five branches to its inferior surface, and it then terminates in several fine soft filaments, which are lost in the conjunctiva, lining the superior palpebra, and in the cellular membrane between the lachrymal gland and malar bone.

The *frontal nerve* enters the orbit, between the superior rectus and the periosteum, along with the fourth, but inferior and external to it; it passes forwards on the upper surface of the levator palpebræ muscle, and near the superciliary arch it divides into two branches, an internal and external; the *internal*, or *supra-trochleator* nerve, the smaller branch, runs forwards and inwards above the trochlea of the superior oblique muscle, and is distributed to the corrugator supercilii, orbicularis palpebrarum, and occipito-frontalis muscles, also to the integuments of the forehead and superior eye-lid; it communicates with the infra-trochleator branch of the nasal nerve, and sends one or two small filaments into the frontal sinus. The *external* branch, or the *supra-orbital* or *proper frontal nerve*, appears, both in size and in direction, as the continuation of the original trunk; it passes through the superciliary notch or foramen along with the frontal artery, ascends on the forehead, divides into two branches, which subdivide into numerous filaments; these chiefly ascend in the muscles and integuments of the scalp; many of them take a very long course, and communicate with the portio dura, with the occipital nerves, and with those from the opposite side. Both the frontal and lachrymal are nerves of sensation.

The *nasal nerve* separates from the frontal behind the orbit, enters this cavity beneath that branch, and between the two heads of the external rectus; it then runs obliquely forwards and inwards above the optic nerve and below the superior rectus muscle, along with the ophthalmic artery, continues its course along the inner side of the orbit below the superior oblique muscle, and divides into two branches, the external or the infra-trochleator nerve, and the internal or the nasal. The *nasal nerve*, previous to its entrance into the orbit, is joined by a filament from the sympathetic nerve; on the outer side of the optic, and just as it enters this cavity, it gives off a delicate branch about an inch in length, which runs along the outer side of the optic nerve, and forms the long root of the lenticular ganglion; as the nasal nerve passes over the optic it gives off three ciliary nerves. The *infra-trochleator* nerve runs forward beneath the pulley of the oblique muscle, and divides into several filaments, which communicate with the supra-trochleator nerve, and are distributed to the lachrymal passages, and to the integuments and muscles on the side and dorsum of the nose. The *internal* branch, or the *proper nasal*, passes through the anterior of the internal orbital holes into the cranium, crosses the cribriform plate, and descends by the side of the crista galli into the nasal fossæ, where it divides into posterior and anterior filaments; the former are distributed to the septum, the latter descend behind the nasal bones, and are lost in the integuments at the tip of the nose. The sixth pair of nerves should be next dissected, as it is distributed along with the preceding nerves in the orbit.

Sixth, or Abducens Nerve, after traversing the cavernous sinus (where it is joined by branches from the carotid plexus of the sympathetic nerve), on the outer side of the carotid artery, enters the orbit through the lower part of the foramen lacerum, between the origins of

the external rectus, beneath the other orbital nerves, and above and outside the ophthalmic vein; it then passes forwards and outwards, and is distributed to the ocular surface of the external rectus muscle. All the motor nerves in the orbit are distributed to the same surface of their respective muscles, except the fourth, which spreads its branches on the orbital surface of the superior oblique muscle.

The student should next examine the *lenticular* or *ophthalmic ganglion*. This small body is situated near the back part of the orbit, between the optic nerve and the external rectus muscle; it is of a reddish colour, and surrounded by soft fat; its posterior superior angle receives the long filament before mentioned from the nasal branch of the ophthalmic, a small filament from the sympathetic accompanies this, and its posterior inferior angle receives the short twig from the inferior oblique branch of the third pair. These two nerves are described by some as the roots of this ganglion, others consider the lenticular or opthalmic ganglion as one of the cranial ganglia of the sympathetic nerve. I prefer describing it in direct connexion with the two principal nerves connected with it, the third and fifth, and which thus become connected in function, while the sympathetic filament is only a branch of communication, as in the case of the spinal ganglia. From the anterior angles of the ganglion two fasciculi of fine nerves proceed, termed the *ciliary;* the inferior fasciculus is larger than the superior. The *ciliary nerves* are about twenty in number: eight or ten in the inferior fasciculus, about six in the superior, and three or four internally, which arise from the nasal nerve. The ciliary nerves twine along the surface of the optic nerve, accompanied by the ciliary arteries, and pierce the back part of the sclerotic coat; they then become flat, and proceed forwards in parallel grooves on the inner surface of that membrane, with very little connexion to the choroid coat. At the anterior part of the eye they meet the ciliary ligament; in this substance most of these nerves appear to be lost, but really are not so, as one or two branches may be traced through this into the iris, in which they divide into numerous filaments of extreme minuteness.

The several nerves of the orbit have different offices to discharge. No less than *seven nerves* are engaged in the optic apparatus, viz., the second, third, fourth, sixth, one division of the fifth, the seventh, and the sympathetic. The respective office of each of these is probably as follows: the second is the sentient nerve, for vision; the third, fourth, and sixth supply the orbital muscles with their voluntary or motor power; branches of the seventh also impart the same to the sphincter oculi, or orbicularis palpebrarum; the ophthalmic portion of the fifth endows with sensation all the parts within the orbit, also the interior of the eye, the surface of the globe, the palpebræ, the lachrymal apparatus, the integuments of the forehead, &c. &c. The filaments of the sympathetic nerve serve to connect more closely the component parts of the orbital plexus with each other, and with the system at large; they also probably serve some useful purpose in reference to the ophthalmic ganglion, to which they are connected through the nasal nerve, the sympathetic being directly connected to or engaged in the

principal ganglions in the body. The lenticular or ophthalmic ganglion also is interesting as to its connexions, as it in this respect resembles the ganglions on the spinal nerves; thus it has two roots, the third pair supply the motor, while the nasal filament of the fifth, which also carries the sympathetic connexion, imparts the sensitive quality. The distribution also of the branches of this ganglion is in accordance with its component elements, inasmuch as they are distributed to one of the most delicately sensible, and to one of the most active structures in the whole range of the animal economy, namely, the iris, the muscular nature of which, too, may be inferred from the very circumstance of this peculiar nervous supply.

The student should next proceed to examine the superior and inferior maxillary nerves, the remaining divisions of the fifth pair. Remove the outer wall of the orbit with the saw or hammer, make a vertical section of the nose and face, and separate the globe of the eye and its muscles from their attachments; below the cavity of the orbit the superior maxillary nerve may be seen.

The SUPERIOR MAXILLARY NERVE is larger than the ophthalmic, passes from the middle of the Casserian ganglion forwards through the foramen rotundum into the pterygo-maxillary fossa; it here sends off several branches, and then, passing through the spheno-maxillary fissure, continues its course forwards along the infra-orbital canal to the face, where it terminates in the infra-orbital nerves. In the pterygo-maxillary fossa it first sends down two small branches along the back part of the superior maxillary bone; these, after a short course, unite in a small triangular, reddish substance, called the *spheno-palatine ganglion*, or the *ganglion of Meckel.* This ganglion is imbedded in fat, surrounded by the branches of the internal maxillary artery, and is situated on the external side of the nasal plate of the palate bone, which separates it from the cavity of the nose, behind the tuberosity of the superior maxillary bone, and in front of the pterygoid processes. Three sets of branches proceed from this ganglion, an inferior, internal, and posterior. First, the *inferior*, or the *palatine nerves*, descend in the bony canal of that name, send some small twigs through this canal to the spongy bones, and near the palate separate into three filaments, an anterior, middle, and posterior; the anterior is the largest, passes forwards in a groove within the alveoli and above the mucous membrane, supplying the latter, and sending small branches to the bone and teeth, and, finally, enters the foramen incisivum by a very fine filament, which communicates with nerves on the septum nasi; the middle and posterior filaments of the palatine nerves are distributed to the amygdalæ, the soft palate, and the uvula; the posterior usually descends through a distinct osseous canal in the pterygoid portion of the palate bone. The *internal* branch, or the *spheno-palatine* nerve, is very short, passes through the spheno-palatine hole into the upper and back part of the nose, and divides into five or six branches; the most of these pass immediately into the mucous membrane, covering the superior and middle spongy bones; one branch, called the *naso-*

palatine nerve, or *nerve of Cotunnius*, passes beneath the sphenoidal sinus across the roof of the nose, and descends obliquely forwards along the septum nasi as far as the foramen incisivum, where it communicates with the anterior palatine branches, and where some anatomists describe a small ganglion (*naso-palatine*) to exist; this, however, in the human subject, can seldom be distinguished from the surrounding fat and vessels. The third, or posterior branch of the ganglion, is the *Vidian* or *superior petrosal nerve*. This passes backwards through the Vidian canal above the internal pterygoid plate, and sends some small filaments into the sphenoidal sinus; it then perforates the cartilaginous substance that closes the foramen lacerum anterius, enters the cranium, and divides into two branches, an inferior and superior; the inferior or carotid branch enters the cavernous sinus, and joins the plexus formed around the artery by the ascending branches of the superior cervical ganglion of the sympathetic: the superior or petrosal branch runs backwards and outwards beneath the dura mater and Casserian ganglion in a groove on the petrous bone, enters the hiatus Fallopii in this bone, and becomes attached to the portio dura nerve, the point of junction being marked by a small gangliform expansion. The Vidian nerve accompanies the portio dura as far as the back part of the tympanum; it then leaves it, receives the name of *corda tympani*, and enters the tympanum a little below the pyramid; invested by mucous membrane, it now proceeds forwards between the long leg of the incus and the handle of the malleus; to the latter it is firmly connected; it then escapes by a canal which opens near the internal extremity of the glenoid fissure; it next runs downwards, inwards, and forwards, joins the gustatory nerve, and continues attached to it as far as the submaxillary gland; it now leaves the gustatory nerve, and unites with some filaments from it in the *submaxillary ganglion*, which is situated near the posterior edge of the submaxillary gland, and from which a number of filaments proceed; these form a plexus which supplies this gland. As this Vidian or recurrent nerve takes this singularly intricate course, it goes under different names in different situations, and it serves to maintain several interesting communications; for example, it connects the cervical ganglions of the sympathetic nerve with the spheno-palatine, also the latter with the submaxillary ganglion; it also joins the superior and inferior maxillary nerves to one another, and both to the portio dura; the nervous supply to the muscles of the palate also is thus connected to the portio dura, the great muscular nerve of the face, &c. Some anatomists deny the continuity of the Vidian and corda tympani nerves, and consider them as distinct, the Vidian as a connecting branch between the spheno-palatine or Meckel's ganglion and the portio dura, and the corda tympani as a branch of the latter, arising lower down than the end of the Vidian, then proceeding across the tympanum, and, finally, joining the gustatory nerve and the submaxillary ganglion.

The superior maxillary nerve, immediately after, and sometimes previous to giving off the two descending branches which join the spheno-

palatine ganglion, sends off the *orbital branch;* this ascends through the spheno-maxillary fissure, and divides into two branches, the malar and temporal. The *malar* communicates with the lachrymal nerve, passes through a small canal in the malar bone, and is distributed to the integuments and muscles covering the malar bone; the *temporal* branch also passes through the malar bone into the temporal fossa, pierces the temporal fascia, becomes cutaneous, and, joining some branches of the facial nerve, it accompanies the temporal artery, and is lost in the integuments on the side of the head. The superior maxillary nerve next gives off the *posterior dental nerves;* these are two or three branches, which wind round the tuberosity of the maxillary bone, enter small foramina, which lead to the posterior alveoli in this bone, and supply the molar teeth; some branches also supply the gums and the buccinator muscle. As the *infra-orbital nerve*, which is the last branch of the superior maxillary, proceeds along the floor of the orbit, it sends off some small filaments to the fat and muscles in this region, also the *anterior-dental;* this nerve descends in an osseous canal along the forepart of the antrum, to the lining membrane of which it gives some fine filaments, and is then lost in several branches which supply the canine and incisor teeth: the infra-orbital nerve then escapes through the foramen of the same name, beneath the orbicularis palpebrarum and levator labi superioris alæque nasi muscles. It here divides into several branches, which are distributed to the face; some of these ascend to the palpebræ, others pass outwards to the cheek, and the largest branches descend to the ala nasi and to the upper lip; these different branches have frequent communications on the side of the face with the portio dura, on the nose with the nasal nerves, and on the buccinator muscle they form a plexus with each other and with the buccal and facial nerves.

The Inferior Maxillary Nerve.—This, which is the third and largest branch of the fifth pair, immediately descends from the ganglion, through the foramen ovale, into the zygomatic fossa, behind the external pterygoid muscle, where it divides into two large branches, a superior or external, and an inferior or internal. The inferior maxillary nerve consists of two portions, one is plexiform and sensitive, and proceeds from the Casserian ganglion; the other is concealed by this, and consists of white parallel fibres, which do not pass through the ganglion; this is the motor portion of this nerve. In the zygomatic fossa this small, deep portion winds round the other, becomes anterior to it, and both unite inseparably; the nerve then divides into two branches, superior and inferior. The *superior* or *external* retains the motor portion of the trunk, and immediately subdivides into five branches, viz., the two deep temporal, masseteric, buccal, and pterygoid. The *inferior* or *internal* division of the nerve is the larger, and subdivides into the auricular, inferior dental, and gustatory nerves, which are probably all nerves of sensation. First, the *deep temporal nerves* are two in number, an anterior and posterior; they ascend between the temporal bone and muscle, and are lost in the latter; some small

branches escape through the temporal fascia, and communicate with the cutaneous temporal nerves. Second, the *buccal nerve* arises in general in common with one of the last; it passes forwards and downwards between the pterygoid muscles, to the external of which and to the temporal it sends some branches; it then passes between the coronoid process and the buccinator muscle, and on the latter it divides into several long branches, which form a plexus on this muscle with branches of the facial and infra-orbital nerves. Third, the *masseteric* branch descends obliquely backwards and outwards through the sigmoid notch of the inferior maxilla, between the temporal muscle and the neck of the lower jaw, close to the latter, to the articulation of which it also sends some filaments; it is lost in the substance of the masseter muscle. Fourth, the *pterygoid nerves* are two or three delicate branches, which descend to the pterygoid muscles. Thus the motor portion of the trunk of the inferior maxillary nerve can be traced into those muscular branches which supply the five great muscles of mastication.

The inferior division of this nerve divides into three branches, viz., the auricular, dental, and lingual or gustatory nerves. First, the *auricular* or *temporo-auricular* branch arises by two or three roots, between which the arteria spinosa ascends. This nerve passes backwards and outwards behind the neck of the lower jaw, and before the meatus auditorius; it here communicates with the facial nerve, and sends small filaments to the meatus and to the cartilages of the ear, also to the articulation of the lower jaw; it then divides into several branches; some ascend through the parotid gland over the zygoma, follow the divisions of the temporal artery, and communicate with the facial nerve, and are lost in the integuments on the anterior and lateral parts of the head; others descend in the gland, send small filaments into the tympanum, and communicate with the facial, dental, and ascending branches from the cervical plexus. Second, the *inferior dental nerve* separates from the gustatory, and is again connected to it by a small twig; it then descends external to it, at first between the two pterygoid muscles, then between the lower jaw and the internal pterygoid; it is here separated from the latter by the internal lateral ligament; about the middle of the internal surface of the ramus of the jaw it sends off a small filament, the *mylo-hyoid nerve;* this descends obliquely forwards, confined in a groove in the bone by an expansion from the internal lateral ligament; near the chin it divides into small branches for the mylo-hyoid, genio-hyoid, and digastric muscles, the adjacent cellular tissue, and lymphatic glands. The dental nerve then enters the canal in the lower jaw, which extends from the dental foramen obliquely forwards beneath the teeth as far as the chin. In this course this nerve, which is accompanied by the dental vessels, supplies each of the molar and canine teeth with soft, delicate twigs; and at the mental foramen it divides into two branches, one continues its course within the bone beneath the incisor teeth, the other is the *mental nerve;* this escapes by the mental foramen, bends upwards, and di-

vides in a radiated manner into several branches, which pass to the muscles, mucous membrane, and integuments of the lower lip, and communicate with the facial nerve. Third, the *lingual* or *gustatory nerve* is smaller than the dental, to which it is connected by a short branch which encloses a space through which the internal maxillary artery passes. Beyond this branch of communication the corda tympani (which has been before traced from Meckel's ganglion) joins the gustatory nerve at an acute angle; the latter is increased in size at this spot. The gustatory nerve is here situated between the external pterygoid and the muscles of the palate and pharynx; it then descends obliquely forwards between the internal pterygoid and the ramus of the lower jaw; it next turns forwards above the sub-maxillary gland and the mylo-hyoid muscle, and lies on the mylo-hyoidean attachment of the superior constrictor of the pharynx and on the mucous membrane of the mouth and the stylo-glossus muscle, and accompanies the Whartonian duct; it then ascends above the sublingual gland, and becomes attached to the lateral and anterior parts of the tongue. In this arched course the gustatory nerve gives off, first, one or two small filaments to the internal pterygoid muscle; second, several to the tonsils, to the muscles of the palate, to the upper part of the pharynx, and to the mucous membrane of the gums; third, the corda tympani, and some accompanying filaments to form a plexus which supplies the sub-maxillary gland; fourth, a few branches which descend along the hyo-glossus muscle to communicate with the ninth or the lingual nerve; fifth, a fasciculus of nerves to the sublingual gland, and to the surrounding mucous membrane; lastly, at the tongue it divides into several branches, some pass deep into the tissue of this organ, others, long, fine, and soft, rise towards its surface, and are lost in the mucous membrane and in the small conical papillæ near its tip.

In addition to the four ganglions already described in connexion with the fifth pair of nerves, namely, the Casserian ganglion with the trunk of the nerve, the lenticular or orbital ganglion with its first division or the ophthalmic nerve, the spheno-palatine or Meckel's ganglion, with its second division or superior maxillary nerve, and the sub-maxillary ganglion, with its third division or inferior maxillary nerve, another in connexion with the last-mentioned nerve has of late years been described by Arnold under the name of OTIC GANGLION. This body, small and indistinct, is situated immediately below the foramen ovale, on the inner side of the inferior maxillary nerve, external to the Eustachian tube and tensor palati muscle, and in front of the middle artery of the dura mater; it is connected by very short filaments to the maxillary nerve and to its pterygoid and auricular branches, the latter being a sentient, the former a motor nerve; it is also connected to the soft branches of the sympathetic nerve which accompany the spinous artery; it gives off, first, a small filament to the tensor palati muscle; second, a larger one to the tensor tympani muscle, lodged in the canal in the petrous bone above the Eustachian tube; and, third, the small, superficial, petrosal nerve. This enters

the cranium through a small canal between the petrous bone and spinous process of the sphenoid, passes backwards on the surface of the former, enters a minute foramen in front of the hiatus Fallopii, and divides into two filaments; one joins the ganglionic expansion at the junction of the large petrosal or Vidian nerve with the portio dura, the other enters the tympanum, and joins the tympanic branch of the glosso-pharyngeal in the tympanic plexus. This latter branch Arnold describes as one of the origins of the otic ganglion, and compares it to the long sentient root in the ophthalmic ganglion derived from the nasal nerve, while the short motor root unites it to the inferior maxillary nerve. It requires much time and care to expose the nervous filaments just mentioned; a vertical section of the fœtal head is best suited for the dissection; the inferior maxillary nerve should be exposed as it is passing through the foramen ovale, and as the motor is joining the sentient portion; the dissection should be made on the inner or pharyngeal side of the nerve; connected to it, in this situation, will be found a quantity of reddish, fibro-cellular tissue, traversed by the fine nervous filaments above-mentioned; but, as far as my observation extends, a distinct ganglion is by no means so evident as is represented by Arnold and the other writers who have followed his description. The same remark will apply to the spheno-palatine and to the sub-maxillary ganglions; but the lenticular or ophthalmic ganglion is always to be found, though variable as to size and colour, in some being pale and flat, in others red and round, like a small berry.

The SIXTH PAIR of nerves have been described at page 533.

VI. FACIAL NERVE, or PORTIO DURA of the seventh pair. This nerve first traverses the meatus auditorius internus in a direction outwards; on the inner wall of the tympanum, and between the vestibule and cochlea; it then enters the semicircular canal, named aqueduct of Fallopius. This canal leads from the meatus at first in a horizontal direction backwards, then outwards, above the fenestra ovalis and at the back part of the tympanum; it then descends vertically to the stylo-mastoid foramen on the lower surface of the petrous bone; the nerve then bends forwards into the parotid gland, and, after a course of about half an inch in length, divides behind the ramus of the jaw into its two terminal branches, the temporo-facial and cervico-facial. In the meatus internus the portio dura, or facial, lies above the portio mollis, or auditory nerve, in a groove in the latter, a small artery intervening. If the upper part of the meatus be removed with the bone forceps, the early course of the nerve is exposed; in raising it out of this groove fine filaments are seen connecting it to the portio mollis. These are considered by most anatomists as communicating nervous filaments. I have some doubts, however, whether these connecting fibres are really nerves, or only fine vessels and areolar tissue; if nerves, they present the singular peculiarity of union between a nerve of motion and one of special sense. Opposite the hiatus Fallopii the portio dura is joined by the great petrosal or Vidian nerve from Meckel's gan-

glion, and by the lesser petrosal nerve from the otic ganglion, also by a small filament from the sympathetic nerve, which accompanies the spinous artery, and is named the external petrosal nerve. At the junction of these three branches with the portio dura, a flattened ganglionic expansion is observed, in which the exact arrangement, and from which the further course of these small connecting filaments, are differently described by different anatomists. Some affirm that in this ganglion they are all blended together, and cannot afterwards be distinguished from the portio dura; others maintain that the large petrosal or Vidian nerve can be separated from the portio dura, though connected to it in a plexiform manner, and can be traced into that remarkable branch called the corda tympani, which is afterwards connected in a similar plexiform manner to the gustatory nerve. From my own dissections of these nerves, I am induced to adopt the latter opinion. This remarkable union at the back of the hiatus Fallopii must serve to maintain free communication between the facial or motor nerve and the fifth or the sentient nerve, analogous to those more obvious communications seen upon the face between the terminating filaments of these nerves. This connexion, also, so close to the tympanum, which contains the ossicula and musculi auditus, may be designed to impart the twofold properties of sensation and of motion to this apparatus, through the filaments which connect the portio dura subsequently to the tympanic plexus: thus the organ of hearing, like that of vision, will be furnished with the three sets of nerves, one for special sense, one for sensation, and one for motion. In its course along the aqueduct of Fallopius it sends a small branch, the *tympanic*, into the tympanum, close to the neck of the stapes; and lower down it gives off the *corda tympani;* this first ascends in a bony canal on the back of the tympanum parallel to the aqueduct; it then enters the tympanum through a foramen between the pyramid and the osseous border of the membrana tympani, and crosses the tympanum obliquely downwards and forwards, invested by mucous membrane, and placed between the handle of the malleus and the long leg of the incus, and then escapes at the anterior inferior angle of this chamber through a small distinct foramen on the inner side of the Glasserian fissure; proceeding downwards and inwards it increases in size, probably only from receiving a stronger sheath, and soon joins the gustatory nerve between the pterygoid muscles; in this nerve it appears intimately connected with its general fibres; it is by dissection alone that the connexion can be unravelled, and then it will be seen to present a plexiform appearance through its whole course, at one time receiving filaments from the gustatory, at another giving them off, so that it is not a separate or independent filament throughout this course; below the angle of the jaw it separates from the trunk of the gustatory, and, accompanied by some filaments from the latter, enters the sub-maxillary ganglion. Near the origin of the corda tympani the portio dura is joined by one or two filaments from the auricular branch of the pneumogastric nerve, and

still lower down by one from the glosso-pharyngeal. As it escapes through the stylo-mastoid foramen it gives off three branches, the posterior auricular, stylo-hyoid, and sub-mastoid or digastric; the first, or the *posterior auricular*, bends upwards and backwards behind the cartilage of the ear, to which it sends several long branches; others also pass backwards to the integuments covering the mastoid process and the occipital bone; the second, or the *stylo-hyoid* nerve is distributed to the digastric and styloid muscles, and anastomoses with the sympathetic and glosso-pharyngeal nerves; the third, or the *sub-mastoid* or *digastric branch*, perforates the posterior belly of the digastric, supplies it with several filaments, and then communicates with the glosso-pharyngeal nerve around the jugular vein, close to the base of the cranium; other filaments descend, and join the laryngeal branches of the pneumogastric nerve. The facial nerve then turns forwards over the external carotid artery and external jugular vein, but sometimes between these, and through the parotid gland; in this substance it divides into two large branches, the superior or larger is called the temporo-facial; the inferior, which is smaller, the cervico-facial: these two branches take different directions, but are still connected together by cross branches, which form loops and interlace with each other in a plexiform manner; this plexus is named *parotidean plexus* or *pes anserinus*. The *temporo-facial nerve* ascends obliquely forwards across the neck of the lower jaw; it first communicates with the auricular branch of the inferior maxillary nerve, and then divides into three fasciculi, the temporal, malar, and buccal. These nerves take that course which their names imply; they are all remarkable for the plexiform arrangement of their branches, and for their frequent communications with each other, and with the three divisions of the fifth pair, which are distributed to the face. The *cervico-facial nerve* descends obliquely forwards through the parotid gland towards the angle of the jaw, where it is only covered by the skin and platysma. This nerve also divides into many branches, which may be arranged in three fasciculi, the maxillary, the sub-maxillary, and the cervical; the first, or the *maxillary*, cross the ramus of the jaw and the masseter muscle, and communicate in the muscles of the lower lip with the mental nerve, and with the superior division of the seventh; the second, or *sub-maxillary*, course along the base of the jaw, sending filaments to the integuments and superficial muscles; these also communicate at the chin with the mental nerve; the third, or *cervical* branches, are very long and numerous, they are distributed to the platysma and to the superficial muscles of the neck, and communicate with several filaments of the cervical plexus. The portio dura nerve has been ingeniously supposed by Mr. Bell to be the nerve designed to excite the muscles of the face in particular conditions of respiration and in the expression of passion, &c.; hence he has named it the respiratory nerve of the face. Others, more correctly, consider it as the exclusive motor nerve of all the superficial muscles of the face, of the eye-lids, nose,

mouth, lips, ear, also of the cutaneous muscle of the neck; it communicates with the three divisions of the fifth, with the glosso-pharyngeal and par vagum, and with the cervical spinal nerves.

VII. The Auditory Nerve, or Portio Mollis of the seventh pair. This, which is a simple nerve of sense, separates from the portio dura at the bottom of the meatus auditorius internus, and then divides into two branches, an anterior and posterior; the anterior passes forwards to the cochlea, penetrates through many small openings, and is distributed to the membrane, covering its spiral laminæ, and to that lining the canal in its axis: the posterior branch passes outwards, forms a grey swelling, from which proceed several filaments to supply the membrane lining the vestibule and semicircular canals.—(*See* Anatomy of the Ear.)

VIII. Glosso-pharyngeal Nerve, the first and highest branch of the eighth pair. This small nerve passes through the foramen lacerum posterius by a distinct fibrous canal, anterior and internal to the vein, and to the other divisions of the eighth pair of nerves; it then descends between the jugular vein and internal carotid artery, passes forwards in front of the latter and behind the styloid process and muscles, but soon winds round the stylo-pharyngeus to its forepart, and descends obliquely inwards between it and the stylo and hyo-glossus to the posterior and lateral parts of the tongue. In this course this nerve forms an arch nearly parallel to those which the gustatory and lingual nerves describe; it is smaller than either of these nerves, is situated between them, but deeper than either, and has very little, if any, communication with them; it is superior to the laryngeal nerve, and ends in branches to the pharynx, to the tongue, and to the tonsil. As this nerve is passing through the jugular canal and foramen it presents two ganglions, one (the jugular ganglion) at the upper part of the canal, small, and only involving a portion of the nerve; the other (the petrous or ganglion of Andersh) is lower down, and much larger, and is lodged in a depression in the petrous bone; from this arise its principal communicating branches, to join the sympathetic, the facial, and the pneumogastric; also its *tympanic filament*, or *nerve of Jacobson*. This nerve arises from the inferior ganglion, ascends into the tympanum through a small canal in the ridge of bone between the jugular and carotid foramina; it divides into numerous branches, some join with filaments from the fifth, the facial, and sympathetic nerves, and form with these the tympanic plexus; other filaments pass along the bony canals in the walls of the tympanum in different directions, and unite some with the sympathetic in the carotid canal, others with the large petrosal nerve in the hiatus Fallopii, and another either joins the lesser petrosal nerve from the otic ganglion, or may be considered as this nerve itself. In the neck this nerve next gives off some branches to the lateral and posterior parts of the pharynx; these, together with branches from the pneumogastric and the sympathetic, form the pharyngeal plexus; others descend still lower in the neck, and unite with the sympathetic and cardiac nerves; others ascend to the amyg-

dala, and assist in forming the tonsillitic plexus. As it approaches the pharynx it gives several branches to the stylo-pharyngeus and hyo-glossus muscles, also to the superior and middle constrictors of the pharynx; several filaments pass between these to the mucous membrane of the pharynx and fauces, also to the folds or arches of the palate and to the epiglottis; the remaining branches of the glosso-pharyngeal nerve are distributed partly to the muscular substance, but principally to the large papillæ and mucous membrane at the root of the tongue. The function or office of this nerve has given rise to much difference of opinion; the lingual branches have been by some considered sentient, and the muscular or pharyngeal both sentient and motor; but the observations and experiments of Dr T. Reid (see Encyclopædia of Anatomy, art. Glosso-Pharyngeal Nerves) lead to the conclusion that it is one of common sensation, and essentially an afferent nerve, conveying the impressions made on the mucous surface to the medulla oblongata, which there excite the reflex motor powers in other nerves and in the muscles of the fauces and pharynx.

Pneumogastric Nerve, or nervus vagus. This large compound nerve passes through the foramen lacerum in a fibrous canal in common with the spinal accessory, but distinct from the last described nerve, and anterior to the jugular vein. In the foramen it presents a ganglionic expansion, and below it a gangliform swelling near an inch in length; the latter communicates beneath the base of the cranium, and in front of the two first cervical vertebræ, with the facial, glosso-pharyngeal, spinal accessory, sympathetic, and superior spinal nerves; all these form an intricate plexus, which may be named "basilar plexus." The nerve here has the compact appearance, and sometimes the greyish tint, of a ganglion; at first it is placed anterior to the vein and to the lingual nerve; it soon, however, passes behind both, and opposite the atlas the vein separates it from the glosso-pharyngeal nerve which lies anterior to that vessel; the vagus then descends along the forepart of the neck, enclosed in the sheath of the carotid artery and jugular vein, between these vessels, but rather behind them, and more closely connected to the vein; on the right side it enters the thorax between the subclavian vein and artery, crossing the latter at right angles; on the left side it is also anterior, but nearly parallel to the subclavian artery, a little below which it crosses obliquely the back part of the arch of the aorta. In the thorax these nerves descend at first obliquely backwards behind the roots of the lungs, and enter the posterior mediastinum; they then descend along the œsophagus through the diaphragm, and end on the stomach. The branches of each may be divided into cervical, thoracic, and abdominal. The cervical branches are the communicating, the auricular, the pharyngeal, the superior laryngeal, the cardiac, and the recurrent or inferior laryngeal. Its superior ganglion, in the jugular foramen, communicates with the glosso-pharyngeal nerve, and the inferior ganglion gives off the *auricular;* this ascends in a small canal in the petrous bone external to the jugular and internal to the stylo-mastoid foramen, enters

the aqueduct of Fallopius, crosses and is connected to the facial nerve, and then, escaping from the bone between the external meatus and the mastoid process, is distributed to the integuments and to the cartilage of the ear. The inferior ganglion communicates with the several nerves before-mentioned in the basilar plexus. The *pharyngeal nerve*, or nerves, arises from the vagus near the base of the cranium, and soon receives a twig from the spinal accessory; it descends obliquely inwards, behind the carotid artery, to the side of the pharynx, divides into several branches, which communicate with those from the glosso-pharyngeal, superior laryngeal, and sympathetic; all these branches form the *pharyngeal plexus.* This plexus extends along the side of the middle and upper constrictors, and sends numerous filaments to each of these muscles, and to the mucous membrane of the pharynx and fauces. The *superior laryngeal nerve* arises from the ganglion a little below the last; it runs in an arched manner downwards and forwards behind the internal carotid artery, and below the superior cervical ganglion, with which it communicates, as also with the lingual nerve; it sends several filaments to the pharyngeal plexus, and then divides into two branches, external and internal; the external and smaller is distributed to the sterno-hyo and crico-thyroid, and to the other superficial muscles, also to the thyroid body and to the cartilages of the larynx, and communicates with the sympathetic and recurrent nerves. The internal, accompanied by a small artery, perforates the thyro-hyoid membrane, and divides into numerous branches; many of these go to the anterior surface of the epiglottis, to the glands and mucous membrane connected with it, to the arytenoid glands and muscles, and communicate with the recurrent or inferior laryngeal, beneath the ala of the thyroid cartilage; occasionally a long filament descends obliquely forwards along the side of the larynx, beneath the thyroid cartilage, to supply the crico-thyroid muscle, in case the external laryngeal branch has not done so. This internal branch of the laryngeal nerve is chiefly distributed to the mucous membrane of the glottis and larynx, and is essentially the sensitive nerve to this very sensible region. As the vagus descends it gives off fine filaments to the carotid artery, some of which unite with the sympathetic and with the cervical nerves. A little above the arteria innominata the right vagus gives off *cardiac branches*, two or three in number; these cross the carotid either before or behind it, and join the cardiac nerves from the sympathetic. The nerve of the left side does not send off so many or such large cardiac branches as that on the right side; on the left they accompany the carotid artery to the arch of the aorta, expand over it, and join the cardiac plexus. The *inferior laryngeal nerve*, or *recurrent;* that on the *right side* curves round the subclavian artery, ascends obliquely inwards, behind the carotid and inferior thyroid artery, along the side of the trachea to the larynx. At its origin it gives off some cardiac filaments, afterwards some branches to the forepart of the trachea and the thyroid gland; it then supplies the lower part of the pharynx, and ends in the posterior and lateral crico-arytenoid and

in the thyro-arytenoid muscles, also in the mucous membrane of the larynx, on which it communicates with the superior laryngeal nerve. The *recurrent nerve on the left side* is longer, as it curves round the arch of the aorta behind the ligamentous remains of the ductus arteriosus; it gives off several cardiac and pulmonary branches, and then ascends along the œsophagus, and terminates in a similar manner to that on the right side. The recurrent nerves are the proper motor nerves of the larynx, and supply all its muscles except the crico-thyroid.

The pneumogastric nerves, in their course through the thorax, pass behind the roots of the lungs, close to the bronchi, where they present an open, plexiform appearance, and send off the pulmonary and œsophageal nerves. The *pulmonary branches* arise from each vagus a little above the roots of each lung; a few of these branches pass to the forepart of the bronchial tubes, and form there a small plexus, termed the *anterior pulmonary plexus.* This plexus communicates with the phrenic and cardiac nerves, and sends its fine filaments along the pulmonary vessels to the lungs and pericardium: the greater number of these pulmonic branches pass behind the bronchial tubes to the posterior pulmonic plexus. Near the root of the lung each vagus increases in size, its fibres divide, subdivide, and reunite in an areolar or plexiform manner, forming the *posterior pulmonic plexus.* This plexus is very large, lymphatic glands and vessels are entangled in it, and several branches from the sympathetic join it; its numerous filaments accompany the bronchial tubes closely through the substance of the lungs. Below the root of each lung the fibres of each vagus again approximate, and these nerves now become attached to the œsophagus, along which they descend to the stomach, the left on its anterior, the right (which entered the chest on a plane anterior to the left) on its posterior surface: they frequently communicate with each other, so as to encircle the œsophagus with a sort of plexus, which is named the *œsophageal plexus*, or *plexus gulæ.* On the stomach, the right vagus, which is the largest, passes behind the cardiac orifice, to which it sends several small branches, which unite with some from the left or anterior nerve; these form the cardiac plexus which encircles this part of the stomach. It then sends many long filaments to the muscular and mucous coats of the stomach; these communicate very freely with the solar plexus, also with the splenic, hepatic, and renal. The left or anterior vagus spreads its branches along the anterior surface of the stomach and the lesser curvature; several of these pass along the lesser omentum to the liver and gall bladder. The pneumogastric nerves supply the pharynx, œsophagus, and partly the stomach, also the larynx, trachea, lungs, and partly the heart; they are, therefore, concerned in deglutition, voice, respiration, circulation, and digestion, and maintain important sympathies between the different organs concerned in these functions.

The NERVUS ACCESSORIUS, or spinal accessory, is the third branch of the eighth pair. This nerve, in passing through the foramen lacerum, is closely connected to the vagus by one or two filaments. Below

the base of the cranium it communicates with the ninth and sympathetic nerves, and divides into two branches, the internal and smaller of which joins the ganglion of the vagus near the origin of the pharyngeal nerve; the external branch passes outwards behind the internal jugular vein, but sometimes before it, perforates the upper third of the sterno-mastoid muscle, to which it sends some filaments; it then communicates freely with the cervical plexus, is increased in size, and supplies the trapezius, even to the scapula, &c. This is supposed to be a compound nerve, but essentially motor, and has been named by Bell "the respiratory nerve of the neck." When this and the vagus are considered in conjunction, they may be compared to a compound spinal nerve, the vagus with its ganglion being the sensitive, and the accessory the motor root; their connexion, however, may render the branches of each compound in function.

IX. The Lingual Nerve, or the ninth, is a simple motor nerve. On escaping from the anterior condyloid foramen it communicates with the eighth, the sympathetic, and the nervous arch or loop of the atlas; it is at first posterior to the vessels and nerves in this situation; it then descends between the vein and artery, soon turns forwards, and becomes superficial to them, as well as to the external carotid; it takes the arched course of the digastric muscle across the neck, hooking round the occipital artery, parallel but superficial to the lingual, and, arriving at the side of the base of the tongue above the os hyoides, it passes above the mylo-hyoid muscle, and lies on the middle constrictor and on the hyo-glossus, at the anterior edge of which it divides into several filaments; some of these plunge into the lingualis and genio-glossus muscles, others continue on to the point of the tongue, communicating with each other, and supplying the muscular substance of this organ. As the lingual nerve is bending across the neck, below the digastric tendon and around the occipital artery, it sends off a considerable branch, the *descendens colli*, or *noni*. This nerve frequently receives a filament from the pneumogastric; it descends along the fore-part of the sheath of the carotid artery; about the middle of the neck it is joined by the internal descending branches of the cervical plexus, with which it forms a small triangular plexus, the branches of which pass to the omo and sterno-hyoid and thyroid muscles; on the latter some filaments descend into the chest. Near the os hyoides the lingual nerve sends some filaments to the constrictors of the pharynx and to the stylo-pharyngeus, also a superficial branch to the thyro-hyoid muscle. On the surface of the hyo-glossus it gives off several branches to the surrounding muscles, some also to communicate and form a plexus with the gustatory branch of the fifth pair; the lingual nerve then terminates chiefly in the genio-hyo-glossus muscle, and in the general muscular structure of the tongue, which organ it supplies with motor power.

SECTION II.

DISSECTION OF THE SPINAL NERVES.

THERE are eight CERVICAL NERVES, which increase in size as they descend; the first passes out above the atlas, and is named the sub-occipital; the eighth passes out above the first dorsal vertebra. All these nerves, except the first and second, immediately outside the inter-vertebral foramina, divide into a posterior and an anterior branch; the posterior of each is smaller than the anterior, with the exception of the two first; the divisions of the first are nearly equal, but the posterior branch of the second is much larger, as it not only supplies the adjacent muscles, but also accompanies the occipital artery and its ramifications in the scalp. The posterior branches of the other cervical nerves are small, they all communicate with each other, and are distributed to the integuments and muscles on the back part of the neck; the anterior branches of the four first form the cervical plexus, and those of the four last the brachial plexus. The anterior branch of the first, or the *sub-occipital*, passes forwards above the transverse process of the atlas, in a groove beneath the vertebral artery; it supplies the adjoining small recti muscles, then descends before the atlas, and unites with the anterior division of the second cervical, so as to encircle the transverse process of that bone with a *nervous loop*. In this course the sub-occipital is united by branches to the eighth and ninth, and to the superior ganglion of the sympathetic nerve; with the latter nerve the anterior branches of all the spinal nerves regularly communicate.

The *second cervical nerve*, like the first, divides within the canal into its anterior and posterior branch. The *anterior branch*, at first between the arches or laminæ of the atlas and dentatus, passes forwards between their transverse processes, and on the outer side of the vertebral artery; it there gives off filaments to the adjacent muscles, and soon divides into an ascending and descending branch; the former joins the descending loop from the first, and the latter unites with the ascending branch from the third, and both are connected to the superior cervical ganglion of the sympathetic. The *anterior division of the third* is much larger than that of the second, but, like it, divides into an ascending and descending branch, which unite with the second and the fourth. The *fourth* divides in like manner; its descending branch is joined by a small filament to the fifth, and then divides into several branches, which pass downwards and outwards towards the clavicle and acromion, and between the sterno-mastoid and trapezius muscles. The anastomoses, between the anterior branches of the four superior cervical nerves, constitute the cervical plexus. The anterior branches of the four inferior cervical are much larger than those of the superior; they are united in a somewhat similar manner to each other, and to the anterior branch of the first dorsal, and constitute the bra-

chial plexus. These two plexuses and their branches the student may next dissect.

The Cervical Plexus is formed by the loops and communications between the anterior branches of the four superior cervical nerves, which join each other in arches, from the convexities of which branches arise that again join in a similar manner; lymphatic glands and a quantity of cellular tissue are entangled in the areolæ between these. This plexus, or rather series of plexuses, is situated on the side of the neck, on a level with the second, third, and fourth vertebræ, between the sterno-mastoid and trapezius muscles; is partly covered by the former and by the platisma and fascia; it rests upon the vertebral attachments of the levator anguli scapulæ and splenius muscle, and is external to those of the rectus anticus major and to the internal jugular vein. This plexus communicates with the superior cervical ganglion of the sympathetic above, and with the continued cord of this nerve lower down, also with the pneumogastric and lingual nerves, and with the spinal accessory; the latter may be said to assist in forming it beneath the sterno-mastoid muscle. In addition to numerous communicating and muscular filaments it sends off several long branches, which may be classed into ascending and descending; the former are superficial, the latter are both superficial and deep. The ascending superficial branches are two or three in number, viz., superficial, cervical, auricular, and occipital. The first, or *superficialis colli*, is often double; it arises about the middle of the neck, and principally from the second and third cervical nerves, bends round the posterior border of the mastoid muscle, ascends obliquely forwards along with the external jugular vein, and divides into several fine, long filaments, some of which descend in the integuments on the antero lateral regions of the neck, but the most of them ascend towards the angle of the jaw, and form cutaneous plexuses with the cervico-facial nerves. The second branch, or the *auricularis magnus*, is larger than the last, arises in the same situation, and ascends nearly parallel, but posterior to it. At the parotid gland it divides into an anterior superficial and cutaneous branch, and a posterior larger and deeper, which passes through the lower part of the gland, crosses the mastoid process, and is distributed to the external ear, and to the side and back part of the scalp. The filaments of this nerve communicate with those of the facial, not only in the integuments and fascia, but also in the substance of the parotid gland. The third branch, or *occipitalis minor*, arises near the last, from the second cervical nerve; it ascends parallel to the posterior border of the mastoid muscle to the scalp, and is distributed to the skin and to the occipito-frontalis muscle, and communicates with the great occipital and auricular nerves.

The descending branches are superficial and deep; the superficial descending branches, or *supra-clavicular*, are long and rather large; they are uncertain in number, and in exact situation, they arise from the third and fourth cervical nerves, and descend between the trapezius and mastoid muscles, and supply these in their course; they become larger near the clavicle, over which they pass. The internal

and middle branches ramify in the cellular tissue and integuments over the pectoral and deltoid muscles, and the external branches over the acromion and the clavicular attachment of the trapezius.

The deep descending branches are the muscular, the communicating, and the phrenic. The *muscular branches* arise from different parts of the plexus, and are principally distributed to the trapezius, levator anguli scapulæ, and sterno-mastoid muscle; small and deep-seated branches also supply the scaleni and the deep anterior spinal muscles. The *communicating branches* are very numerous; each cervical nerve is connected, as already stated, to the sympathetic. The branches of the spinal accessory are entangled among those of the plexus; some join its loops between and beneath the mastoid and trapezius muscles, and others unite in a plexiform manner with the nerves that supply these. From the second and third roots of the plexus descends the *communicans noni.* This, which is very regular, is often double, and arises by two or three roots, which unite and form a long and delicate nerve that descends obliquely inwards and forwards, generally in front of the sheath of the cervical vessels, though sometimes behind the jugular vein, and unites with the descendens noni or colli nerve, opposite the thyroid body, and near the middle tendon of the omo-hyoid muscle. A small plexus, or open net-work, exists at the junction, and from this, branches proceed to the posterior portion of the omohyoid and to the inferior portions of the sterno-hyoid and thyroid muscles. The last and most important branch of the cervical plexus is the *internal respiratory* or *phrenic nerve.* This arises from the lower part of the plexus, chiefly from the third and fourth cervical; it has also in general a filament or two from the fifth, or from the brachial plexus, and from the sympathetic. The phrenic nerve descends obliquely inwards on the anterior scalenus muscle, and at the lower part of the neck communicates with the lower cervical ganglion, and often with the vagus or its recurrent; it then enters the thorax between the subclavian vein and artery, and descends in the middle mediastinum to the diaphragm on the side of the pericardium, between it and the pleura, accompanied by a small artery from the internal mammary: the right phrenic is nearly perpendicular, the left takes an oblique course round the apex of the heart; it is. therefore, longer, and lies more posterior than the right. On the diaphragm these nerves divide into several branches, some of which ramify on the superior surface of that muscle, others on its inferior; the latter accompany the phrenic vessels. The terminating branches on the right side send some filaments to the inferior vena cava and to the liver, and unite with the nerves of this organ; on the left side some very fine filaments pass towards the œsophagus and stomach; these, probably, communicate with the vagus and solar plexus.

Next examine the posterior branches of the cervical nerves.

The *posterior division of the sub-occipital* is as large as the anterior, passes out of the spinal canal, above the arch of the atlas, along with and posterior to the vertebral artery, enters the triangular region beneath the occipital bone, bounded by the recti and obliqui muscles;

it then divides into several small branches, which are enveloped in the adipose substance which abounds in this situation; these branches are distributed to the greater and lesser recti and obliqui muscles, also to the complexus. A small cutaneous branch has been observed, and a filament descends either through or around the inferior oblique to join the second cervical nerve.

The *posterior branch of the second* is the largest of the entire series of the spinal nerves; it passes backwards and outwards between the laminæ of the axis and dentatus, and beneath the inferior oblique muscle, where it communicates with the sub-occipital nerve, and soon afterwards with the third cervical. It then gives off filaments to the adjacent muscles, viz., the complexus, splenius, trachelo-mastoideus, and obliquus inferior. The continued trunk, named the *occipitalis major*, ascends over the inferior oblique, pierces the complexus, and shortly afterwards the trapezius, and then becomes sub-cutaneous; is broad and flat, accompanies the occipital artery in the scalp, between the skin and occipito-frontalis, divides into numerous long filaments, which can easily be followed as far as the vertex; some pass laterally to the ear, and communicate with the auricular nerves.

The *posterior branch of the third* is much smaller than the last, and that of the fourth is smaller than the third; they both communicate with each other, also with the second, and through that with the first. This series of communication between these four nerves, beneath the complexus muscle, has been named by Cruveilhier and others the "posterior cervical plexus." The branches from this plexus principally pass inwards towards the spinous processes, some supply the different laminæ of muscles, others pierce the complexus and trapezius, and become cutaneous; one branch from the third cervical nerve ascends to the lower part of the occipital region, internal to the great occipital nerve, and is distributed to the scalp.

The *posterior branches of the four inferior cervical nerves* diminish in size to the eighth, and are all disposed in a similar manner; they pass towards the mesial line between the different muscles, and gradually become subcutaneous; they then bend outwards, and are distributed to the integument covering the trapezius muscle. While the direction of the three first is principally upwards, that of the fourth and fifth is nearly transverse, and that of the three last is rather downwards.

We may next proceed to examine the anterior divisions of the four last cervical, and at the same time that of the first dorsal, as the latter joins the former, to constitute the following very important plexus.

The BRACHIAL PLEXUS is formed by the junction of the anterior branches of the fifth, sixth, seventh, and eighth cervical, and of the first dorsal. This plexus is broad and flat, the nerves forming it are very large, particularly the inferior; it is situated at the lower and lateral part of the neck, between the scaleni muscles and above the subclavian artery; it descends obliquely outwards beneath the clavicle

and subclavian muscle, and over the first rib into the axilla, where it rests on the serratus magnus, behind the axillary artery and vein, and on the inner side of the humero-scapular joint and sub-scapular tendon. The fifth and sixth cervical unite first, the seventh cervical runs alone for some distance, the eighth cervical and first dorsal unite immediately, so that, at first, this plexus consists of three roots; these, however, soon unite in the following manner: The upper root, which is joined by a filament from the fourth cervical, soon divides into a superior and inferior branch; the lower root also soon bifurcates in a similar manner; lower down, or behind the clavicle, the seventh cervical or the middle root divides into a superior and inferior branch, the former joins the lower division of the upper, and the latter joins the upper division of the lower root; the three cords then converge, and the plexus becomes narrow as it enters the axilla, when it again expands and opens out into several divisions, which surround the axillary artery in a plexiform manner, and from which the terminating branches proceed. The roots of the plexus are covered by the anterior scalenus, and by a strong fascia prolonged from the margin of this muscle. It then traverses the inferior lateral triangular region of the neck, nearly parallel to but deeper seated than the omo-hyoid muscle. It next descends behind the clavicle, the subclavius muscle, the strong coraco-clavicular aponeurosis, and the greater and lesser pectoral muscle. It ends in its ultimate divisions, opposite the coracoid process. In the neck the plexus is superior and external to the subclavian artery, and distinct from it. As it descends it approaches this vessel, and in the upper part of the axilla it is almost immediately behind it, though somewhat external to it; in the middle of this region it partly embraces the artery, and inferiorly the latter is placed between the roots of the median or brachial nerve, one of its largest branches; the corresponding vein is inferior to it in the neck, and on a plane internal and anterior to it in the axilla, and never so closely connected to it as the artery is.

The numerous branches of this plexus may be arranged into two orders, one (supra-clavicular) arises above the clavicle, the other (axillary) arises below this bone. This arrangement, though convenient, will seldom be found critically correct, as the origin and disposition of some of the branches are not uniformly the same in all cases. The *supra-clavicular* branches are—First, for the subclavian muscle; this arises from the first root of the plexus; it generally gives off a filament to join the phrenic nerve, and then enters the subclavian muscle. Second, small branches also from the upper root of the plexus to the scaleni, levator anguli, and rhomboidæi muscles. Third, *posterior thoracic*, or *external respiratory*, also arises from the fifth and sixth cervical, close to the spine, and in the substance of the middle scalenus muscle; it also sometimes receives a branch from the fourth cervical. This nerve, about the size of the phrenic or internal respiratory, takes a long course; it descends obliquely outwards, behind the brachial plexus, and between the sub-scapular and serratus mag-

nus muscles: on the external surface of the latter it descends even to its lower border, and supplies its costal fasciculi with filaments through its whole course. As this nerve arises in the neck so close to the roots of the phrenic, it must serve to associate (as Sir C. Bell has remarked) the serratus magnus muscle with the diaphragm in inspiratory efforts; hence it has been named the external respiratory nerve. Fourth, the *supra-scapular nerve* also arises from the upper division of the plexus, descends obliquely backwards, beneath the trapezius, and parallel to the omo-hyoid muscle, to the superior costa of the scapula, enlarges and passes beneath the posterior ligament, which converts the notch in this part of the bone into a foramen; it then gives off two considerable branches to the supra-spinatus muscle, and proceeds beneath the acromion process, behind the neck of the scapula, and in front of its spine, to the infra-spinous fossa, where it is distributed to the infra-spinatus and teres minor muscles; it also gives off one or two delicate articular branches to the shoulder joint.

The *infra-clavicular*, or axillary branches, are, first, the thoracic; second, sub-scapular; and, third, circumflex; these are to supply the pectoral muscles, the axilla, the integuments, and several of the muscles of the shoulder: fourth, internal cutaneous; fifth, external cutaneous, or musculo-cutaneous; sixth, the median or brachial; seventh, the ulnar; these four nerves are associated in function, they supply sensitive and tactile filaments to the anterior and internal aspect of the arm, forearm, hand, and fingers, and motor filaments to the extensive group of the flexor and pronator muscles; eighth, the musculo-spiral or radial nerve. This large cord is destined to supply the extensors and supinators of the forearm, hand, and fingers, and might be named the *great extensor nerve* of the upper extremity, as the combined median, ulnar, and musculo-cutaneous may be regarded as the *great flexor*. All these nerves are probably compound, that is, their fasciculi contain both sensitive and motor filaments, excepting the internal cutaneous nerves, whose distribution is entirely to the skin. These nerves are arranged in respect to the artery in the following manner: the vessel lies between the two roots of the median nerve; the outer root of the latter and the external cutaneous are to its outer or humeral side; the inner root of the median, the internal cutaneous, and the ulnar, are to its inner or costal side; the circumflex and the musculo-spiral are behind it; and the trunk of the median is in front of it.

The *thoracic branches* are two or three short nerves, which supply the pectoral muscles, accompany the thoracic arteries, communicate freely with each other and with branches from the intercostal nerves, which cross the axilla to the integuments of the arm. These nerves also distribute filaments to the areolar tissue and glands in the axilla, and contribute to the plexiform appearance which the dissection of this region presents. The *anterior*, or more superficial thoracic nerve, arises nearly opposite the clavicle, crosses the axillary vessels, and is distributed to the deep surface of the great pectoral muscle; small filaments also pass to the clavicular portion of the deltoid. The *posterior*,

or deeper thoracic branches, pass behind the artery, and come forwards between it and the vein, form loops or plexuses with branches from the former, and are distributed to the lesser and partly to the great pectoral muscle.

The *sub-scapular nerves* are three or four in number; they arise from different parts, but chiefly from the upper division of the plexus; they descend behind the vessels, and ramify in the sub-scapular, latissimus dorsi, and teres major muscles.

The *circumflex* or *articular nerve*, or *deltoid*, arises from the lower and back part of the plexus, in common with the musculo-spiral, descends round the lower edge of the sub-scapular muscle, and, passing backwards and outwards, escapes from the axilla by a large opening between the humerus and the long head of the triceps, above the tendons of the latissimus dorsi and teres major muscles, and below the capsular ligament of the shoulder joint; it then winds round the neck of the humerus, attached to the internal surface of the deltoid to its anterior border. In this course the nerve sends some small branches to the sub-scapular, latissimus dorsi, and teres major and minor; it then divides into two branches, a superior and inferior, both of which encircle the neck of the humerus, and send their numerous subdivisions into the deltoid muscle. At the inferior and posterior margin of the deltoid a considerable cutaneous branch arises from the inferior division; this ascends beneath the fascia, becomes cutaneous, and ramifies in the skin, covering the lower part of the deltoid; other branches pierce the muscle higher up, and are distributed to the integuments of the shoulder; it also sends a considerable branch to the capsule of the shoulder joint, which passes to it beneath the tendon of the sub-scapular muscle. The circumflex nerve and its divisions are accompanied by the posterior circumflex artery and its branches; both are liable to be injured in fracture of the surgical neck of the humerus; and the trunk of the nerve may suffer such compression in case of dislocation of the head of the humerus into the axilla as may impair the power of the deltoid muscle. The student will find it convenient to postpone the dissection of this nerve until the other branches of the plexus have been examined, or until the arm has been detached from the trunk.

Internal cutaneous nerve is long and delicate; it arises out of the lower division of the plexus, in common with the ulnar and inner head of the median, descends nearly perpendicularly along the inner side of the arm, at first covered by the brachial aponeurosis; near the elbow it pierces the latter, becomes subcutaneous, and parallel to the basilic vein, and divides into two branches, an external and internal; the external passes along the border of the biceps over the bend of the elbow to the fore arm, where it divides into several filaments, some of which descend in the integuments as low as the wrist, and communicate with the other cutaneous nerves. This branch generally crosses the median basilic vein, superficial to it, and rarely behind it; the internal branch descends towards the internal condyle, and divides into several fila-

ments, some of which descend along the inner, and others along the posterior part of the forearm ; they all terminate in the integuments. An *accessory* or *lesser internal cutaneous nerve*, or *nerve of Wrisberg*, may also be noticed in connexion with that just described. This small branch, arising from the lower and back part of the plexus, descends on the back part of the arm, pierces the fascia, is distributed to the integuments about the elbow, and communicates with cutaneous filaments of the internal cutaneous and of the musculo-spiral nerves. In the axilla it often joins with the humeral cutaneous branch from the first intercostal nerve ; indeed this latter branch is sometimes named "nerve of Wrisberg," and not unfrequently takes the place of the lesser cutaneous.

The *external cutaneous nerve*, or *musculo-cutaneous*, or *perforans Casserii*, is larger than the last, and arises from the upper division of the plexus, in common with the external root of the median ; it descends obliquely outwards through the fibres of the coraco-brachialis, and between the brachiæus anticus and the biceps ; it then descends along the outer border of the latter to the bend of the elbow, pierces the aponeurosis, becomes cutaneous, and descends along the radial side of the forearm to the wrist. In the arm this nerve gives muscular branches to the coraco-brachialis, biceps, and brachiæus anticus : in the latter muscle it frequently communicates with the median nerve. At the elbow this nerve is situated between the biceps and supinator longus, and behind the cephalic and median cephalic veins ; along the forearm it accompanies this vein, and is often superficial to it. Near the wrist it divides into an anterior and posterior branch, the former passes to the ball of the thumb and palm of the hand, the latter to its dorsum, and both communicate with the cutaneous filaments of the radial nerve : this nerve does not always pierce the coraco-brachialis muscle.

The *median* or *brachial nerve* is the largest branch of the plexus ; it generally arises by two roots, a small external one, which is in common with the external cutaneous from the upper part of the plexus, and a large internal one from the lower division of the plexus, in common with the ulnar and internal cutaneous. The brachial artery in general separates these two roots, which soon unite into one thick cord ; it descends obliquely outwards along the inner edge of the biceps, as far as the bend of the elbow ; in this course it is covered only by the skin and fascia, is situated rather to the outer side of the artery above, crossing over it about the middle of the arm, and to its ulnar side below ; at the end of the elbow it passes deep between the supinator longus and pronator teres, and lies on the brachiæus anticus ; it then perforates the pronator, and descends along the middle of the forearm (hence its name), between the superficial and deep flexors, passes beneath the annular ligament of the carpus, where its size is increased, and where it assumes a greyish or ganglionic appearance, and terminates in the palm of the hand by dividing into five or six branches. In the arm the median nerve gives but few branches, small and unimport-

ant. In the forearm it sends several considerable branches to the superficial and deep pronators and flexors, but not to the supinators; a little below the elbow it gives off the *anterior interosseal nerve;* this accompanies the artery of the same name along the anterior surface of the interosseous membrane, and supplies the deep flexors; at the pronator quadratus it divides into two branches, a small one to supply that muscle, and a larger which traverses the interosseous space, ends in a soft, gangliform expansion, filaments from which spread over the dorsum of the carpus, and supply its several articulations. Above the wrist the median nerve is only covered by the skin and fascia, and sometimes by the palmaris tendon; it here gives off a superficial branch, which passes over the annular ligament, and is lost in the integuments. In the palm of the hand it first gives off a considerable branch to supply the muscles of the ball of the thumb, and then divides into five *digital branches;* the two first pass one along either side of the thumb, the third goes to the radial side of the index finger, the fourth supplies the opposed sides of the index and middle finger, and the fifth, which is joined by a small branch from the ulnar nerve, supplies the opposed sides of the middle and ring fingers. These digital branches in the palm of the hand are superficial to the tendons, and form an arch nearly parallel to that formed by the ulnar artery; the branches of the latter and the digital nerves then run together to the extremity of each finger, the nerves being on the internal side of the arteries; in this course they supply the lumbricales, the integuments of the hand and fingers: opposite the base of the first phalanx each sends off a dorsal cutaneous branch, which runs along the posterior border of each finger, and unites with the posterior cutaneous nerves; and near the last phalanx of each the nerves enlarge, become red and soft, and divide into a dorsal and palmar branch; the former is lost in the vascular matrix of the nail, and the latter subdivides into numerous fine branches, which are lost in the sentient or tactile papillæ of the cutis.

The *ulnar nerve* arises from the lower part of the plexus, in common with the internal cutaneous and the inner head of the median; descends obliquely backwards along the triceps, internal to the brachial vessels, and accompanied by the inferior profunda artery; it pierces the internal intermuscular ligament, becomes very superficial, and passes behind the elbow-joint through the groove between the inner condyle and the olecranon process, between the origins of the flexor carpi ulnaris muscle; it then passes forwards, and descends along the ulnar side of the forearm to the carpus, and, passing over the annular ligament close to the pisiform bone, ends in the palm of the hand, in two branches, a superficial and a deep. In the arm this nerve is superficial, and gives off a few branches to the triceps and to the skin; as it passes behind the inner condyle it gives off some articular and cutaneous branches. In the forearm it lies on the flexor profundus, and between the flexor sublimis and ulnaris, overlapped by the latter; the ulnar artery is to its radial side; to these muscles it sends several filaments; a little above the wrist it becomes superficial, and gives off the

dorsalis carpi ulnaris, a large branch which winds round the ulna, beneath the flexor carpi ulnaris, to the back of the hand, and divides into several long branches, which are lost in the integuments of that region and on the dorsum of the three inner fingers, and anastomose with the radial branch of the musculo-spiral nerve. Of the terminating branches of the ulnar nerve the *superficial* is the larger; it divides into three branches, which supply the palmaris brevis, the muscles, and both sides of the little finger, also the ulnar side of the ring finger. The *deep palmar branch* passes beneath the flexor tendons, runs across the metacarpus, and assists in forming a deep palmar arch, the branches of which supply the adductor and flexor pollicis brevis, and the interossei muscles.

Connected to the digital and other sensitive branches, both of the median and ulnar nerves, are a number of small, indurated, white bodies, now known by the name of *Pacinian Corpuscles;* so called from Filippo Pacini, who discovered them in 1830. These have since been more accurately described by him, by Henle, and others. They are most distinct on the small branches of the digital nerves: at first view they appear like globules of firm cellular membrane, of an elliptical form,* imbedded in the subcutaneous adipose tissue, and surrounded by capillary vessels; their size varies from the twentieth part of an inch upwards; each corpuscle is connected to a nerve by a short, delicate, nervous stem, which bends from it at an acute angle, and is about the eighth or tenth of an inch long. The corpuscle itself is found to be composed of a great number of delicate, concentric, membranous capsules, with intervening clear fluid: on the presence of the latter the size of the corpuscle chiefly depends, as on puncturing it, it collapses into a mere flattened band; the central capsule is also filled with fluid. The stem contains a minute nervous filament, which perforates the several capsules, becomes pale, flat and small, and traverses the central cavity in a straight line to its remote end, where it adheres, and is said to terminate, not in a plexus or loop, but in an adherent pulp or bulb. The use or function of these bodies is unknown, but from the uniformity of their existence we may presume they are the seat of some peculiar vital or nervous agency: they are not seen on any of the true motor nerves; they have been found in other situations beside the hand, as the sole of the foot, on the cutaneous nerves of the limbs, and of those of the intercostal spaces, and on the great plexuses. They are said to occur in great numbers in the sympathetic plexuses in the mesentery and mesocolon in the cat. Paccini endeavours to establish a structural analogy, and would thence infer one in function, between these corpuscles and those very remarkable electric organs found in certain fish, as in the electric ray, near the head, and in the electric eel, near the tail. These organs consist of membranous prisms or columns filled with fluid; they are of an hexagonal and triangular form, and are subdivided by transverse septa, on which are distributed the terminal

* See preparation of these in the Museum of Trinity College.

plexuses of nerves and vessels. On these partitions, however (according to Wagner; *see* Wagner's Comp. Anat., translated by Tulk, page 219), the nerves terminate, not, as in the Pacinian corpuscles, in adherent bulbs, but much in the same way as they do on the voluntary or transversely striated muscles.—(*See* British and For. Med. Review for Jan., 1845, p. 78). A minute and very interesting account of the structure of these singular bodies, microscopically examined, has been lately published by Todd and Bowman (*see* Phys. of Man, p. 400).

The *musculo-spiral* or *radial nerve* is the largest branch of the plexus; it proceeds from its middle and lower divisions in common with the circumflex nerve, descends obliquely backwards and outwards, between the three portions of the triceps and the humerus, to the external side of the latter; it then turns obliquely forwards and downwards towards the elbow, between the supinator longus and the brachiæus anticus, and there divides into two branches, an anterior or radial branch, a posterior or interosseal branch; it is accompanied by the inferior profunda artery. In its course down the arm this nerve sends several branches to the triceps, and to the integuments on the inner and posterior part of the arm, also to the elbow; a little above the outer condyle it gives off a large cutaneous branch, which descends along the radial side of the forearm to the thumb. At the bend of the elbow this nerve sends several branches to the long and short supinators, also to the extensors of the carpus. On the surface of the supinator brevis it expands and divides into its two terminating branches. The *anterior* or the *radial nerve* descends along the inner side of the supinator longus, which it supplies, and lies external to the radial artery. About the middle of the forearm, or a little lower, this nerve passes behind the tendon of the supinator longus, and, becoming cutaneous, descends behind the radius to the back of the hand, where it divides into two considerable branches; one supplies the integuments of the radial side of the thumb, and communicates with the posterior branch of the external or musculo-cutaneous nerve; the other, or the internal branch, crosses the extensor tendons of the thumb, expands on the dorsum of the hand, and supplies the inner border of the thumb, and the index and middle fingers, and communicates with the dorsalis ulnaris nerve. The *deep* branch of the musculo-spiral, or the *posterior interosseal nerve*, is larger than the radial, winds backwards round the upper part of the radius and the supinator brevis; it then descends along the back part of the forearm, with the posterior interosseal artery, and divides into several branches, superficial and deep, which supply the two layers of extensor muscles.

The DORSAL NERVES are twelve in number on each side. The first pair passes between the two first dorsal vertebræ, and the last pair below the two last dorsal vertebræ; the first is very large, the following diminish in size, but the two last again increase, and the twelfth is nearly equal to the first. These nerves are distributed to the parietes of the thorax and abdomen, also to the muscles and integuments on the posterior and lateral regions of the trunk; they are not con-

nected together in any plexus, like the cervical, lumbar, and sacral nerves, but are distributed separately; all their anterior branches, however, are united through the medium of the chain of the dorsal sympathetic ganglions, each of the former being connected by one or two filaments to one of the latter; the first dorsal is also joined to the last cervical in the brachial plexus, and the last dorsal is connected to the first lumbar: they all divide into a posterior and an anterior or intercostal branch. The *posterior* or *dorsal branches* are smaller than the anterior; they each pass backwards, accompanied by the posterior branch of the intercostal artery, through a foramen bounded above and below by the transverse processes, internally by the bodies of two vertebræ, and externally by the anterior or great costo-transverse ligament; they supply the muscles and integuments of the back and loins.

To obtain a view of the posterior dorsal nerves, place the body on its forepart, divide the skin along the spine from the neck to the loins, and dissect it over towards the scapula and side of the thorax and abdomen. Several long nerves will be met with in this dissection, which, having pierced the trapezius, rhomboid, latissimus dorsi, and inferior serratus, are distributed to the integuments of this region. Some of the *superior cutaneous nerves* of the back pierce the laminæ of dorsal muscles close to the spinous processes, and then pass transversely outwards towards the scapula, and some ascend. The *inferior cutaneous* perforate the latissimus dorsi and inferior serratus on a plane external to the superior nerves, nearly opposite the angles of the ribs; these nerves ramify on the lower part of the back, chiefly in a direction downwards, and some branches extend over the lumbar to the gluteal and sacral regions. By a little dissection they may be followed deep among the muscles to the cellular line, between the sacro-lumbalis and longissimus dorsi, and beneath or through the latter to the foramina, between the transverse processes. The six superior escape from these between the semispinalis dorsi and multifidus spinæ, and the six inferior between the latter and the longissimus dorsi; these increase in size as they descend; they all divide into two branches, an *internal* and an *external;* the former supply the long erector or extensor muscles of the spine, the latter pass through these, supplying them at the same time, and are chiefly distributed to the broad superficial muscles which they perforate; both also furnish the cutaneous branches; superiorly these are chiefly derived from the internal muscular branches, but inferiorly from the external muscular and musculo-cutaneous.

The anterior dorsal nerves are named, from their situation, intercostal, with the exception of the first, which joins the last cervical in the brachial plexus, first giving off a small intercostal branch; the remaining eleven are disposed in a somewhat similar manner; they all pass round the parietes of the thorax, between the laminæ of the intercostal muscles, and inferior to the blood-vessels of that name; the superior five or six are confined to the chest, and extend as far as the sternum, but the anterior portions of the five or six inferior are placed in

parallel lines between the abdominal muscles, and extend to the rectus; they supply the parietes, muscles, and integuments of the thorax, and of the upper part of the abdomen; also some cutaneous filaments to the arm; they all communicate by two short branches with the thoracic ganglions of the sympathetic, which are placed on the side of the spine; they diminish in size as they descend, except the two last: the twelfth is nearly as large as the first, it often communicates with the first lumbar by a small branch called *dorso-lumbar nerve;* this is not always present; the connexion is then maintained through the sympathetic. These nerves may be exposed either by raising one or two of the external intercostal laminæ, or by breaking and everting the ribs on one side, raising the pleura, and dividing some of the internal laminæ of the intercostal muscles. Each intercostal nerve is separated from the posterior branch by the costo-transverse ligament; it then becomes flattened, and passes first between the pleura and a strong fascia, which occupies the place of the internal lamina of the intercostal muscles; it then enters the interstice between the internal and external intercostals, beneath the groove which lodges the artery and veins; as it passes forwards it descends near to the centre of the intercostal space, and, about midway between the spine and sternum, divides into a superficial or cutaneous branch and the continued intercostal. The *first anterior dorsal* is very large, and is an exception to this description; it ascends from the thorax into the neck, in front of the neck of the first rib, has a very close connexion to the large ganglionic mass which the sympathetic here presents, and joins the eighth cervical nerve; it first sends off a small intercostal branch, which runs forwards between the first intercostal muscles towards the sternum, and ends anteriorly in a small cutaneous filament. The *second intercostal* proceeds in like manner in the second space; about midway it gives off a large branch, which passes outwards to the integuments of the arm; this is named the *first intercosto-humeral*, and, by some, the nerve of Wrisberg The *third intercostal nerve* very often, but not always, gives off a similar branch, the *second intercosto-humeral nerve;* both these nerves perforate the costal origins of the great serratus, pass outwards across the axilla, communicate with each other and with the thoracic branches of the brachial plexus, and with the lesser internal cutaneous one of the arm, and finally terminate in the skin on the posterior and internal part of the arm, descending even to the elbow. The *five* or *six superior intercostal nerves* continue forwards as far as the costal cartilages, then rest upon the pleura, cross the internal mammary vessels and some fibres of the triangularis sterni muscles, send some filaments to the latter, and finally pierce the internal intercostal and great pectoral muscles, and end in the integuments in a series of small branches, named *anterior cutaneous nerves.* Besides these cutaneous branches, they all, except the first, give off the *lateral cutaneous nerves;* these pierce the external intercostals and the anterior border of the great serratus, give off small muscular branches, become sub-cutaneous, and divide each into an anterior and posterior branch, which supply the

integuments; the anterior branches turn forward towards the anterior cutaneous nerves, and some are distributed to the integuments of the breast; the posterior pass backwards to the skin over the inferior costa of the scapula and over the latissimus dorsi muscle.

The *five* or *six lower intercostals* (not the last) pass in a similar manner in the intercostal spaces, and at the anterior extremity of each, where the cartilages bend upwards, they pass forwards parallel to the intercostals above, between the internal oblique and transverse muscles of the abdomen, as far as the outer edge of the sheath of the rectus, perforate this along its outer border, pass behind the muscle, and about its centre perforate it, and divide into muscular and anterior cutaneous branches; the latter pass through the anterior wall of the sheath, along the side of the linea alba, and are reflected transversely outwards in the integuments. In this course these nerves supply the intercostal and the abdominal muscles, send small filaments to the diaphragm, communicate with each other, and about midway between the spine and the linea alba each sends off a lateral cutaneous nerve; these pierce the external intercostal and abdominal muscles nearly in the same line as those from the upper intercostals; they become subcutaneous, and divide into anterior and posterior cutaneous filaments; the anterior branches are continued forwards to communicate with the anterior perforating cutaneous branches from the sheath of the rectus, and the posterior are continued round over the external oblique and latissimus dorsi to meet the posterior cutaneous nerves from the posterior dorsal. The anterior branch of the *last dorsal* is abdominal rather than intercostal; it is very large, and generally communicates with the first lumbar close to the spine by the dorsal lumbar branch; it then runs below the last rib, crossing the quadratus lumborum, and the diaphragm, to which it gives some filaments, and, piercing the anterior leaf of the tranversalis tendon, it passes forwards, like the other nerves, between the transverse and internal oblique muscles to the sheath of the rectus; between the ilium and last rib it gives off its lateral cutaneous branch, which is very large, pierces and supplies the two oblique muscles, descends almost vertically over the crest of the ilium, and divides into anterior, middle, and posterior cutaneous filaments, which ramify over the gluteal, iliac, and trochanteric regions.

Lumbar Nerves.—Of these there are five pair; they are larger than the dorsal, and increase in size from above downward; the first escapes between the two first lumbar vertebræ, and the fifth between the last vertebra and the sacrum; like the dorsal they divide into posterior and anterior branches. The *posterior* pass between the transverse processes to the lumbo-spinal muscles, and each divides close to the multifidus spinæ into an internal and external branch; the former is lost in the multifidus spinæ, inter-spinous, and inter-transverse muscles; the external branch is larger and musculo-cutaneous; it supplies the sacro-lumbalis and lumbar aponeurosis, pierces the latter, and is lost in the integuments. The two last posterior nerves are very small, and are distributed to the integuments of the gluteal region.

The *anterior* branches are much larger than the posterior, and increase as they descend; they all pass obliquely downwards and outwards in the psoas magnus, and separate the origin of this muscle into two planes, much in the same way as the cervical plexus divides the scaleni. In this muscle they unite with each other by a series of loops, each nerve dividing into two or more, and the branches arch up and down to join the corresponding nerve above and below. This plexiform arrangement of these nerves resembles that in the cervical more than the brachial or sacral plexus. The first lumbar is usually connected to the last dorsal, and the fourth lumbar is joined to the fifth, which does not enter this plexus, but descends into the pelvis, under the name of the lumbo-sacral nerve, to join the great sacral plexus. Each of the anterior lumbar nerves is joined to the long ganglions of the sympathetic, and, as these are placed on the forepart of the vertebræ, these connecting filaments are much longer than those in the back.

The *lumbar plexus* is long and somewhat triangular, broad below and narrow above, is situated along the sides of the lumbar vertebræ, in front of their transverse processes, and near the posterior surface of the psoas magnus muscle; in addition to its three principal and terminal branches, the anterior crural, obturator, and lumbo-sacral, it also gives off some long superficial branches.

The *superficial branches* of the lumbar plexus are variable in number, size, and exact situation; they supply the inferior portion of the abdominal muscles and integuments, the integuments of the groin, and upper and outer part of the thigh; also those of the inguinal and pubic regions: they are, therefore, abdomino-crural and genito-crural. They are differently named by different writers: the arrangement adopted by Bichat appears as appropriate as that of more modern authors. He enumerates four, viz., the superior, middle, and inferior musculo-cutaneous, and the genito-crural.

Superior musculo-cutaneous (external ilio-inguinal, or ilio-hypogastric, or ilio-scrotal).—This, like the following branches, is exposed by detaching the peritonæum from the lumbar and iliac fossæ; it arises from the upper root or roots of the plexus, traverses the psoas, and gives it some filaments; then proceeds obliquely outwards, on the quadratus lumborum muscle and behind the kidney, to the posterior part of the crest of the ilium, enters a groove between this and the transversalis muscle, and divides into an external and internal branch. The external is distributed to the abdominal muscles and integuments; the internal passes forwards towards the anterior iliac spine, then proceeds parallel to the crural arch, and near the rectus perforates the external oblique, and becomes cutaneous in the inguinal and pubic regions. Near the ilium it gives off a cutaneous branch, which passes over the bone, and is distributed to the integuments over the glutæus medius, behind the lateral cutaneous branch of the last dorsal nerve.

The *middle musculo*, or *inguino-cutaneous*, arises close to the last, and has nearly a similar course and termination.

The *inferior musculo-cutaneous*, or *external cutaneous*, is a small, long branch arising from the first and second lumbar, descends along the iliac fossa, escapes into the thigh between the superior and inferior iliac spinous processes, and divides into two branches. The posterior passes backwards behind or through the tensor vaginæ, and becomes subcutaneous on the upper, outer, and back part of the thigh. The anterior branch perforates the fascia lata three or four inches below the arch, and ends in long cutaneous filaments, which descend towards the knee, along the outer and anterior aspect of the thigh.

The *genito-crural nerve* arises from the second and third lumbar, descends obliquely through the psoas, in front of or connected to the external iliac artery, and divides into the genital or spermatic and crural branch. The spermatic pierces the transverse fascia, or escapes through the internal ring, joins the cord, descends at first posterior to it, gives off cutaneous filaments, supplies the cremaster, and is lost in the scrotal and pubic integument : in the female it accompanies the round ligament, and ends in the labium. The crural branch accompanies the external iliac artery beneath the arch, crosses the root of the circumflex ilii branch, pierces the sheath of the vessels and the fascia lata, sends some filaments along the artery, and is distributed to the inguinal integuments and glands.

The *anterior crural nerve* arises in the lumbar plexus from the four superior nerves, but principally from the third and fourth; it is the largest and the most external branch of the plexus, and is destined to supply the integuments on the anterior and inner aspects of the thigh, leg, and foot, also all the extensor muscles of the leg or of the knee-joint, and the principal flexors of the thigh or of the hip-joint, flexion of the latter and extension of the former being associated in locomotion. It perforates the psoas, descends obliquely outwards, along its external side, in the groove between it and the iliacus internus, covered by the iliac fascia; it passes beneath Poupart's ligament about half an inch external to the femoral artery, separated from it by the psoas and by the iliac fascia, and is thereby excluded from the sheath of the vessels. It is next covered by the fascia lata, becomes flat and broad, and divides into two fasciculi, a superficial and a deep, between and among which the branches of the external circumflex artery are entangled. Within the abdomen the anterior crural nerve gives off one or two filaments to the psoas and several to the iliac muscles, and sometimes one or two to the external iliac or femoral artery. The superficial or anterior division of the nerve subdivides into several muscular and musculo-cutaneous branches, which pierce the fascia lata, and descend along the inner and forepart of the thigh to the knee. It would be useless and almost endless labour to apply distinct names to all the individual branches of this long nerve, neither could any one description apply to all cases, as the exact point of their origin, as well as of their separation and subdivision, is very variable. If the integument be carefully raised from the anterior and lateral aspects of the thigh, from the pelvis to the knee, several long cutaneous nerves will be

2 o 2

exposed, in addition to those already traced from the lumbar plexus. Many of these cutaneous nerves are rather large, and are seen to perforate the fascia lata by distinct oblique canals, carrying with them, in some instances, a sheath from the fascia; they descend between the skin and aponeurosis to a variable distance, at first isolated from the surrounding parts; they soon enter the subcutaneous tissue, and their filaments separate and scatter, some pass transversely, others loop upwards in arches convex inferiorly. Near the knee the terminating filaments become soft, enlarged, and ganglionic, and end in the subcutaneous adipose tissue around the patella. When the cutaneous filaments have been thus exposed, the fascia lata may be next divided and partially raised, so as to bring into view the trunk of the anterior crural at the seat of its expansion and division. This point, however, is variable, as the nerve often separates into many of its branches higher up, even in the iliac fossa.

The principal branches of the *superficial division* of the anterior crural nerves are the middle cutaneous, the internal cutaneous, the vaginal branches to the sheath of the vessels, and the long saphenous; the branches of the deep division are wholly muscular. These two divisions are variable as to size, and therefore some branches, which are usually described as arising from one, may be found to proceed from the other. This separation or distinction into two portions appears to me to be merely caused by the accidental passage of the external circumflex artery through the fasciculi of the nerve.

The *middle cutaneous* or *musculo-cutaneous nerve of the thigh* perforates the sartorius very obliquely, gives some branches to it, then pierces the fascia lata three or four inches below Poupart's ligament, and soon divides into long fasciculi, which descend towards the inner and forepart of the knee, sending off numerous filaments to the skin, which communicate with other cutaneous nerves. Not unfrequently two or three nerves will be found to correspond to this description.

The *internal cutaneous nerve*, or nerves, descend in the line of the femoral artery to its outer side, supply the sartorius, and either perforate it or pass at one side of it, pierce the fascia lata about the middle of the thigh, and descend towards the inner side of the knee, where they end in numerous branches; some bend forwards towards the patella, end in the skin and in a subcutaneous plexus along with the other superficial nerves. In the upper parts of the limb this nerve gives small filaments to the sheath of the femoral vessels; others pierce the fascia at irregular intervals along the inner side of the limb; and some escape through the saphenous opening, or in its vicinity (*superior* or *short saphenous*), and accompany the saphena vein along the thigh; some of the deep branches communicate with the inferior or long saphenous and with the obturator nerve, forming an interlacement beneath the sartorius muscle in the course of the femoral vessels.

Vaginal branches pass inwards to the sheath of the vessels; some twine around the artery, and pass between it and the profunda towards the pectinæus; others join in the general interlacement between the

muscular branches and the obturator, and one very generally passes in front of the artery, above the middle of the thigh, in its course to the adductor longus muscle.

Inferior or *long saphenous nerve* sometimes arises wholly or in part from the deep division of the anterior crural, descends obliquely inwards, at first on the outer side of the artery, afterwards in front of it; passes along with this vessel into its tendinous sheath or canal in the middle third of the thigh, but separates from it at the opening in the adductor tendons, through which the artery glides backwards into the poplitæal space, the nerve continuing to descend vertically, accompanied by the anastomotica magna artery, and, crossing the adductor tendon obliquely from before backwards, arrives at the inner side of the knee, a little behind the internal condyle of the femur; becomes subcutaneous between the tendons of the gracilis and sartorius, anterior to the former, and sometimes perforating the latter; and then divides into two branches, the cutaneous nerve of the knee and the proper saphenous or internal cutaneous nerve of the leg. In the upper part of the thigh it communicates by small filaments with the obturator and with branches of the internal cutaneous, and with the muscular branches of the anterior crural nerve. These communications are very variable: I have seen it receive a considerable branch from the obturator, in other cases I have not found any direct connexion between these nerves; while in the femoral sheath, in the middle of the thigh, it sometimes gives off a small cutaneous branch, also some filaments to the vastus internus and sartorius. Near the opening in the adductor tendon it gives off an articular branch, which descends along the adductor tendon in company with a small artery, and is distributed to the synovial membrane. The internal cutaneous nerve of the knee or patellary branch is a large flat nerve, which sometimes perforates the sartorius tendon, and arches forward over the inner side of the joint to the margin of the patella, divides into three sets of branches, superior, middle, and inferior or descending; they all ramify in the integuments around the patella and over the upper part of the tibia and ligamentum patellæ, and communicate with the other cutaneous nerves of this region. The proper saphenous nerve continues to descend, crosses the tendon of the gracilis, and joins the internal or great saphena vein, which it accompanies as far as the foot, twining around it, occasionally splitting, and the divisions encircling the vessel and reuniting. In this course it distributes numerous filaments to the integuments on the forepart of the tibia, some also to the inner and back part of the leg, which communicate with the posterior saphenous or cutaneous nerve of the leg; it descends nearly parallel to the inner border of the tibia, and near the malleolus divides into two principal branches; one descends to the inner ankle, and subdivides into cutaneous filaments for that region; the other, the larger branch, accompanies the vein in front of the malleolus, and divides into numerous filaments, some of which supply the synovial membrane, others expand on the dorsum and

inner side of the foot, along with the cutaneous veins, and communicate with the dorsal nerves of the foot derived from the peronæal nerve.

The *deep fasciculus of the anterior crural* is larger than the superficial; it immediately divides into numerous muscular branches, which supply the muscles on the outer and forepart of the thigh, and partly also those on the inner. These branches may be arranged into three sets, an external, middle, and internal; the first supply the vastus externus, rectus, and iliacus internus, also a small branch to the tensor vaginæ, this muscle being also supplied from the superior gluteal nerve; the middle set supply the sartorius in part, but principally the cruræus and vastus internus; the internal set accompany the femoral artery; one or two pass behind it, and supply the pectinæus; some filaments also pass to the adductor longus, and the remainder to the inner surface of the vastus internus. Almost all these muscular nerves take a descending course, and are accompanied by large blood-vessels, branches of the external circumflex artery and vein, and are all surrounded by much adipose and areolar tissue; the principal branches follow the intermuscular spaces between the two vasti and cruræus, also between the latter and the rectus. Some of the external are very large and long, and in their descent give off cutaneous branches to the outer and posterior part of the thigh, which pierce the vastus and fascia lata below the insertion of the glutæus maximus; some long filaments descend between and beneath the muscles on the periosteum to the synovial membrane of the knee-joint.

The *obturator nerve* arises chiefly from the third and fourth lumbar, perforates the psoas, and descends obliquely inwards, along the inner side of that muscle, above the pelvic cavity and obturator vessels, and in the angle between the internal and external iliac arteries, to the obturator foramen, through the upper part of which it passes to the inner side of the thigh, where it is covered by the pectinæus, and where it divides into its two branches, an anterior and posterior; the anterior or superficial branches are lost in the gracilis, adductor brevis, pectinæus, and vastus internus, and communicate with the internal saphenous and vaginal branches of the anterior crural; some also perforate the fascia, and become cutaneous on the inner side of the thigh: from the pectinæal and adductor branches articular filaments pass to the inner side of the hip-joint, to supply the synovial membrane, and accompany the articular artery through the notch in the acetabulum. The posterior or deep branches supply the obturator externus and adductor magnus; some branches perforate the latter, and supply the adductor longus, and proceed as far as its lower border; some filaments then become superficial, others join internal branches of the anterior crural, and several supply the adductor magnus; one long branch may be traced through it to the lower part of the thigh, into the poplitæal space, and along the poplitæal artery to the back part of the knee-joint. A small nerve from the lumbar plexus (*accessory obturator*) is occasionally met with: this nerve arises from the fourth lumbar,

perforates the psoas, descends on its pelvic side, over the pubis, passes beneath the pectinæus, and ends in several branches; some join the obturator nerve, others are articular, and the remainder are distributed to the pectinæus and adductor brevis muscles.

The *lumbo-sacral nerve* is the largest branch of the lumbar plexus, is formed by a large portion of the anterior division of the fourth and the whole of that of the fifth lumbar nerves, enters the pelvis close to the base of the sacrum, internal but near to the sacro-iliac synchondrosis, and behind the iliac vessels: it immediately divides into two branches; one, the *communicating*, is inferior or anterior, and joins the first anterior sacral nerve, and forms a part of the sacral plexus; the other, posterior and superior, is the *great* or *superior glutæal nerve.* This escapes from the pelvis, along with the glutæal artery and veins, through the upper and anterior part of the great sacro-sciatic foramen, and above the pyriformis muscle; is then bent forwards, and ends in two long branches beneath the glutæus medius, which are destined to supply this and the glutæus minimus and tensor vaginæ femoris muscles. One branch ascends and bends semicircularly along the iliac attachment of the glutæus minimus muscle, supplies it and the medius, and is accompanied by the superior deep branch of the glutæal artery. The inferior branch descends over the glutæus minimus in a layer of loose cellular tissue beneath the medius, supplies both these muscles, and passes obliquely forwards and downwards towards the space between the great trochanter and spine of the ilium, and is lost in the tensor vaginæ muscle.

The Sacral Nerves are six pair: they form their ganglions and divide within the spinal canal into anterior and posterior branches. The *posterior sacral nerves* are very small, pass through the posterior sacral holes, and supply the muscles and integuments of the sacral and glutæal regions; the three superior are covered at their exit from the sacrum by the multifidus spinæ muscle, and divide, as all the other posterior spinal nerves, into internal and external branches. The internal are small, and end in the adjacent muscles and tendons; the external communicate and form loops with each other and with the last lumbar, and distribute their branches to the sacro-sciatic ligaments, glutæus maximus, and integuments. The three inferior are smaller, and are lost in the fibrous structure and integument of the coccygæal region: both the anterior and posterior divisions of the fifth and sixth nerves are very small, and the student must pursue a careful dissection to expose them; the sixth is very minute, and cannot in all cases be found. I do not think it always exists, except as a part of the fifth, which it may have joined in the canal: it may be questioned whether there are six distinct pairs of sacral nerves. Bichat states that the sixth is not always to be found externally, although its ganglion is never wanting in the canal. Although I have occasionally seen it, yet it has been extremely minute, and in some cases I have looked for it in vain.

The *anterior sacral nerves* are very large, particularly the three

superior; the three last are much smaller, and the sixth is very minute, and not always present. The four superior, with the branch from the last lumbar, form the *sacral plexus*, broad and flat, placed on the sacrum and pyramidal muscle, behind the pelvic fascia, which separates it from the internal iliac vessels, from the rectum, and from the other pelvic viscera; its form is somewhat triangular or palmate, the four sacral nerves corresponding to the fingers, and the lumbar branch to the thumb, and the five cords converge to the sciatic foramen. The first sacral, very large, descends obliquely outwards in front of the pyriform muscle, and is joined by the lumbo-sacral; the second sacral, also very large, descends more obliquely outwards into the plexus; the third, much smaller, passes horizontally outwards to the plexus, at some distance below the second; a branch generally unites these in front of the pyriformis; the fourth is considerably smaller, and only a portion of it directly enters the plexus, the remainder of it is distributed to the pelvic viscera; the fifth and sixth do not enter the plexus, but communicate together, as the former does with the fourth. Each of the sacral nerves, immediately after its emergence from the foramen, is joined by a short branch from one of the ganglions of the sympathetic. It sends off the following branches, both internal and external: the internal or pelvic are the hæmorrhoidal, vesical, and muscular, and in the female the uterine and the vaginal; the external branches are the inferior or lesser sciatic, the inferior glutæal, posterior cutaneous, pudic, and great sciatic or posterior crural. All these escape by the lower part of the great sciatic notch, below the pyriform muscle. To expose the *visceral branches*, as well as the early course of some of the external, the lateral section of the pelvis should be made in the manner directed at page 305; the large veins must be emptied, and all the blood carefully washed out. The *visceral branches* arise from the fourth and fifth sacral, but chiefly from the fourth; they are directed forwards into the cavity, and are joined by numerous filaments from the sympathetic nerve, which form the hypogastric plexus, a complex net-work of nervous filaments entangled around the branches of the internal iliac artery, and accompanying these to their terminations. This plexus will be described hereafter with the sympathetic nerve.

The internal or *pelvic muscular* branches supply the levator ani, obturator internus, pyriformis, and sphincter ani. The levator ani of each side receives two branches from the fourth sacral, besides small filaments from the vesical and hæmorrhoidal. The internal obturator nerve arises from the upper part of the plexus, that is, from the lumbo-sacral and first sacral nerves; it accompanies the internal pudic artery through the great sciatic foramen, around the spine of the ischium, and then passes forwards and inwards through the lesser sciatic foramen, and divides into three or four branches, which expand among the fasciculi of the obturator internus muscle. The pyriform muscle receives two or more filaments from the second, third, and fourth roots of the plexus; the sphincter muscles and the lower extremity of the rectum

are supplied by the inferior hæmorrhoidal nerves, which may either arise from the internal pudic, behind the spine of the ischium, or along with it from the lower part of the plexus. The posterior part of the anal region and the coccygæus muscle are also supplied by the terminal filaments of the fifth and sixth nerves. The *lesser sciatic*, *inferior glutæal*, and *posterior cutaneous nerves*, may be all regarded as one large, loose, and flat fasciculus, escaping from the pelvis along with the sciatic artery, below the pyriform muscle, internal but rather superficial to the great sciatic nerve, and covered by the glutæus maximus: this fasciculus passes over the gemelli and quadratus femoris muscles, and separates into the above-named branches. The *inferior glutæal nerve* sends off numerous muscular branches to the glutæus maximus, also cutaneous branches, which descend beneath this muscle to its lower border, become superficial, and run in different directions: some ascend in the integument of the nates. The *lesser sciatic nerve* passes downwards to the space between the tuber ischii and trochanter major, but nearer to the former, round which it twines, and at its lower part divides into two sets of branches, a superficial and a deep; the former pass over the hamstring muscles with the posterior cutaneous nerve, and are lost in these muscles and in the integuments, one long cutaneous branch passes along the ramus of the ischium to the perinæum, and is lost in the scrotum or labium; and the latter pass deeper, and are distributed to the quadratus femoris, upper part of the adductor magnus muscles, &c., and some go to the hip-joint. The *posterior cutaneous nerve* descends obliquely outwards, beneath the glutæus maximus, over the tuber ischii and origin of the hamstrings; it here gives off numerous superficial branches, and then descends along the back of the thigh, beneath the fascia lata, as far as the upper part of the leg; it then pierces the fascia, becomes subcutaneous, and communicates with the external saphenous nerve.

The *pudic nerve* arises from the third and fourth sacral, passes through the great sciatic notch or foramen, internal to the preceding, and is accompanied by the pudic artery; it then re-enters the pelvis by the lesser sciatic notch, and passes upwards and forwards along the internal surface of the tuber ischii towards the pubis, covered by the obturator fascia, and lying inferior to the artery. It then divides into two branches, an inferior and superior; the inferior branch, or the perinæal nerve, is the larger; it ascends obliquely forwards and inwards along the ramus of the ischium to the perinæum, and is distributed to the muscles and integuments in that region; its branches accompany the perinæal branches of the artery, some to the anal region, some to the tuber ischii, but the largest follow the anterior branches; one to the bulb and corpus spongiosum of the urethra is seen among the fibres of the triangular or interosseous ligament. The superficial perinæal branch, in the male, is of considerable size, is placed at first beneath the superficial fascia of this region, forms a scattered plexus or net-work in the cellular tissue, entangled with numerous subcutaneous veins; as it proceeds towards the scrotum it becomes more superficial, and is finally

expended in this cutaneous process. In the perinæum, between the scrotum and anus, I have seen the nerves of opposite sides communicate; they are also joined by cutaneous filaments from the lesser sciatic. The superior branch continues its course along the ramus of the pubis near to the symphysis, along with the terminating branch of the pudic artery; it then passes between the subpubic veins and the layers of the suspensory ligament, and turns forwards along the dorsum of the penis, superficial to the artery, and runs along the median line, increasing in size as it approaches the glans penis, in the subcutaneous cellular tissue of which it terminates. Near the attachment of the crus penis to the pubis it sends a small branch into the corpus cavernosum; on the dorsum of the penis it gives off a large cutaneous branch, which passes obliquely upon the side of the organ, and divides into numerous long filaments, some of which expand on the surface of the corpus cavernosum, others in the skin and subcutaneous tissue as far as the prepuce: the continued dorsal nerve runs more deeply along the median line as far as the corona glandis; here it expands considerably, acquires a reddish, ganglionic appearance, sinks between the crus and the glans, and penetrates the latter in delicate filaments, which can be traced to the fine papillary integument covering this organ. In the female the internal pudic nerve is much smaller than in the male; its inferior or perinæal branch is distributed to the labium, to the side of the vagina, and to its bulb and constrictor muscle; the superior branch, still smaller, passes beneath the arch of the pubes to the dorsum and substance of the clitoris.

The *great sciatic*, or *posterior crural nerve*, is the principal branch of the sacral plexus, and the largest nerve in the body; it proceeds from the four superior sacral nerves, forms a flat, broad band, which escapes from the pelvis below the pyriform muscle, sometimes through it; it soon becomes of a round form, and descends close to the outer side of the tuber ischii, along the back of the thigh, over the obturator tendon, the gemini, quadratus, and adductor magnus muscles, as far as the ham, where it divides into the external and internal popliteal nerves. In this course it is covered superiorly by the glutæus maximus and the hamstrings, inferiorly by the fascia lata and the integuments; while sunk in the fossa, between the tuber ischii and great trochanter, it is covered by a considerable quantity of adipose tissue and by the thick folded margin of the glutæus maximus; below this, or opposite the depression below the nates, it is only superficially covered for a short extent. It is next concealed by the biceps, semitendinosus, and membranosus; and lower down, where these muscles diverge, it is again only superficially covered, and continues so to its division: a small artery from the sciatic accompanies it, and is often enclosed between its fasciculi. This vessel maintains frequent inosculations with the perforating branches of the profunda along the back of the thigh; these inosculations have been found wonderfully increased in number and in size in cases where the femoral artery had been successfully tied long previous to death, and where collateral circulation had been fully

established. The sciatic nerve sends off several cutaneous and muscular branches; the latter supply the three hamstrings, the gracilis, and the adductor magnus. While passing over the quadratus muscle it sends off some articular filaments to the hip-joint, and about the middle of the thigh it often gives off a large articular nerve for the outer side of the knee-joint. This *external articular nerve* arises as often from one of the poplitæal divisions as from the trunk itself; its course is superficial, and parallel to the biceps tendon, downwards and outwards to the external condyle, where it divides into numerous filaments directed forwards, and distributed to the external side of the joint. Although the sciatic nerve generally bifurcates below the middle of the thigh, or at the superior angle of the poplitæal region, yet this division may occur much higher, and not unfrequently it is found at the sciatic foramen, above the spine of the ischium, with a fasciculus of the pyriform muscle interposed. In all cases a little forcible traction can separate the nerve into its two portions from the ham to the pelvis.

The *external poplitæal*, or the *peronæal nerve*, is the smaller division, and may be first pursued, as its general distribution is more superficial than that of the other; it is destined to supply the muscles on the external and anterior aspect of the leg, as well as the integuments of the leg and dorsum of the foot; it descends obliquely outwards, along with the biceps tendon, to the external condyle of the femur, superficial to the external heads of the gastrocnemius and solæus; it then turns forwards through the peronæus longus, round the neck of the fibula, and divides into two branches, the musculo-cutaneous and anterior tibial. The peronæal nerve, before it arrives at the head of the fibula, sends off two or three long branches, termed the *external cutaneous nerves of the leg*. Some of these descend along the outer and back part of the limb, and supply the integuments as low as the outer ankle; and one, the *communicans peronæi*, passes backwards over the outer part of the gastrocnemius, and communicates with the external or posterior saphenous nerve, a branch of the posterior tibial, which will be described hereafter. Some filaments of this communicating nerve are also distributed to the integument of the back of the leg and heel; the communicans peronæi often arises so high as the upper part of the poplitæal space. As the peronæal nerve passes round the joint it gives off articular and cutaneous branches.

The *musculo-cutaneous nerve* descends at first in the substance of the peronæus longus, and then between it and the extensor digitorum longus; to these and to the short peronæi muscles it sends several muscular branches; about the middle of the leg it perforates the fascia, between the peronæus longus and brevis, and a little above the outer malleolus it divides into the internal and external tarsal nerves, or *dorsal nerves of the foot*. The *internal* is distributed to the integuments of the first and second toes, and communicates with the internal saphenous nerve and with the anterior tibial. The *external* supplies

the integuments on the three outer toes, and communicates with the internal branch and with the external saphenous nerve.

The *anterior tibial*, or *interosseous nerve*, descends obliquely forwards, along with the anterior tibial artery, between the tibialis anticus and the extensor digitorum longus and extensor pollicis, which muscles it supplies ; it also sends branches through the fascia to the integuments. In this course down the leg it accompanies the anterior tibial artery, lying at first to its outer side, and then in front of it ; but near the ankle it is again external to it, and then passes along with it, beneath the anterior annular ligament, over the synovial membrane, and enclosed in a sheath along with the extensor pollicis tendon. On the tarsus it divides into an external and internal branch ; the external or tarsal passes outwards beneath the extensor brevis muscle, close to the tarsal bones and joints, divides into several reddish and expanding filaments, which supply this muscle and the adjacent articulations. The internal branch is the continued trunk, accompanies the dorsal artery of the foot to the first interosseous space, gives off small muscular filaments to the muscles in that space, which maintain a delicate communication with the external plantar nerve, and ends in two branches which supply the dorsal integument on the opposed sides of the first and second toe. In this course along the foot it gives off subcutaneous and cellular filaments, which communicate with the dorsal cutaneous nerves from the musculo-cutaneous.

The *internal poplitæal*, or *posterior tibial nerve*, is much larger than the preceding ; in direction and size it is the continued trunk of the sciatic, and is destined to supply the large muscles on the back of the leg, and the muscles and integuments of the sole of the foot ; in the ham it may be named poplitæal, in the leg posterior tibial.

The *poplitæal nerve* descends nearly vertically between the heads of the gastrocnemius and solæus muscles, behind the articulation of the knee and the poplitæus muscle, passes beneath a tendinous arch in the solæus, and becomes the posterior tibial. In this course the poplitæal nerve is covered by the skin and by the strong aponeurosis of this region ; is superficial to the artery and vein, and separated from them superiorly by a considerable quantity of fat, but inferiorly is in close contact with them ; above, the nerve is to their external side, but as it descends obliquely inwards it gradually crosses them, and inferiorly is inclined to their inner aspect, but still superficial to them. In this course it gives muscular, articular, and cutaneous branches. The *muscular* are very large, and some of them are very long ; they arise behind the knee-joint ; a large branch divides into two for each portion of the gastrocnemius ; these ramify on their deep or anterior surface, and soon enter the interstices between their fasciculi. The plantaris receives a small branch either from the last or from the trunk of the poplitæal. Another large nerve descends between the gastrocnemius and solæus, ramifies on the superficial or posterior surface of the latter, and penetrates its structure ; lower down arises the nerve for the poplitæus,

this ramifies on its surface, and some filaments bend round its lower border, and are lost on the deep aspect of the muscle. The *articular branches* are usually three in number, superior and inferior internal, and azygos or middle; these accompany the corresponding arteries, and supply the synovial membrane and the other articular tissues. The external articular nerves are derived from the peronæal nerve. The *cutaneous branch* is also named *external saphenous*, or *communicans tibialis*, or *posterior cutaneous nerve of the leg*. It arises as a large branch about the middle of the ham, or sometimes higher, either from the trunk of the poplitæal, or in common with one of the long muscular branches; it descends in the groove between the heads of the gastrocnemii, beneath the fascia, accompanied by a small artery and vein; about the middle of the leg it perforates the fascia, and is joined by the communicans peronæi nerve (this sometimes joins it beneath the fascia); it is here also often joined by a filament from the posterior cutaneous nerve of the thigh, a branch of the sacral plexus. The external saphenous nerve, now subcutaneous, soon meets the external or posterior saphena vein, and descends along with it obliquely outwards to the outer border of the tendo Achillis, and then bends forwards behind the outer malleolus to the external border of the foot and little toe. In this course it gives but few branches to the integuments of the leg; near the heel it sends off several long and large filaments, which descend and expand in the granulated fat on its side and under surface; along the outer border of the foot it supplies the integuments both on the plantar and dorsal surface; the branches to the latter communicate with the external dorsal nerves of the foot from the musculo-cutaneous of the peronæal.

The *posterior tibial nerve*, or continued poplitæal, descends behind the tibia obliquely inwards from the lower margin of the poplitæus muscle to the internal malleolar region; here it becomes flat and thick, and divides into the internal and external plantar nerves. In this course it passes beneath the tendinous arch at the upper end of the solæus, protected by it from the pressure of the surrounding muscle, then beneath the entire mass of the superficial muscles on the back of the leg, also beneath the strong fascia which separates these from the deep muscles, the tibialis posticus, and flexor communis, on which it rests. Along the inner side of the tendo Achillis it is only covered by the skin and aponeurosis; it accompanies the posterior tibial vessels, being to their inner side above for a short distance, and external to them during the remainder of its course. In the malleolar region it is placed external or posterior to the sheaths of the tibialis posticus and flexor communis, and to the tibial vessels, and anterior to the sheath of the flexor pollicis longus. In this region it is only covered by the skin and by a tense aponeurosis, consisting of two laminæ. This nerve, in the upper part of the leg, sends muscular branches to the tibialis posticus, flexor communis, and flexor pollicis; that to the latter accompanies the fibular artery, and sends small filaments through the interosseous membrane. On the inner side of the tendo

Achillis it gives off one or two very large branches, which pierce the fascia and descend to the integument on the internal and inferior surface of the heel and inner side of the sole of the foot.

The *internal plantar nerve* is larger than the external; it passes forwards along the inner side of the tarsus above the abductor pollicis, accompanied by the internal or smaller plantar artery, sends many branches to the plantar muscles and to the integuments, and, arriving near the base of the great toe, divides into four digital branches. The first runs along the tibial side of the first toe; the second subdivides and supplies the opposed sides of the first and second toes; the third, in like manner, the second and third toes; and the fourth the opposed sides of the third and fourth toes: these digital nerves also supply the lumbricales, and give off dorsal cutaneous branches, which communicate with the dorsal nerves of the foot.

The *external plantar nerve* passes forwards and outwards, along with the external plantar artery, above the flexor brevis and beneath the long flexor tendons and their accessory muscle, to the fifth metatarsal bone, and divides into two branches; one, the superficial, supplies both sides of the little toe and the outer side of the fourth; the deep branch passes obliquely inwards, in the form of an arch, across the metatarsus, and supplies the interossei and the other deep plantar muscles.

SECTION III.

DISSECTION OF THE GANGLIONS.

In addition to the five small ganglions on each side, already noticed in the description of the cerebral nerves, viz., the Casserian, the lenticular or ophthalmic, the spheno-palatine or Meckel's, the sub-maxillary, the Otic, or the ganglion of Arnold, also the several ganglions on the posterior roots of the spinal nerves, we find one continued chain of these bodies placed along the vertebral column on either side of the median line, and at regular intervals. These ganglions, on each side, are all connected to each other, and resemble a knotted cord; these cords receive the name of the sympathetic nerves.

The Sympathetic Nerves, therefore, are two in number; they descend from the base of the cranium perpendicularly along the neck, placed anterior to the vertebræ, on the rectus capitis and longus colli muscles, and behind the great vessels and nerves. At the upper end of the chest each of these nerves is divided by the subclavian artery into several branches, which encircle that vessel and unite below it in the thorax. Through this cavity they descend at first obliquely backwards and outwards along the side of the spine, over the heads of the ribs, and their stellate ligaments, and covered by the pleura; they

then incline a little forwards, and pass behind the true ligamentum arcuatum into the abdomen; through this region they descend obliquely outwards on the forepart of the lumbar vertebræ, between the psoæ and the crura of the diaphragm; they then sink into the pelvis, keeping close to the sacrum, and descend along the anterior surface of this bone obliquely inwards; near its inferior extremity, or on the first part of the coccyx, they unite and terminate in a small ganglion, named coccygæal, or impar. The superior extremity of each sympathetic nerve is connected by several filaments to several of the cerebral nerves. Some of these connexions, particularly that to the sixth, have been improperly termed the origin of the sympathetic; at the base of the cranium it communicates, either directly or indirectly, with the seventh, eighth, and ninth; in the cavernous sinus and orbital plexus with the third, fourth, fifth, and sixth; and even with the olfactory, optic, and auditory, by the fine filaments which accompany the nutrient arteries of those several orgâns in which these nerves expand and terminate: it also communicates, as has been already noticed, with the several ganglions in the head. In their course along the spinal column, each nerve regularly communicates with every pair of the spinal nerves, with each of the cervical nerves by one, and sometimes by two filaments, and with each of the dorsal, lumbar, and sacral nerves by two, so that these nerves may be said to communicate with every nerve in the cerebro-spinal system. The sympathetic nerves have been considered by some as independent nervous systems, communicating by numerous branches with every portion of the cerebro-spinal system; by others they are regarded as nervous cords, formed by the union of branches from all the spinal and from several of the cerebral nerves: the latter is probably the more correct view. The doctrine propounded by Bichat has had many supporters. This distinguished anatomist and physiologist maintains that there are two distinct nervous systems, one presiding over volition and all the functions of animal life, the other over all the organic functions and involuntary motions; the cerebro-spinal axis, the cerebral and spinal nerves, constitute the first, the numerous ganglions the second. All these latter bodies he accordingly associates in one group, and describes the lenticular or ophthalmic and spheno-palatine as offsets from the superior cervical ganglion. This arrangement has been adopted by many subsequent anatomical writers. Bichat further contends that there are no such nerves as the sympathetic, and that none such ought to be described; but that, scattered at intervals along the whole length of the spine, are a number of ganglions of irregular and variable form and size; that these are each independent centres of nervous matter and distinct sources of nervous power; that they communicate with all the nerves of animal life, also with one another, and that the latter series of connecting filaments (commonly called sympathetic nerves) are merely communicating branches, and very variable as to size, and even as to existence, and that some of these are occasionally wanting, so as to cause an interruption or want of continuity in the cord in

some parts, as between the thorax and abdomen, where the connecting filament is often extremely minute, and, according to Bichat, sometimes absent. These views, though very ably and ingeniously maintained (*see* Bichat's Anat. Gen., tom. i. p. 215, *et seq.*), are strongly opposed to the opinions and more accurate researches of modern observers, as also by the excito-motor theory. Two very obvious objections also present themselves to this proposed division of all the nerves into two distinct orders, animal and organic: the first is, that the eighth pair, or pneumogastric, large nerves in the cerebral or animal system, are as much engaged in some of the important functions of organic life as any of the ganglionic nerves; and the second is, that the thirty or thirty-one pairs of spinal ganglions are excluded from either class; these clearly appertain to the cerebro-spinal system, and yet are associated with the organic ganglions in many instances as distinctly as either the lenticular or spheno-palatine. Indeed Bichat himself admits that the ganglions on the posterior roots of the spinal nerves form an important exception to his arrangement, and one which he is unable to qualify or to explain away (*see* tom. i. p. 232). Without entering further into physiological discussion as to these different views, it appears to me that, in studying the anatomical relations of the ganglionic system, or the sympathetic nerves, it is advisable to regard them as two nervous cords, extending from the head to the coccyx, along the spine, and formed most probably by converging filaments or roots from all the spinal nerves, ganglions existing at the numerous points of junction. I have also considered it advisable for the student to examine the several small ganglions in the head along with those cerebral nerves to which they are principally connected, or more obviously so than they are to the sympathetic. The student may now proceed to examine the sympathetic nerves, their ganglions, and their branches: the structural peculiarities of this nerve shall be noticed after its descriptive anatomy. Although perfect symmetry does not exist between these on the right and left sides, yet the differences are but trifling. The sympathetic nerves send off numerous branches, which are chiefly destined to supply the heart and the coats of the great vessels, and all the pelvic and abdominal viscera, except the stomach. These should be examined distinctly in the four regions in which they exist, the neck, chest, abdomen, and pelvis. These branches arise from the ganglions on these nerves; of these there are generally three in the neck; in the back and loins they correspond with the number of vertebræ in those regions, and in the pelvis there are three on each side, and the coccygæal or impar ganglion below.

The *cervical ganglions* are three, the superior, middle, and inferior. The number, however, is variable, frequently there are only two, occasionally there are four: sometimes the superior is continued along the cord more than half-way down the neck; the number and size often vary on the opposite sides.

The *superior cervical ganglion* is of an oval figure and reddish colour,

extending from the first to the third cervical vertebræ, placed on the rectus capitis anticus, behind the carotid artery and jugular vein, and internal to the eighth and ninth cerebral nerves; its upper end is very small, and about half an inch beneath the carotid foramen in the petrous bone; its lower is often undefined, but is usually on a level with the lower border of the third cervical vertebra; it is sometimes round and prominent, sometimes prolonged upon the cord, and sometimes bifid. This ganglion sends off several branches, viz., superior, inferior, internal, external, and anterior. The *superior branches* are two in number; they ascend in the carotid canal to the cavernous sinus, and communicate with the sixth and with the vidian branch of the fifth. In the carotid canal they form the internal carotid plexus, which is entangled with fine areolar tissue and capillary vessels, and sometimes presents some ganglionic appearance. From this plexus some filaments pass through the petrous bone into the tympanum, and join the nerve of Jacobson, a branch from the glosso-pharyngeal; it next gives off (or, according to some, receives) the vidian branch to the spheno-palatine; above this, and at the lower part of the cavernous sinus, branches join the sixth nerve; the latter appears flattened and slightly enlarged at the junction. In this sinus the ascending small filaments, two or three in number, again form a plexus, named *cavernous plexus;* this is chiefly on the inner side of the artery, while the sixth nerve is on its outer side. From this plexus filaments pass to the Casserian ganglion, others to the orbital plexus and lenticular ganglion, and the remainder accompany the artery to the brain, subdivide into extremely minute filaments, which follow the ophthalmic and the other branches of the artery. The *inferior* or *descending branch* is the continued cord of the sympathetic itself, which joins the middle or inferior cervical ganglion, and is very variable as to colour and size. The *anterior branches* are numerous; some communicate with the eighth and ninth in the great basilar plexus, others surround the external carotid, and divide into fasciculi, which accompany all its branches, and form loops and plexuses around each, named, from their destinations, thyroid, lingual, &c. Most of these branches are of a grey colour, and very soft, and have been named by Scarpa "nervi molles." The *external branches* join the superior cervical nerves; they are large and ganglionic, some join the nervous loop, the principal unite with the second cervical, and others with the third and fourth. By careful dissection these communicating spinal branches may be traced along the spinal nerves into the intervertebral foramina. Their connexion with the anterior root of each is very obvious; but I have frequently demonstrated filaments continuing to the ganglions on the posterior roots. Although these uniting branches are here described as arising from the sympathetic, it would probably be more correct to consider them as proceeding from the spinal nerves, to form the cervical roots of the sympathetic. The *internal branches* are pharyngeal, laryngeal, and cardiac. The *pharyngeal* arise from the superior part of the ganglion, are of a pale red colour and ganglionic structure; they

pass inwards and join the pharyngeal branches of the glosso-pharyngeal and pneumogastric in the extensive plexus which supplies the pharynx and fauces. The *laryngeal branches* arise near the last, pass downwards and inwards, and join the branches of the superior laryngeal nerve. The *superior cardiac*, or superficialis cordis, arises near the lower part of the ganglion, descends obliquely inwards, behind the sheath of the common carotid, along the side of the trachea and œsophagus, crosses in front of the inferior thyroid artery, and becomes nearly parallel to the inferior laryngeal nerve; it then enters the chest, sometimes anterior, sometimes posterior to the subclavian artery; on the right side it follows the innominata, arrives at the back part of the arch of the aorta, and passes obliquely inwards between this and the trachea, and joins the great cardiac ganglion, which shall be considered presently. The superficial cardiac nerve often arises by several filaments, some of which are from the cord below the ganglion, others from the vagus; in its descent also it is often joined by branches from this nerve, and inferiorly from the recurrent; it sometimes passes behind the inferior thyroid artery, or, dividing into two branches, these separate, enclose the artery, and reunite. As it enters the chest it is frequently joined by filaments from the other cardiac nerves and from the inferior cervical ganglion of the sympathetic; before it enters the cardiac ganglion it sends off some filaments to the forepart of the innominata and of the arch of the aorta. The nerve of the left side pursues an analogous course; but these nerves on either side are extremely variable, and the description will seldom exactly accord with the dissection.

The *middle cervical ganglion* is sometimes wanting; it is smaller than the superior, of a triangular, often of an irregular form; is situated behind the carotid near the curve of the inferior thyroid artery, opposite the fifth vertebra, and upon the longus colli muscle; it sends off branches in different directions, externally to communicate with the fourth and fifth cervical nerves, internally with the vagus: from its anterior and internal aspect it sends off the *middle* or *great cardiac nerve*, which descends parallel to the recurrent, communicating with it and with the vagus, and with the superior and inferior cardiac nerves, enters the chest in several branches, which pass around the subclavian artery, and finally join the cardiac ganglion and plexus.

The *inferior cervical ganglion* is of an irregular figure, semilunar or triangular; it frequently appears to consist of several small ganglions, connected to each other by reddish filaments; it is situated between the transverse process of the last cervical vertebra and the neck of the first rib, behind and on either side of the vertebral artery, and between the scalenus and longus colli muscles; filaments from it communicate with the phrenic nerve and with the brachial plexus; several also encircle the subclavian artery, and unite beneath it in the first thoracic or dorsal ganglion; its external branches join the three last cervical and first dorsal nerves; some extend along the subclavian or axillary artery and its branches, and may be traced to a great distance, forming

plexuses in their tissue; a considerable fasciculus ascends along the vertebral artery, forms plexuses around this vessel, which, in their ascent, communicate with the cervical nerves through the intertransverse spaces. These may be followed into the cranium; those of opposite sides unite on the basilar artery; they follow its branches, on which they communicate with the analogous filaments from the carotid plexus. From its internal aspect proceed the *inferior cardiac nerve*, or nerves, which communicate with the middle and with branches from the vagus and recurrent, and pass inwards between the aorta and division of the trachea, and end in the cardiac plexus.

The student may next examine the *cardiac nerves, ganglion*, and *plexus*. These nerves are extremely irregular as to origin, size, course, and number. Scarpa has delineated them beautifully, but few dissections will be found exactly to correspond with his representations or descriptions; there are usually three on each side, and are named superior, middle, and inferior. The *superior* cardiac nerve, though very small, takes a long course; it arises by two or three filaments from the inner and forepart of the superior cervical ganglion, but is very variable; descends along the side of the trachea, behind the carotid artery, to the chest. In this course it communicates with the laryngeal nerves, with the vagus, and with the inferior and middle ganglions of the sympathetic; there is sometimes a small ganglion upon it near the inferior thyroid artery; at the lower part of the neck it passes behind the subclavian vein, and over, but sometimes behind, the subclavian artery, or encircling it with its branches, then passes along the lower and posterior aspect of the arteria innominata. It here divides into several filaments; some pass along that vessel to the forepart of the aorta, others join the recurrent nerve and the middle and inferior cardiac nerves. The superior cardiac nerve on the left side has a similar origin and course in the neck, but it enters the chest in a deeper situation than the nerve of the right side; it descends between the left carotid and subclavian arteries, and, arriving at the arch of the aorta, divides into branches, some of which pass behind that vessel and join the cardiac ganglion; others unite with the cardiac nerves from the sympathetic, or from the vagus and recurrent. The *middle* cardiac nerve on the right side is generally the largest of the cardiac nerves; on the left side it is sometimes wanting; the inferior in such a case will be of a greater size; it arises by several filaments from the middle cervical ganglion, or from the sympathetic nerve about the middle of the neck; it descends, either a single cord, or divided into several parallel filaments, behind and internal to the carotid, and enters the thorax anterior to or encircling the subclavian artery. It here is joined by large branches from the vagus and recurrent nerves; it then descends obliquely inwards along the side of the arteria innominata, glides between the arch of the aorta and the division of the trachea, and terminates in the cardiac ganglion or plexus. On the left side the middle cardiac nerve sometimes arises from the inferior cervical ganglion; it enters the chest along the subclavian artery, and either joins the inferior car-

diac nerve, or enters the cardiac plexus. The *inferior* cardiac nerve, or nerves, proceed from the inferior cervical ganglion, and on the right side descend behind the arteria innominata to the arch of the aorta, round which some pass to its forepart; the others terminate principally in the anterior cardiac plexus. Some branches pass between the aorta and pulmonary artery to the cardiac ganglion; these inferior cardiac nerves communicate with the preceding, also with the vagus, and especially with its recurrent; they form an irregular net-work or plexus in their course to the aorta. On the left side these nerves accompany the subclavian artery, and partly join the middle cardiac nerve, and partly the cardiac plexus. Thus the cardiac nerves of one side communicate freely with each other on the sides and forepart of the trachea and with those of the other side in the concavity of the arch of the aorta, both below and above the right or transverse branch of the pulmonary artery.

The *cardiac ganglion* is situated within the arch of the aorta, on the right side of the ductus arteriosus; it is joined by the right and left superior cardiac nerves, and by branches from the pneumogastric. Its size and structure are very variable; instead of a single distinct ganglion it often appears as a congeries of small ganglions entangled in the plexus of the uniting nerves.

The *great cardiac plexus* is exposed by dividing the aorta and pulmonary arteries above their roots; it is situated behind the ascending aorta, near its origin, and in front of the division of the trachea, and above the right pulmonary artery; it consists of a plexus of nerves formed by the middle and inferior cardiac nerves from opposite sides, also by branches from the eighth pair and the recurrent nerves. In the meshes of this plexus several small ganglions are enclosed; the roots of the large vessels and the structure of the heart are supplied by branches from the great cardiac ganglion and plexus, and from the cardiac nerves. These branches form two smaller plexuses, named the anterior or superficial, and the posterior or deep.

The *superficial* or *anterior cardiac*, or *coronary plexus*, is placed on the forepart and right side of the aorta near its root; it is formed partly by filaments from the superior cardiac nerve, and from the cardiac ganglion and plexus; the latter come from beneath the arch, between it and the right auricle. Many of the former can be seen, without dissection, upon the convexity of the aorta, through the serous membrane; the branches spread over the anterior surface of the heart; some accompany the left coronary artery, but the greater number surround the right or anterior coronary, and form a plexus around it, and the filaments accompany the branches of this vessel, and supply the right auricle and ventricle. The *posterior plexus* is formed of branches from the great cardiac plexus and left inferior cardiac nerve; it is behind the root of the aorta and between this vessel and the pulmonary artery, and above the auricular sinuses; its branches principally accompany the left coronary artery, form a plexus around it, and follow its ramifications through the tissue of the left

ventricle; other branches pass into the auriculo-ventricular sulcus towards the right side, and join the anterior plexus. The coronary plexuses, so named from their attachment to the coronary arteries, supply both auricles and ventricles; the branches to the latter are larger and more numerous; at first they are distinguished with some difficulty from the vessels and from the serous tunic. If the heart be immersed for some time in boiling water, or allowed to remain a few days in strong spirits, the nerves can be easily exposed; they are extremely minute, but very long, and can be traced at first parallel to the muscular fasciculi, then crossing them, and subdividing into their ultimate fibrillæ.

The sympathetic nerves in the thorax have twelve ganglions on each side of the spine, sometimes only eleven, the last cervical and first dorsal being then united. Each of the *thoracic ganglions* is small, flat, and triangular, the base towards the spine, the apex externally, covered by the pleura and a thin fascia; they are placed on the heads of the ribs, in front of the intercostal vessels; the first, second, and last are the largest; they all communicate by their external branches with the anterior or intercostal branches of the spinal nerves. These branches are two in number, white and fibrous; they in general ascend obliquely to join the spinal nerves, which they resemble in structure, and ought properly to be considered as the dorsal roots of the sympathetic. From the base or anterior edge of each ganglion arise the *internal* branches, the mediastinal and the great and lesser splanchnic. The mediastinal or aortic branches pass forwards into the posterior mediastinum, ramify on the aorta and its intercostal branches and the adjacent vessels, and communicate with the pulmonary plexus: those from the right side are longer, as they have to cross the spine. From the six inferior ganglions the splanchnic nerves arise; these are two in number on each side, the greater and lesser, or upper and lower.

The *great splanchnic nerve* arises by four or five distinct roots from the sixth, seventh, eighth, ninth, and tenth ganglions; they descend obliquely forwards, and unite on the tenth dorsal vertebra into one large, flat cord, which enters the abdomen either along with the aorta or separated from it by a fasciculus of the diaphragm; each nerve then expands into the semilunar ganglion. The great splanchnic nerves are very variable as to their number of roots, there being sometimes only two, sometimes five or six; that from the sixth ganglion is the largest. This nerve is white and fibrous, and more like the spinal than the sympathetic: careful dissection can loosen and detach it in a great degree from the ganglions, and shew its real origin to be from the spinal system.

The *lesser splanchnic nerve* arises by two roots, from the tenth and eleventh ganglions; these unite on the side of the last dorsal vertebra. This small nerve then enters the abdomen through the crus of the diaphragm external to the great splanchnic nerve, with which it communicates, and then ends in the renal plexus; it sometimes escapes along with the great splanchnic. There are sometimes two nerves answering

this description, one of which will join the first lumbar ganglion, and may thus maintain the communication between the thoracic and lumbar portions of the sympathetic. Before we trace the latter we shall follow the great splanchnic nerves, which form the chief supply of nerves to the abdominal viscera.

The *semilunar ganglion* of each side is situated on the diaphragm, and partly on the aorta, on either side of the cœliac axis, and above and behind the suprarenal capsule. These are the largest ganglions on the sympathetic; though called semilunar, their form is very variable and irregular, and frequently, instead of a single mass, they consist of a congeries of knotted ganglions on the nervous cord; the right and left communicate with each other by several filaments, on which again small ganglions are placed. This communication surrounds the cœliac axis, and, as branches radiate from it in all directions, it is termed the *solar plexus*. This plexus is situated in the epigastrium, behind the stomach, in front of the aorta, and above the pancreas. In this plexus there are also some filaments from the lesser splanchnic and phrenic nerves, and the right vagus terminates in it; it is the most highly developed portion of the sympathetics, and has been regarded as the head or centre of the great organic nervous system by some, who maintain the independence of the ganglionic system and its distinctness from the cerebro-spinal nerves. From it numerous nerves pass off in various directions; these nerves accompany the blood-vessels, and form plexuses around each, which are named, according to their destination, *hepatic*, *splanchnic*, *gastric*, &c.

1st. The *phrenic plexuses* consist of branches arising on each side from the upper part of the solar plexus, accompany the phrenic arteries, and enter the diaphragm beneath the peritonæum; some branches follow the phrenic vessels, others pass in different directions, and join some minute filaments from the phrenic nerves of the cervical plexus.

2nd. The *suprarenal plexuses* arise partly from the last, and, by some delicate filaments from the semilunar ganglion of each side, they twine around the arteries which conduct them into the suprarenal bodies.

3rd. The *coronary* or *gastric plexus*.—This fasciculus arises from the upper and anterior part of the solar and from the right vagus, accompanies the arteria coronaria ventriculi, along the lesser curvature of the stomach, to the lesser omentum; its filaments are lost in the submucous tissue, and communicate with those of the right and left vagi.

4th. The *hepatic plexus* is a very large fasciculus, arising partly from the solar and partly from the semilunar ganglions; its large posterior filaments accompany the vena porta, and its anterior the hepatic artery; these nerves accompany the vessels in the lesser omentum to the liver; some are very large and distinct, they enter the transverse fissure, and ramify along with the vessels through the capsule of Glisson. While in the lesser omentum they send long filaments to form the right gastro-epiploic plexus along the great border of the stomach; others also along the cystic artery to the gall bladder.

5th. The *splenic plexus* proceeds in a similar manner around the splenic artery; it is not so large as the hepatic; it sends many filaments to the pancreas, to the great end of the stomach, and along the left epiploic artery, to its great curvature: the remaining few filaments enter the spleen.

6th. The *superior mesenteric plexus* is a very broad and thick fasciculus, continued from the lower border of the solar; it forms a complete sheath for the superior mesenteric artery; its branches are numerous, very long, and distinct; they accompany the arteries, but are straight, and do not form the same number of arches as the vessels are remarkable for: near the intestine many of them usually unite in an arch, from which fine filaments enter the tissues of the intestine. This plexus supplies all the small intestines, the cæcum, ascending colon, and right portion of its transverse arch.

7th. The *renal plexuses* are formed by branches from each side of the solar, joined by the lesser splanchnic nerves; they surround the renal arteries, and accompany them into the kidneys. In the male each renal plexus gives off a fasciculus to accompany the spermatic artery, around which it forms the *spermatic plexus*, and descends to the testis; in its course along the psoas it gives off filaments to the ureter. In the female corresponding branches from the renal plexuses supply each ovary.

8th. The *inferior mesenteric plexus* is much smaller than the superior, from the root of which it is principally derived, being also joined by branches from the lumbar ganglions of the sympathetic; it accompanies the inferior mesenteric artery and its branches, and supplies the left portion of the arch, the descending and the sigmoid flexure of the colon.

9th. The *hæmorrhoidal plexus* is formed by the filaments of the inferior mesenteric, continued around the superior hæmorrhoidal arteries, joined by small branches from the lower lumbar ganglions; it supplies the superior and middle portions of the rectum, and communicates with the hypogastric plexus.

From the sympathetic cords in the thorax a small branch is continued obliquely downwards and forwards on each side, close to the spine, and behind the crus of the diaphragm, to join the first lumbar or abdominal ganglion. This branch is seldom absent; when it is, the inferior splanchnic nerve, after joining the renal plexus, enters this ganglion, so that the continuity is always maintained between the thoracic and abdominal portions of the sympathetic nerves. The *lumbar ganglions*, and their connecting thread, are placed on the anterior aspect of the lumbar vertebræ, in a tendinous groove, between the crus of the diaphragm and psoas magnus of either side, nearer the median line above, but diverging below; they are variable in number, usually four, and sometimes only three, and often one is prolonged into another. The *external branches* of each are two, *communicating;* they accompany the lumbar arteries, beneath the psoas muscle, close to the grooves on the sides of the vertebræ, and join the anterior lumbar

nerves in the intervertebral foramina; they are white and distinct, and may be regarded as the lumbar roots of the sympathetic. These branches frequently have ganglions upon them, and they often unite with filaments from the lumbar plexus.

The *anterior* and *internal branches* are aortic and splanchnic. The aortic branches are numerous, they pass forwards in front of the aorta, the nerves of opposite sides unite, and are joined by branches from the solar plexus, and form a plexus, *lumbo-aortic*. This surrounds the aorta between the superior and inferior mesenteric arteries; small arteries, and lymphatic glands and vessels are entangled in it; some of its branches join the inferior mesenteric plexus; inferiorly it divides into three portions; the middle enters the pelvis, and joins the hypogastric plexus; the lateral accompany the common iliac arteries to their division, and several filaments are prolonged around the internal and external iliac vessels. The *splanchnic branches* pass forwards from each ganglion, and join the several abdominal plexuses already mentioned.

The *hypogastric plexus* is of considerable extent; it is formed by the continuation of the lumbo-aortic plexus, joined by filaments from the lumbar ganglions; is situated in front of the base of the sacrum, between the common iliac arteries, and divides into a *right* and *left hypogastric plexus;* each of these is joined by branches from the sacral ganglions and anterior sacral spinal nerves; each plexus sends off numerous branches, which again form secondary plexuses on the organs to which they are distributed. Thus we have hæmorrhoidal, vesical, prostatic, vesicular, ovarian, and uterine plexuses. All these plexuses contain filaments from the sacral nerves as well as from the sympathetic, and all are conducted to their termination by the arteries of each organ.

As the sympathetic cords descend obliquely inwards, over the base of the sacrum, behind the iliac vessels, they are extremely small; in the pelvis they at first increase in size, descend converging, and each ends in a minute thread; they are placed near the inner margin of the anterior sacral foramina. The *sacral ganglions* are four or five in number, of an oval or round form; their *external branches* join the anterior sacral nerves; their *internal branches* join the hypogastric, or some of their secondary plexuses. From the last ganglion a small branch arches across to meet a similar one from the opposite side; on this a small ganglion (*impar*) is occasionally to be found; if absent, a connecting plexus occupies its place: the terminal filaments are very minute, and distributed to the forepart of the os coccyx.

Although the sympathetic nerves and their branches appear to differ in structure from that of the cerebro-spinal nerves, yet they are essentially the same; the fibres seldom appear so white, but have rather a greyish, red colour. The general neurilemma of each nerve is more dense, and, therefore, the internal fibrous or fasciculated texture is not so obvious; but, if the former be carefully divided, the latter will be found equally apparent. The great distinction depends on the

occurrence of numerous ganglions, both on the principal cords as well as on their branches; each ganglion is invested with a firm capsule, which is continuous with the sheath of the afferent and efferent nerves. This capsule is surrounded by areolar tissue and blood-vessels; the latter ramify on and pierce the capsule; the internal surface of the latter is very vascular, and may on the larger ganglions be separated as a vascular membrane from the external fibrous layer, and is analogous to the pia mater on the cerebro-spinal axis. The mass of a ganglion is composed of a plexus of nervous filaments, with a variable quantity of vesicular or grey neurine; the afferent nerves divide into numerous fibrillæ, which pass in the most varied directions, and reunite most probably in different combinations, the interstices being filled with capillary vessels and grey neurine. Whether the efferent nerves consist of those filaments only which composed the afferent, or whether additional fibres are added to these in the ganglion, it is difficult and, in the present state of our knowledge, impossible to determine. The only material difference to be observed between the structure of the ganglions of the sympathetic and those of the cerebro-spinal system is, that the latter appear in general to be less red and vascular, and to contain less of the vesicular or grey neurine; the interlacement of white fibres is more obvious in them, and constitutes the greater portion of each, particularly of the spinal ganglions.

CHAPTER IV.

ORGANS OF SENSE.

The organs of the senses establish certain relations between man and the external world, and are the instruments, or media, whereby he obtains all his knowledge of the physical characters and of the general and particular properties of all surrounding objects. They are generally considered as five in number, viz., the nose, or the organ of smell; the tongue, or the organ of taste; the eye, or the organ of vision; and the ear, or the organ of hearing. To these may be added the integuments, or the organ of touch. Each organ of sense is placed near the surface of the body, is furnished with an appropriate apparatus suited to its peculiar function, and is in direct connexion with the nervous centre. The four first-mentioned organs are connected to particular portions of the brain, each by its proper or peculiar nerve; but the sense of touch being disseminated over the whole surface of the body, and its apparatus being supplied by the posterior or ganglionic roots of the fifth cerebral and of all the spinal nerves, is therefore connected to the cerebro-spinal axis generally.

SECTION I.

ANATOMY OF THE SKIN, OR ORGAN OF TOUCH.

As the *sense of touch* is diffused over the whole surface of the body, and is uniformly present, though in very different degrees in the different classes of the animal kingdom, and as the apparatus for its development is more simple than that for the other senses, we shall consider it first. This sense resides essentially in the skin, but it also exists more or less in the mucous surfaces, particularly near their outlets, as in the mouth, anus, and urethra; also in the conjunctiva or mucous membrane of the eye, and in that of the nose, fauces, and larynx: indeed, as the skin and mucous membranes are continuous, so are they closely allied in function and in structure, and both may

be regarded as one extensive membraneous expansion, investing the whole external surface of the body, and lining all the hollow viscera of the respiratory, digestive, urinary, and generative apparatuses, and also prolonged into all the follicles, excretory ducts, and their tubular ramifications through the secreting glands. This extended membrane, though differently modified in different portions of its extent to suit particular purposes, is yet analogous in structure throughout, and is essentially composed of the same elements, namely, of two laminæ; one is external or superficial, and named cuticle, or epidermis, or epithelium; the other is deeper, and is named the cutis vera, dermis, or chorion. Beneath the latter is added more or less of areolar, or cellular, and adipose tissue, which serve to support and conduct the numerous vessels and nerves that supply this highly organized structure.

The sensibility of the skin renders the individual not only sensible to the contact and pressure of external objects, but also enables him to appreciate many of their physical qualities, such as their temperature, size, form, consistence, and weight; all parts of the skin, and indeed most structures in the body, possess a certain degree of sensibility to temperature and to contact, that is, they possess *touch* generally; but the power of discerning the other qualities of bodies is developed only in certain situations, where there is a corresponding refinement of organization and development of sentient papillæ, which are enabled to take cognizance of these qualities with a wonderful degree of nicety and perfection. This power is by some denominated the sense of *tact*, and resides especially in the integument of the fingers and toes.

The skin also effects other important purposes in the animal economy; it forms a perfect covering for the body, which is strong, dense, and resisting, but flexible, yielding, and elastic, and, while its external lamina is sufficiently thin to allow impressions to be conveyed to the deeper sentient surface, it is itself an insensible protecting investment. The skin is also the seat of an important secretion, which serves to purify or aerate the blood in a manner somewhat analogous to respiration: this secretion is discharged in the form of a fine halitus or vapour, named the "insensible perspiration;" but when the circulation is increased in activity, or when the body is exposed to a high degree of temperature, it is given forth in the form of minute drops, which appear like dew upon the surface, and is then called "sensible perspiration," or "sweat." This exhalation carries off from the blood a large quantity of water, carbonic acid, saline, and various animal or azotized matters, which are effete or injurious to the system. The importance of this cutaneous exhalation is well known both in health and in disease, and is influenced by the general state of the body, of the mucous surfaces, and of the vascular and nervous systems, and is also in some measure vicarious with the renal secretion. The skin is also the seat of a sebaccous or oily secretion, which preserves it in a soft and pliant state, repels external moisture, and defends it from the drying influence of the air. The cutaneous exhalation and secretion

also exert a useful influence in regulating animal heat; the constant evaporation upon the surface, which is proportioned to the surrounding temperature, must affect that of the skin and of its fluids in a corresponding ratio; and as the perspiration is increased in warm weather, or in hot climates, and under increased activity of the healthy circulating organs, the cooling effect of its evaporation becomes the more powerful and useful. The skin is also an inhalent and absorbent surface; its numerous lymphatics, arranged in a plexiform manner, would alone indicate this fact, which, however, has been proved by several experiments. Thus, immersion of the body has been found to increase the general weight, to relieve thirst, and even to supply nutrition, and certain coloured infusions, applied to the surface, have been subsequently detected in the urine.

To fulfil these several intentions, the integument must possess a complex structure and a high degree of organization; accordingly we find that, in addition to its three essential elements, namely, the protecting epidermoid lamina, the true chorion, and the areolated fibrous tissue, it also contains numerous glands and follicles, the sources of the perspiration and sebaceous secretion; it is also the seat of a most extensive and minute capillary net-work of arteries, veins, lymphatics, and nerves. The latter are principally derived from the cerebro-spinal system; and so universally distributed are the vessels and nerves, that the smallest spot upon the surface cannot be punctured with the finest-pointed instrument without more or less discharge of blood ensuing, and pain being felt, instant and acute. The skin is also furnished with certain appendages, the hairs and nails; the former serve as a partial covering and protection; the latter as means of defence and offence, and a support in those particular situations where the tactile papillæ reside. We shall now proceed to examine these several tissues.

The *external surface* of the skin presents varying shades of colour in different situations, which partly depend on the different density and vascularity of each, and partly on a peculiar colouring matter found beneath, or rather entangled in the deeper layers of the epidermis. On the greater or lesser development and peculiar tint of this pigment depend the various shades of colour in the different races of mankind. This surface of the skin also presents numerous folds or wrinkles, lines, and furrows; thus, over many of the joints, and principally on the aspect of extension, there are permanent folds to admit of free motion and flexion without any stretching of the skin, as on the knuckles, elbows, and knees. Almost the entire surface presents small folds, of an irregular form, enclosing areolar spaces; these are to admit of the easy extension and motion of the skin in every direction; in particular situations also there are certain folds depending on the contraction of muscles, and are permanent in some cases, transient in others. Between all these cutaneous folds, or elevations, there are numerous depressed lines running in the most irregular order; on the plantar and palmar regions, particularly on the pulpy extremities of the fingers and toes, there are numerous fine ridges and intervening

depressions, arranged in concentric arches, convex towards the tips; these correspond to the sentient papillæ on the cutis. This surface also presents numerous minute pores; some are the orifices of the various ducts and follicles, others are for the passage of hairs. The integument is more dense, but less vascular and sensible on the posterior part of the body and of the limbs than on the anterior aspect; it is thin and very highly organized on the face and neck. In the plantar and palmar regions the cuticle is infinitely thicker than in any other situation, but the cutis is very vascular and sensible.

The *deep surface* of the skin is an areolar structure, which serves to connect it to the subjacent parts, and contains the glands, hair bulbs, and the vessels and nerves in their course to the cutis. The density and structure of this subdermoid tissue differ in different situations, in some being very fine, reticular, soft, and moist, where free motion is required, as in the eye-lids; in others it is loaded with more or less adipose substance, where it is designed to support much pressure, as on the nates and on the hands and feet; in some situations it is very dense and fibrous, where it is connected intimately and almost immoveably to the subjacent structures; in some situations also, as on the face and neck, muscular fibres are inserted into the skin as they are into the mucous chorion generally. In many animals a cutaneous muscular investment, "panniculus carnosus," exists, by which the skin can be corrugated and moved with ease and freedom, so as to shake off any irritating matter. In man, although the skin, except on the face and neck, is deprived of this appendage, it yet possesses some involuntary contractile power, as is seen under certain mental emotions, or on sudden exposure to cold.

To examine the structure of the skin, small portions of it may be removed from different parts of the body, from the back and chest, and from the palm of the hand and sole of the foot. The most careful dissection cannot detach the cuticle from the cutis, although during life the separation is easily effected, either by the application of a blister to the surface for a few hours, which causes an effusion of serum between them, or almost immediately, by moist or dry heat, which produces the same effect; and in the dead body it may be caused either by long maceration in cold water, by putrefaction, or by immersion for a short time in boiling water; but dry heat will not produce the same effect as during life.

The *cuticle* or *epidermis* appears to be a thin, semitransparent, grey lamina, hard, dry, horny, and homogeneous; when minutely examined, however, particularly during its separation from the cutis, its deep surface will be found to be soft and moist, and numerous fine filaments may be seen to pass between it and the cutis; these can also be well seen in a portion of detached cuticle when floated in water; they are most probably the elongated and ruptured extremities of the fine, exhalent, and sebaceous ducts, also the sheaths of the fine hairs that cover almost the entire surface. All these delicate, cuticular processes, whose direction is mostly oblique, serve to connect the cuticle

to the cutis in the most intimate manner. These must be stretched and torn when vesication occurs, and they are thereby closed, so that the fluid is retained. The deep surface of the cuticle is also very uneven, as it is accurately moulded on all the irregularities of the cutis, covering all the ridges or papillæ, and lining all the depressions on its surface. In some animals, where the papillæ project much in a conical or tubercular form, these cuticular sheaths are very obvious. In the plantar and palmar integuments in man, also, these filaments are numerous and distinct, although there are no hairs in those situations. In addition to the lines and furrows already noticed on the external surface of the epidermis, it also presents between these, numerous small pores, which are not visible to the naked eye; in some situations, however, as between the linear papillæ on the fingers and toes, also on the forehead and face, these can be discerned with the assistance of a lens, particularly during increased perspiration. In some animals, especially in fish, excretory ducts are distinct and obvious on the anterior part of the body, and a glairy mucus can be pressed out of them.

The epidermis is composed of small, hard, dry laminæ, in each of which may be observed one or two opaque spots, the original nuclei and nucleoli of the cells, now flattened into scales, of a polygonal and irregular form, overlapping each other at their edges, and adhering to subjacent softer scales; as those on the surface become more dry and thin, they desquamate and pass off as particles of dust, or bran-like scales; this desquamation is often very evident in inflammatory affections of the skin, in which the cuticular scales, or cells, are rapidly formed, and as rapidly shed; it is also well exemplified on the surface of different animals, particularly certain reptiles, and on the wings of some insects; the deeper structure of the cuticle consists of softer scales, or rather flattened cells, and that portion in immediate contact with the cutis is still softer, and is almost a semifluid stratum, containing cells and nuclei. The cuticle is not itself organized, that is, it does not possess vessels or nerves; superficial injuries, so long as they are confined to it, cause no hæmorrhage or pain. It is formed by the vascular surface of the cutis, and the process is supposed to occur in the following manner: from the capillaries of the cutis, fluid lymph, or blastema (βλαστανω, *germino*), constantly exudes; in this are numerous cytoblasts, or cell-germs; these gradually enlarge into cells, which lie closely pressed together, and cover every portion of the papillary surface of the cutis; as soon as the first layer is completed a new layer is formed beneath it in the same manner, and the layer first secreted is separated from the true skin, changes its form and consistence, becomes hard and flat, then by evaporation dry and firm, and after some time desquamates; this is succeeded by fresh ones from below or from within, and thus the processes of waste and supply constantly keep pace with one another; in some situations the cuticle can be separated into different laminæ, in which these successive changes can be observed, and the whole thickness is found to be composed of several strata of nucleated cells in different stages of development, from the

external, dry, desquamating scale, to the internal, or deep, soft blastema, containing the cell-germs. The superficial scales adhere by their edges; the middle laminæ of cells are flattened, and adhere by their surfaces; and the deepest set are soft, connected together, and supported by the semifluid blastema in which they are formed. This varied structure and consistence of the epidermis causes it to form an exactly fitting mould and covering to the uneven papillary surface of the cutis; hence the internal surface of the cuticle presents corresponding irregularities, while the external surface is rendered smooth and even by the condensation of the scales; some papillæ, however, are so prominent, as on the fingers and toes, as to cause slight, permanent, cuticular projections. Among the deeper cells, and in the connecting lymph, granules of coloured matter are contained. On the amount and tint of these, the complexion of the skin depends. In the negro and other dark-coloured races, this colouring matter appears as a layer of pigment; it is not, however, a distinct or organized membrane, but merely colouring matter deposited in the interstices of the cells; as the latter approach the surface, any colouring matter they carry along with them is lost as they become dry and hard, partly by evaporation, and partly, in all probability, by undergoing some chemical change. Although the epidermis forms one uniform investment for the body, it presents different density on different parts; on the scalp, eye-lids, lips, and face generally, it is thin and delicate; but on the palm of the hand and sole of the foot, and in other situations subjected to pressure, it becomes extremely thick and hard; this increase in density appears in many cases to be the result of long-continued pressure and friction, as in the hands and feet of the labouring poor, and may probably be caused by increased action of the vessels of the cutis excited by pressure and exercise; in the plantar and palmar regions, however, even in the fœtus, the cuticle is more dense than in other situations.

It has been already observed that a scaly epithelium exists in other situations as well as on the surface; thus it lines all the blood-vessels and the serous membranes, from which it can be easily detached, and, when examined by the microscope, the nucleated scales appear of a polygonal form; the same scaly structure also exists on the surface of the tongue, mouth, and throat, vagina, and anterior portion of the urethra; but on the more internal mucous surfaces, the epithelial scales assume the columnar form, that is, the cells are elongated like short columns, perpendicular to the surface.

The cuticle, being itself insensible and extravascular, forms a most useful protecting investment for the body, and defends a highly sensitive surface from pressure and friction, and from the stimulating effects even of the atmosphere; while by accurately and closely fitting on all the sentient papillæ, it transmits every external impression with rapidity; the cuticle also, together with the sebaceous secretion, which forms a sort of varnish upon it, is well adapted for repelling external moisture, which accordingly takes no effect upon it, unless very long applied, as in the case of a poultice, when it is found to thicken it, and render it opaque, white, and laminated: the cuticle possesses but little

hygrometrical property, and therefore resists the permeation of fluids; hence it can retain for a long time the fluid of a blister, and is of invaluable service in keeping the cutis soft and pliant, and preventing the evaporation of its fluids; and if it be removed, even in the dead body, the surface of the cutis very soon becomes dry and stiff, and in the living body, the motion of the denuded part is impaired and highly painful.

Dermis, or *chorion*, or *cutis vera*, is composed essentially of areolar tissue condensed into a firm, compact membrane, in which is interwoven more or less of the yellow, elastic, fibrous tissue, with numerous nerves and vessels. Its deep surface is loose, open, and cellular, connected and continuous with the areolar tissue of the subjacent parts, without any exact limit or distinction, only more loose and free in the latter, more close and compact in the former; the subdermoid cellular tissue contains the cutaneous glands and hair bulbs, and the vascular and nervous ramifications which are to supply the dermis, also more or less of adipose tissue, which not only forms a soft, yielding, and elastic support to the skin, but also adds to the general symmetry of the figure, by filling up the muscular interstices, and smoothing or levelling the general outline of the surface. The subcutaneous adeps differs in quantity, colour, and consistence, not only in different individuals, but also according to sex and age; generally it is softer and more abundant in the female; in the child, it is usually at its maximum; in the fœtus, it is peculiarly firm and white; in the adult, it is softer and yellower; and in the aged, it is pale, scanty, and often nearly absent. In the dermis, the areolar tissue becomes condensed and interwoven into a smooth, membraneous surface, which is exquisitely vascular and sensible, and presents beneath the epidermis numerous minute, elevated lines, which are called papillæ; this surface is often spoken of as a distinct lamina of the cutis, under the name of the *papillary membrane*, or surface; it is not, however, to be understood as a separate structure. Immediately beneath this papillary surface is found some yellow, elastic tissue intermingled with the condensed, white, fibrous structure; the fibres of the former are rather horizontal or parallel to the surface, branching and crossing each other, and interwoven with the white, fibrous basis; these two elements can be partially separated and distinguished by long maceration, or by immersion in acetic acid; in either case, the white, fibrous constituent is softened, while the yellow, being little affected, can be partially isolated from the other; by thus treating portions of the integuments removed from different regions, we may contrast the structure, and we shall find that in some places the elastic, and in others, the white tissue, predominates: thus if we compare a portion of the skin and areolar tissue of the axilla, or of the lower part of the abdomen, with that of the plantar or palmar region, we shall find the yellow, elastic tissue to abound in the former, where free motion and elasticity are required, whereas in the latter, the white, fibrous tissue is in the greatest quantity, its tough, ligamentous fibres, with intervening adipose granules, passing deep to join the subjacent aponeuroses, and thereby imparting den-

sity and resistance in situations exposed to pressure or violence. The subdermoid areolar tissue also varies in its character in different situations; on the posterior aspect of the trunk, and on the outer side of the limbs, it is more dense, and less vascular and sensitive, than in front; it is soft, fine, delicate, and free from adeps in those situations where rapid motion is required, as in the eyelids.

In the subdermoid tissue, in some situations, reddish fibres are very evident, irregular and wavy in their course; they are seen in the scrotum, labia, penis, and nipples; they are contractile during life, and in structure resemble the involuntary muscular fibre: on the existence of these fibres the contractile property of the skin, so evident in these particular parts, depends; and it is not improbable that the same structure exists more generally, but in a less degree, which may account for the general contractile power occasionally exhibited in the skin, either under certain mental emotions, or from sudden exposure to cold. The cutis abounds in the animal principle named gelatine; this is chiefly derived from the white fibrous tissue.

The *superficial*, or *papillary lamina* of the cutis, is the seat of a vascular capillary plexus, and in the living body appears uniformly red, when the cuticle has been detached; in the dead body it can be so minutely injected that it assumes the colour of the fluid. With a lens, the net-work arrangement of the vessels can be discerned; and if a portion thus injected be extended, dried, and then suspended in spirits of turpentine, the vascularity may be well displayed. This surface is studded over with minute elevations or papillæ, which are larger, more numerous, and more distinct in some situations than in others; on the posterior aspect of the back and limbs, though the cutis is dense, the papillæ are small and indistinct; and accordingly, although general sensation exists there, yet there is but little of the discriminating power of touch, whereas on the palmar and plantar surface of the fingers and toes, and of the hand and foot generally, the true sentient or tactile papillæ are highly developed. On the fingers the skin presents, as before mentioned, numerous curved or arched grooves and ridges; each ridge consists of a row of conical papillæ, and into the intervening grooves the epidermis sinks, and in these the small exhalent pores open. In the separation of the cuticle after maceration, the numerous points of connexion between it and the cutis can be perceived, and the fine excretory ducts are seen to admit of some distention before they break or give way. The exact structure of the papillæ themselves cannot be fully ascertained; each appears to be an eminence or projection of the superficial lamina of the cutis, with some portion of the fibro-cellular tissue containing blood-vessels, and most probably nerves. The vessels appear as convoluted loops, and constitute the greater portion of the papillæ; nerves can be traced through the cutis to each papilla, and although the functions of the latter may lead to the inference that they enter its structure, yet they become so soft and fine that it cannot be determined how far they extend, or whether they terminate in loops, or plexuses, or in soft bulbs.

There can be no doubt that in these papillæ exquisite sensibility resides, and that they are the true organs of the *sense of touch* or *tact;* and the same organs, being diffused generally over most parts of the surface, but in a less highly developed state, possess this sense in an inferior degree, while all parts of the skin are sensible to mere contact, and to heat and cold. The voluntary muscles also possess this latter property, and the mucous surfaces, as far as we are acquainted with them; indeed some portions of the latter in an eminent degree, as the membrane of the eye-lids, nose, mouth, fauces, and larynx, all of which are supplied with nerves from the ganglionic branches of the fifth and eighth cerebral. The lining membrane of the rectum, urethra, and vagina, are all sensible to touch, as well as to heat and cold, which nervous endowment they most probably derive from filaments of the ganglionic or posterior roots of the spinal nerves; and in like manner the voluntary muscles and the skin generally are supplied from the same source. The mucous lining of the trachea and lungs, and of the stomach, is sensible to heat and cold; and the former is highly excited by contact with any foreign body, even with noxious air; all this surface receives its nervous supply from the eighth pair of cerebral nerves. How far the abdominal mucous membrane, beyond the stomach, enjoys sensibility to contact, or even to temperature, is uncertain; most probably it presents it only in a very faint degree, but sufficient to excite reflex motion. This observation would lead to the question, are the branches of the sympathetic nerve sentient, that is, cerebro-sentient, or sensiferous? The functions of the alimentary canal, which receives its nerves from this source, and its not possessing the sense of touch, at least not conveying sensation to the sensorium, would induce us to give the negative answer.

The excreting apparatus of the skin consists of glands and follicles, some of which supply the perspiration or sweat, others the sebaceous secretion. The *sudoriferous* or *sweat glands* exist in all parts of the skin, and are simple follicular bodies, soft and round, imbedded in the dermis, or subdermoid tissue. In the axilla they are large and very distinct, surrounded by capillaries, and their reddish colour distinguish them from the adjacent fatty grains; they are composed of a convoluted tube, which ends cæcally by one extremity in the gland, the other becomes the fine exhalent duct which passes in an oblique or spiral course through the cutis and cuticle, and opens by a minute pore; it is lined by a fine epithelium involuted from or continuous with the cuticle. This system of glands must present an extensive secreting surface, capable of eliminating from the blood a prodigious quantity of fluid and effete animal matter.

The *sebaceous glands*, though not so numerous as the last, are very generally diffused through all parts of the skin, except the palms of the hands and soles of the feet. They are very distinct in the auditory meatus (glandes ceruminosæ), on the inner aspect of the eye-lids (glandes Meibomianæ), also on the scalp, face, and tip of the nose, around the nipples, and about the anus, scrotum, and corona glandis (glandes

odoriferæ); they are small, round bodies imbedded in the dermis; some are simple, soft, convoluted tubes, others are firm and lobulated; their ducts perforate the skin in a straight line; some are spiral and oblique, and are lined by the involuted cuticle; in the scalp and other parts where the hair exists, one or more of them open into the hair follicles; these ducts frequently form the habitation of a small parasite which has been minutely described by Wilson and Simon (*Phil. Trans.* 1844; and *Muller's Archives*, 1842). This sebaceous secretion serves to keep the surface moist, soft, and pliant, and in particular situations answers special purposes, as in the meatus auditorius, eye-lids, nipples, &c., it also cooperates with the sudoriferous glands in separating hydrocarbonaceous matters from the blood.

The hairs and nails are appendages of the skin, but are rather modifications of the cuticle than allied to the cutis; the nails in particular are so directly continuous with the former, that after maceration they separate along with it from the true skin.

The *nails* cover the dorsal surface of the last phalanges of the fingers and toes, and have a tendency to extend around the extremity of each; they are strong, elastic, insensible plaits, curved or concave so as to fit closely to the cutis; the *root* and *borders* are concealed and fixed in a narrow, deep fold in the cutis, named *nail follicle;* the exposed portion or *body* is convex, and ends in the *free margin*, which is variously modified in different animals. The surface of the cutis to which the body of the nail adheres is termed the *matrix*, and is so vascular that the red colour is seen through the nail; at the root and a short distance beyond it, it is less vascular and more dense, and causes the semilunar white spot called the *lunula*. In the follicle, at the root and borders, are a number of papillæ which secrete the nail, and on which the latter is accurately moulded, and thereby fixed in its situation; the whole surface of the matrix is also raised into fine, long, papillary plaits or laminæ, which are received into grooves in the nail, whereby the latter is still more firmly attached; from these the nail receives additional matter, and is rendered thick and strong, while the roots and margins are thin, soft, and uneven. In tearing off the nail these subjacent papillary plaits can be seen, as also the ribbed appearance on the concave surface of the former, each ridge fitting into the sulcus between two laminæ of papillæ. The cuticle is continuous with the nail a little beyond its root and lateral borders, and is also continued from the back of the pulpy end of the finger to its concave surface near the end or free edge; and as the nail is thus continuous with the cuticle, so is the matrix with the adjoining cutis. The nail is produced in a manner analogous to the cuticle; the papillæ secrete the blastema and cell-germs, these become flattened and compressed, dry, and harden into nail; as this elongates it thickens from fresh matter being added to its concave surface; thus it grows in length from addition to its root, in breadth from addition to its borders, and in thickness from addition to its concave surface. The nails not only protect the sensitive ends of the fingers, but aid them as instruments of pre-

hension, as well as in various manual operations; they also afford a firm point of support behind the tactile papillæ, which is of essential service in the exercise of touch.

Hairs.—These cutaneous appendages, like the epidermis and the nails, are insensible and non-vascular; they exist on all parts of the body except the palms of the hands and the soles of the feet; they vary much in strength, form, colour, and extent, in different situations. On the greater portion of the body they are fine, short, soft, and downy; they grow to the greatest length on the head, but are strongest in the beard and eye-lashes; they also differ according to age, sex, and race. The structure of a hair is best seen in a whisker of one of the feline tribe. The loose or projecting part of a hair is called the *shaft;* the *root* is fixed in a follicle composed of an involution of the cuticle, and of the superficial lamina of the cutis; this follicle is depressed through the cutis, enlarges into a pyramidal or bulbous form, and is imbedded in the areolar and adipose tissue, from which it receives its vessels, and by which it is so firmly implanted, that it cannot be disturbed by the forcible evulsion of the hair. The whole follicle is lined by the involuted skin; at the bottom of it the cutis presents a vascular papilla or pulp, the size and organization of which are proportioned to the size and strength of the hair; these papillæ are highly sensitive beneath the vibrissæ or whiskers of the feline animals, also beneath the eyelashes and the hairs at the entrance of the nares in man. From this papilla the hair is produced; its vessels give out the lymph or blastema containing the cell-germs; these become cells with nuclei, and are gradually condensed and elongated into a scaly, fibrous substance, which is pushed forwards by successive additions from beneath, and escapes through the opening in the epidermis, generally in an oblique or slanting manner, which gives the hair its peculiar direction in the rest of its course, and finally it ends either pointed or split. Those cells which form the outer surface or *cortex* of the hair are flat and hard, and enclose a more loose fibrous texture, named the *medulla* or pith; these external scales are imbricated, those last formed overlapping the preceding; hence the wavy, transverse lines observed on some hairs, as also the peculiar roughness experienced when drawing a hair between the fingers from the point towards the root. The central cells are less condensed, hence the structure is more loose and open, and a magnified view of a transverse section presents a cellulo-tubular appearance, like that of a piece of cane; hence a hair may often be split into fibrillæ, a change it often undergoes spontaneously at its end. Thus, as the hair follicle is lined by an involution of cuticle, so the hair itself is an evolution of the same substance, only differently modified by the papilla at the bottom of the follicle. Pigment granules are also intermingled with and adherent to the cells at the root of each hair; on these the colour of the hair depends. Into the hair follicle one or more sebaceous ducts open, the secretion from which lubricates the hair through the rest of its course. The colouring matter may be unequally developed at different times, and thus a hair may present spots

or shades of different colour, or the secretion may altogether cease, and then the hair is grey or whitish.

As more or less cellular tissue and adipose membrane exist beneath the skin, connected to and continuous with it, and contributing to this general investment of the body, some have considered and described these as constituent parts of the integument. Although this view is not critically correct, inasmuch as they are diffused through almost every other portion of the system, yet a few remarks on these tissues may be not inappropriate in this place.

Cellular tissue is the most general and universal constituent of animal bodies; it exists all over the surface (*subcutaneous*); it connects all parts together, and fills up their interstices (*intermedius*); it encloses almost every organ, permeates its structure, and connects its component particles (*stipatus* or *parenchyma!*); in some situations it is very strong and fibrous (*fibro-cellular*); in others, it is fine, soft, loose, and delicate (*reticular*); and in others it is intermingled with adipose tissue (*cellulo-adipose*). The term *cellular membrane* has been objected to by many writers, and properly so, as it implies that it consists of distinct membraneous cells or chambers, whereas it is only a cellular web composed of fibres or threads interweaving and crossing each other, like the fibres of cotton or wool, in every direction, so as to bound very irregular spaces or areolæ of the most varied form and size, and all communicating freely. Hence the term *areolar tissue* has been adopted by some; others have named it *filamentous tissue* from its structure; and Henle has suggested the expressive title of *conjunctival tissue* from its functional office, as being the bond of union, the connecting medium between all parts of the body. As the cellular and adipose tissues are very generally associated, and in close connexion, they were formerly regarded as the same structure, some cells containing fat, others containing fluid or vapour; they are, however, totally distinct elements, and, in some situations, are located separately. The difference between these tissues have been clearly set forth by Dr. William Hunter (*Med. Observ. and Inq.* vol. ii.); the cellular or filamentous tissue being composed of fine threads or bands of white, fibrous tissue, crossing each other, and leaving interstices which communicate freely; whereas the adipose consists of numerous shut sacs, having no opening or communication, each sac being a delicate, simple membrane supplied with blood-vessels, and secreting into its cavity the inorganic substance named fat.

The *areolar*, or *filamentous*, or *cellular tissue*, when minutely examined, is found to consist of filaments of variable size, some as fine as hairs, others are aggregated into firmer and broader bands and fine laminæ; they pursue, some an undulating or wavy course, others branch out into fibres, and all cross each other in the most irregular manner, so as to form a true cellular web, soft, yielding, and elastic; the latter property developed in some parts more than in others, partly depending on the blood-vessels and partly on the yellow fibrous or elastic tissue, which is disseminated very generally through the fila-

mentous, and very abundantly in some situations where that property is required. It is very loose where free motion exists, as in the eye-lids; but, where compression or support is necessary, it is compact and dense, and assumes a membraneous form, as in the superficial fasciæ and the capsules of different organs. The areolæ contain serum, or rather serous vapour, which preserves the tissue in a soft and pliant state, and the whole is traversed by numerous vessels and nerves in their course to the skin and other adjacent parts; the tissue itself, however, possesses a low grade of organization, and the fibres are neither vascular nor sensible. The bulk or quantity of the cellular texture varies not only in different individuals, but in the same individual at different periods of life, and according to the state of health: these changes depend very much on the state of the vessels passing through it, and on the amount of serous exhalation it contains. This tissue is continuous through the whole body; from the head and face it leads into the neck; from the latter, through the axillæ, into the upper extremities; also into the thoracic mediastina, and thence along the lumbar vertebræ and abdominal parietes to the pelvis and lower extremities. The areolæ also freely communicate, as is seen in anasarca, also in emphysema, in consequence of a scratch of the pleura pulmonalis from a fractured rib. This free communication can also be demonstrated in the dead body, by injecting air into it; and a portion thus treated and dried will exhibit the filamentous web and the irregular interstices, like a fine, spongy, or cottonny texture. This tissue is found in almost every part of the body, but in different proportions: beneath the skin, throughout its entire extent; and whenever free motion is required, it is loose and abundant; between all the muscles, confining them in their situation, but still admitting of their actions and change of form and place; around each it is condensed into a sheath, and is prolonged into it along with its nutrient vessels and nerves, and forms smaller sheaths for each fasciculus and fibre, but it does not penetrate the sarcous element of the latter; around the nerve it is disposed in an analogous manner, forms a sheath for each cord, and for each fibre, but does not extend into the latter; it also encloses the blood-vessels in sheaths which confine them in their proper position, and defend them from the pressure of the adjacent parts; it also invests the serous and the mucous membranes, and the different glands, and accompanies the vessels of the latter through their intimate structure; in some glands, as the mammary and salivary, it is more abundant than in others, as the liver, kidneys, and testes. In some few situations it is in very small quantity, as in the heart, and in the brain and spinal cord; in the latter but little more can be found than the fine sheaths for the capillary vessels; and its very existence may be doubted in cartilages, in the vitreous table and compact laminæ of the bones, and in the dental ivory and enamel.

Adipose tissue consists of two distinct elements: one is the secreting membrane, the other is the secreted product. The former consists of fine, transparent, membraneous cells or sacs surrounded by capillaries; each sac is somewhat round, but, from several being aggregated toge-

ther, they become compressed, and partially flattened, so as to assume various figures. The vessels pass in the interstices between the cells, and surround each by a delicate inosculation. In some situations the cells are very large, and then the tissue is loose and soft, as in the orbits or cheeks, around the kidneys, &c.; in other places they are small and firm, and present a granulated appearance, as in the scalp, and on the palmar and plantar surfaces of the hands and feet; each cell is filled with adeps, a soft, yellowish, oily, or unctuous unorganized substance, presenting great variety as to quantity, colour, and consistence in different individuals, at different ages, and in the different classes of the animal kingdom. In the fœtus it is white, and forms a thick and firm covering all over the surface, beneath the skin; and but little is found deeper seated, or in the cavities. In youth it is but moderately diffused in all situations; in middle age it is generally increased in quantity in all parts of the body; in old age it nearly disappears from the surface, but is often accumulated in the cavities, as about the heart and large vessels, around the kidneys, in the omenta and mesentery, and about the rectum and colon. Although the adipose and cellular tissues are generally associated together, yet they are distinct in some parts: in the medullary canals of the long bones there is but little of the cellular, the space being occupied by a peculiar kind of adipose tissue, the cells very fine and reddish, and the adipose matter very soft, and sometimes semifluid; in the omenta, and along the mesenteric vessels, and upon the heart, the adipose tissue is often abundant, though very little cellular tissue exists in those situations. The fat contributes to the covering of the body, and, being a bad conductor of heat, may assist in retaining its temperature; by filling up numerous interstices it adds to the general symmetry; it affords a soft and yielding support to different organs, and defends vessels, nerves, and other parts from pressure; it may also serve as a reservoir of nutritive materials, from which the system may derive an occasional supply.

SECTION II.

ANATOMY OF THE NOSE, OR ORGAN OF SMELL.

THE *nose* is situated between the orbits, above the mouth and glottis, and in front of the pharynx and of each tympanum, and communicates with all these regions; though it occupies a median place, it is a double organ, being perfectly divided by a septum into two symmetrical portions, called the *nares* or *nasal fossæ*. These passages have two distinct offices to perform: first, they constitute the organ of smell, the olfactory nerve being distributed to the vascular membrane covering their irregular and convoluted surface, the anterior opening of each having an horizontal aspect, in conformity to man's erect posture, and adapted to direct the odoriferous air upwards towards the

sentient surface; and, second, they serve as avenues to the respiratory organs, and are, therefore, constructed of such unyielding materials as may secure a free and permanent passage for the atmosphere: their surface also is rendered highly sensible by the filaments of the fifth pair of nerves, and this sensibility enables it to take cognizance of the quality of the air, and gives warning to the nervous centre of what may be injurious to the system, and by reflex power excites the action of the expiratory muscles to effect a violent expulsion of the noxious or offending matter. This action is often spasmodic and repeated, as in sneezing. From the proximity of the nose to the mouth, the sense of smelling becomes subservient and auxiliary to that of taste in the selection or rejection of food. For the study of the anatomy of this organ, the student should be provided with a vertical section of the dry skull, and of one in the recent state, the section made close to one side of the septum narium. This organ may be divided into two parts: the one is anterior or external (commonly called the nose), and is composed of cartilages and soft parts; the other is posterior or internal (the nares or nasal fossæ), and is composed of several bones covered by a very vascular mucous membrane. First examine the external apparatus, or the nose.

The *nose* is essentially formed of cartilages; one occupies the median line or septum, the others are placed on each side, and form the alæ; they are continuous laterally with the superior maxillary, and superiorly with the margin of the nasal bones, which form the prominence called the *bridge of the nose*, which is so very variable in different individuals; inferiorly they bound two oval openings (the *nostrils*); these are directed downwards, separated from the mouth by the upper lip, and from each other by the septum, beyond which the integument forms the projection called the *tip of the nose*. Each nostril has its long axis from before backwards, and is partly surrounded by stiff hairs (*vibrissæ*), which bend across it, and prevent the entrance of foreign particles, and, like the whiskers of feline animals, convey the slightest impression to the sensitive nerves in their bulbs, whereby the expiratory muscles are excited to immediate action. The skin covering the extremity or tip and alæ of the nose is thick, is inflected into each nostril, and becomes mucous membrane at the roots of the vibrissæ; it is furnished with numerous sebaceous follicles, the small ducts of which open on the surface, and frequently appear as black dots, owing to the adhesion of external matter. The sebaceous secretion can often be forced out in fine, long threads, like small worms. These follicles are occasionally hypertrophied, so as to cause a considerable enlargement, and an irregular, tuberculated state of the extremity of the organ. Beneath the integuments are the several subcutaneous muscles, pyramidalis nasi, compressor, &c.; these have been already examined (page 8). These muscles can alter the form of the nostrils, but cannot wholly close them.

The cartilages, or fibro-cartilages, are five in number, one in the centre, one at each side, and one inferiorly in each ala. The *septal*

or *median cartilage* is of considerable strength, and is true cartilage, flexible and elastic; it not only separates the nostrils, but also the anterior portions of the nasal fossæ; it is somewhat triangular; the anterior margin is connected above to the inside of the suture between the nasal bones, and below to the two lateral cartilages beneath the integuments. The posterior border leads downwards and backwards, and is attached to and often continuous with the nasal or perpendicular plate of the ethmoid; its inferior border, which leads from behind downwards and forwards, is received between the laminæ of the vomer and the rising spines of the palatine plates of the superior maxillary bones. This and the lower portion of the anterior edge are rounded off anteriorly, and present a thick, convex border, which is received between the two alar cartilages, and forms the septum between the openings of the nostrils. The apex enters the angle between the vomer and ethmoid lamella, and is prolonged backwards in the former bone for some distance, sometimes even to the azygos process of the sphenoid. The nerves of Cotunnius are parallel to it, and often enclosed in the same bony canal. This cartilage is very thick anteriorly, and presents several small mucous pores; it is enclosed in thick mucous membrane, is not always vertical, but frequently projects to one side, and is concave to the opposite. A similar deviation is often remarked in the bony septum, where the vomer meets the ethmoid plate, and a considerable osseous projection to one side is not uncommon.

The *lateral nasal cartilages* are two on each side, superior and inferior; the latter are also called alar cartilages. The *superior lateral* is attached externally and posteriorly to the nasal process of the superior maxillary bone and to the inferior margin of the nasal bone; anteriorly and internally it is connected to the opposite one and to the septal cartilage, of which latter they are by some described as a part, or as a lateral process; however, they are always distinct from it, and move upon it. The inferior border is connected by fibrous tissue to the following. The *inferior lateral* or *alar cartilages* form the upper part of each ala, the tip or lobe, and the boundary of the nasal openings; each is of a very irregular form; it is curved around the orifice of the nostril in a peculiar manner, is somewhat semicircular, the cornua converging behind towards the bone, and not meeting; the largest part is in front, and is deeply excavated, thereby enlarging the cavity of the nose, and extending it into the tip or lobe; the external crus is thin and long, curved in the form of the ala, the upper part of which only it forms, the lower portion being composed of the thick folded integument; the inner limb is thicker and larger than the external, and on a plane inferior to it, is in contact with that of the opposite side, beneath the septum, which is received between them, and beneath which each alar cartilage can glide to either side. The internal crura of the opposite cartilages pass horizontally backwards, and are connected by fibro-cellular tissue to the nasal spine of the superior maxillary bones, and form the projecting ridge between the

two nostrils; this ridge is named by some the *columna;* it is nearly horizontal, but variable. The upper margin of the alar cartilage is connected by fibrous tissue to the border of the superior lateral cartilage: all these lateral cartilages are very moveable, as they are attached by fibrous tissue to the bone and to each other; they are easily acted on by the superimposed muscles, which can move the whole organ, or alter the form of the openings, enlarge and contract, but cannot perfectly close them.

The NASAL FOSSÆ are bounded by several bones, which are all covered by a very delicate periosteum, inseparably united to the highly sensible lining mucous membrane; to the anterior part of the bones of

Fig. 71.*

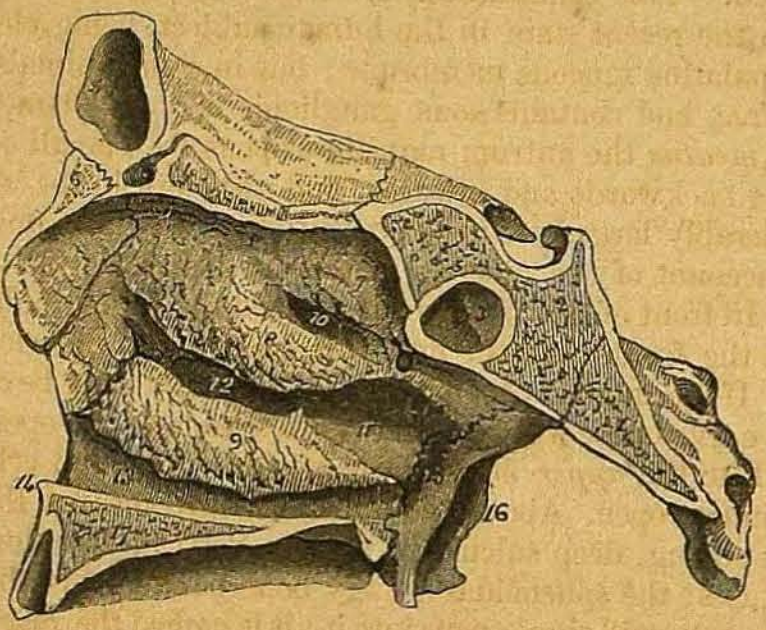

the nose, the cartilages of the septum and alæ nasi, which have been described, are attached. Each naris is bounded superiorly by the lateral nasal cartilage, and by the nasal, frontal, ethmoid, and sphenoid bones; the roof is arched, and has different aspects; the anterior part looks downwards and backwards, the middle perpendicularly downwards, and the posterior part downwards and forwards: the floor is nearly horizontal, but with a slight inclination backwards, and concave in the transverse direction, and is formed by the palatine plates of the maxillary and palate bones, and in part by the velum palati: the external wall is formed by the superior maxillary, unguis, spongy, ethmoid,

* The external wall of the right nasal fossa. 1. A section of the basilar process of the occipital bone. 2. A section of the body of the sphenoid bone. 3. The sphenoidal sinus. 4. A section of the crista galli of the ethmoid bone. 5. The frontal sinus. 6. Os nasi of right side. 7. The superior spongy or turbinated bone. 8. The middle spongy bone. 9. The inferior spongy bone. 10. The superior meatus of the nose; the figures are placed immediately in front of the orifice of the sphenoidal sinus. 11. The middle meatus. 12. The opening of the antrum Highmorianum, or sinus maxillaris. 13. The inferior meatus. 14. The anterior nasal spine. 15. The internal pterygoid process. 16. The external pterygoid process. 17. The palate process of the superior maxillary bone, separating the mouth from the nasal fossæ.

and palate bones, and by the internal pterygoid plate. The septum is composed of the azygos plate of the sphenoid, the nasal lamella of the ethmoid, the vomer, the spines of the palate and maxillary bones, and the septal cartilage. The external wall of each naris is deeply grooved by three fossæ, or meatuses, the superior, middle, and inferior; these are situated between the spongy bones; the middle is the widest. The nasal or lachrymal duct opens into the anterior third of the *inferior meatus*, the Eustachian tube behind, but on a level with the inferior spongy bone. At the side of the septum anteriorly may be observed, in the dry skull, the superior orifice of the anterior palatine canal, which, although a distinct opening superiorly in each naris, yet inferiorly, or towards the mouth, it forms with the one of the opposite side a common foramen. This communication between the nose and mouth does not exist in the recent state in the human subject, being closed by the nasal and palatine mucous membrane; but in some animals it is permanently free, and contains some ganglionic nervous filaments. Into the *middle meatus* the antrum maxillare opens by a small oblique slit, which looks backwards and inwards, and although in the dry bone it appears tolerably large, yet in the recent state it admits only a small probe, on account of the mucous membrane being thrown into a fold around it. In front of this is a groove, named the infundibulum, which leads from the frontal sinus; into this groove the anterior ethmoid cells open. If the anterior part of the middle spongy bone be cut off, this projecting, curved tube will be seen; it often leads to the opening of the antrum. Into the *upper meatus* the posterior ethmoid cells and the sphenoid sinuses open. Above the upper or third meatus there is frequently an oblong, deep sulcus, in a more vertical direction than the other meatuses; the sphenoidal spongy bone bounds this above; when present, the sphenoid sinus opens into it; it is named the *fourth meatus*, or *summus*. This spongy process is sometimes coiled inwards, so as to present even a fifth fossa or meatus. The external wall of each naris is rendered, by means of these several fossæ, very extensive, and thereby not only is the sentient surface of the membrane greatly enlarged, but the many irregularities and offsets must serve to detain for a longer time the odorous air, which latter can only be displaced gradually, and thus the impressions upon the olfactory nerves must be prolonged. Each naris opens posteriorly into the pharynx, above the velum, by an oblong, oval opening; these are separated from each other by the vomer, the internal pterygoid plates bound them externally, the sphenoid above, and the palate bones and velum below.

All the internal surface of the nose, and of the sinuses communicating with it, are lined by a soft, vascular, and highly sensible mucous membrane: this is the *pituitary* or *Schneiderian membrane*. It is continuous anteriorly with the integuments, adheres to all the internal surface of the bones of the nose, lines the sinuses, is continuous through the nasal duct with the membrana conjunctiva of each orbit; round the lower extremity of each duct it forms a slight circular fold, valvular in front; this elongates the canal, and contracts the opening to a small size:

posteriorly it is continuous with the membrane of the pharynx and Eustachian tubes. In some places it adheres inseparably to the periosteum, so as to deserve the name of a fibro-mucous membrane: in others it is villous, very vascular, soft, and thick, as on the septum and turbinated bones; and in these situations both it and the submucous tissue are loose, cellular, or spongy, and probably possess some of the properties of erectile tissue. At the extremities of the latter, particularly of the inferior, it forms thick, fleshy-looking folds or lips; it closes the ethmoidal, spheno-palatine, and incisor or anterior palatine foramina, and smooths off many of the irregularities so remarkable in the dry sections. In the sinuses it is pale and thin; it is constantly moistened with a mucous secretion, but mucous glands are not distinct in it; like other mucous membranes, it possesses an epithelium which is columnar, except in the sinuses, where it assumes the character of the squamous; it is furnished everywhere with cilia, even in the sinuses, in which, in the lower animals, the vibratile motions have been observed to produce currents towards their openings.—(Cruveilhier's Anat. p. 857.) The olfactory, or first pair of nerves, are distributed to it on the septum and ethmoidal region in the form of numerous plexuses; it is also supplied on each side and on the septum with branches from the ophthalmic and superior maxillary divisions of the fifth pair. The *olifactory* may be seen by gently tearing off the membrane from the bones, commencing at the upper part of the septum, or of the spongy laminæ; or, when the bone has been exposed on one side, break it, and with the forceps pick off the fragments from the opposite membrane. The nerves may be then seen descending through the cribriform plate, enclosed at first in short bony tubes, and then in fibrous sheaths; they soon expand in plexuses of fine filaments. On the septum these can be traced for nearly an inch very distinctly; the fibrillæ then enter the mucous tissue, the exact mode of termination in which cannot be ascertained: externally many of the olfactory nerves can be traced to the superior spongy bone, but very few to the middle, and none to the lower. The branches of the fifth pair do not pursue the same plexiform arrangement; some of these enter the mucous tissue abruptly, others extend some distance as distinct, undivided filaments before they terminate. The septal branches of the spheno-palatine, or nerves of Cotunnius, descend in this form obliquely forwards, all along the septum, as far as the foramen incisivum. The first pair endow the superior portion of this membrane with its peculiar sense or power of smelling; while its general acute sensibility depends on the fifth pair, the general feeling nerve of the head. Majendie's experiments prove that the branches of the fifth pair in the nose are very sensible to acid or pungent odours, in the same manner as the surface of the eye, and hence he inferred that these nerves are accessory to the special function of this organ. However, it may now be considered as an established fact that the first pair of nerves are alone olfactory; they are wholly distributed to the mucous membrane, and give off no motor filaments; irritation of their bulb or

branches, in experiments on the living animal, excites no muscular effort, direct or reflex. Valentin's experiments also demonstrate that destruction of these nerves annihilates the sense of smell without impairing sensibility, and that the membrane will continue sensible to irritating vapours, which will excite sneezing and other muscular exertions through the fifth pair. No doubt the acuteness of smell must be diminished by division of the fifth, because the functions of the membrane, and of its sense, become impaired if secretion be suspended; and this is the effect of division of this nerve. The membrane, when dry, is not susceptible of the impressions made by minute odoriferous particles: we may, therefore, affirm that the olfactory are the true nerves of the special sense of smell, and that the fifth pair are accessory in so far only as they tend to maintain the due organization of the membrane and the secretion from its surface.

SECTION III.

ANATOMY OF THE TONGUE, OR ORGAN OF TASTE.

The apparatus for the exercise of this sense, though less complex than that for smell, is in most essential respects analogous to it, as also to that for touch, of which latter many regard it as a modification or refinement. In each case contact between the external substance and the sentient surface is requisite, and motion, friction, or compression, render the sensations more perfect; for the perception of taste, however, the object applied must be either in a gaseous or fluid state, or soluble in the moisture of the sentient surface; if perfectly dry, the sensation of contact only is conveyed to the sensorium.

Taste may be defined to be the faculty of distinguishing, not only the temperature and many of the physical characters of bodies (in which respect it is similar to touch), but also the peculiar properties, chemical and others, which certain substances alone possess, and which are, therefore, called "sapid bodies." This sense is greatly assisted by that of smell; the odorous effluvia from the sapid body being first noticed by the olfactory nerves, and then more fully recognised or discriminated by the gustatory organ. The faculty is most delicate and exalted on the anterior, the lateral, and the posterior parts of the upper surface of the tongue; the central portion possesses it in a less degree; it also resides, but feebly, in the palate, and membrane of the mouth generally, to which surfaces the fifth pair of nerves are distributed.

Placed at the entrance of the alimentary apparatus, the great object of the tongue, and of its special endowment, is the choice of food, to reject what is nauseous and noxious, and select and retain what is grateful and nutritious; and it may be affirmed as a general law (though with some few striking exceptions), "that what is good to

the taste will prove nutritive to the system." The tongue also, in most animals, is an active agent in suction, prehension of food, mastication, insalivation, and deglutition; and in man it is the great instrument for speech. In the animal series it presents great variety in form and structure, which are always in accordance with the functions it is to execute, and with its endowments and privations.

To fulfil its several functions, the tongue must possess a very complex structure; it is, accordingly, highly organized: six cerebral nerves are distributed to it; it is freely supplied with blood-vessels, is covered by a sentient and very sensitive papillary surface, and is essentially composed of muscular and very irritable fibres, which form an intricate interlacement, not unlike the wall of the left ventricle of the heart. This muscular structure can change the form and consistence of the organ with wonderful rapidity; can move it in every direction, so as to bring and retain its sentient papillæ in contact with foreign matter; can strike its point with agility against the lips and teeth, to produce the articulate sounds of speech; can press and bruise the food against the palate, gums, and teeth; can, with great dexterity, collect the particles together, pick them out of every recess, and compress them into one mass, and then force the whole backwards through the fauces.

The tongue is described as of various forms, triangular, oval, irregularly square; from the nature of its structure, however, it cannot present any uniform shape. When detached and extended it is somewhat oval, the large end (base or root) being posterior and inferior; the small end (apex or tip) being superior and anterior; the middle portion (body), placed within the lower alveolar arch, is broadest opposite the last molar teeth, and, being thicker posteriorly than the vertical depth of the arch, it rises above the level of the molar teeth, so that when the mouth is closed, its upper surface, which is a little grooved, is in contact with the palate. A median groove above, a cellulo-adipose line below, and a vertical fibro-cellular septum extending through it, render the apparatus of taste double or symmetrical, like that of the other senses. We shall next proceed to the more accurate examination of this organ, and consider it as presenting a base, an apex, a superior and inferior surface, and two lateral borders or edges.

The *base* of the tongue is posterior and inferior, and very thick; is connected to the body of the os hyoides by muscles, and by a fibrous tissue named the *hyo-glossal ligament*, above which it is connected to the epiglottis by three semilunar folds of mucous membrane (glosso-epiglottidean), the central of which is very prominent, and is named frænum-epiglottidis, or posterior frænum of the tongue; the os hyoides forms, as it were, a foundation for the tongue, and, as the larynx is attached to it, the latter follows many of the motions of the tongue. The *superior surface* is rough, from the numerous papillæ scattered over it, and which will be more particularly noticed presently; a median groove also extends along it, which is deeper behind than before. At the posterior extremity of this groove we generally observe a small

circular depression, opposite the uvula, named foramen cæcum. The *apex of the tongue*, or the anterior third, is thin and pointed or rounded; all this portion is enveloped by mucous membrane, and unattached, and can move with freedom in every direction. The *sides* or borders of the tongue are smooth and convex, thicker behind than before, and are connected by the stylo-glossi muscles to the styloid processes of the temporal bones. The *inferior surface* is irregular, and presents posteriorly in the median line a dense fibrous tissue, which ascends vertically to the mucous surface; this forms a partial *septum*, and is attached inferiorly to the hyo-glossal ligament. In many animals it is a long, bony style, with a fibrous septum extending from it; in some it is cartilaginous, and it has been described by some writers as presenting this tissue in man; it is seldom, however, more than fibro-cellular tissue; it becomes weak and indistinct anteriorly; to a certain extent it renders the tongue a symmetrical organ, similar parts being found on each side of this median septum. In that paralytic affection, termed hemiplegia, this formation becomes evident, as one-half only of the organ is then affected with paralysis. This septum, however, is not perfect, as some of the intrinsic muscles of the tongue pass through it from one side to the other. The anterior portion of the inferior surface is smooth and free, and presents the fold of membrane called anterior frænum linguæ, extending from it to the inside of the symphisis of the jaw, beneath the incisor teeth. On each side of this is a bluish appearance, caused by the ranine veins shining through the membrane, and at its base is the prominent crest, with the two openings of the Whartonian ducts.

The muscular structure of the tongue consists of intrinsic or true lingual muscles, and of extrinsic, or those which have additional attachments. The extrinsic or accessory muscles are the stylo-glossi, hyo-glossi, genio-hyo-glossi, and palato-glossi; as these muscles have been already described (p. 44), we shall only now allude to them in connexion with this organ.

The *stylo-glossus* of each side runs in a superficial fasciculus along the border of the tongue as far as the apex; a deeper band intermingles with the hyo-glossus, and some fibres pass in transversely, and join the intrinsic muscles; these muscles can raise and retract and expand the tongue transversely, or, acting singly, can move it to either side.

The *hyo-glossi* muscles ascend from the os hyoides nearly parallel; approaching the tongue they expand, and are inserted between the stylo-glossus and lingualis of each side; their combined action will depress the margins of the tongue, contract it transversely, and render it convex from side to side.

The *genio-hyo-glossi* are the largest of this class; the convex border of each fan-shaped muscle ascends vertically on each side of the median septum, and is inserted into the dense mucous chorion of the upper surface, from the base to the apex; the two muscles are parallel, and separated below by cellular and adipose tissue, and above by the

median septum, into which also some fibres are inserted; their anterior border is beneath the frænum linguæ: their action must vary according as the whole, or part only, of both, or of one muscle, is engaged; both will raise and draw forward the os hyoides and tongue, and protrude the latter from the mouth; their anterior portions, on the other hand, will retract it, and bend the tip behind the lower incisor teeth, so as to make the dorsum of the tongue convex from before backwards; the central portions will depress the middle of the tongue, and form a groove leading downwards and backwards: if one muscle only act, it will protrude the tongue to the opposite side, as is well seen in cases of hemiplegia.

The *palato-glossi*, or anterior palatine arches, are inserted into the posterior part of the side and upper surface of the tongue, and partly join the stylo-glossi; their action will be to raise the margins of the base of the tongue, and approximate the latter to the velum.

The intrinsic muscles of the tongue consist of fleshy fibres running in different directions, and interlacing very like those of the heart, excepting that there is more adipose tissue intermingled with them. This tissue is peculiar; it is very soft, almost fluid, and has but little or no cellular membrane along with it. If the tongue be boiled for a short time, the true lingual fibres can be more distinctly traced, and their attachments to the mucous chorion seen; the latter is thereby made more firm and resistant. In some animals, when treated thus, it assumes an almost cartilaginous appearance. Gerdy has described the lingual muscles accurately, and names them the superficial, the two deep, and the vertical of each side, and the transverse. The *superficial lingual* covers the edge and upper surface on each side of the middle line, and its fibres are intimately attached to the dense investing membrane. The *deep lingual* are two fasciculi on each side, between the hyo and genio-hyo-glossi muscles, attached posteriorly to the dense submucous tissue. The *transverse lingual* are beneath the superficial, perforate their fibres at right angles, and are attached to the membrane towards either side. The *vertical lingual* descend from the superior membrane to the inferior surface, perforate the other fasciculi, and bend obliquely below towards the base of the tongue. While the whole organ is moved in various directions by the extrinsic muscles, these intrinsic fibres can effect changes in form and density with infinite variety; these changes must affect the sensitive papillæ, bring the food into contact with them, and move it from one to another; they are also instrumental in mastication and in deglutition.

As a sentient organ, the mucous or papillary membrane is most important; this is continuous with the general mucous membrane of the mouth and digestive apparatus; on the antero-inferior lateral portions of the tongue it is loose and simple in its organization; on the lateral borders small pores are distinct, orifices of submucous glands; over the base and posterior part, in front of the epiglottis, it is smooth and rather loosely connected; mucous glands are obvious beneath it, and their small ducts open upon the surface; over the whole dorsum of the

tongue it is rough, from the presence of numerous papillæ of various forms and texture. Malpighi has given an accurate account of the membrane covering the tongue, and but little has been added to our knowledge since; he has established its similarity to the cutis, and that it is composed of, first, a dense chorion; second, numerous papillæ furnished with nerves and vessels; third, a rete mucosum, or pigment layer; and, fourth, an epithelium, or epidermis. In the human subject, however, the reticular layer cannot be distinguished, but in those animals whose tongue is wholly or partially black, a pigment lamina exists. The *chorion* is very dense, and under the knife feels a little crisp; a section exhibits its compact texture, and its deep surface presents a slight yellow tint, probably from some yellow tissue intermingled with it; the muscular fibres are inserted into every part of it: when viewed with a lens they appear to enter its tissue, and some even appear to extend to the bases of the conical or cuticular papillæ. The entire of the upper surface of the tongue, except in front of the epiglottis, is studded with eminences of various forms, some glandular, but most are papillary. The glands and papillæ have been occasionally confounded by writers. The *lingual*, or the *mucous glands*, are most obvious posteriorly, and where the secretion is most required at the moment of deglutition. They form small projections in this region through the membrane, which is thin and rather loosely adherent to them, except in the centre of each, where there is a small pore, which is the excretory orifice; through this the fluid can be expressed by pressure, whereas the papillæ are closely invested by membrane, and present no orifice or pores. Lingual glands also exist along the borders and on the under surface of the tongue, but are not evident on the dorsum. There are probably, however, minute follicles which furnish the secretion that constantly moistens this surface, and which, together with the epithelial scales, form the fur or coat which in fever and gastric disease often accumulates into a thick adhesive lamina. The *papillæ* have been variously designated from their form. They present such different characters that we may infer they have different offices or functions. Near the posterior part of the body of the tongue the most conspicuous papillæ are arranged in a peculiar manner: two rows, each six or eight in number, converge behind so as to enclose a V-shaped space. These remarkable papillæ have been variously designated by authors: calyciform, circumvallate, truncated, pyramidal, button-shaped, &c. &c. The name *calyciform*, applied by Cuvier, is very appropriate, as each is partially enclosed in a small membraneous cup, whose circular margin is loose, and, according to Cruveilhier, papillary also. To the bottom of this cup the papilla adheres by a narrow stalk; from this it swells out like a small mushroom, and ends in a firm, round, prominent base, a little flattened, to range on a level with the surrounding parts. At the angle of junction of these two rows of calyciform papillæ is the deep lacuna, named "foramen cæcum:" mucous follicles open into it, but its margins are probably

papillary. Not unfrequently, instead of a lacuna, a papilla occupies its place.

Anterior to these, the dorsum of the tongue presents a variety of other papillæ, generally arranged under two classes, and named from their shape fungiform, and conical or filiform. The *fungiform* are chiefly towards the tip, and near each side; they have a red colour, and can be best seen in the living organ; if any sapid substance be then applied, they become erect and distended, and appear to move somewhat, probably from the excited action of the subjacent muscular fibres; their base projects a little, and is larger than their apex, which sinks below the surface.

The *conical*, or *filiform papillæ*, are whiter and more cuticular than the others; they occupy the greater portion of the dorsum; they are bent backwards, but, by scraping the tongue, they can be raised and turned forwards; they then give the tongue a rough or brush-like appearance. These papillæ do not appear so organized as the fungiform or calyciform, and are chiefly situated on that part where most pressure against the palate and the food must occur in mastication and deglutition. In many of the lower animals these papillæ are very long, white, dense, and prickly, and bent towards the pharynx, and must serve in the retention, compression, and direction of the food.

All the papillæ, as well as the mucous surface, are covered by a scaly epithelium, which can often be detached, particularly from the conical papillæ, in large patches, by immersing the tongue in boiling water, or by the application of a strong acid. During life this occasionally occurs accidentally, as also in certain fevers; in some animals it is very dense, and admits of easy separation; it forms an accurate covering for the surface of the organ and for all the papillæ, which are thus strengthened in their tissue and defended from the action of foreign bodies, as well as from pressure and friction.

The minute structure of the papillæ is involved in obscurity. They appear to the naked eye smooth, but, when viewed with magnifying powers, they present an irregular surface, villous or papillary; fine injection partially colours and enlarges them; the capillaries form arches and complicated loops upon each; the interior is filled with a soft tissue, covered by a delicate membrane beneath the epithelium. This interior soft tissue probably contains the nervous structure, but the exact form or mode of arrangement of the latter has not been ascertained; the nervous filaments can be traced into the immediate vicinity of each, but become too soft and minute to pursue any further. An accurate description of the lingual papillæ, microscopically examined, has been published in Bowman and Todd's Physiology of Man, page 437.

The nerves of the tongue have been already described: three on each side, the ninth or hypoglossal, the lingual branch of the fifth or the gustatory, and the glosso-pharyngeal division of the eighth. The

ninth is almost wholly distributed to its muscles; from the os hyoides it passes upwards and forwards, between the genio-hyo-glossus on its inner side and the hyo-glossus on its outer; on the outer surface of the latter some branches communicate, and form a plexus with filaments of the gustatory nerve. This plexus, between the motor and sentient nerve, is named the *lingual*, and is distributed to the surrounding muscles and glands. The lingual nerve divides into numerous branches, which are lost in the extrinsic and intrinsic muscles of the organ. Some filaments can be traced upwards, even to the mucous chorion, into which the muscular fibres are inserted, and some accompany filaments of the gustatory as far as the tip or apex. The *gustatory* proceeds in an arch from behind forwards, supplies the sublingual glands and mucous membrane, and its terminating filaments can be followed to the mucous surface on the tip and side of the tongue. The *glosso-pharyngeal*, also, runs in an arched manner, but deeper than the last, and passes between the posterior part of the stylo and hyo-glossi muscles to the base of the tongue; its branches take rather a transverse course, and are distributed superficially on the base and posterior part of the organ, to the calyciform papillæ, and glosso-epiglottidæan folds of mucous membrane. Many facts and experiments have established the opinion that the lingual or ninth nerves are the true motor, and that the fifth and glosso-pharyngeal are both the sentient and sensitive nerves of the organ. The sense of taste especially resides in the papillæ at the point, sides, and base; those in the two former situations appear most quickly sensitive to the qualities of sapid bodies, while the posterior papillæ retain the impressions for a longer time. The conical papillæ on the dorsum do not appear to possess the sense so acutely, probably from being covered by a more dense epithelium; they are, however, highly sensitive to contact, and may thereby serve to regulate the muscular efforts in mastication. This region of the tongue is supplied superficially from the gustatory, and the subjacent muscular fibres from the lingual nerves. The organization of the papillæ, being extremely complex, may account for the difference between the sensitive and sentient properties of different regions, rather than any peculiar endowment of particular nervous filaments proceeding from a common trunk. The glosso-pharyngeal has been already considered as a compound nerve, supplying the base of the tongue with sensation and sense, and the surrounding muscles, through its primary branches in the pharyngeal plexus, with motor power; this nerve also maintains a remote but very obvious sympathy between the tongue and the stomach, and associates in harmonious action all the apparatus for deglutition.

The tongue is very vascular, particularly its surface: it receives its blood from the two lingual arteries, also from the pharyngeal and palatine: the lingual are the principal. These vessels are remarkable for anastomosing, but feebly, on opposite sides, so that if a different coloured fluid be injected into each, the two sides of the organ will be coloured accordingly. A slight communication, however, takes

place on the dorsum of the base and at the apex between the ranine arteries. The veins escape from the tongue, partly at its base and root, and partly by two ranine branches, one at each side of the frænum, which join the veins in the neck.

SECTION IV.

ANATOMY OF THE ORGANS OF VISION.

ALTHOUGH the apparatus for this sense is double and symmetrical, so that each eye can act singly, yet the muscles which move each, have such consent and harmony that both are generally directed simultaneously to the same object, and therefore cooperate, and act as a single organ, whereby vision is rendered more powerful and accurate. The two sentient nerves, also, which are very large, are most intimately connected by their commissural and decussating fasciculi, so that, although the external apparatuses for this sense are more separate and distinctly double than those for smell and taste, yet the connexion between their essential nerves is much more impressed with the character of unity than in those of any of the other senses; a fact which mainly accounts for their sympathy in health as well as in disease. By the sense of sight we acquire a knowledge of the existence, position, relation, form, and colour of external bodies, by means of the rays of light which those objects are continually sending off, being either luminous themselves, or reflecting the light received from other bodies. Each optic nerve is expanded into a concave, delicate, membraneous net-work, named the retina, and is so organized as to receive an impression from these luminous rays, and to convey to the sensorium the sensation of light. Such an impression, however, would be far from distinct vision. To accomplish the latter, those rays of light alone which proceed from the object must impinge upon the retina, and each pencil of rays must also impinge exclusively on some one part of it. To effect these purposes, each pencil of rays from every point of the object must be collected into one point or focus upon the nervous expansion, and this can only be effected by bending the rays from their straight course, that is, by refracting and collecting them into foci upon the retina: hence the eye must act as a powerful optical instrument. It is, therefore, furnished internally with transparent fluids and humours of varying density, and with a powerful double convex lens. By the nice adjustments of these different parts there is produced, upon the concave surface of the expanded optic nerve, a minute but accurate image of the objects before it, in which are represented the outlines, forms, colours, lights, and shades of each in their exact relative position. As the central parts of the retinæ are the most sensible, the images of objects must fall upon them, and therefore the eye requires a capabi-

lity of motion, so as to change its axis towards those objects wherever situate; hence it is furnished with several muscles which, aided by the motions of the head and atlas on the axis, and of the spine generally, can move it with rapidity and exactness; hence, too, it requires a soft and yielding support, and accordingly it rests on a mass of soft adipose tissue, on which it can roll freely in every direction. In addition to its sentient nerve, an organ of such complex and delicate structure must possess the usual elements of organization; it is, therefore, duly supplied with vessels and nerves; special protection is afforded to it by its being lodged in a strong, bony cavity, open only in front, and in which aspect it is defended by the eye-lids, with their cartilages and ciliæ, and powerful sphincter muscles; and, lastly, to keep the surface of the transparent cornea (the window of the eye) clean, clear, and polished, as well as to facilitate the motions of the globe and of the palpebræ, a mucous membrane lines the latter and coats the former, and whose surface is still further moistened by the tears, for the supply and removal of which a distinct apparatus, lachrymal, is superadded. Thus protected and defended, the eyes are at the same time placed in the most favourable position for commanding an extended range of vision, being situated at the forepart of each orbit and at the upper and anterior part of the face. In considering the anatomy of the eye, we must examine not only the globe, or the visual instrument itself, but also these several appendages, or "tutamina oculi," which, though not directly ministering to the sense, are yet so connected with its general well-being, that a derangement of any one of them will more or less impair the functions of the whole organ. The appendages of the eye are the orbits, supercilia, palpebræ, cilia, conjunctiva or mucous membrane, lachrymal apparatus, orbital muscles, nerves, and vessels. In studying the anatomy of the eye and its appendages, the student should be prepared with a section of the dry skull, to examine the orbit and its communication with the nose; he should next, on one side of the subject, carefully dissect the orbicularis, or sphincter palpebrarum muscle; examine the structure of the palpebræ, the puncta lachrymalia, and pass fine wires or flexible pins through each of the latter into the nasal sac, duct, and nose. On the other side, the roof of the orbit must be raised in the manner directed (page 531), the orbital muscles cleaned, and the several vessels and nerves dissected. Lastly, he should procure some fresh eyes of the ox, sheep, and pig, raise the several tunics, and examine the structure of each. It is difficult in a dissecting-room to procure the human eye sufficiently fresh for a satisfactory dissection; but the student should endeavour to do so, as he cannot fully comprehend its structure in man merely by examining it in the quadruped.

Orbits are conical, osseous recesses, their sides of unequal length, and joined to each other at angles, so as to form quadrangular pyramids; seven bones contribute to their formation, viz., the frontal, sphenoid, ethmoid, malar, maxillary, unguis, and palate (*see* Osseous System). In each orbit we have to consider the base, apex, roof,

floor, inner and outer wall, angles, axis, and foramina. The *base* or circumference is very wide and open, directed forwards, outwards, and a little downwards; is somewhat quadrilateral, but wider externally than internally; and the transverse diameter being larger than the vertical, the former is directed obliquely outwards and backwards, as the outer margin of the base is cut off obliquely, whereby lateral or external vision is extended. The vertical diameter of the base is perpendicular in the young, but, as the frontal sinus and superciliary arch become developed, the upper margin overhangs the lower, and then this diameter leads obliquely downwards and backwards, and consequently the eye-ball is directed downwards more freely than upwards. This margin of the orbit is thick and strong, formed superiorly by the superciliary arch of the frontal bone, in the inner third of which is the notch or foramen for the frontal nerve and vessels; externally by the malar, which joins the external angular process of the frontal; inferiorly by the malar and by a short portion of the maxillary, the latter being overlapped by the former, beneath the inner end of which is seen the infraorbital foramen, vertically beneath the supraorbital notch; internally by the ridge of the unguis, in front of which is the nasal or lachrymal fossa and the nasal process of the maxillary bone. The *apex* is in the posterior narrow part of the cavity, and is open; it corresponds to the inner or large extremity of the superior foramen lacerum or sphenoidal fissure, and is below and a little external to the optic foramen. The *superior wall*, or the *roof*, is smooth, thin, and concave, supports the anterior lobe of the cerebrum, is formed chiefly by the frontal bone, but posteriorly the lesser wing of the sphenoid completes it. This surface presents posteriorly and internally the optic foramen or canal; in front of this the transverse suture, between the sphenoid and frontal bones; anteriorly and externally a broad and deep depression, within the external angular process, for the lachrymal gland; and internally, behind the internal angular process, a superficial depression, or sometimes a rough surface, for the attachment of the trochlea of the superior oblique muscle. The *inferior wall*, or *floor*, is shorter than the superior, smooth, and nearly flat, inclined downwards and outwards, formed principally by the orbital plate of the maxillary bone, which covers the antrum maxillare; the malar bone completes it anteriorly, and the anterior small, triangular, orbital process of the palate bone posteriorly; it presents the sutures connecting these bones, and the infraorbital groove or canal leading nearly horizontally forwards and a little inwards; also near the anterior and inner border a slight ridge or roughness for the origin of the inferior oblique muscle. The *external side*, or *wall*, is the shortest; is formed in two-thirds by the sphenoid, and one-third by the malar bones; it leads obliquely forwards and outwards, and presents a suture and a small, irregular foramina, for the passage of nerves and vessels. The *internal side*, or *wall*, is longer than the last, and straight and parallel to that of the other orbit; is formed by the nasal process of the superior maxillary bone, the smooth posterior division of the unguis, the planum

of the ethmoid, and the anterior clinoid process, and part of the side of the body of the sphenoid; it presents the several sutures uniting these bones, also, in that between the ethmoid and frontal, the two internal orbital holes, and anteriorly the deep fossa for the lachrymal sac, formed by the unguis and nasal process of the maxillary, from the lower part of which fossa the nasal canal, or duct, formed by the unguis, maxillary, and inferior spongy bones, leads downwards and backwards into the inferior meatus of the nose.

The *four angles* of the orbit are, first, the *superior* and *internal*, between the frontal, planum, and unguis; second, the *superior* and *external*, between the frontal, malar, and sphenoid, corresponds to the foramen lacerum; third, the *inferior internal*, between the maxillary, planum, and unguis, is rounded off, and scarcely deserves the name of angle; fourth, the *inferior external*, between the malar and sphenoid, and the maxillary and palate bones, corresponds to the spheno-maxillary fissure, or inferior foramen lacerum. The *axis*, or central line, leads obliquely from the apex forwards and outwards, and a little downwards. If, therefore, the axes of both orbits be produced, they will diverge considerably in front, but meet rapidly behind, and decussate at the back of the body of the sphenoid bone. These lines, therefore, are not parallel to the axes of the eye-balls, which lead more directly forwards, and are nearly horizontal, though not precisely so, their direction being a little inwards and forwards, and probably a little downwards, tending to converge towards the visual object. As the eye, however, is in such constant motion, the direction of its axis must as constantly vary. The *foramina* in the orbit are the optic, the lacerum superius, or sphenoidal fissure, the lacerum inferius, or spheno-maxillary fissure, and the anterior and posterior internal orbital. The *optic foramen* is placed in the anterior clinoid process, or between the two roots of the lesser wing of the sphenoid, not exactly in the apex of the orbit, but above and internal to this point: it is a flattened, oval canal, leading from the cavity backwards and inwards, parallel to the line of the axis, but internal and superior to it. If the optic canals of the opposite sides be supposed to be prolonged backwards, they would meet and decussate in the sella turcica. This foramen transmits the optic nerve, which is also flattened at this spot, and beneath it, where the foramen enlarges a little, the ophthalmic artery. *The superior foramen lacerum*, or *sphenoidal fissure*, is a long, narrow slit, triangular, wide internally, narrow externally, placed between the lesser and greater wings of the sphenoid bone, and closed externally in general by the frontal. Its larger inner end corresponds to the axis of the orbit, and transmits the third, fourth, ophthalmic division of the fifth and the sixth cerebral, and filaments of the sympathetic nerves. Beneath these, the ophthalmic vein escapes from the orbit to join the cavernous sinus. The external part of this foramen is closed by membrane, through which a small artery from the middle meningeal sometimes passes, and assists in supplying the lachrymal gland. The *inferior lacerated hole*, or *spheno-maxillary* fissure, is in the inferior external angle of the orbit, bounded by the sphenoid and malar bones

externally, by the maxillary and palate internally, and in front by the malar; posteriorly it is open, and communicates with the last described opening, from which it differs in form, being narrow in the centre, and wide at each extremity. It is occupied by fat, which can thus yield a little in the motions of the eye-ball; it also transmits small nerves and vessels from the orbit to the zygomatic fossa. The *internal orbital foramina*, generally two, but sometimes three, or even four, are in the superior internal angle, in the suture between the planum and frontal bones: the *anterior* transmits the nasal twig of the ophthalmic nerve; the *posterior* the ethmoidal branch of the ophthalmic artery. The foramina in the outer wall are too minute and variable to receive distinct names, though occasionally one or two in the malar bone are of considerable size. The three openings in the circumference, viz., nasal duct, supra and infra-orbital foramina, have been already noticed.

Supercilia, or eye-brows, bound the superior eye-lids; they correspond to the superciliary arches of the frontal bone, which partly cause their prominence; the latter also depends on a thick stratum of subcutaneous, adipose, and cellular tissue, together with the muscular fibres of the orbicularis palpebrarum, and the roots of the hairs. The hairs are mostly directed in a slanting manner outwards, and are placed in two rows; the superior directed downwards and outwards, the inferior upwards and outwards: and both rows converge in a median ridge, which causes a greater fulness, and an even, regular appearance. Internally the hairs are inclined inwards; and not unfrequently those of the opposite sides meet and decussate above the root of the nose. The eye-brows, however, are very variable as to length and prominence, also as to the size and direction of the hairs. These varieties, as well as the alteration in their form and position, induced by muscular action, exert a remarkable and well-known influence on the general expression of the countenance, and are even occasionally indicative of certain emotions of the mind. The eye-brows are of use in shading the eye from very strong light, and protecting it from particles of dust or fluid. They can be moved in three directions: elevated by the occipito-frontilis muscle, depressed by the orbicularis, and also depressed and adducted by the corrugators. (*See* Muscles of the Face, page 7.)

Palpebræ, or *eye-lids*, are the two moveable, semilunar curtains, or cutaneous folds, placed in front of each orbit, convex towards the surface and rounded, with horizontal wrinkles, smooth and concave towards the eye, and so exactly moulded to it, and arranged, as, when approximated, to conceal, and, when separated, to expose its anterior surface. The opening between them is named *palpebral fissure*, or *rima*. When closed, this fissure is a mere line, nearly transverse or horizontal, but a little curved, convex downwards, and higher externally than internally; it is inferior to the transverse axis of the eye, below the pupil, and cannot therefore be called "equator oculi." When the lids are opened, their margins are concave, and circumscribe an opening more or less elliptical, but very variable, and on the size of which the apparent magnitude of the eye very much depends. Its extremities are named *canthi*. The *outer canthus* is an acute, angular

commissure, a little rounded, and about a quarter of an inch distant from the edge of the orbit, to which it is attached by a tense, fibrous membrane. The *inner canthus* extends from the inner extremity of the fissure for a short distance inwards towards the side of the nose, the edges being round or concave, and presents externally a small tubercle on each edge named *lachrymal papilla*, the point of which presents a minute but distinct foramen, *the punctum lachrymale*, which is the commencement of a small canal, *lachrymal duct*, which conveys the tears into the lachrymal sac, and thence into the nose. From between the puncta the palpebral fissure leads inwards, and expands into a small triangular space, *lacus lachrymalis*, in the centre of which is a red papilla, the *lachrymal caruncle*, between the upper and lower lachrymal duct. The upper eye-lid is much deeper and more moveable than the lower, and in sleep or death conceals the greater portion of the cornea. The free, or *ciliary margins* of the palpebræ, are thick, firm, and abrupt, cut off horizontally so as to meet closely by flat surfaces; the innermost edge being very slightly bevelled, as it corresponds to the row of Meibomian orifices, so that a very narrow groove or line exists between them. If the lids be examined when removed from the subject, and their edges placed in apposition on a convex surface, this arrangement may be observed. Many anatomists affirm that the opposed edge of each lid is cut off obliquely backwards towards the eye, so that when closed, a triangular canal is formed, the base being the surface of the eye-ball; and that along this canal the tears are conducted inwards towards the puncta by the orbicular muscle acting in this direction. There is, however, no distinct canal, but at the most a narrow line or groove, which is a little wider internally. Majendie totally denies the existence even of any groove. He conceives that the secretion during sleep passes along the palpebral sinuses, and that the puncta are perfectly capable of imbibing the fluid from these, and that ordinarily, and when awake, the secretion is supplied only in sufficient quantity to moisten the surfaces, and is then removed partly by evaporation and partly by absorption, and little or none passes by the puncta; and that these, therefore, are only designed to carry it off during sleep, or when supplied in unusual quantity. When the lids are separated, the margin of the upper may be observed to be bevelled upwards and backwards, but the edge of the lower is sloped in the contrary direction, that is, from the ocular margin downwards and forwards towards the skin, so that no canal can exist, such as described, when the lids are closed during sleep; during this time, also, the edges of the lids are not in close apposition, but the upper somewhat overlaps the lower.

The palpebræ are composed of skin, areolar tissue, an orbicular muscle, cartilage, or fibro-cartilage, with connecting fibrous membrane, glands, and mucous membrane. The upper lid also has a special levator muscle, and the free border of each is fringed with rows of hairs or cilia.

The *skin* is continuous with that of the forehead and cheek, and is thin, soft, and moveable, in delicate persons almost semitransparent,

the blue veins shining through it, particularly in the upper lid, which is finer than the lower. When the lids are apart it is thrown into semilunar, concentric folds, but, when closed, these are effaced. The *palpebral areolar tissue*, both subcutaneous and submucous, is very fine, loose, and reticular, and perfectly free from adipose structure; it admits of freedom of motion, and is very susceptible to serous infiltration.

The *cilia*, or *eye-lashes*, are stiff, strong, curved hairs, placed in three or four rows on the cutaneous edge of the free margin; they are all curved or bent, the superior upwards, the inferior downwards, so that when the lids are closed the convexities of the cilia only touch, and, therefore, do not catch or entangle in each other. Those in the upper lid are longer, stronger, and more numerous than those in the lower; they first descend, and then bend upwards; the central cilia in each lid are longer than the lateral; they are absent at the inner canthus, that is, internal to the puncta, along the borders of the lacus lachrymalis; their bulbs or follicles are rather deep-seated, close to the tarsal cartilages, and beneath the orbicular muscle. The cilia defend the eye from the admission of particles of dust or other foreign bodies, and can also shade the eye from the impression of too strong light. Along the posterior or ocular edge of the free border of each palpebra is a row of minute foramina, the orifices of the *Meibomian glands*, to be noticed presently. That portion of the free margin of each lid, surrounding the lacus and internal to the punctum, is thin, round, and free from hairs and Meibomian follicles; these are transferred to the enclosed caruncle.

The *orbicular*, or *sphincter muscle*, is the next tissue in the palpebræ; it also extends over the circumference of the orbit; superiorly into the supercilia, and inferiorly upon the cheeks. In these latter situations its fibres are red and circular; on each curtain they are thin, scattered, and elliptical; but near the ciliary edge of each they are collected into a thick fasciculus; the external or orbital fasciculi are red, but the palpebral and ciliary are as pale as the involuntary muscular fibres of the alimentary canal. All the fibres are attached to the internal tendon, named "tendo oculi," or, more properly, *tendo palpebrarum*. This tendon is inserted internally into the nasal process of the maxillary bone, thence it is directed outwards in front of the lachrymal sac, above its centre, and bifurcates. Each band encloses a lachrymal duct, and is inserted into the inner extremity of each tarsal cartilage beneath the punctum. From the upper and lower margins of the tendon a strong fascia extends over the sac, binds it down in the lachrymal fossa, is inserted into the maxillary and unguis bones, and is continuous with the periosteum: inferiorly this fascia can be traced obliquely outwards, as far as the origin of the inferior oblique muscle of the orbit.

The *orbicularis palpebrarum* muscle closes the lids as a sphincter, partially or completely, by depressing the upper one considerably, and very slightly raising the lower, at the same time it draws the latter a little horizontally inwards; it also presses the lids against the globe, protects and supports the latter, compresses the palpebral sinuses, and

directs the lachrymal secretion into the puncta. Its frequent and rapid motion, as in winking, cleans and polishes the surface of the cornea, and by partially closing the curtains, and approximating the eye-lashes, it shades the eye from too bright light, and thus serves as an external iris and pupil: its thick, ciliary fasciculus strengthens the edges of the lids, supports the ciliary bulbs, and expresses the Meibomian secretion.

The *palpebral* or *tarsal cartilages*, with their fibro-membraneous connexion to the base of the orbit, are seen on removing the orbicular muscle and some fine areolar tissue. Each tarsal cartilage, or fibro-cartilage, is a thin, elastic plate, covered by and connected to the orbicular muscle on its superficial or convex surface, and lined by mucous membrane and follicles on its ocular or concave surface. The upper cartilage is between the orbicular and levator palpebræ muscles; it is semilunar, broad in the middle, narrow and pointed towards either end, and much larger and stronger than the lower, which is merely a narrow band, and more fibrous than cartilaginous. The ciliary, or free margin of each is abrupt, nearly horizontal, or slightly bevelled, as before-mentioned, and is very thick, which causes the firmness of these edges of the lids. The orbital, or fixed edge of each, is thin, and attached to the base of the orbit by a fibrous expansion, named *broad ligaments of the tarsus*. These are not true ligaments, but only dense fibrous structure, continuous with the periosteum at the base of the orbit; it is strong and tense in the outer half of each lid, but internally, especially in the upper, it becomes weak and filamentous: at the external canthus it is very strong and cord-like; extending inwards from the edge of the malar bone it divides into two bands, which partly decussate, and are inserted into the extremities of each cartilage. The tendo oculi also answers as a ligament to these cartilages at the inner canthus. Connected to the deep surface of the broad ligament, in the upper lid, is the aponeurosis of the elevator muscle of the latter, and which is expanded between this and the superior palpebral sinus of the conjunctiva, as will be explained presently. The tarsal cartilages, thus retained in their situation, enjoy sufficient freedom of motion to admit of being rapidly moved over the front of the eye; their peculiar structure preserves the form of the palpebræ, and imparts to them sufficient strength and firmness, pliancy and elasticity.

The *Meibomian glands*, or *follicles*, can be seen distinctly when the palpebræ are everted, but may also be exposed from the cutaneous surface; they appear as pale, yellow, long parallel ducts, but slightly tortuous, leading from the free margin of each lid, where they open in a row of minute pores, behind the cilia, visible with a lens, along the ocular surface of the cartilage, imbedded in grooves in the latter, and covered by the mucous membrane, through which they never project in their normal state. They are longer and more numerous in the upper than in the lower lid; each gland, or sebaceous follicle, is an inflection of the mucous membrane in a tortuous and coiled tubular form, ending in a cæcal extremity, and surrounded by minute follicles,

which are cæcal diverticula, opening into it. These secrete an unctuous fluid, which lubricates the edges of the lids and the cilia, prevents their friction and adhesion when closed, opposes the entrance of minute foreign bodies, such as particles of dust, and also prevents the overflow of the tears when the latter are secreted in moderate quantity. In the dead subject the secretion has solidified, and can be squeezed out like fine, white, twisted threads.

The *conjunctiva*, or *internal integument of the palpebræ*, lines these curtains, and connects them to the eye; hence its name. It covers the anterior third of the globe, lines the numerous Meibomian follicles, is prolonged from within the upper eye-lid, near the external canthus, through the eight or ten excretory vessels of the lachrymal gland, into that organ; forms a fold or duplicature at the inner canthus, and is continued through the puncta into the lachrymal ducts, sac, and nasal duct, into the nose, where it becomes continuous with the gastro-pulmonary mucous surface. Though, strictly speaking, it is a mucous membrane, some portions of it are so modified as to bear but little resemblance to that tissue. Its connexions and arrangement deserve particular attention. At the free edge of each palpebra it is continuous with the skin; within the superior lid it ascends, adheres to the cartilage, rises above it into a *cul de sac*, the *superior palpebral sinus*, which is loosely connected to the cellular and adipose tissue within and beneath the rim of the orbit, and is then reflected on the forepart of the sclerotic coat of the eye; to this it is connected by areolar tissue, which is loose externally, and often the seat of serous and sanguineous effusion: it becomes more close and tense near the cornea; over the latter it is continued, but so delicate and so adherent to it that it cannot be separated by dissection for any considerable extent without previous maceration, and is so fine and transparent, and devoid of vessels, that its existence has been doubted by some and denied by others. From the lower part of the sclerotic, to which it is loosely connected, as above, it is reflected on the inner surface of the inferior lid, forming another loose *cul de sac*, the *inferior palpebral sinus*, similar to but smaller than the superior. These folds admit of the free motion of the lids and of the eye-ball. It then lines the lower lid, and is continuous with the skin at its margin; at the outer canthus it also forms a *cul de sac*, behind the external palpebral or tarsal ligament; internally, at the inner canthus, it forms a vertical, semilunar fold, concave outwards, towards the cornea, named *plica semilunaris*. This fold is extremely vascular, and contains a thin plate of dense tissue, like fibro-cartilage. It may be considered as rudimental of the membrana nictitans, as seen in most quadrupeds, or of the third eye-lid in birds. When the eye is rotated inwards it becomes very distinct, but it is effaced when the former rolls outwards.

The *caruncula lachrymalis* is a small, irregular eminence, of a lively red colour, plump and full in health, but pale and flaccid in sickness, placed in the lacus, at the inner canthus of the internal palpebral fissure, internal to the plica lunaris, and between the lachrymal ducts. It consists of dense fibro-areolar tissue around a number of minute fol-

licles, which secrete a sebaceous secretion that often accumulates in this corner, also of the bulbs of several minute hairs; these are all covered by the conjunctiva, which is perforated with minute pores. It has some analogy to the gland of Harder, in the third eye-lid of birds; both, however, coexist in some quadrupeds. The conjunctiva is thicker, more vascular, and adherent in its tarsal than in its sclerotic portion; by means of the palpebral sinuses or reflections, and the plica lunaris, it completely cuts off all communication with the orbit; and when the lids are closed we may consider it as forming almost a short sac, like that of a serous membrane, or bounding a space, named *oculo-palpebral*, which is formed in front by the eye-lids, behind by the eye, and circumscribed all around by the reflections of the membrane, which separate it from the cavity of the orbit. It is constantly moistened with the twofold secretion, partly from its own vessels and follicles, and partly from the lachrymal gland. It is exquisitely sensible in some situations, especially when any foreign substance is interposed between its palpebral and ocular surfaces; it receives its nerves from the ophthalmic, a branch of the ganglionic or sentient division of the fifth cerebral. Its arteries are derived from the ophthalmic, the labial, and transverse facial.

The intimate structure of the conjunctiva has been found, by the aid of the microscope, to be analogous to that of mucous membrane generally; it consists of a fine epithelial lamina and a chorion, with a very vascular or papillary surface. The existence of epithelium was formerly denied, but of late years it has been established by the concurring observations of different anatomists. It consists of minute rhomboidal scales, or flattened cells, closely connected, each with its dark central nucleus. In some animals pigment granules are diffused among the deeper cells in different patches. In some chronic diseases of the lids, with ectropium, the epithelium occasionally becomes developed; and in certain forms of very prominent staphyloma of the cornea the latter also becomes covered with a distinct epithelium or cuticle. The chorion, with its papillary layer, is best developed on the palpebral portion of the conjunctiva; it adheres so closely to the cartilage as to resemble a fibro-mucous tissue; it has all the characters of the other mucous membranes. These commence a little behind the inner sharp edge of each ciliary margin. The papillary lamina is very vascular on the inner side of each lid, and, when viewed through a lens, presents numerous red papillary grains; these probably are mucous follicles. This lamina is less developed on the sclerotic conjunctiva, and cannot be demonstrated on the corneal portion. In certain forms of chronic ophthalmia this papillary surface of the palpebræ is very prone to thickening, and to assume a granular appearance. The perfect transparency of the cornea, the total absence of red vessels, its density, and the difficulty of detaching from it anything like a continuous membraneous structure, has led some to deny the existence of the conjunctiva in front of the eye; modern anatomists, however, have determined this point affirmatively. If the recent cornea

be gently scratched or torn with a needle, portions of soft membrane can be raised, similar to the surrounding tissue in all respects save vascularity, and the compact and dense cornea may be seen smooth and uninjured. Superficial wounds and injuries during life exhibit the same phenomena; and, if the eye be allowed to remain in water for twenty-four or thirty-six hours, a distinct membrane can be turned off the entire cornea, and its continuity with the surrounding conjunctiva seen, a very intimate adhesion existing at the circumference of the former. This covering of the cornea, so distinct and different from its proper substance, appears under the microscope composed of two laminæ: the more superficial is epithelial and non-vascular; the deeper layer is loose and areolar, and is a modification of the chorion and papillary structure. In and beneath this the vessels from the sclerotic conjunctiva pass; these are very minute and colourless, and most difficult to inject; they have, however, been filled, and have been minutely described by Römer and Müller. Morbid and comparative anatomy afford additional evidence on this point. In chronic ophthalmia red vessels occasionally extend from the circumference of the cornea, over its surface, and render the latter distinctly vascular and opaque. Pustules also form upon the cornea similar to those on the sclerotic conjunctiva; and in very prominent staphyloma, as before remarked, the cornea becomes coated with a distinct cuticle or epithelium. In some of the subterranean mammalia, in some reptiles and fish, a thin integument passes over the front of the eye and of the cornea, and can be easily detached by dissection: in serpents also, during the well-known process of casting their skin, the cuticle is detached from the forepart of the eyes along with that from the head. This fact, however, though commonly adduced in support of the anatomical position we are here maintaining, does not afford any such proof, inasmuch as, according to J. Cloquet (*see Mem. sur les Voies Lachrys dans les Serpens*), there exists beneath this transparent cutaneous frame a conjunctival lining, which is also reflected over the forepart of the eye, so as to form a true oculo-palpebral chamber, communicating with the mouth by a small palatine duct; and when the animal casts its coat it only sheds the palpebral epidermis, but not the conjunctiva, and neither is the oculo-palpebral space opened during that process.

The *lachrymal apparatus* consists of the lachrymal gland and its excretory ducts, the two puncta lachrymalia, the lachrymal canals leading from each into the lachrymal sac, and, lastly, the nasal duct, leading from the latter into the nose.

The *lachrymal gland* is of the conglomerate or compound order of secreting organs; of a pale reddish colour, surrounded by a cellular capsule, situated to the upper and outer aspect of the globe of the eye, a position from which its secretion can most effectually flow over the anterior surface of the globe; it consists of two lobes, a superior or orbital, and an inferior or palpebral. The orbital is the larger lobe, is lodged in the fossa of the frontal bone, behind and within the exter-

nal angular process, of an oval form, about half an inch in breadth from before backwards, and three-quarters of an inch in length from within outwards; its upper surface is convex, and attached to the periosteum of the orbit; its lower is a little concave, and in relation with the globe and with the external and superior recti muscles; its anterior border corresponds to the superciliary arch and to the tarsal ligament; its vessels and nerves enter its posterior margin and inferior surface.

The inferior or palpebral lobe is only partially separated from the former, is smaller and thinner, and enclosed in a more dense capsule; it extends in the upper eye-lid as far as the outer part of the orbital margin of the cartilage, is behind the fibrous ligament of the latter, and rests upon the superior palpebral sinus of the conjunctiva. If the lid be fully everted, it can be seen through the membrane. Six or eight delicate ducts descend nearly parallel from the gland, and open opposite to its lower border by separate orifices, near each other and in a row, on the inner surface of the upper lid, commencing about half an inch from the outer canthus, and a little above the upper margin of the cartilage. These ducts are very difficult to detect, and for a long time were unnoticed by anatomists. They can be well seen in the dog. This organ is the source of the tears which are continually supplied in sufficient quantity to moisten the surface of the lids and of the eye-ball, and, mingling with the more viscid secretion of the mucous membrane, are then partly evaporated, and, according to Majendie, partly absorbed; the remainder are conducted, by the constant motion of the palpebræ, inwards along the palpebral sinuses, and partly along the narrow channel between the ciliary margins of the tarsi and the globe, to the puncta lachrymalia. The *lachrymal secretion* consists of water and one per cent. of muriate of soda, and a yellow extractive matter. The tears are so abundantly afforded, when the entrance of any foreign body excites irritation, or under certain mental emotions, as to flow over the margins of the palpebræ and of the lacus lachrymalis upon the cheek.

The *puncta lachrymalia* are the two small holes in the cartilaginous projections, named lachrymal papillæ; they are always open, and visible to the naked eye, at the inner extremity of the ciliary margin of each cartilage, at the outer extremity of the "lacus," just where the internal fissure commences, and about two lines distant from the inner canthus; each opening is much larger than any of the Meibomian follicles, and will admit a bristle or moderately-sized pin. They both have an aspect outwards and backwards towards the surface of the eye and towards the groove, between the closed tarsal cartilages; the upper one also looks a little downwards; and the lower one, which is more prominent and a little more external, upwards: they are separated by the caruncula, and each leads into the following.

The *lachrymal canals* are two, a superior and inferior. The superior is longer and more curved; from the punctum it first ascends, then bends abruptly inwards and downwards, and enters the anterior and outer or orbital side of the sac. The lower canal first descends a little,

then also bends abruptly inwards, ascends a little, runs close to the upper, and opens into the sac, so near to it that, at first view, they appear to end in common; they generally, however, open distinctly behind the tendo oculi: each canal is lined by mucous membrane, and covered by a fibrous tunic derived from the bifurcation of the orbicularis palpebrarum and tensor tarsi tendons; they are each dense and elastic, whereby their calibre is preserved from collapse, and a little larger at their angles than at either extremity; they bound the lacus and lachrymal caruncle. When the lids are closed their course is more transverse or horizontal, and their angles more acute; when the upper lid is raised the direction of the superior duct becomes more oblique and less angular. Depressing the lower lid has the same effect on the inferior duct; the tears are carried into the puncta, and forced along these canals partly by the absorbing power of their capillary openings, and partly by the adducting power of the orbicular muscle, and of the tensor tarsi, or the muscle of Horner.

The *lachrymal sac* is the upper extremity, or oval *cul de sac*, of the nasal duct, distinguished from it externally only by a slight constriction, and internally by an imperfect valve, or semilunar fold; it is deeply imbedded in an osseous fossa, at the inner and anterior part of the orbit, bounded internally by the nasal process of the maxillary bone, and posteriorly by the anterior concavity of the unguis; open anteriorly towards the surface, also externally towards the orbit, but is covered and bound down in these aspects by the tendo oculi, which crosses it transversely a little below its *cul de sac*, and above its centre, also by a strong and very tense aponeurosis, derived from the margins of this tendon, and which are inserted into the bony margins of the fossa; it is also covered by the skin, and the angular vein and artery are superficial to it, and a little to its nasal side. The tensor tarsi, which may be considered as an appendix to the orbicular muscle, is on its external or orbital aspect. This muscle arises from the vertical ridge of the unguis, and passes forwards and outwards behind the tendo oculi.

Open the sac, and the interior will be seen, soft and of a pale colour, usually filled with adhesive mucus; its *cul de sac* above, its continuity with the nasal duct below, and sometimes a small semilunar fold between them; also, on its anterior and outer wall, the two orifices of the lachrymal canals, near its centre, from above downwards. The sac is situated opposite the middle meatus of the nose, and, if the unguis be perforated, a probe may be passed into this region, or perhaps into the infundibulum. This fibro-mucous sac receives the lachrymal secretions from the small ducts, and transmits them to the nose. The tensor tarsi and orbicular muscles may adduct these ducts, and urge their contents into the sac; how far they can also compress the latter is doubtful, from the strength and tension of the intervening aponeurosis.

The *nasal duct* leads from the sac obliquely downwards, backwards, and outwards, and opens into the anterior part of the outer side of the

roof of the lower meatus of the nose, under cover of the inferior turbinated bone; it is about three-fourths of an inch long, is a little curved, convex backwards, flattened at the sides, and wider about the centre than at either extremity; separated from the antrum by a thin but strong bony lamella, and is on the outer side of the middle meatus and inferior spongy bone. It is a fibro-mucous duct, enclosed in and rather loosely adherent to the osseous canal, formed by the maxillary, unguis, and inferior spongy bones. The membraneous portion is elongated inferiorly beyond the osseous, in the form of a narrow, oblique process or valve, but very variable in extent. Whether this or the superior semilunar fold can act as such is doubtful, but is rendered probable by the fact that air cannot be forced by any effort during life from the nares into the sac, or through the lachrymal ducts.

The student may next examine the muscles, nerves, and vessels of the orbit. The roof of the cavity having been carefully raised, the periosteum usually separates from it, and remains attached to the parts beneath and to the ligament of the upper eye-lid; it appears continuous with the dura mater. As this membrane enters the apex of the orbit by the optic and superior lacerated foramina, it divides into two laminæ; one joins or becomes the periosteum, the other is continued as a sheath on the several nerves. At the optic foramen this arrangement is very evident; it forms a tubular sheath for the optic nerve, and joins the sclerotic coat of the eye. Divide and raise the periosteum; three nerves are seen, the frontal in the middle, the lachrymal externally, and the trochleator internally; the latter rests on the superior oblique, the frontal on the levator palpebræ, and superior rectus, and the lachrymal on the external rectus muscle. Small vessels accompany these nerves. The orbit contains seven muscles and several nerves; the interstices are filled with a quantity of soft adipose substance; this must be carefully drawn out with the forceps, and snipped off with the scissors. The muscles are the levator palpebræ, four recti, and two oblique; all these, except the inferior oblique, arise near or around the apex of the cavity, and thence diverge to their respective insertions. Three are situated above the optic nerve, viz., levator palpebræ, superior oblique, and superior rectus; two are beneath it, the inferior rectus and inferior oblique, and one is at either side, the internal and external rectus.

The *levator palpebræ superioris* is one of the largest and the highest muscles in this region, being immediately beneath the periosteum. Thin, flat, and triangular, it *arises* narrow by radiated, tendinous fibres from the upper or anterior border of the foramen opticum, and from the fibrous sheath of the optic nerve; passes forwards, at first a little upwards and outwards, in the axis of the orbit, becomes broad, thin, and fleshy, and anteriorly bends downwards in front of the eye, and ends in a thin, fibro-membraneous expansion, which is *inserted* into the convex border of the superior tarsal cartilage, and through the medium of a thin fascia, which covers and encloses the muscle, into the convexity of the superior palpebral sinus of the conjunctiva and

subconjunctival fascia, behind or beneath the broad ligament of the tarsus. *Use:* to elevate the upper eye-lid; it also retracts its cartilage beneath the edge of the orbit; at the same time the eye is slightly protruded, either by the swelling and fulness of the muscle within the orbit, or by the partial withdrawal of the compression of the lid in front; and at the same moment, as remarked by Sir C. Bell, the lower lid is depressed by slipping off the convexity of the protruding globe, and thus the forepart of the organ becomes fully exposed, as in staring. It lies above and rather external to the superior rectus; the trochleator nerve crosses over its origin, also the ophthalmic, the frontal division of which, and its branches, continue on its upper surface and nearly parallel to it. A branch of the third, or the motor nerve, is distributed to its inferior or ocular surface. When this nerve and muscle are in a state of paralysis the upper lid droops down in front of the eye—an affection named "ptosis." The inferior lid is elevated by the orbicularis palpebrarum, and has no special muscle; neither has it any depressor. In most birds the lower lid chiefly covers the eye during sleep, and possesses a distinct depressor muscle.

*Fig. 72.**

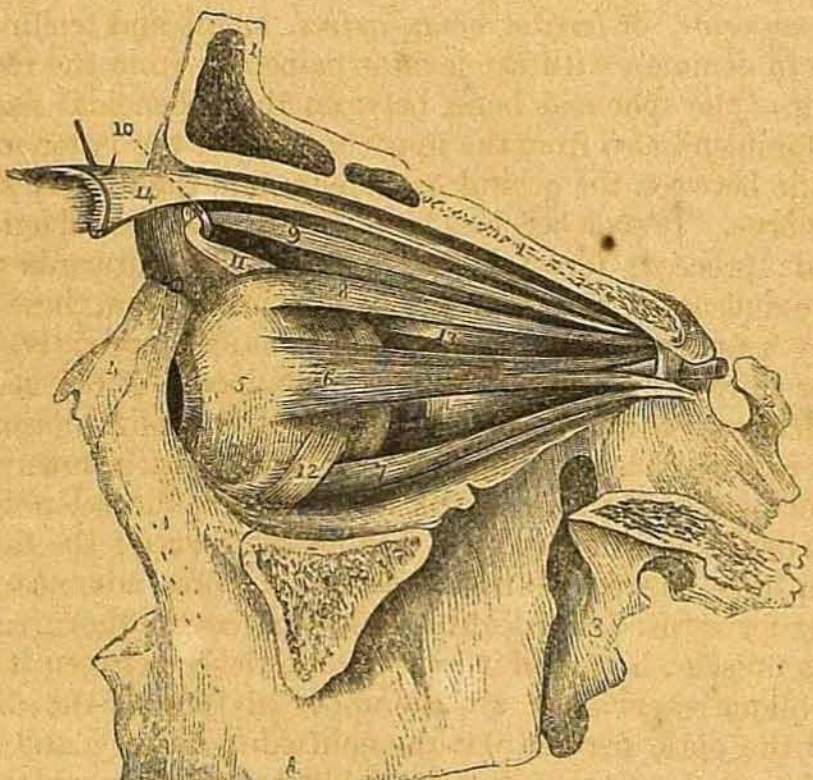

* The muscles of the orbit of the left side. 1. 1. Portion of the frontal bone, forming part of the roof of the orbit. 2. Portion of the sphenoid bone. 3. External pterygoid plate of sphenoid bone. 4. The ossa nasi. 5. The globe of the eye. 6. The external rectus muscle, with its two heads of origin. 7. The inferior rectus. 8. The superior rectus. 9. The superior oblique muscle of the eye. 10. The cartilaginous pulley of the superior oblique. 11. The reflected tendon of same muscle. 12. The inferior oblique muscle. 13. The internal rectus. 14. The levator palpebræ superioris.

The six following muscles are proper to the eye-ball; four are called *straight*, and two *oblique;* by their several actions the varied motions of the eye-ball are performed. We shall first examine their anatomical relations, and afterwards consider their actions individually and combined. The four muscles named *recti* are by no means straight, for they all converge towards the apex of the orbit, where they arise, and as they pass forwards they diverge so as to bound a sort of pyramidal space enclosing the greater part of the globe of the eye, the optic nerve, some smaller nerves and vessels, a quantity of adipose substance, and a strong fascia; and, lastly, each of these muscles bends a little around the forepart of the globe to reach its insertion. Each of the recti, therefore, must take an oblique or slanting course, and must represent a curve concave towards the eye, convex forwards and outwards towards the orbit; they are each of a triangular form, the apex behind, the base before; the superior is the thinnest and smallest, the external the longest, and the internal is the shortest and thickest; they all terminate in front in thin tendons, which extend to within a few lines of the circumference of the cornea. These tendinous expansions have long received the name of "tunica albuginea," a term which is incorrect, as their margins do not coalesce, being only connected together by an investing fascia.

Rectus superior, or *levator oculi*, *arises*, small and tendinous, beneath and in common with the levator palpebræ, from the root of the lesser wing of the sphenoid bone, between the sphenoidal fissure and the optic foramen; also from the upper margin of the latter, or rather in the angle between the orbital periosteum and the fibrous sheath of the optic nerve. It soon becomes fleshy, thin, and flat, about half an inch broad; proceeds forwards and a very little outwards over the optic nerve and upper part of the globe; separated from these by some fat, also by a fascia (ocular fascia), to be noticed presently. About its anterior third it ends in a thin tendon, composed of bright parallel fibres, which pass through this fascia, the latter being continued as a sheath over the muscles; the tendon then bends a little downwards on the anterior part of the eye, and is *inserted* into the sclerotic, about four lines, or the third of an inch, behind the cornea; the line of insertion is a little convex, so that the central fibres advance about a line further forwards. The levator palpebræ covers the greater portion of this muscle; a part of it appears anteriorly between it and the superior oblique; beneath it are the upper division of the third, the nasal, and the optic nerves, also the ophthalmic artery and the eye-ball. A fine areolar tissue, often resembling a small synovial sac, lies beneath the tendon of this as well as of the other recti as they bend towards the forepart of the eye to their insertion. This must facilitate the action of these muscles and the motions of the eye-ball.

Rectus internus, or *adductor oculi*, *arises*, in common with the last, from the optic sheath, also from a strong, semicircular, fibrous tissue, *tendon* or *ligament of Zinn*, which is attached to the lower or posterior margin of the optic foramen, and to a depression on the inner

side of the sphenoidal fissure; proceeds nearly horizontally forwards, ends in a tendon which pierces the ocular fascia; is *inserted* in the same manner as the last, and between it and the inferior rectus, into the sclerotic, about three lines behind the cornea by its central fibres; its superior edge is distant four and its inferior edge five lines (Lucas).

Rectus inferior, or *depressor oculi*, *arises* from the ligament of Zinn, in common with the last and with the lower head of the external rectus, passes forwards and downwards, ends in a tendon which is disposed similarly to the others, and is *inserted* into the sclerotic about the same distance from the cornea as that of the superior rectus, to which it is directly opposite; it lies beneath the optic nerve and the globe, is separated from the floor of the orbit by the inferior oblique muscle and much adipose tissue.

Rectus externus, or *abductor oculi*, is the longest and most oblique of the recti; *arises* by two very distinct origins, an inferior from the ligament of Zinn, in common with the two last muscles, and a superior or external from the optic sheath and margin of the optic foramen, between it and the sphenoidal fissure, in common with the superior rectus; a tendinous arch connects these heads, from which additional fibres arise; between these origins pass the third, the nasal, and the sixth nerves, and sometimes the ophthalmic vein. The muscle proceeds very obliquely forwards and outwards, and its tendon is inserted into the sclerotic in the same manner as those of the other recti, but does not approach so close to the cornea, its central fibres being nearly five lines, and its upper and lower six lines distant from it. Its external surface corresponds to the wall of the orbit, and to the lachrymal gland anteriorly; the lenticular ganglion, ciliary nerves, vessels, and fascia separate it from the optic nerve and the globe; the sixth nerve is wholly distributed to its ocular surface.

The recti muscles are all connected together by a cellulo-fibrous tissue, which may be named *ocular fascia*. Though not very thick or strong, it is tough, flocculent, and difficult to remove; it covers these muscles as far back as their origin, and is continued anteriorly over their tendons, but of a finer and denser tissue, nearly to the circumference of the cornea, and beneath the conjunctiva, on the ocular surface of which it is reflected outwards towards either canthus of the orbit, and forwards to join the fibro-ligamentous structure and the cartilages of the palpebræ. It is also prolonged as a thick sheath round the trochleator tendon, as far as its pulley, to which it is connected, and around the inferior oblique to its origin. This fascia so far seems to connect and retain all these muscles and tendons in their proper relative situations, both to each other and to the eye-ball; but it has a still further and more interesting relation, for it is continued beneath the four recti, forming for each a perfect sheath and a non-adherent envelope for the posterior part of the eye-ball. To expose this portion, separate the margins of two or three of these muscles; divide them about their centre, avoiding any injury to the subjacent fascia; raise the divided muscles, one portion backwards, the other forwards.

This fascia is then seen to pass backwards as far as the optic nerve, in the sheath of which it is lost, and forwards as far as the tendons of the recti and obliqui, round each of which it is prolonged in an infundibuliform manner to the external surface of their fleshy fibres, on which it is expanded, as before stated, while a thinner lamina is also continued forwards upon the conjunctiva, and ultimately to the eyelids. This membrane covers the ball very loosely, so that the latter can move or rotate freely within it. This will be better seen if the fascia be divided longitudinally, or from before backwards; it is attached to the sclerotic coat by areolar or serous cellular tissue, containing the ciliary vessels and nerves, and a little adipose substance. This deep portion of the ocular fascia is thick, strong, and elastic, but variable in these respects; it is of a yellowish white colour, and appears composed of areolar and yellow elastic tissue, rather than the white fibrous basis of ordinary fasciæ or aponeurosis. When the divided margins of it are held asunder, its prolongations round the six tendons are seen, presenting internally smooth spaces around each; these are not, however, foramina, or perforations in the fascia, but merely the inner extremities of the funnel-shaped processes continued from this deeper portion to the superficial surface of the muscles. This fascia serves as a loose covering for the eye, within which it can rotate freely, and is protected by it from the friction of the surrounding muscles; also, by its attachment to the optic nerve behind, and to the eye-lids and orbit in front, it in some measure contributes to support and suspend the organ in this region. Although this fascia has long been familiar to every practical anatomist, it has only been noticed by modern writers. Tenon, I believe, has first described it (*Tenon, sur une nouvelle tunique de l'œil, Mem. et Observ. sur l'Anatomie*). Dalrymple, in the year 1834, has also noticed it very correctly in his Anatomy of the Eye (page 248); but Malgaigne, in 1838, in his *Anatomie Chirurg.*, has described it with anatomical correctness (page 375), and names it, from its peculiar whitish appearance, *albugineal membrane;* and again, in his *Manual de Medecin Operatoire* (p. 376), points out the necessity of dividing, not merely the subconjunctival portion of this membrane when cutting across the tendon of the internal rectus for the relief of strabismus, but also the deep or the ocular layer, which forms the posterior part of the sheath of the muscle; and he states that, if the tendon be divided close to its insertion, the superficial lamina only of this fascia will be cut through, and the operation will prove of no avail, and, therefore, the cutting instrument should pass behind the rectus, near its fleshy portion, so as to divide this deeper fascia. This membrane has been also named *ocular*, *subconjunctival fascia*, *fibrous capsule of the eye*, &c. Mr. J. M. Ferral, in 1841, has described it as a *new structure in the orbit*, and named it *tunica vaginalis oculi* (Dub. Jour. of Med. Sci., July, 1841, p. 329). For the exposure of it he directs the following dissection: "Divide both palpebræ vertically, turn the separated portions backwards towards the forehead and cheek, and fix them by hooks; divide the conjunctiva at

its angles of reflection from the eye-lids to the ball, and separate the edges. We expose a distinct fibrous tunic, of a yellowish white colour, continuous in front with the posterior margin of the tarsal cartilage, and extending backwards to the apex of the orbit, where its consistence is less marked. This dissection may be made with the probe or director, gently breaking the cellular connexions between the ball and this *new organ*. Its colour differs from that of its external surface, being perfectly smooth where the eye glides over it in its movements. The muscular substance of the recti is no where visible, as they lie outside this fascia, which insulates and protects the eye in the most perfect manner. In the concavity of this tunic, and half an inch posterior to its orbital or anterior margin, are found six well-defined openings, through which the tendons of the muscles emerge in passing to the sclerotic, and over which they play, as over pulleys, in their course; the tendons are loosely connected to the edges of those apertures by fine cellular tissue, which oppose no obstacle to their gliding motion." Much of the appearance, however, last described, arises from the tense and constrained position in which the tissues are held, by the hooks in the first instance fastening them in front. To this fascia Mr. Ferral ascribes more mechanical uses than we have stated above, and with which we cannot entirely concur; he conceives it is capable, first, of protecting the eye-ball from the pressure of the recti muscles during their action; second, of preventing these muscles retracting the eye; third, that their rotatory influence is secured and facilitated by passing through what he describes as distinct trochlear openings in the fascia, and that their force acquires thereby a new direction, that is, they act as if they arose from the sides, and not from the apex of the orbit; pathologically, he conceives that certain cases of disease within the orbit, accompanied by protrusion of the eye-ball, are to be explained by reference to this tunic.

Use.—From the manner in which the four recti muscles are arranged, converging behind, expanding and diverging before, connected together by fasciæ, embracing the eye as it were by a conical muscular capsule, but separated from immediate contact with it by the elastic albugineal membrane, or ocular fascia, and from their tendinous expansions being continued over the forepart of the globe, as far nearly as the cornea, they must possess considerable power as rotators of the spherical body, and can turn the cornea or the pupil in almost every direction with the slightest possible muscular effort, and with the greatest accuracy and precision. Their combined actions, even little more than their mere tonic state, can maintain it fixed steadily upon the object, and individually they can rotate it in different directions. The superior and inferior can turn it on its transverse axis, that is, on an imaginary line passing through it from the temple towards the nose: the superior rectus, by rotating the ball on this axis, will turn the cornea and pupil upwards, the inferior downwards; hence the former is named levator, or attollens, the latter depressor oculi; corneæ would be a more suitable term, for the whole eye is neither raised nor depressed,

but merely rotated. In like manner the internal and external recti rotate the organ on its vertical axis, that is, on a line supposed to pass through the centre of the globe from the roof to the floor of the orbit; the internal rectus, by rotating the eye on this axis, turns the cornea and pupil inwards, the external outwards; hence the former is called adductor, the latter abductor oculi. The extent to which these several motions can be carried varies in different individuals. The rotation on the vertical axis, whereby the cornea moves horizontally inwards towards the nose, and outwards towards the temple, appears more extended than the rotations on the transverse axis, or those of the cornea upwards and downwards; in neither case, however, can the eye be rotated to such an extent that the cornea can become concealed by the lids. The recti have not the power of rolling the eye, or rotating it on its long or antero-posterior axis, that is, a line supposed to pass through the centre of the cornea and pupil to the back part of the orbit. This rolling or rotatory motion is most probably effected by the oblique muscles, to be considered presently. In addition to rotation in the four distinct directions just mentioned, the cornea can also be directed in the intermediate or diagonal lines; thus the superior and internal recti can direct it upwards and inwards, the superior and external upwards and outwards, the inferior and internal downwards and inwards, and the inferior and external downwards and outwards. By the rapid succession of these several actions the organ may also undergo a sort of circumductory motion, different from rotation, or rolling on the antero-posterior axis. In the former the centre of the cornea describes a portion of a circle; whereas in rotation on the antero-posterior axis the centre of the cornea remains fixed, and forms the anterior extremity of the imaginary axis round which the circumference of the cornea revolves. It has been maintained by some that the combined action of the four recti can also retract the eye to a greater depth in the orbit, a change which is effected in many of the lower animals by a distinct muscle, confined to the posterior part of the orbit and of the eye, named the "retrahens oculi;" there is no proof, however, that these muscles can, or that they ever do, exert this power in the human subject. To accomplish it, the four must combine in one strong and simultaneous contraction, which is contrary to their usual mode of action, as in general only one or two act at any one time; neither is there any empty space within which the eye can be easily drawn, as the orbit is exactly filled by its contents, which, though yielding, are elastic; the connexion of the globe anteriorly to the palpebræ and canthi of the orbit serves to keep it forward, and the oblique muscles can also afford opposition to any retracting force. Another opinion also, formerly prevalent among anatomists, and still entertained by some, but one equally destitute of proof, is that the simultaneous contraction of these four muscles can compress the eye-ball so as to alter its shape and elongate its antero-posterior diameter, and thus contribute to the adaptation of its optical apparatus to vision at different distances. The recti muscles have been thought by some to denote peculiar passions

or emotions of the mind, and have accordingly received these fanciful names: the superior, *superbus* or *mirator;* the inferior, *humilis;* the external, *indignatorius;* and the internal, *amatorius* or *bibitorius*, from the eyes being turned inwards in drinking.

The oblique muscles are two in number, the superior and inferior.

The *obliquus superior*, or trochleator, is long and slender, and rather round, situated at the upper and inner part of the orbit; *arises* by a delicate tendon from the sheath of the optic nerve and from the inner margin of the optic foramen, on the inner side of the levator palpebræ, and between the superior and internal recti; it passes forwards and a little upwards and inwards along the os planum, parallel to the suture between it and the frontal; ends in a round tendon which passes through the cartilaginous pulley, attached by a moveable fibrous ligament to a depression behind the inner angle of the os frontis, and lined by a synovial membrane, which admits of the free play of the tendon; the latter is then reflected backwards, outwards, and a little downwards, enclosed in a membraneous sheath from the ocular fascia, over the internal rectus, and beneath the superior rectus, that is, between it and the globe, and, becoming broad and thin, is *inserted* into the posterior part of the sclerotic coat, between the superior and external recti, and nearly midway between the cornea and the entrance of the optic nerve, or nearly on a level with, but a little behind, the transverse axis of the eye, and external to the vertical. The fourth nerve is distributed to the upper or orbital surface of this muscle; the nasal nerve and ophthalmic artery are beneath it. The pulley is generally a semicircular cartilage, its two cornua being attached by short ligaments to the bone. In some instances there is a bony pulley, like the hamular process on the pterygoid plate of the sphenoid. As this pulley changes the direction of the tendon, the action of the muscle is directed towards this point; and in considering the use of the muscle we may regard it as arising from the pulley, a point nearly vertically opposite to the origin of the inferior oblique muscle.

The *obliquus inferior* is the shortest of the group, and the only one that is not connected to the apex of the cavity, being situated at the anterior and inferior part of the orbit, behind the lower eye-lid; *arises* tendinous from a rough ridge, behind or within the orbital margin of the superior maxillary bone, above the infraorbital foramen, and external to the lachrymal sac; it soon forms a flat, thin muscle, which ascends obliquely outwards and backwards, curving in a semicircular manner beneath the inferior rectus and the eye-ball, then ends in a broad, thin tendon, which ascends between the eye and the external rectus, and is *inserted* into the posterior external part of the sclerotic, between the external and superior recti, near the expansion of the superior oblique, and a little behind the transverse axis, and of course external to the vertical axis of the eye-ball. This muscle can be exposed either by dissecting the orbit from above downwards, or from below and from before by removing the lower eye-lid and dividing the inferior palpebral sinus of the conjunctiva: it receives on its ocular surface the

long branch from the inferior division of the third nerve, which is connected to the lenticular or ophthalmic ganglion. *Use.*—The two oblique muscles may be considered as running from the inner side of the orbit to the outer and back part of the eye, nearly at right angles with its antero-posterior axis, one above, the other below it, and are peculiarly well adapted for rotating the eye on this axis, that is, on a line supposed to pass through the centre of the cornea and of the eye-ball backwards towards the apex of the orbit. The lower oblique will roll or rotate the upper and outer part of the cornea round this line downwards and inwards, and the superior oblique will roll it in the opposite direction, and rotate the upper and inner border downwards and outwards. They cannot have much influence in rotating it either on its transverse or vertical axis unless assisted or wholly unopposed by the recti; neither can they execute the circumductory motions. Mr. John Hunter, in an essay (Animal Economy, p. 254) on the action of these muscles, has fully stated the difference between their action and that of the recti, and has clearly explained their power and their use as rotators of the eye-ball round the antero-posterior diameter. A simple and satisfactory experiment, also, has been made, and detailed by Dr. G. Johnstone (*see* Todd's Encyc. of Anat., art. "Orbit"), where each of these muscles being exposed and excited to contraction by the electric current, these rotatory motions were instantly and rapidly performed. These muscles, also, from their oblique course backwards, one a little downwards, and the other upwards, can also turn or rotate the eye somewhat on the other axes, so as to alter the direction of the antero-posterior one, and thereby the aspect of the cornea and pupil. It is difficult to determine the extent and even the direction of this power during life and health, as one or more of the recti may be, and generally are, engaged at the same time; neither can it be very decidedly proved in the dead body, for traction of the muscle is but an unsatisfactory test, where the organ, having lost the steadying or balancing influence of the recti muscles, is only supported by soft and yielding structures. Traction of the inferior muscle appears to direct the cornea somewhat upwards and inwards; and that of the superior oblique is said by many to direct it downwards and outwards, while others maintain that it directs it downwards and inwards; but the general opinion, and, I believe, the correct one, is, that it turns it downwards and outwards.* From the slanting direction of these muscles backwards they have been considered by some not only as antagonists to the retracting influence of the recti, but that they can also draw forward the eye-ball, as in staring intently on any object; the prominence of the eye-ball, however, at this time, is probably apparent rather than real, and some deception may arise from the greater elevation of the upper lid, and consequent exposure of a larger portion of the sphere; the eye, however, is always a little protruded by the elevation of the superior palpebra. Those who maintain that the recti can, by

* In the former editions of this work I have stated, I believe incorrectly, "downwards and inwards."

their combined action, alter the form of the eye, also attribute to the oblique an influence of the same nature, either assisting, modifying, or perhaps antagonizing that of the recti, and conceive that, by these agencies, the interior of the optical apparatus may be adjusted to vision of objects at different distances. This hypothesis, however, does not rest on any positive proof, and indeed, from the nature of the inquiry, appears almost incapable of it. The oblique muscles may also be considered as supporting the eye on its outer or temporal side, where the wall of the orbit is short, forming a sort of sling around the outer side of the globe, and may thus not only oppose the abducting power of the external rectus, but also suspend the organ, and incline it towards the inner rather than to the temporal side of the cavity, and thus both oblique muscles can cooperate with the internal recti. In rotation of the cornea downwards and outwards the superior oblique may be assisted by the inferior and external recti, while their combined power will be resisted, or rather balanced, by the superior and internal recti and by the inferior oblique; in rotation of the cornea upwards and inwards the inferior oblique may be assisted by the superior and internal recti, and balanced or opposed by the superior oblique and inferior and external recti. Excessive action of the superior or of the inferior rectus may be resisted, the former by the superior oblique, the latter by the inferior. Although both oblique are said to draw the eye forwards, this does not appear so evident in traction of them in the dead state, because the eye is thereby drawn inwards; perhaps, however, during life, this latter tendency being opposed by the external rectus, they may exercise that influence in a slight degree.

It is difficult, even by the closest observation on the living, to appreciate the precise action of the orbital muscles, either individually or combined, for almost all the motions of the eye-ball are beautifully and wonderfully assisted by the lateral and antero-posterior motions of the head upon the atlas, and by the rotation of both upon the dentatus, as well as by the mobility of the cervical vertebræ generally. In the exercise of vision, although the cornea and pupil appear to have changed their direction, and really have done so in one sense, yet the change may have been effected at the occipito-vertebral articulations, and the orbital muscles have been engaged, not so much in moving or rotating the organ, as in keeping it fixed and steady, and thereby retaining its antero-posterior diameter in the visual axis. Another circumstance which deserves attention, when analyzing the actions of the orbital muscles, and one extremely interesting in itself, is the consent or association between certain muscles, and the antagonism between others; and these principles may be observed in operation not merely in the muscles of one side, but of both. Some circumstances in the nervous arrangements in this region, already alluded to (*see* Nervous System), may partly explain these phenomena. Thus the third nerve supplies five muscles of this group, viz., three recti, one oblique, and the levator palpebræ, and it also, most probably, endows the iris with its motor power. This nerve, therefore, associates these parts in a remarkable

manner; thus the levator palpebræ and levator oculi act in unison, and the inferior oblique and internal and superior recti concur in turning the cornea upwards and inwards, as in sleep, and the iris is at the same time contracted. There is also an association between those muscles in each orbit which are supplied by these nerves; thus both eyes always move together upwards and downwards, and volition cannot alter this tendency. The internal recti can also act in unison, and adduct both eyes; this motion, however, is rather a constrained one. The sixth nerves also exhibit a consentaneous action in returning the eyes from this state of forcible adduction to their former state; yet the external recti do not concur in their ordinary action of abduction, as when one eye is turned outwards the opposite is directed inwards; they cannot maintain the eyes in a state of divergence, and hence, probably, this nerve is destined to this single muscle. The superior oblique muscle, in like manner, receives but a single nerve, and is not associated with that of the opposite side; when the pupil of one eye is directed downwards and outwards, that of the other looks downwards and inwards. There are, therefore, certain combinations of muscular actions that cannot be explained on the anatomical nervous arrangements, or on any settled principles of consent or of antagonism. Thus, when one eye is everted, the internal rectus of the opposite side is in action, and, therefore, the two internal recti are then opposed, or, in other words, there is an association between the sixth and third nerves of opposite sides, nerves which, in most other motions, are in opposition. When the superior oblique and external rectus of one eye direct it downwards and outwards, the opposite eye is directed downwards and inwards by the inferior and internal recti; we then have an association and consent between nerves and muscles which, at other times, are totally opposed. To these and many other examples, which do not come within the scope of the explanation above-mentioned, we might add that the motions of the head upon the spine are as rapid, and as consentaneous with every required change in the direction of the cornea, as are those of the orbital muscles; and certainly no anatomical nervous arrangements that we know of can satisfactorily account for that connexion. Though pleasing to the speculative anatomist to attribute the several combinations of the actions of the orbital muscles to the peculiar distribution of the nerves, each aided "either by the impulse of consentaneous motion or of antagonism," yet we must confess that the theory is inadequate to explain all the phenomena, although it suits several of them. Many of these combined and opposing actions, and which are in a great degree involuntary, appear to be innate or instinctive tendencies in certain muscles to act under certain circumstances; or they have gradually and imperceptibly acquired the power by practice and habit, so that the mind is unconscious of their acts; or, according to the excito-motor theory, the impressions made from without are rapidly conveyed to the nervous centre, and as rapidly give rise to the reflex motion in the manner required. The actions of the orbital muscles, and the association of the latter by different

nerves, are of great interest, not only in connexion with anatomy and physiology, but especially with the pathology of the eye and its appendages. Our limits, however, will not permit us to pursue the inquiry further. Should the student wish to do so, he may consult with advantage Hunter's An. Econ. (*loc. cit.*); Muller's Phys. by Baly (p. 100, *et seq.*); Sir C. Bell on the Nervous System (p. 170); also a paper by Dr. Evers on the Physiology of the Muscles and Nerves of the Orbit (Dublin Journal of Medical Science, May, 1841, p. 165). Sir C. Bell concurs in the general opinion that the superior oblique muscle turns the pupil downwards and outwards, and the inferior oblique turns it upwards and inwards under the upper eye-lid. He further considers that both perform the involuntary movements of the eye-ball, and produce an insensible rolling of it, holding it in a state of suspension between them. He also considers that the eye is always rolled by the inferior oblique upwards and inwards, under the protection of the upper lid, in sleep, or during any violent excitement, as in difficult respiration and sneezing. To support this opinion he has recourse to the strange hypothesis that the fourth nerve causes a relaxation of the superior oblique, and, therefore, the inferior must roll the eye in this direction with greater effect. There is no good reason, however, to support this novel theory, "that an active influence of a nerve can cause a relaxation of the muscle it supplies;" neither is there any ground for assuming that the inferior oblique muscle is less a voluntary one than the three recti and the levator palpebræ muscles, which are all supplied from the same, or the third nerve.

The blood-vessels which supply the parts within the orbit are the ophthalmic artery and its ramifications, assisted by small vessels from the facial, temporal, and internal maxillary arteries. The *ophthalmic* arises from the internal carotid just as the latter has emerged from the cavernous sinus, and is curving upwards by the side of the anterior clinoid process; it immediately becomes attached to the sheath of the optic nerve, being placed inferior and rather external to it, passes through the optic foramen into the orbit, and still bears the same relation to the nerve; it soon, however, ascends obliquely over it, and passes forwards and inwards to the nasal side of the orbit, and finally terminates at the inner canthus. This vessel sends off numerous branches to supply the optic apparatus. These have been already noticed (*see* Vascular System); they mostly accompany the branches of the ophthalmic division of the fifth nerve. The veins which return the blood from the eye and its appendages to the general system do not exactly correspond to the ophthalmic artery and its branches. The veins of the temple, forehead, and face, receive the branches from the eye-lids, also some from the inner side of the orbit; others pass through the spheno-maxillary fissure, and join the deep temporal veins: those from the ocular portion of the conjunctiva, from the lachrymal gland, the muscles, and fat of the orbit, also the ciliary, choroid, and retinal, all proceed backwards, end in three or four branches, which unite into one considerable vein, the *ophthalmic*, which escapes from the orbit by

the inner wide portion of the sphenoidal fissure, generally below the lower origin of the external rectus muscle, but sometimes between its heads, also inferior to the sixth nerve; it then enters the cavernous, whence the blood is carried by the petrous sinuses to the internal jugular veins; sometimes there are two ophthalmic veins, one between the heads of the recti, the other beneath them.

The nerves which supply the optic apparatus have been already examined (Nervous System, page 535), and, with the exception of the optic, have been individually described. Considering the size of the eye and its appendages, these nerves are large and numerous, and present some interesting peculiarities. No less than four entire nerves, and a portion of three others, are distributed to this organ, namely, the second, third, fourth, and sixth; one division of the fifth, and branches of the seventh or facial and of the sympathetic. Each of the cerebral nerves arises from a distinct part of the nervous centre, and each ministers to some distinct and special purpose, which can be ascertained in respect to many of them with tolerable certainty, but, in respect to others, is still involved in obscurity and doubt. Their respective functions have been deduced partly from observation, experiment, and reasoning from analogy, and partly from pathological research. The optic nerves are remarkable and peculiar for the intimate connexion that exists between them. The origin, or central attachment, may be considered as one common point of union, for the corpora geniculata and quadrigemina, the optic thalami, the posterior, and the pineal commissures, all constitute one central nervous mass, through which the nerves of opposite sides are united into one: each tractus, in its course forwards, is in close apposition with the crus cerebri, the great volition tract, and anteriorly it is connected to the tuber cinereum and to the thin extremity of the corpus callosum, or superior cerebral commissure. In front of the pituitary body the two nerves are joined in the chiasma, or commissure, partly by transverse and partly by decussating fibres; thence each passes forwards and outwards, of a flattened form, invested by a close neurilemma of pia mater and a loose sheath of arachnoid; the latter is reflected from it in a *cul de sac* in the foramen opticum of the sphenoid bone. Here the nerve receives a sheath from the dura mater, one layer of which joins the orbital periosteum, the other encloses the nerve as far as the sclerotic, with which fibrous membrane it becomes continuous. Having passed through the foramen, the nerve is encircled by the annular tendinous origin of six of the orbital muscles, and then bends somewhat, and proceeds forwards, and a little inwards and downwards, to reach the back part of the eye, which it joins on the inner side of its antero-posterior axis, and is here obviously constricted; it then passes through the sclerotic and choroid tunics of the eye, as will be seen in the dissection of the globe. From the optic foramen to the eye its course is tortuous, and longer than the space it traverses, whereby it admits of the free motion of the ball without itself sustaining any tension or extension. It is surrounded by the recti muscles, some adipose substance, and anteriorly

by the ocular fascia. The ophthalmic ganglion lies upon its outer side, and the ciliary nerves and vessels twine around it. In the optic foramen the ophthalmic artery is beneath it, but, in the orbit, this vessel bends around its outer and upper aspects to its inner side; near the globe its ramus centralis retinæ pierces the nerve obliquely, and runs along its axis to the interior of the eye. Of the functions of the *optic nerves* there can be no doubt: their expanded terminations receive the impressions of the rays of light which impinge upon their concave surface, and the nerves transmit these impressions to the brain, the seat of perception. The office of the palpebral filaments of the *facial* is also well established: they endow the orbicular or sphincter muscle with motor power, whereby it closes the lids and protects the eye from injury, and shades it from the light. When this nerve is suffering from paralysis, a common result of inflammation of its sheath in some part of its course, the eye remains constantly exposed, and the individual cannot close it, neither are the tears directed to the puncta; the features on the same side are also affected, and the expression of the countenance is changed. During sleep, however, the eye is partially covered, as the upper lid falls from the relaxation of its levator muscle. The other five nerves are all closely grouped together by the side of the body of the sphenoid bone, in the wall of the cavernous sinus, and form what I have ventured to name the *orbital plexus;* an arrangement somewhat analogous to the great plexuses on the spinal nerves, only that in this the nerves do not decussate or interchange their filaments, but pursue their course unbroken. In this plexus, however, more or less connexion exists between the several nerves, and a sort of general union is effected by the filaments of the sympathetic; and, as the plexus at the head of each upper and lower extremity associates the several nerves which are to supply the region beneath, so this may be designed to effect a similar purpose with regard to the orbit and its contents. All the nerves of this plexus enter the orbit through the foramen lacerum or sphenoidal fissure, and soon separate, each passing to its destination. The *third* resembles nerves in other parts of the body, by dividing into several branches to supply different muscles, no less than five, namely, the levator palpebræ, the superior, internal, and inferior recti, and the inferior oblique; it is also connected to the lenticular or ophthalmic ganglion by a short, thick filament, which passes between this body and the long branch to the inferior oblique muscle. This nerve is named the *motor nerve* of the orbit, as it seems to excite so many of its muscles, and most probably the iris. This pair arise very close together from the base of the cerebrum, and serve not only to excite, but also to associate several muscles in each orbit, as well as those of opposite sides, and produce their consentaneous action. Thus the levator palpebræ and oculi act together on one or on both sides, and also the levator and depressor of both eyes; and in sleep the internal and superior recti and inferior oblique act together, and the iris also is contracted. That the lenticular ganglion should be connected in all cases to the inferior oblique nerve

cannot be perfectly explained; though it may be suggested that, as both oblique muscles are important agents in the optic apparatus, in adjusting the axis of the eye to the visual line, by the delicate rotation and balancing of the globe, so a special connexion is established between this muscle and the iris by the same motor nerve, whereby the contraction and expansion of the pupil become consentaneous with certain motions of the eye-ball, as well as from the influence of increased or diminished light. Paralysis of the third nerve affords negative evidence, which assists in proving its function to be motor: several of the motions of the eye are lost, the upper lid droops and cannot be raised by volition (ptosis); the ball appears fixed, the cornea cannot be directed upwards or inwards, but may be everted by the external rectus, and rotated downwards and outwards by the superior oblique; the iris is often dilated and insensible to light, or responds feebly to its influence; vision is feeble, imperfect, and often double, as the affected eye cannot follow the motions of the sound one, so as to preserve the parallelism of their axes, and, therefore, the pencils of luminous rays from the object do not fall upon the corresponding parts of the two retinæ. In this affection, when vision becomes much impaired, we may suspect that either the optic nerve, or some part of the brain itself, has also become diseased. The *fourth*, or trochleator nerve, forms a striking contrast to the third, being exclusively distributed to the superior oblique muscle; it is remarkable for its remote and peculiar origin, delicate size, and long and isolated course to the orbital plexus; it is the motor nerve to the trochleator muscle, but most probably it also carries with it some sensitive filaments from the plexus in the sinus, or from the ophthalmic nerve when crossing it in the foramen lacerum. Although the fourth pair arise very close together, the muscles they supply are not associated in their actions. From the proximity of their origin to that of the optic nerves they appear well adapted for exciting reflex motion in accordance with any peculiar impression made upon the retina; and these muscles, like the inferior oblique, which are associated with the iris, are, most probably, of great service in effecting the delicate or adjusting motions of the visual axis. Paralysis of the fourth nerve and trochleator muscle so seldom occurs, as a separate and well-marked affection, that no conclusion can be deduced from it as to the function of either. The *fifth* nerve, or the ophthalmic, accompanies in a great measure the ophthalmic artery, and supplies filaments to all the appendages of the eye, to its mucous surface and lachrymal apparatus, also to the ophthalmic ganglion and to the internal structure of the globe. It is a sensitive nerve, and imparts feeling and organic sensibility to the eye-lids, conjunctiva, and to all parts within the orbit; its minute filaments accompany the nutrient and secreting vessels, and serve to maintain the healthy organization of the entire apparatus, and thus indirectly to assist the optic nerve in its special function. How far the orbital branches of the sympathetic may aid the ophthalmic nerve in nutrition and secretion is unknown, but most probably they exert some influence in these re-

spects. When the fifth nerve is paralyzed, the eye-lids and conjunctiva, and even the cornea, become insensible to contact; the surface is dry, or not moistened as usual; the lachrymal secretion is suspended; the iris is sometimes sluggish and languid; the healthy state of the tissues is deranged, and the cornea becomes the seat of destructive inflammation, and vision is impaired and ultimately lost; the optic nerve itself, also, not unfrequently falls into an unsound state during the course of the disease. The *sixth*, or *abducens* nerve, resembles the fourth in being distributed exclusively to one muscle, the external rectus, paralysis of which is denoted by the internal strabismus, the inability to direct the cornea or iris towards the temple, and by the imperfect and double vision when the individual attempts to look outwards towards the affected side. This nerve communicates more freely or directly with the sympathetic than do the other orbital nerves. The precise office of the *sympathetic nerves* in the orbit is not ascertained. These filaments arise from the superior cervical ganglion, accompany the internal carotid artery, and in the cavernous sinus join, first, the sixth nerve, and subsequently the other nerves in the plexus; branches accompany the ophthalmic artery and its ramifications, and a delicate twig joins the nasal root of the lenticular ganglion. As branches of the sympathetic accompany the nutrient arteries in other parts of the body for the purposes of organization, we may suppose they assist in this office in this region; they also maintain a connexion between the several nerves of the orbit and between the ophthalmic and the other ganglions in the system; but the exact object of the latter we cannot determine, although it may seem to explain the sympathy between the eye and the viscera of organic life. Thus the excited or depressed action of the heart quickly changes its appearance and expression, and many diseases of the digestive system are not unfrequently attended by, and probably in some instances the exciting cause of, deranged action of the orbital nerves and muscles, and of impaired vision; and these latter affections sometimes disappear as the former have been removed. In addition to these several nerves, the superior maxillary also sends some sentient filaments into the orbit, through the spheno-maxillary fissure; these supply the cellular and adipose tissue, and one (the malar) not unfrequently communicates with the lachrymal branch of the ophthalmic.

SECTION V.

DISSECTION OF THE GLOBE OF THE EYE.

The eye is placed at the anterior and internal part of the orbit, behind the conjunctiva, surrounded by fascia, muscles, vessels, nerves, and adipose substance, and retained in its situation by the optic nerve,

the recti and superior oblique muscles, which support or suspend it in the surrounding fat, and admit of its free and easy motions. It is small in comparison with the cavity which contains it. In some persons it appears more prominent than in others; the variety in this respect depends partly on the amount of adeps in the orbit, and partly on the size of the palpebral opening; it is also absolutely larger in some than in others. The eye is nearly spherical, and about one inch in diameter; but, in consequence of the slight projection of the cornea, which is a segment of a smaller sphere superadded to the larger one formed by the sclerotic, the antero-posterior axis is one or two lines longer than the transverse. A transverse section dividing it into an upper and lower half, or a vertical section dividing it into a right and left portion, will exhibit an oval outline; but a perpendicular section, cutting it into an anterior and posterior half, will exhibit the circular form. The long axes of the eyes are nearly parallel to each other, and, therefore, not so to that of each orbit. The eye is a hollow globe, the wall or shell of which is composed of different membranes or tunics, and the cavity is filled by transparent fluids or humours for optical purposes. The *coats* are three, the sclerotic, the choroid, and the retina; these fit accurately one within the other, and are in close apposition. The first is called sclerotic; it is a fibrous membrane for the protection and maintenance of the form of the organ; it invests the posterior four-fifths, and presents a circular opening in front, into which the transparent cornea is inserted, which completes the anterior fifth; the cornea and forepart of the sclerotic are also covered by the conjunctiva. Within the sclerotic is the second tunic, the choroid, extremely vascular, and containing the nutrient vessels and nerves; it also secretes the brown or black pigment, which deeply stains the interior of the globe and the back of the iris, to prevent the reflection of the rays of light from the bottom and sides of the organ back again through the retina. In the anterior part of this tunic there is also a circular opening or deficiency, into which the iris is fitted, as the cornea is into the sclerotic. External to the circumference of the iris the choroid is intimately attached to the sclerotic by the ciliary band or ligament; and internally and behind the iris it is connected to the membrane of the vitreous humour by a series of folds, called ciliary processes, arranged in a circular form around the margin of the crystalline lens. The third or innermost tunic is the retina, the delicate expansion of the optic nerve; this extends from the entrance of the nerve, at the back of the eye, all around the interior of the choroid membrane, and terminates in front about two lines behind the anterior border of the latter; this is the essential part of the organ, being endowed with sensibility to light; all the other parts may be considered as subordinate to it. The *humours* of the eye are the aqueous, the crystalline lens, and the vitreous; these, though of different densities, and enclosed in membraneous capsules, are all transparent, and exactly fill the globe. The aqueous fluid occupies the space between the cornea and the lens; the iris floats and moves in this fluid, and divides

the space into two chambers, the anterior and posterior. The anterior is between the cornea and iris, and the posterior between the iris and the lens and vitreous humour; this space is very small, and both communicate freely through the pupil, or the circular aperture in the centre of the iris. All the posterior region of the eye is filled by the vitreous humour, a soft, gelatinous, transparent mass, composed of the most delicate cellular membrane, the cells filled with fluid. In a depression on the forepart of this substance, and behind the pupil and iris, is placed the crystalline fluid or humour, of greater density than either of the other two, and of the form of a double convex lens. Each of the parts thus alluded to in a general way, may next be examined individually and minutely. The eye should be carefully removed from the orbit, and its surface cleanly dissected; the optic nerve and the tendinous insertions of the muscles may be retained.

*Fig. 73.**

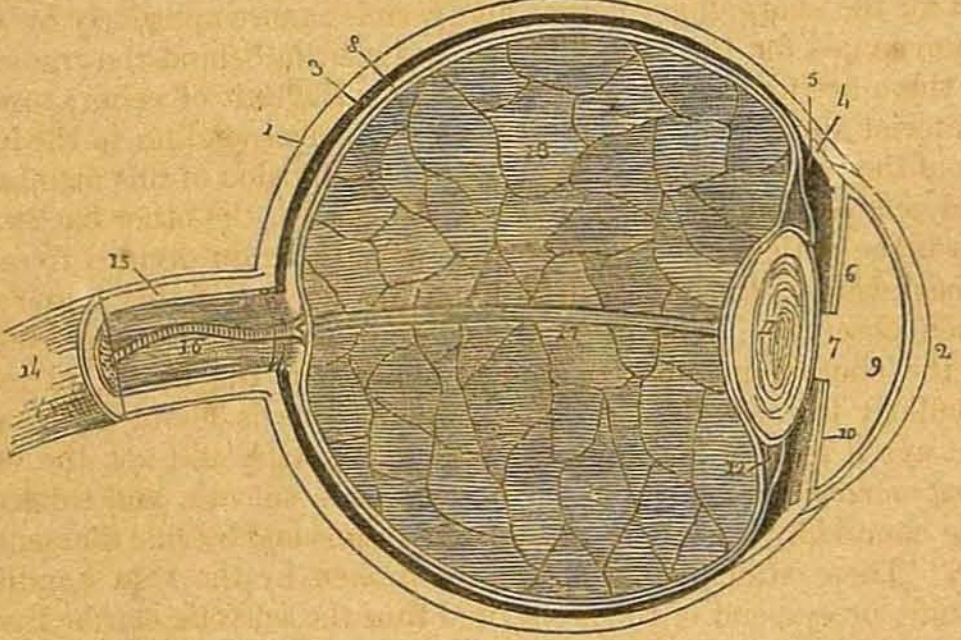

The *tunica sclerotica* (σκληρος, *durus*). This, together with the cornea in front, forms the external coat or case of the eye, and extends from the optic nerve to the circumference of the cornea; it is a dense, opaque, fibrous membrane, very strong and inelastic, preserving the figure of the organ, and protecting from injury and pressure the delicate structures within; it has been named by some "cornea opaca,"

* A longitudinal section of the globe of the eye. 1. The sclerotic or fibrous tunic. 2. The cornea. 3. The choroid or vascular tunic. 4. The ciliary ligament, containing the supposed canal of Fontana. 5. The ciliary processes. 6. The iris. 7. The pupil. 8. The retina or nervous coat. 9. The anterior chamber of the eye, containing the aqueous humour. 10. The posterior chamber. 11. The crystalline lens, enclosed in a fine capsule. 12. The canal of Petit. 13. The vitreous humour enclosed in the cells of the hyaloid membrane. 14. The optic nerve. 15. Its sheath or neurilemma. 16. The arteria centralis retinæ, a branch of the ophthalmic artery. 17. A branch of the central artery of the retina passing through the vitreous humour to the capsule of the lens.

χερατοειδης, χερας, *cornu*, ειδος, *similis*, but incorrectly, as it has no analogy in structure to the true cornea. It is covered posteriorly by cellular tissue, by the ocular fascia, and by the recti muscles; more anteriorly by the tendons of the obliqui and recti and by the conjunctiva, which externally is rather loosely connected to it by a fine cellular tissue prone to serous infiltration, but near the cornea is more intimately attached to it. The expansion of the recti tendons covered by the conjunctiva has been considered by some as a partial tunic to this region of the eye, and has been named "albuginea," or "adnata;" and to its peculiar tissue has been ascribed the white and glistening appearance of this portion of the organ, commonly called the "white of the eye." No such distinct tunic, however, exists; neither do the margins of the tendons unite, and the interstices present the same clearness and brightness of colour. The sclerotic membrane, if recent and cleanly dissected, is of a glistening, white, fibrous texture. Near the entrance of the optic nerve it is pierced by numerous small foramina for the short ciliary nerves and vessels; more anteriorly by small oblique canals for the long ciliary; and a little behind the transverse axis there are four or six larger canals for the exit of veins; towards its anterior surface small depressions exist corresponding to the insertions of the recti tendons. Make a circular division of this membrane, reflect one portion forwards towards the cornea, the other backwards towards the optic nerve; each portion may be again divided from before backwards; the inner surface and the density of this tissue may be then observed. The internal surface of the sclerotic is in contact with the choroid membrane, and is stained by the brown pigment, particularly towards the back part; and as this is found in the very recent eye it is most probably the permanent state, and not the effect of *post mortem* transudation. This surface is smooth, and connected to the choroid by the ciliary nerves and vessels and by fine filamentous tissue. These attachments are easily broken by the thin handle of the knife, or eye-end of the probe, and thus the sclerotic can be turned or peeled off the choroid without injury to the latter. When this inner surface is washed clean it presents a smooth and glossy appearance, and a very fine, serous-like lamina may be dissected from it. This lamina has been described by some as a true serous membrane, lining the sclerotic, and reflected from it anteriorly and posteriorly upon the choroid, forming a close serous cavity between the two. To produce this appearance, which is probably more artificial than natural, the ciliary vessels and nerves, and the cellular connexion between the two membranes, must be ruptured. This surface presents the several openings seen externally, also fine grooves in which the vessels and nerves run for some distance before they cross over to the choroid membrane. The divided edges of the sclerotic exhibit its density, which is greatest posteriorly near the optic nerve; thence it becomes gradually thinner towards the centre; in front of the transverse diameter, however, it receives the addition of the recti tendons; but the whole of the anterior portion is so thin that, in the child and in deli-

cate young persons, the black colour of the choroid appears through it, and gives to this part of the eye a peculiar dark or deep bluish tint. The superior thickness of the sclerotic posteriorly is more remarkable in many other animals, and more so in proportion as the eye deviates from the spherical form. In the ruminants, as ox and sheep, it is well seen, also in the horse, but little so in the elephant, as in it the eye is nearly globular; and it is most striking in the cetacea. The optic nerve perforates the sclerotic about a line and a half internal to the antero-posterior axis. As the nerve approaches this point it is suddenly constricted; its fibrous sheath of dura mater is intimately united to the sclerotic, and the contracted nerve passes through a small aperture in the membrane, which appears traversed by fibres, and has received the name of "lamina cribrosa," through the foramina of which the filaments of the nerve are supposed by some to pass in separate fasciculi, as those of the olfactory and auditory nerves pass through osseous cribriform plates. This mode of passage through the sclerotic, however, is by no means distinct, and this cribriform appearance may partly depend on the structure of the nerve itself and the vessels which accompany it. When the nerve is squeezed, the fibrous substance, no doubt, exudes on the concave surface in minute and distinct points, in the centre of which one appears much larger than the others, and is of a red or dark colour; this is named "porus opticus," and transmits the central artery of the retina. In like manner, if the nerve be divided behind this in any part of its course, and then squeezed, the medullary substance will exude in the same manner. If the nerve be shaved off from both surfaces parallel to the plane of the opening in the membrane, and the latter macerated for a little time, a thin membraneous tissue will be found to occupy the opening, and to be continuous with or connected to the margin, which is thin and not very accurately defined. Immediately around the opening the increased density of the sclerotic commences. In the anterior part of the sclerotic is the large opening, into which the transparent cornea is inserted, of nearly a circular form; the transverse axis is said to exceed the vertical from half a line to a line; the margins of the sclerotic are bevelled off obliquely, the outer lamina extending further than the inner; and between the edges there is a shallow groove or depression. Into this opening the cornea is fixed by several means of attachment, which dissection or maceration cannot open; rapid boiling assists but imperfectly. These two tissues, so completely opposed in physical properties and in structure, are yet most intimately united: first, as the conjunctiva extends from the sclerotic in front of the cornea it adheres almost inseparably to their border of conjunction, and assists in the latter; second, the outer layer of the sclerotic overlaps the cornea by so fine and thin an edge as not to cause the least projection; this overlaying is more considerable above and below than laterally, and hence the transverse diameter of the cornea appears to exceed the vertical; third, the inner or elastic lamina of the cornea, on the other hand, is prolonged behind the sclerotic, between it and the ciliary ligament; fourth, the circum-

ference of the proper laminated cornea is adherent to the groove in the sclerotic by strong fibrous tissue; the short, white fibres of the sclerotic appear engrained like the teeth of a suture into the plates of the cornea; and, lastly, the lining membrane of the cornea, which is continued to the ciliary ligament and iris, assists in the union of these parts. This apparently simple but truly complex structure is best seen by carrying a section through the cornea and forepart of the sclerotic, and then opening the line of union partly by dissection and partly by forcibly tearing the parts asunder. The sclerotic membrane is a true fibrous structure, and one of the strongest in the body; its fibres interlace in every direction, and no true division into laminæ can be effected by dissection or maceration; though perforated by vessels and nerves, it possesses but little organization or sensibility in the normal state; it receives some very small filaments from the ciliary nerves, and its arteries are derived posteriorly from the ciliary, and more anteriorly from the muscular branches of the ophthalmic; small branches from the latter also pass forwards, pierce the recti tendons, and converge towards the cornea, where they are too minute to follow or to inject; but in inflammation of the iris they become enlarged and distinct, and form the peculiar vascular pink zone, behind the junction of the cornea and sclerotic, so characteristic of that disease. The sclerotic, though insensible in its healthy state, yet when attacked with rheumatic inflammation, common to fibrous tissues, becomes the seat of intense pain; and when the globe is distended from suppuration or effusion, its dense and unyielding tissue considerably aggravates the sufferings of the patient.

Cornea (like horn) forms the anterior fifth of the globe, and completes the external case; it projects beyond the level of the sclerotic, being a small segment of a smaller sphere engrafted on the larger one formed by that membrane, and, though intimately united to it, is totally different in structure and organization; it is a perfectly transparent layer of animal tissue, convex and highly polished anteriorly, concave and smooth posteriorly; its form is circular, but very accurate measurement shews that its transverse diameter exceeds the vertical by nearly one line; and Haller asserts that its nasal side is circular, while its temporal is elliptical; its posterior surface is more accurately circular and more extended than its anterior, in consequence of the sclerotic overlapping the latter above and below more than on either side; it is rather thicker than the sclerotic, particularly in the child, and its circumference, being bevelled off externally and overlapped by the sclerotic, as was already described, is thinner than its central portion. Transverse or vertical sections of it from the eyes of the larger mammalia clearly exhibit a greater thickness in the centre but in fish it is the contrary. In the human eye the difference is not very considerable, but sufficient to shew that the two surfaces or curvatures are not precisely parallel; consequently, the cornea cannot be considered a simple meniscus, that is, a concavo-convex medium, with its two surfaces parallel, and, therefore, with its curves of equal diameter; but, being thicker in

the centre, it is also a lens with refracting and converging powers. A simple meniscus would merely transmit all rays of light falling parallel to its axis, as a transparent crystal; but experiment proves that the cornea has a magnifying power, and, as Haller has correctly stated, if removed from a recent eye, and held over the letters in a book, it magnifies them. Its refracting and converging powers may be further deduced from the fact that the optical powers of the eye are partly retained after the successful extraction or removal of the opaque crystalline lens, especially in young persons. The cornea, though perfectly diaphanous, is of a complex structure, and consists of different tissues:—First, it possesses a fine *epithelial lamina,* derived from the conjunctiva of the surrounding sclerotic. This has been already alluded to; it is exquisitely sensible, is composed of cells, the superficial orders are flat and smooth, the deeper are rounder and smaller; they contain a clear fluid, and, very soon after death, become white and opaque, and form the peculiar film upon the eye; when this has been wiped off the subjacent cornea is found clear. This change sometimes commences even before death, and the eye loses its lustre. Second, the peculiar or *proper cornea* consists of transparent laminæ, soft and flexible; their number is undetermined, depending in a great measure on the degree of maceration and the patience of the dissector. These are connected together by a fine, transparent, areolar tissue, which contains a small quantity of fluid, and maintains the laminæ in their proper relations to each other. A slight alteration in this respect will impair the transparency of the whole: thus, if the perfectly fresh eye of the sheep, suppose, be gently squeezed in the hand, the cornea becomes gradually milky, and as the pressure is removed the clearness returns. Maceration causes infiltration into this tissue, and thus renders the cornea opaque; but, if the lamellæ be then separated, they will still be found transparent: if boiled, however, or long suspended in spirit, they become permanently opaque. In the eye long dead, the cornea becomes flaccid, and loses a portion of its convexity, and the lamellæ glide on each other when pressed by the finger; this is probably owing partly to the transudation of the aqueous humour, as well as to changes in the areolar tissue between the laminæ; and, no doubt, on the healthy condition of the latter much of the plumpness and clearness of the cornea depend. Dulness of vision, caused by distension of the eye, or by pressure or injury, may partly depend on derangement of this tissue and altered relations between the corneal laminæ; it is this portion of the cornea that is so inseparably united to the sclerotic. When sections of the cornea are examined under the microscope, fine fibres are seen uniting the lamellæ, and the latter appear very thin and numerous, and present minute cells. Although at first view these plates bear some resemblance to chondrine or cartilage, they are most probably composed of a peculiar modification of fibro-cellular tissue. Third, posterior to the proper laminated cornea is a thin, but strong, elastic, cartilaginous lamina, named the *membrane of Demours;* it is perfectly transparent, and in close apposition with the cornea, between

it and the membrane of the aqueous humour. It appears homogeneous and hyaline. The eye of the horse, and also that of the elephant, present it in great perfection.* Its transparency is not affected by those agents which render the cornea opaque, and is retained for an interminable period when suspended in spirits. This lamina extends beyond the proper cornea, and fits in by a defined margin between the sclerotic and the ciliary ligament, as has been correctly noticed by Jacob, Med. Chir. Trans., vol. xii. p. 504. By this writer this lamina is named the elastic cornea; it bears a close analogy to the capsule of the crystalline lens, but is thicker and stronger; it serves to support the cornea, and to preserve its proper curvature. This lamina is easily exposed in an eye macerated for a few days; the cornea proper, which has become opaque, can be raised off, and the transparent elastic cornea left uninjured; it appears devoid of all vessels, although in iritis it becomes opaque; it must, however, be difficult to determine how far this appearance depends on an alteration in this tissue, or on the next that enters into the composition of the cornea, viz.:—Fourth, the membrane or *capsule of the aqueous humour*, a tissue of such exquisite delicacy that its demonstration on the back part of the cornea is extremely difficult, and its existence has long been inferred rather from analogy than from ocular proof. We shall allude to it again when examining the humours of the eye. The cornea, in its normal state, never admits red vessels, neither can nerves be satisfactorily traced into it; its surface, but not its substance, is exquisitely sensible; in disease, however, not only does the surface become vascular, but also its proper tissue; deposition of lymph occurs between its laminæ, causing various degrees of opacity. The process of ulceration in all its stages may be occasionally observed in it, and wounds heal by the first intention in a very short time. These facts indicate a high degree of organization. The cornea forms a strong and transparent window in the front of the eye, less liable to rupture or to yield under distention than the sclerotic; it also serves to transmit, and at the same time to refract or bend towards a focus, the rays of light. Being bright and highly polished, like a convex mirror, it also reflects a portion of the light which falls upon it, thus contributing to the brilliancy and expression of the eye; this reflected light also forms the images which we see behind the cornea in the eye of another.

Choroid coat is the second tunic in the eye-ball, and is so named from an imaginary resemblance to that vascular organ in the gravid uterus called chorion: it is a soft membrane, of a dark brown colour, extending from the optic nerve as far forwards as the ciliary ligament, which is internal to the line of junction between the cornea and sclerotic, and external to the iris. This ligament and the ciliary processes may be considered as appendages to it; it is pierced posteriorly by an annular foramen for the passage of the optic nerve, which has but little connexion to its border; anteriorly it presents a large opening, into which the iris is inserted, analogous to the circular deficiency

* *See* preparations in Museum.

in the sclerotic into which the cornea was received; it forms a sort of case between the sclerotic and retina, connected to the former by cellular tissue, vessels, and nerves, but merely lying in apposition with, and not adhering to, the smooth surface of the latter; it is extremely vascular and organized, and serves as the medium not only for connecting different parts of the organ, but also for conducting vessels and nerves to the interior, especially to the iris; and it also secretes the dark pigment so essential to the optical purposes of the eye. When successfully injected with a coloured fluid, it appears to equal in vascularity any of the mucous membranes, or the papillary surface of the cutis, which tissue it also resembles in presenting on its convex or adherent aspect a coarser or cellular texture, containing larger vessels, particularly veins and nerves. Internal to this is a most vascular lamina, composed of a beautiful net-work of capillaries, and on the inner concave surface of the latter a pigmentary secretion. The anatomist can actually divide it partially into these three lamina, and hence the choroid coat has been described by some as composed of three membranes, an external or venous, a middle or arterial, also called Ruyschiana (from Ruysch, who, by his beautiful injections, attracted great attention to it), and an internal or pigmentary. Such divisions, however, are useless, and merely artificial; it is but one membrane, highly organized and vascular, externally rough and cellular for connexion to the sclerotic, and containing the larger vessels and nerves; as these enter into the tissue they subdivide minutely before they reach the inner or more vascular and villous surface. The veins on the outer surface are remarkable for their size and peculiar arrangement, and have been named "vasa vorticosa." Four or six considerable veins may be observed about the middle of this surface; numerous small vessels run in clusters towards each of these, at first from behind forwards, then bend round in gentle curves, compared to the branches of the weeping willow; these are joined by small vessels from the fore-part, and unite in the larger trunks; these then pass from the choroid into the external cellular tissue, pierce the sclerotic obliquely, and make their way to the ophthalmic vein. In a recent eye these veins are sometimes beautifully distinct, being injected with blood, which becomes reddened by exposure to the air. On the surface of the choroid the ciliary nerves and arteries are also seen; of the latter a great number penetrate into its tissue, a little distance from the optic nerve; the long ciliary arteries pass on undivided, in company with the ciliary nerves, as far as the ciliary ligament, through which they pass in their course to the iris; to the latter organ the nerves are chiefly destined, but most probably small filaments also accompany the arteries of the choroid membrane. This external lamina of the choroid is very intimately connected to the ciliary ligament; the sclerotic coat can be easily detached from the choroid, except near the optic nerve. When removed, this surface of the choroid presents a smooth, glistening appearance, like a serous membrane; and we have already stated that some suppose a fine serous sac to exist between these two coats, one lamina lining the sclerotic, the other investing the choroid; this appear-

ance, however, rather depends on the fine and serous character of the connecting areolar tissue, which, when divided during the separation of the coats, presents a smooth, shining surface on each. The dissector may now easily detach patches of this external or venous lamina of the choroid membrane, particularly posteriorly. The choroid membrane should next be divided circularly about half-way round the eye, also from before backwards, and the angles carefully turned off the retina; a gentle stream of water will wash off the internal pigment, and the inner surface of the membrane will be exposed. If the head have been minutely injected, either veins or arteries, the vascularity of this surface, called "Membrana Ruyschiana," will be very conspicuous, or when suspended as a preparation. When viewed with a lens, the surface appears villous and the vessels extremely minute, forming a fine capillary net-work, without any peculiar arrangement of veins, as upon the outer surface. When the whole of this membrane is separated from the retina, and one part thrown backwards, the other forwards, we see in the concavity of the former the free circular aperture for the optic nerve; but anteriorly, as it approaches the ciliary ligament, to which its external lamina is closely attached, we perceive its concave surface presenting small folds or plicæ, which are the commencements of the ciliary processes, to be described presently. If the sclerotic and choroid be separated in a recent eye, and the latter also partially detached from the retina, the pigment will attract attention. In man this is of a dark brown colour, but in most animals it is a deep black; the interior of the sclerotic is stained by it, but not the retina; it seems to pervade the entire of the choroid, but coats it more thickly internally, and is thicker and of a deeper colour posteriorly and anteriorly than laterally; it is not confined to the choroid, but abounds on the back part of the iris and on the surface of the ciliary circle. In many animals also there is a black rim of it around the cornea, and in the border of the nictitating eye-lid; also in the marsupium in the bird, and in other detached situations. It is of a deeper colour in the child, but does not stain the sclerotic so much as in the adult; it is less in quantity, and of a paler colour, in the old. Its tint differs in different individuals, and probably bears some proportion to the general complexion; in some, as albinoes, it is altogether absent, and vision is defective in consequence. If the recent choroid be agitated in water, the pigment does not render the fluid turbid, and is not detached, and sometimes can be peeled off in small pieces; but after a few days' maceration, or when decomposition has set in, it mingles with the water, and can be washed off, leaving the choroid, if uninjected, of a grey or whitish colour; this is probably owing to the pigment being enclosed in fine cells, which do not rupture for some time after death. Some consider the pigmentary layer of the choroid as a distinct organized membrane (*see* a Paper by Wharton Jones, Edinb. Med. and Surg. Jour., July, 1833), composed of hexagonal plates disposed in regular mosaic order; in these the pigmentary particles are deposited, and even if the pigment be absent the membrane will still exist. The fact, however, of its being deposited in so many situations, and so variably in some animals, would indi-

cate that the vessels in any part of the orbital region, even in the sheath of the optic nerve, may separate the pigmentary cells without the intervention of a distinctly organized membrane. Dalrymple (Anat. of the Eye, p. 96) describes a fine serous lamina as covering the inner surface of the pigment, a continuation or reflection of the external tunic of the retina, or the membrane of Jacob. Henle gives a full account of the microscopical appearances of these pigmentary cells, and the history of the various opinions entertained as to their anatomical structure and development (which *see*, Anatom. Gen., p. 300). This peculiar animal secretion is designed to darken the interior of the eye in the same manner as the inside of the microscope and telescope is blackened, to absorb the rays of light, and to prevent their being reflected back again to the retina; it also renders the forepart of the sclerotic and all the iris opaque, and thereby obstructs the light entering through any part of the globe except through the pupil.

In many animals, as the sheep, ox, horse, and in most of the carnivora, the pigment is not apparent at the bottom of the eye, and the choroid presents a beautiful bronze or metallic lustre of various tints, green, blue, yellow, and white; this appearance is named *tapetum;* it occupies nearly one-fifth of the eye, commencing at the outer side of the optic nerve, and extending forwards to an irregular distance, and terminating by an undefined edge: but little of it appears on the nasal side of the globe, the pigment overlaps its border, and sometimes to an irregular extent, and more in the young than in the adult animal, as I find in comparing it in the lamb and sheep; it is not so brilliant in the pig as in the horse; in the elephant it exists, but is very much concealed by the pigment. The tapetum resembles the brilliant metallic tint of some nacreous shells, and the colours probably depend, not on any colouring principle, but on some peculiar arrangement in the structure or surface of the inner lamina of the choroid, whereby the rays of light are decomposed, some colours absorbed, and others reflected, in the same manner as Sir D. Brewster has shewn (Phil. Trans., 1814, p. 397) that the iridescent colours in mother of pearl depend on the parallel grooves in the structure, and can be transferred to any material taking an accurate cast of the surface. On removing the tapetum, in the sheep, I find the black pigmentary membrane is perfect behind it.

Ciliary ligament is a soft, spongy, fibro-cellular annular band, of a greyish white colour, about a line and a half broad, not stained by pigment, situated on the anterior and external borders of the choroid membrane, and intimately adhering to and continuous with its external lamina, internal to the line of junction of the cornea and sclerotic, to which also it adheres, and external to the circumference of the iris, which is inserted into it; while from its internal and posterior aspect are continued the ciliary processes or folds of the choroid membrane, which are attached to the back part of the iris and to the forepart of the vitreous humour. It thus serves as a common central medium to connect these several tissues, and to fix them steadily in their relative

situations; it strengthens the attachment between the cornea and sclerotic, and confines the latter so closely to the choroid that the aqueous fluid cannot possibly penetrate between them; its white colour forms a striking contrast to the black ground of the choroid and to the variegated tint of the iris. In the minutely-injected eye it is not coloured, but the ciliary arteries from behind, and small branches which pierce the sclerotic in front, perforate it in their course to the iris; the ciliary nerves also enter it, subdivide in it, and can be traced through it into the iris. From the connexion of these nerves to it, it was regarded by Soemerring and others, but incorrectly, as a nervous ganglion. Its use appears to be principally mechanical, and there is no proof to support the different opinions that have been entertained by different writers as to its glandular, muscular, tendinous, or nervous structure. A small circular canal has been described in it by Fontana; this appearance most probably arises from a circular blood-vessel or inosculation.

Ciliary processes, or corpus ciliare, are delicate folds or plaits of the choroid membrane extending from within the ciliary ligament to the back part of the iris, and thence along the forepart of the vitreous humour to near the circumference of the crystalline lens. These may be exposed either anteriorly by removing the cornea and one-half of the iris, or from behind by making a transverse section of the globe; and, looking forwards through the transparent vitreous humour, the student should examine them in both these aspects, also in different sections of eyes preserved for a few days in spirits; they are small, triangular processes, between sixty and seventy in number, from a line to two lines in length, and alternately long and short; each process is a fold or plait of the inner layer of the choroid, arising small and narrow; advancing forwards it increases in size, and is attached by its anterior extremity to the back part of the iris or uvea, while its internal border extends inwards in front of and depressed into the hyaloid capsule of the vitreous humour, around and at a little distance from the circumference of the lens; between each pair of processes, thus attached to the hyaloid membrane, a similar process from the latter extends, and is intimately attached to them, the one being dovetailed between two others. The entire series resembles the disc of a radiated flower, placed behind the iris and partly connected to it, its external circumference attached to the ciliary ligament, its internal or lesser circle surrounding the lens, and presenting the fringed points or processes, between which are the corresponding folds of the hyaloid membrane; these complete the posterior wall of the posterior aqueous chamber, and are separated by its fluid from the iris. If these processes or rays be considered as each of a triangular form, their apices or loose points will form the lesser or inner circumference; their posterior and inner borders rest in the hyaloid membrane; their anterior borders correspond to the aqueous fluid internally, and to the iris externally, and the plicated root of each from the choroid may be regarded as its base. The surface of all these processes, as well as of those of the hyaloid membrane, are deeply tinged with pigment; if this be washed off, they are of a

greyish colour, and their surface is villous and highly vascular; when minutely injected they resemble the choroid tissue, with which they are continuous. The extremities of the processes do not touch the border of the crystalline capsule: in the very recent eye a small, clear circle of the hyaloid and vitreous humour, surrounds the latter between it and the ciliary body. If the choroid and its ciliary processes be removed from the forepart of the hyaloid membrane, the depressions which they occupied are perfectly free from pigment; but there still remains another dark and radiated disc, formed by the projecting processes of the hyaloid membrane which were inserted between those of the choroid; the points of these processes are directed outwards, the reverse of the former. Different opinions have been entertained by different writers as to the nature and office of the ciliary processes; some have supposed them to be muscular, and capable of effecting focal changes in the eye; others that they are of an erectile, venous tissue, and concerned in the motions of the iris. Ribes considers them as the secreting agents of the aqueous humour. There is little doubt, however, that they are essentially vascular, and serve to secrete the black pigment in a situation where it is much required; they must also strengthen the connexion between the choroid, the iris, and the hyaloid membrane, and thus complete the boundary of the posterior chamber of the eye.

Iris is the circular, vertical partition seen behind the cornea and in front of the lens, dividing the intervening space which contains the aqueous humour into two chambers, an anterior and posterior; it floats and can move freely in this medium, and the two chambers, which it partly separates, communicate with one another through its central aperture, named the *pupil.* This opening is a little nearer the nasal than the temporal side of the iris, which is consequently broader on the latter aspect than on the former. The pupillary opening is circular in man, but is oblong transversely or vertically in many of the lower animals; in some, also, delicate fringed processes float from its edge; its size varies according to the distance of the object in view, also according to the sensibility of the retina, and, above all, according to the intensity of the light admitted into the eye. When the object of vision is very near, the retina very sensible, and the light strong or bright, it is contracted; under opposite circumstances it is enlarged; these changes occur with great rapidity, and there is also good reason for believing that volition can influence them. The external border or circumference is inserted into the ciliary ligament, or rather between it and the ciliary processes, and corresponds to the junction of the cornea with the sclerotic. The anterior surface is flat, though in dissection it appears a little convex as it falls unsupported upon the lens. This surface presents the well-known varieties as to colour, dark brown, hazel, grey, blue; hence its name, iris or rainbow. The shade towards the pupillary margin often differs from that of the general surface in being much darker; these shades probably depend, partly on its variable density and the black pigment on the back of it par-

tially appearing through it, and partly on irregularities on its surface decomposing the light and reflecting certain coloured rays and absorbing others: its vascularity, also, may have some effect. There is often a correspondence between its colour and that of the hair and complexion: in most fish it presents a metallic lustre. The posterior surface is coated with a thick lamina of dark pigment, and, from a fancied resemblance to the ripe purple grape, has been named *uvea*. The iris is highly organized, receives its blood posteriorly from the long ciliary arteries, and anteriorly from the ophthalmic. The long ciliary have been already seen, between the sclerotic and choroid membranes, proceeding forwards, one on the nasal, the other on the temporal side, parallel to the equator oculi. Having arrived at the circumference of the iris, each divides into two diverging branches; these form a circular inosculation, which is joined by the anterior branches from the muscular arteries of the ophthalmic, and from this are derived numerous branches which converge into the iris, and again inosculate; and, finally, minute tortuous capillaries radiate inwards to the pupillary margin. In a minutely-injected eye the iris is found to be very vascular, but is seldom equal to the choroid membrane or ciliary processes: its veins return the blood either into the vasa vorticosa or into some of the ciliary. The nerves of the iris are derived from the ophthalmic ganglion, that is, from the nasal branch of the ophthalmic or sentient division of the fifth, and from the third, the chief motor nerve in the orbit; the former is also connected with filaments of the sympathetic, which latter communicate with the orbital plexus. The ciliary nerves, about twelve or fourteen in number, are seen to pass through oblique canals in the sclerotic, and then to proceed forwards on the surface of the choroid, with the dark colour of which they form a striking contrast; and in the ciliary ligament they divide into small branches, which become soft and indistinct, and disappear in the iris. To examine the structure of this organ it may be removed from the eye: it is thicker and stronger than the choroid membrane; its anterior surface presents a very irregular appearance, as is well seen in the living eye, projecting lines, with intervening depressions, interrupted by slight projections; these lines mostly radiate from near the pupillary margin towards the circumference; some are straight, others tortuous; some interlace and bifurcate, and others appear to stop in small projections. When the pupil is contracted these lines are more distinct and straight, but when dilated they appear more tortuous and interlaced. This structure is now very generally considered muscular, and is compared by Jacob (Med. Chirurg. Trans., vol. xii.) to the carneæ columnæ and chordæ tendineæ in the heart. Some, however, have contended that this surface is villous, and that the lines and striæ just mentioned are radiating vessels and elastic fibres; their appearance, however, bears no resemblance to arteries, either in size, colour, or inosculation. The border of the pupil is surrounded by a narrow circle of fibres, which can be better seen on the posterior surface; these are also considered muscular, and have been named the con-

strictor or sphincter iridis (Cloquet). It is to be presumed that the anterior surface of the iris is covered by the fine membrane or capsule of the aqueous humour, although it cannot be distinctly demonstrated. The posterior surface, or uvea, is of an uniform deep brown or black tint; when recent, the pigment does not stain the finger, being covered and retained in this situation by the fine membrane of the aqueous humour; when this and the pigment are removed and washed off, the back of the iris is of a greyish colour, and presents a number of minute plicæ, or lines converging towards the centre; the pigment adhered to these folds and depressions. Around the pupil the circular ring is more obvious than in front; into this the anterior radiated fibres are interwoven in a manner analogous to that in which the muscles of the face are interwoven with the orbicularis oris (Dalrymple, p. 50). This twofold order of muscular fibres, supplied by compound nerves, appears fully adequate to explain the functions of the iris. When required to contract, the sphincter fibres close the pupil almost to a point; when enlargement is necessary the sphincter relaxes, and the external or radiated fibres act, and enlarge the opening to the necessary extent; and thus the great design of the iris and pupil is effected, namely, to regulate the quantity of light to be admitted: the pigment on its posterior surface prevents the transmission of any rays external to the pupil. The iris may also assist in the correction of spherical aberration, by the contraction of the pupil excluding all the circumferential rays; and some also have considered it capable of acting, through the ciliary processes, on the hyaloid membrane and lens, so as to adapt the eye to vision at different distances.

During the greater part of uterine life the pupil of the fœtus is closed by a delicate membrane, *membrana pupillaris;* it is most distinct about the fifth month, and is found to consist of two thin membranes, extended from the surfaces of the iris and separating the anterior from the posterior chamber. These membranes are transparent in the centre; but on either side are seen, in an injected preparation, small vessels forming arches or loops; those of opposite sides are said not to anastomose, but from a preparation now before me I consider this assertion very doubtful. It has been also stated that these membranes give way towards the centre about the seventh month, and that the rupture is caused by the retraction of the vascular arches. This description, however, has been rendered more than doubtful by the researches of Jacob (Med. Chir. Trans., *loc. cit.*), and more lately by others, who have proved that the rupture does not occur until near birth, and sometimes not for some time subsequent to it; and that it gives way not by a rent or fissure, owing to the retraction of the vascular loops, but that it gradually loses its vascularity, becomes thin and delicate, and is finally absorbed, often leaving ragged remnants on the margin of the pupil. The membrana pupillaris may be considered as formed by the apposition of the two fine serous sacs which line the two chambers of the eye, one in front of the iris, the other behind it; the vessels of the iris extend between these membranes towards the centre,

and are arranged in the peculiar loops or arches already noticed, those of opposite sides occasionally, but probably not constantly or normally, inosculating with each other. As the iris increases in size and thickness by the process of nutrition, the vascular loops become more closely connected to it, the central partition becomes thin, atrophied, and absorbed, and finally is opened, the remnants soon disappearing, and the two chambers of the eye then permanently communicate through the pupil. Cases have been recorded where this atrophy has not taken place, and where blindness has been the result of a permanent membrana pupillaris. The state of this particular tissue, or the change it undergoes, has not yet been fully examined in other animals.

Retina is the third or innermost, or the nervous tunic of the eye, and in immediate contact with the vitreous humour which distends the posterior part of the globe; it is concentric to, but of less extent than the sclerotic or choroid; it is the most important and interesting constituent in the organ, as it alone is sensible to the impression of light. During life, and for a few hours after death, it is transparent, but soon becomes opaque and milky; it is an extremely thin and delicate tissue, and care and experience are required in the dissection necessary to expose it. Gently tear off the choroid membrane, the eye being secured under water on a plate of glass, and then place an inverted glass globe, filled with clear diluted spirits, over the dissection, which becomes magnified, and the retina presents a semi-opaque, whitish appearance, not unlike ground glass; it is the expansion of the optic nerve into a membrane forming a portion of a sphere, and extended between the choroid coat and the vitreous humour, accurately fitting between these and adhering to the capsule of the latter; the optic nerve pierces the posterior part of the globe, or of the two preceding tunics, about a line and a half internal to the centre, or to the antero-posterior axis, and then expands into this delicate, semi-transparent tissue, composed of membraneous, vascular, and nervous tissue, which extends as far forwards as the posterior extremities of the ciliary processes, and about the eighth of an inch behind the ciliary ligament, and ends in a defined, serrated, or undulating margin, corresponding to that of the ciliary body. The concave surface of the retina may be exposed by making a transverse division of the globe in front of its centre, and removing the lens and vitreous humour; the optic nerve will be then seen at the bottom of the eye as a circular spot, in the centre of which is a dark point, "porus opticus;" through this the small artery, named "centralis retinæ," passes; this immediately divides into diverging branches, which ramify on the internal or vascular layer of the retina, and can be traced as far as its anterior border, where they form a circular inosculation, and probably communicate with the vessels in the ciliary processes. In the very recent human eye, or in those of large animals, these vessels are often beautifully injected with red blood; the centralis retinæ also gives off one delicate branch posteriorly, which passes forwards through the centre of the vitreous humour, and reaches the back part of the capsule of the lens. This branch can be seen in

the eye of the ruminant when very recent; it can also be injected i[n] the human fœtus. The central artery of the retina not only supplies this membrano-nervous expansion, but must also nourish the hyaloid capsule of the vitreous humour; the latter, also, most probably receives an additional supply anteriorly from the vessels of the ciliary processes. As the optic nerve spreads out into the retina, the medullary fibres or fasciculi, diverging and expanding, are at first very evident in the eyes of some animals, as the ox, hare, and rabbit, and, as I have lately seen, in the elephant; but in the human eye the fasciculi are not distinct, a few radiating lines only can be observed in the very recent state; one such line may be observed leading outwards from the entrance of the nerve to a point about a line and a half distant, which exactly corresponds to the axis of the eye; at this point there is a small circular or oval spot, with a dark centre and a yellowish border. This was first noticed by Soemerring, and has since been named the *foramen*, or *spot of Soemerring*, *aureum punctum*, &c. It has been observed in the human eye, and in that of the quadrumana, that is, according to Cruveilhier, in those animals whose visual axes are parallel; but it has been also found in some reptiles, to which this observation cannot apply; it is not seen in the horse, ox, or other mammalia, nor in birds or fish; it is faint in the child and in old age, deeper in youth and middle life: it is well marked in those who have died suddenly between twenty and thirty years of age. We have seen it beautifully distinct in the eyes of some young men executed in Dublin some years since. Soemerring considered this spot as a perfect foramen, or deficiency in the retina; minute examination, however, shews that there is no actual hole or interruption in the tissue; and when the retina has been carefully dissected and suspended in a clear fluid, although in the course of a few days the spot disappears, yet there is no opening or deficiency, nor indeed any peculiar appearance, observable in the situation it occupied, whether viewed on the concave or convex surface: most probably it depends on slight folds or projections, with an intervening depression at that particular point, and which are gradually effaced; there may also, perhaps, be some peculiar vascularity or organization in that situation, which, however, has not yet been ascertained. Sir E. Home fancied that an absorbent vessel passed through it.

Although the retina at first view appears a homogeneous, soft, and delicate pulpy nervous expansion, it is found to consist of three tissues, each differing in texture and function; it was long considered as composed of two laminæ, an internal vascular, and an external nervous. In the year 1819, however, Dr. Jacob discovered the existence of a fine membrane, of a serous or sero-cellular nature, external to the nervous: an account of this was first published in the Philosophical Trans. (1819), and has been reprinted in Todd's Encyclop. of Anat. (art. "Eye," p. 186). This lamina, now named *tunica serosa*, or Jacobi, is the external layer of the retina; it supports the nervous tissue on that aspect, and separates it from the pigmentary surface of the

choroid. The internal lamina of the retina is a fine vascular membrane, essentially composed of the minute capillaries of the arteria centralis; this supports the nervous matter on its internal or concave aspect, and separates, but at the same time connects it in its proper expanded form to the convexity of the vitreous humour. The first, or the *lamina serosa*, is an extremely delicate and soft tissue, but is now recognized by most anatomists as a perfect membrane. Cruveilhier states he has not been able to demonstrate it; it, however, no less exists; but to exhibit it, the directions of its discoverer must be followed: "Place the recent eye under water, fastening it to a piece of wax attached to the bottom of the vessel, having first removed the posterior half of the sclerotic; then, with a pair of forceps in each hand, gently tear and turn down the choroid; instead of the blue, white, reticulated surface of the retina, the eye now perceives a villous surface, more or less tinged with pigment; press the handle of the knife gently against this surface, so as to make a breach in it, and a very delicate membrane may be separated, and thrown in folds over the choroid, or a blunt probe may be introduced between it and the nervous layer, remaining loose over the latter; a particle of air or paper, or a few globules of quicksilver, may be introduced beneath it, and thus render evident its membraneous nature, leaving the retina uninjured." It extends from the optic nerve to the ciliary processes, is firmer in the adult than in the child, and adheres more closely to the pigment; it is connected to the choroid by fine cellular tissue and vessels, but is more intimately attached to the retina. Mr. Dalrymple considers this membrane as a perfect serous sac, one lamina adhering to the retina, the other to the choroid membrane, and reflected from one to the other at the ciliary circle anteriorly, and at the entrance of the optic nerve posteriorly (p. 100). The internal or *vascular layer* of the retina may be considered as analogous in function to the pia mater on the brain, but is so fine and delicate that it is extremely difficult, indeed impossible, to demonstrate it as one continuous structure; it adheres externally to the nervous lamina, and internally to the hyaloid membrane. If the vitreous humour, with the retina, be allowed to remain in water some days, the nervous matter may be gently rubbed off, and this vascular layer or tissue may then be gradually and partially separated from the hyaloid capsule, and left suspended from the optic nerve. When uninjected it is perfectly transparent; it is essentially composed of the capillary ramifications of the centralis artery and vein. The *middle layer* of the retina is the expanded medullary or fibrous substance of the optic nerve; a fibrous arrangement or structure is not obvious. Treviranus, however, has described it as consisting of cylindrical fibres or tubes of unequal length, which, proceeding from the optic nerve in all directions, bend obliquely inwards through the vascular layer, and each terminates in the form of a papilla on the vitreous humour. Different opinions have been entertained as to the extent of the retina anteriorly; the nervous layer obviously ends in an undulating border at the commencement of

the ciliary processes, about a quarter of an inch external to the border of the lens, while the vascular or inner layer appears intimately attached to the hyaloid membrane and ciliary processes. Many, however, have described this layer as continued to, and in front of the capsule of the lens; the connexion, however, between the choroid and hyaloid ciliary processes must prevent any such extension.

The several tunics that have been described form the parietes of the eye-ball, but its cavity is occupied and distended by substances of a totally different character, the humours, or the dioptric or refracting media, three in number, each differing from the other in quantity, consistence, and refractive power, but all equally transparent; they are the aqueous, the crystalline, and the vitreous, and are placed in that order between the transparent cornea and the optic nerve.

Aqueous humour occupies the space between the cornea and the lens, is perfectly colourless, and consists of a fine secreting membrane or capsule and the secreted fluid; the latter is transparent, about five grains in amount; in specific gravity and other properties it differs but little from water; 100 parts contain about 98 of water, the remaining are chloride of sodium and a minute portion of albumen. The *membrane* of this humour is one of the most delicate textures in the organ, and its existence in some situations is rather inferred from analogy than proved by actual observation; it secretes and retains this fluid, and forms the parietes of the space it occupies; this space is divided by the iris, which floats in this fluid, into two chambers. The *anterior* is bounded by the concave surface of the cornea in front, and by the flat surface of the iris behind. The *posterior* is much smaller, and of a more irregular form; the iris bounds it anteriorly; posteriorly it is bounded by the lens, with its capsule in the centre; external to this by the hyaloid membrane, forming a very narrow, but clear circle around the lens; and more externally by the extremities of the ciliary processes: the circumference is formed by the ciliary processes extending from the vitreous humour to the back of the iris. These two spaces, of which the anterior is much the larger, communicate freely through the pupil. The membrane or capsule of this fluid lines the cornea, is thence continued over the front of the iris and around the pupillary margin to its back part, where it can be distinctly raised off from the uvea; thence it passes over the ciliary processes, the hyaloid membrane, and the forepart of the crystalline capsule.

Crystalline humour is a transparent double convex lens, the posterior convexity greater than the anterior; the former forms part of a circle of four or five lines diameter, the latter of one from seven to eight lines. These relative proportions, however, are by no means regular; neither is it possible to obtain accurate measurement of its curves, as its surface is soft and semifluid, and must undergo some change in the process of removal. In the fœtus it is more spherical; in youth and middle age the anterior and posterior convexities are more considerable, but these decrease in old age. The lens is imbedded in the forepart of the vitreous humour, at the junction of the three posterior with

the anterior fourth of the eye-ball, and a little nearer to its nasal than to its temporal side. Its axis corresponds to that of the pupil; it is retained in its situation by the connexion between its capsule and the hyaloid or vitreous membrane posteriorly and circularly, and by the membrane of the aqueous humour, which passes over it, anteriorly. The crystalline humour, like the other humours, consists of a capsule and the contained substance; with this difference, however, that both the aqueous and vitreous fluids are secreted by their investing and containing membranes, and are not themselves organized; but the lens is of much greater consistence, and presents a complex structure, and, no doubt, possesses the requisite degree of organization. The *capsule* is eminently transparent, but dense and elastic, not unlike the posterior layer of the cornea; its transparency is not affected by boiling or immersion in alcohol, and, although the lens has been rendered opaque thereby, yet the thin, transparent capsule may then be separated. This elastic capsule must serve to preserve the form of the lens, just as the posterior layer of the cornea preserves the curvature of that tissue; and as we conclude from analogy that the latter is lined by the aqueous membrane, so we infer that the forepart of this capsule is covered by the same. This capsule is connected posteriorly by a fine, areolar, and vascular tissue to the hyaloid membrane. In finely injected preparations the central artery of the vitreous humour may be seen to ramify on its back, and probably fine vessels from the ciliary processes extend to it laterally and anteriorly. The organization of the capsule may also be inferred from disease; it not unfrequently becomes opaque, and constitutes capsular cataract. On opening the anterior part of the capsule in the eye long dead, a small quantity of fluid escapes; this has been generally named "liquor Morgagni," and has been considered by many as constantly interposed between the lens and its capsule. It is much more probable, however, that the presence of this fluid is a *post mortem* occurrence, because it is not found in the eyes of the larger animals when recent; indeed, in the eyes of sheep and oxen, from which I had removed the cornea, and of course the aqueous humour, I have not found any aqua Morgagni at the end of a week; neither is it present in the human eye, if examined a few hours after death. Were any such fluid naturally and constantly present, it must insulate the lens from its capsule, so that the former should be regarded as an inorganic mass, enclosed in the capsule, like the aqueous humour. This, however, is not only improbable, but is opposed by the fact that, if a recent eye be carefully examined, without bruising or injuring it, the cornea and iris removed, the capsule freely opened anteriorly, the lens may be pressed with a probe or handle of the knife with some degree of force before it is dislocated; or, if the eye be suspended by the nerve, the lens will not fall out of the open capsule. This connexion is certainly more conspicuous posteriorly and circularly than anteriorly; there can be no doubt that this connexion is of an organized nature, and thereby the lens itself receives its nutrient vessels and nerves. When the *lens* is separated from its capsule, it is found

to be perfectly transparent; it sinks in water slowly, as its specific gravity exceeds it but little; its weight has been stated at four grains, its diameter about four lines, and its axis about two: its circumference is not circular, but a little elliptical. It has been already stated that its form, as well as its density, vary at different ages; these also, no doubt, vary in different individuals of the same age, which may partly account for the different power of vision enjoyed by some compared with others, deficient convexity producing presbyopia, and an excess of it causing myopia. In the fœtus it is often of a reddish or pinkish tint; in the adult it is perfectly clear; and in the old it is often of an amber or light brownish hue. The density of the lens is obviously less upon the surface than towards the centre, and this difference is more marked in the old than in the young; the centre is firm and consistent, like a piece of gum arabic, and is named the nucleus. From this to the circumference the consistence diminishes, and the surface is semifluid, but the whole is more dense than either of the other two humours. According to Berzelius, the lens consists of water, 58.0; peculiar matter, 35.9; hydro-chlorates, lactates, and animal matter, soluble in alcohol, 2.4; animal matter, soluble in water, 1.3; insoluble membraneous matter, 2.4. Chenevix states that it contains both gelatine and albumen, and, when reduced by heat to ashes, distinct traces of iron are found; there is no trace of fibrine. That the lens is not a simple, homogeneous mass, but a very compound or complex structure, is obvious from examination. What this precise structure is, is not perfectly ascertained, and various opinions have been entertained upon the subject. When boiled, it can be separated into concentric layers, of which the external are soft; the internal increase in hardness to the central nucleus. These laminæ appear to be composed of parallel fibres, united to each other by indented margins: during the separation of these lamellæ the whole will part under moderate pressure into three triangular or cuneiform segments, their bases towards the circumference, their apices towards the centre. Simple maceration in cold water for two days will cause the lens to become opaque and fissured, and by degrees it expands into a soft, laminated, and fibrous tissue. The laminæ of fibres are wonderfully thin, and have been differently described as to the order in which they are arranged. Sir D. Brewster has described their appearance with great accuracy, and has observed a difference in their arrangement in different animals. In man the structure is the most complex: the three septa diverge from each pole, the septa of the posterior surface bisecting the angles formed by the septa of the anterior surface. These fibres, under the microscope, appear united by a series of fine teeth, those of one fibre locking into those of another. The minute structure of this organ, according to this author, cannot be well understood without reference to his illustrations, and the limits of this work do not permit of more extended remarks upon a subject which cannot be well pursued in the ordinary practical course of study in the dissecting-room. I, therefore, refer the reader to his paper, Phil. Trans., 1833.

The *use* of the crystalline lens is well established.

Vitreous humour, or *hyaloid body*, fills the posterior three-fourths of the globe, and is in contact with the whole of the inner surface of the retina, which it supports in its expanded form; anteriorly and centrally the lens is imbedded in it, and more externally the ciliary processes are attached to it; it is, therefore, of a spheroidal form, truncated in front. In the adult it is perfectly transparent, but in the fœtus has a rosy tint; it is gelatinous or semifluid, and of a medium degree of consistence, and therefore, of refractive power, between the aqueous and crystalline humours. It consists of a fine, transparent, membraneous capsule and areolar tissue, secreting and enclosing a fluid like water. The membrane is named, from its transparency, *hyaloid capsule* (*υαλος*); it not only encloses the humour, but also sends inwards numerous processes, which join each other, and form a fine areolar or cellular tissue, in the interstices of which the fluid is confined; thus the vitreous differs essentially from the aqueous fluid, the latter being contained in one capsule, the former in numerous cells which communicate with each other. If the hyaloid membrane be punctured and suspended, the fluid escapes drop by drop, and the whole will be gradually discharged; if a blow-pipe be then introduced into it, the membrane may be inflated and dried, and its cellular texture will become evident. Immersion in alcohol or acid will render the membrane opaque, and thus also display the numerous internal septa. It is said that freezing the mass affords an opportunity not only of distinguishing the membraneous cells from the congealed fluid, but also of ascertaining the precise figure of the former. My own experience, however, does not confirm that assertion; in the frozen mass I have not been able to distinguish any difference in structure, or any peculiar arrangement of parts. The *vitreous fluid*, when collected separate from the membrane, differs in no essential respect from the aqueous, being composed of water and about two per cent. of animal and saline matter. The vitreous body is traversed by a small artery from the centralis retinæ, which proceeds in a tortuous course from behind, and is lost on the back of the capsule of the lens; it only transmits the colourless parts of the blood, and, though principally destined to the lens, it most probably assists in the nourishment of the hyaloid membrane. The vascular layer of the retinæ, which is attached all around its convex surface, also sends into it vessels, and, most probably, nerves; and anteriorly the ciliary processes of the choroid assist in the same object. Into the depression in front, the lens, with its capsule, is accurately fitted and intimately attached; and all around this body the hyaloid membrane presents a number of folds or plicæ, which correspond in number to the ciliary processes of the choroid, into the intervals between each pair of which one of these hyaloid processes is received, and an intimate connexion exists between them. These also, like the choroid ciliary processes, are stained by pigment, so that the vitreous body presents in this situation the appearance of a radiated disc or zone, which has been named the *corona ciliaris*, or the *Zonula of*

Zinn. It is a dark, radiated circle, concentric to the lens, but at a slight distance from its circumference; between the margin of which and the corona ciliaris a narrow, transparent circle, about the eighth of an inch wide, is seen. This disc is a little broader on the temporal than on the nasal side; like the iris, it serves to exclude the admission into the interior of the eye of lateral rays of light, and it may also absorb any slanting rays which may have passed through the pupil too obliquely to be refracted to a proper focus by the lens.

If the end of a fine blowpipe be inserted under the hyaloid membrane, where it forms the corona ciliaris, between this and the margin of the lens, and a little air injected gently, a number of fine cells will become distended, presenting a circular, beaded appearance around the lens; this has been named the *canal of Petit*, or *godroné*, the exact construction or mode of formation of which it is not easy to determine; it is generally supposed to be formed by the splitting of the hyaloid membrane at the margin of the lens into two laminæ, one passing in front of and the other behind the capsule of that body, and thus bounding a sort of triangular sinus, the base being the margin of the lens, the apex being the hyaloid membrane at the point of splitting, and the sides being the two laminæ; the beaded appearance being caused by imperfect septa passing from one lamina to the other, through which the air may be impelled from cell to cell. It is probable that these septa also extend across the inner end of each cell, even more perfectly than between them; for, as Jacob has remarked, if the canal be injected with air, and the lens and capsule very carefully removed, the air will be still retained, which proves the existence of some membraneous partition between the cells and the surface of the lenticular capsule.

From the preceding description it must appear that the eye is not only of complex structure and delicate organization, but is also a refined optical instrument. The rays of light proceeding from any object strike upon the surface of the cornea, which, being convex and much more dense than air, refracts them, and causes them to converge towards a distant focus. In passing through the anterior chamber this convergence is slightly counteracted, and the degree of refraction is about equal to that which would have occurred had they impinged at once upon the convex surface of the aqueous humour, supposing the cornea not to have been interposed. Much of the light that traverses this fluid falls upon the iris, which, like the stop or diaphragm in any optical instrument, excludes it, and this light is reflected back again through the cornea; hence we see the fibrous texture and variegated colour of the iris when we look upon the eye of another. Those pencils of rays only which pass through the pupil are subservient to vision. As these pass through the lens they undergo two refractions, because this medium is convex on both surfaces, and is more dense than either the aqueous or vitreous humour. These refractions increase the convergence of the rays, and bring them to their proper focus upon the sentient surface of the retina, on which is formed an accurate

image of the various external objects from which the rays of light have been received. This image is inverted; what is above in the object is below in the image; the right side of the object is to the left, and the left to the right, while the relative position of its different parts remains the same; but as all surrounding objects, if seen, must be equally reversed, the relative position of all objects, therefore, remains unchanged, and there can be no comparison between what is erect and what is inverted, and, therefore, the sense acquires a correct idea of the position of objects. The fact, however, of our seeing objects erect, notwithstanding their images are inverted on the retina, as also that of single vision, from the simultaneous action of both eyes, and many other phenômena, have given rise to some interesting inquiries and to much speculation respecting the functions of the retina and optic nerves; but these questions do not receive elucidation from anatomy, and their consideration rather belongs to the writer on physiology.

As the accurate convergence of all these pencils of rays to their respective foci upon the retina is necessary for the formation of a perfect image, and for clear and distinct vision, certain nice adjustments in the apparatus are required, and have accordingly been supplied, and which in artificial optical instruments are attained with difficulty by mechanical skill. An image of an object, formed by a simple refracting medium, is liable to certain imperfections or aberrations of light: these are principally three, and are technically termed, first, aberration from sphericity; second, from parallax; and, third, chromatic aberration. Each of these we shall briefly explain, with a view of considering how they are obviated in the living eye.

Aberration from sphericity arises from this cause: a refracting spherical surface does not unite the parallel or diverging rays of a pencil exactly into one focus, because the lateral rays converge sooner than the central; hence arises a certain degree of confusion, which requires much attention to correct in the construction of the microscope or telescope. This correction is effected in the eye partly by the iris shutting off all circumferential rays, and partly by the form and texture of the lens; its surfaces are not spherical, but elliptical, and it is more convex posteriorly than in front; its density also increases from the surface to the centre, and, as the refractive power is proportioned to the density of the medium, so the rays, which pass through and near the centre, are brought to a focus sooner, and thus accord with those which are refracted more externally, and thereby that defect is obviated which occurs in lenses of uniform density.

Aberration from parallax may be thus explained. When the object viewed is very distant, the rays of light from it may be considered as nearly parallel; but, when the object is very near, the rays from it diverge considerably in their course to the eye. The effect of refraction on the distant or parallel rays is to bring them to a focus very near the lens; but the near or diverging rays are collected into their focus at a greater distance from it; the more remote the object, the

nearer will the focus be to the lens, and for every distance of an object there is a corresponding focal distance behind the lens. If, therefore, the eye be adapted for vision at one particular distance, the images on the retina of objects at any other distance ought to be confused, because the foci will be formed either before or behind the retina; in the latter case this membrane will interrupt the rays in their course, and in the former it will not receive them until they have crossed each other in passing through their focus. This optical defect is counteracted by a power which the eye possesses, named *adjustment*, or accommodating itself to vision at different distances. The immediate agency in this power is not exactly ascertained, but most probably it depends on a vital energy of some of the textures in the globe; it has been ascribed by some to the fibres of the lens being muscular, and capable of altering its form, density, and distance from the retina; by others to a change in the convexity of the cornea, or to an alteration in the form of the globe by the compression of the surrounding muscles, or to a change in the position of the lens through the action of the iris and ciliary body, or through the contraction or erection of the ciliary processes.

Chromatic aberration depends upon the fact that rays of white light are composed of differently coloured rays, red, orange, blue, &c., which are partly separated or dispersed by refracting media; and, as some coloured rays are more refrangible than others, they will converge sooner; thus blue and violet are more refrangible than red or orange, and will sooner be brought to a focus, and thus the distinctness of the image will be impaired or confused, and fringed with different tints. This defect, which is termed chromatic aberration, is obviated in the eye by the employment of several refracting media, each of different density, and even of different chemical composition. Thus the lens has two unequally convex surfaces, each of which differs in density from its more central portions; the cornea and aqueous fluid form a refracting medium of different consistence from the lens or vitreous humour, and it is probable that the dispersive power of these may be disproportionate to their refracting effect, whereby an achromatic combination is established in the eye, as is effected in optical instruments, by combining lenses of different materials: we are not, however, to conclude that the eye is perfectly achromatic.

The two well-known defects in vision, *myopia* and *presbyopia*, depend either upon some peculiarity in the refracting media, or upon a deficiency or weakness in the power of adjusting or accommodating the eye to vision at different distances. Myopia, or near-sightedness, may be caused by too great convexity of the cornea or lens, and is most common in early and middle life; the rays from a near object meet in their focus on the retina, and produce a distinct image; but the rays from a distant object, being nearly parallel, are more easily brought to a focus, and, therefore, meet before the retina, and only form undefined spectra upon it. This defect is partly corrected by means of a concave glass of suitable curvature; this causes the rays to

become more divergent; therefore, they converge less quickly, and form their focus upon the retina. Presbyopia, or far-sightedness, is more common in old age, when the cornea and lens are less convex than in youth; the rays from distant objects, being nearly parallel, are refracted to a proper focus upon the retina; but those from near objects are not refracted soon enough, and, therefore, their focus is formed behind the retina, and do not form the image upon the nerve. This defect is remedied by a convex glass, which will cause the convergence of the rays from a near object, and bring them more rapidly to a focus, so as to form the image upon the retina, instead of behind it.—(For more full information on the function of vision, read Roget's Anim. and Veg. Phys., vol. ii., pp. 444–507; and an excellent chapter in Muller's Phys., trans. by Baly, vol. ii. pp. 1088–1214.)

SECTION VI.

ANATOMY OF THE EAR, OR ORGAN OF HEARING.

By the sense of hearing an animal is enabled to take cognizance of sounds, and of all their varieties. Sound is the result of any impulse conveyed by the undulations of the air to the organs of hearing, and the latter are so constructed as to receive these undulations, and so organized as to become sensible to them, and to convey the impressions to the sensorium. This sense, next to vision, is most valuable to man, as forming the bond of social union, and the great inlet for all knowledge conveyed by voice and language. Each organ, like the eye, consists, first and essentially, of a special nerve, expanded on membranes and endowed with the properties of sensibility to the impression of sounds, varying as they do in strength, quality, and tone, and of conveying these impressions to the sensorium, or seat of perception; and, secondly, of a physical apparatus, fitted for receiving and conducting, and in some degree regulating, these impulses in their course to the sentient nerve. In the study of this organ the student should refer to the dry skull, and notice the form and course of the meatus externus and internus, and the other foramina in the temporal bone (*see* Osseous System). He may also refer to dry sections of the petrous bone exhibiting the semicircular canals, cochlea, vestibule, and tympanum; models and plates will also be of considerable assistance in explaining this complicated apparatus. All these parts should also be examined in the recent state, the most important characters of which can be exposed without much difficulty by the experienced dissector. Thus the tympanum can be easily opened from the inside of the cranium by chiselling out or cutting through, with a short, strong knife, that portion of bone between the squamous and petrous divisions of the temporal. The membrana tympani may then be seen;

also the ossicula auditus, *in situ*, their muscles and ligaments, the corda tympani and tympanic plexus of nerves, and the several openings leading into and from this chamber. Next, by carefully dividing, partly with the saw and partly breaking with a chisel or light hammer, the petrous bone, in the line of the meatus auditorius internus, the vestibule may be opened, and the several openings into it from the semicircular canals, tympanum, and cochlea, seen; and the fibrillæ of the auditory nerve may also be traced through the cribriform plate to the different membranes in the labyrinth. The semicircular canals are best studied in preparations, but they can be also well seen by cutting and breaking the bone behind the internal meatus, as the cochlea can be similarly exposed in front; of course these remarks will not apply when we wish to make and preserve neat preparations of these parts. The canals and the vestibule may be easily exposed, and are beautiful objects for examination in the ear of any large fish; and in the cartilaginous species very little dissection is necessary to uncover them.

We may divide the ear into an external, middle, and internal portion. The external comprises the auricle, commonly called ear, and the external meatus or tube; the middle consists of the tympanum or drum, with the ossicula auditus; and the internal, or true ear, is termed the labyrinth, and comprises the vestibule, cochlea, semicircular canals, meatus auditorius internus, and auditory nerves. This portion is lodged in the petrous division of the temporal bone, so remarkable for its hardness, whereby this organ is effectually protected from external pressure or injury.

The External Ear, or Auricle, is situated at the side of the head, behind the temporo-maxillary articulation, and in front of the mastoid process; it consists of the auricle or pinna and the external meatus, which terminates at and is closed by the membrana tympani.

Pinna, or *auricle*, commonly called the ear, is the external figured portion, composed of cartilage, ligament, and a few muscular fibres; the whole enclosed in a duplicature of the skin; the general surface is convex towards the head and concave outwardly, in which aspect it presents several irregularities, such as eminences, grooves, and depressions, the latter all tending inwards and downwards towards the meatus, in which they end in a funnel-like manner. The convex border, which forms its outline, is named *helix* (ελιξ, *plica*, or ειλω, *verto*). Superiorly this edge is thin, and curled outwards, so as to bound a depression, named *fossa innominata;* anteriorly it bends downwards and backwards, into the concha, and above the meatus. Anterior and inferior to the helix is the semicircular prominence, called *antihelix*. This is narrow below, but very prominent, and covered by very thin integument: as it ascends it becomes broader, retires from the surface, and divides into two crura, which run in beneath the projecting hem-like border of the helix: the depression between its crura is named *scaphoid*, or *navicular fossa*. Anterior to and overhanging the meatus auditorius, somewhat like a valve, is the eminence called *tragus*, of a triangular form. The base is anteriorly behind the max-

illary articulation; the apex is free, and directed a little backwards and outwards towards the concha; its inner surface is set with strong, coarse hairs, or vibrissæ, which extend across the orifice of the meatus, and partly defend it against the entrance of foreign bodies. From

*Fig. 74.**

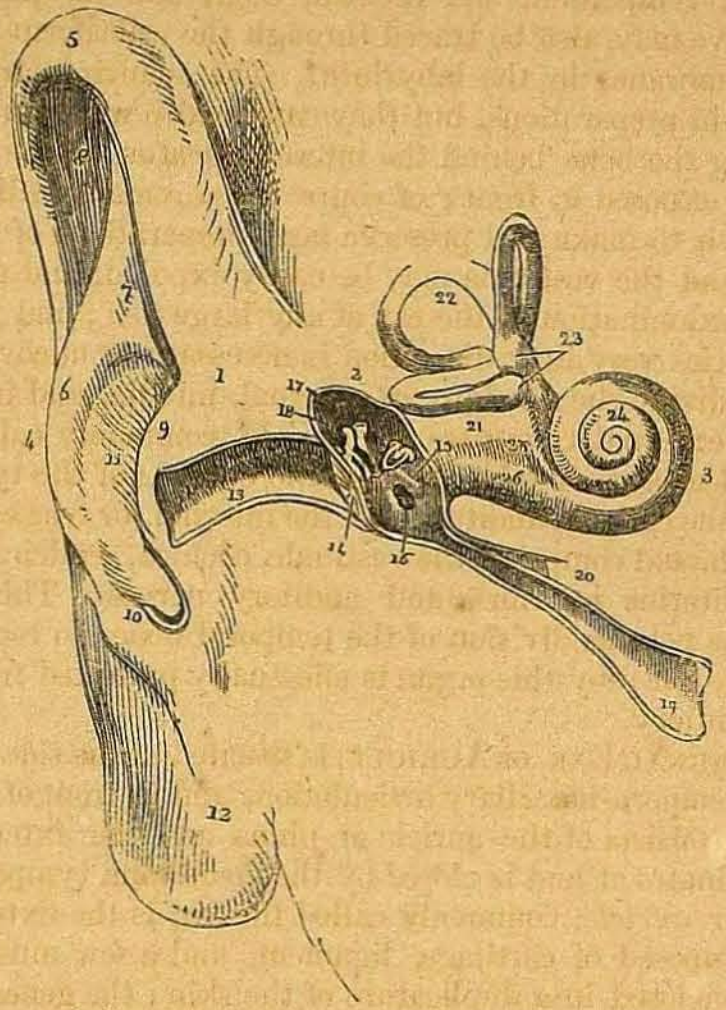

these hairs it has derived its name, τραγος, *a goat.* When pressed backwards or inwards it can cover and close the meatus. Opposite to the tragus, and separated from it by a deep, round notch, is the *anti-tragus,* a small tubercle connected to the lower extremity of the anti-

* The organ of hearing. 1. The external ear, including the cartilages and meatus externus. 2. The middle ear, consisting of the tympanum and its appendages. 3. The internal ear, or the labyrinth. 4. The pinna. 5. The helix. 6. The antihelix. 7. The fossa navicularis. 8. The fossa innominata. 9. The tragus. 10. The antitragus. 11. The concha. 12. The lobulus. 13. The meatus auditorius externus. 14. The membrana tympani. 15. The promontory. 16. The foramen rotundum. 17. The posterior wall of the tympanum, in which is an opening leading to the mastoid cells. 18. The ossicula auditus; four small bones within the cavity of the tympanum, namely, the malleus, incus, os orbiculare, and the stapes. 19. The Eustachian tube. 20. A narrow canal, containing the tensor tympani muscle. 21. The vestibule. 22. The three semicircular canals, viz., the superior, posterior, and horizontal. 23. The ampullæ, at the termination of the superior and horizontal canals. 24. The cochlea. 25. The prominence caused by the scala vestibuli. 26. That of the scala tympani.

helix. Within the antihelix, tragus, and antitragus, and traversed anteriorly and horizontally by the upper and anterior extremity of the helix, is the large, deep depression called *concha*, into which all the other grooves converge; it is of a funnel form, and leads obliquely downwards and forwards into the meatus auditorius. The lower pendulous part of the auricle is named the *lobe*, or lobulus, and is only composed of the soft fold of integument containing cellular and adipose tissue; it possesses but little organization, and has been selected in many countries as a favourable part to perforate, and from which to suspend ornaments of various kinds. The cartilage of the auricle constitutes its skeleton, and, being elastic, preserves its figure. When the integument is removed, it presents eminences and depressions nearly corresponding to those already described. No part of it enters into the lobe; it is covered by perichondrium, from which it derives considerable strength. If the latter be removed, the cartilage becomes brittle and weak. The portion of it forming the helix commences narrow in the concha above the meatus; it ascends and becomes broader, then turns round the top of the auricle, descends, decreases in breadth, and ends in a narrow, caudate point, separated from the antitragus by a fissure. Of the crura of the antihelix, the lower is very prominent, and runs inferiorly into the extremity of the helix. The cartilaginous plate of the tragus is connected to that of the helix only by fibrous tissue: it presents a deep fissure: the plate of the antitragus is continuous with that of the concha.

The *ligaments of the auricle* are, first, the *anterior*, which extends from the root of the zygoma to the anterior part of the helix and to the tragus; second, the *posterior*, which extends from the mastoid process to the concha, where it joins the meatus externus. Some writers also enumerate, as distinct ligaments, bands of fibres which pass from one cartilaginous eminence to another.

The *muscles of the external ear* are divided into those which attach it to and move it upon the head, and those which only pass from one part of the cartilage to another. The former are three in number, viz., the anterior or attrahens, the superior or attollens, and the posterior or retrahens (*see* page 4). The latter, or the intrinsic muscles, are named from the eminences to which they are attached. First, the *major helicis* extends from the lower and anterior part of the helix to its superior free border. The *minor helicis* is inferior and posterior to the last; extends from the commencement of the transverse part of the helix, in the concha, to the posterior border of its ascending curved portion. The *tragicus* covers the cartilage of the tragus, extending from above its base to its apex. The *antitragicus* extends from the antitragus to the lower end of the antihelix. The *transversus auriculæ* consists of a few indistinct fasciculi, extending from the dorsum of the concha to the back of the antihelix. All these intrinsic muscles are feeble, and scarcely to be distinguished in man, and cannot exert any material influence: they may be considered as merely rudimental of those more highly developed muscles found in the large ears of most quadrupeds.

which are enabled to alter the form and direction of the auricle and of its various curvatures with considerable force.

Meatus auditorius externus leads from the anterior and inferior part of the concha obliquely inwards to the membrana tympani; it is about an inch or an inch and a quarter long, is placed between the mastoid process and the maxillary articulation, and above and behind the parotid gland, which is closely moulded around one-half of its circumference. The external half of this tube is formed of cartilage, the remainder of bone (*see* Temporal Bone, Osseous System); its direction is curved or tortuous, as will best appear from a mould taken of the entire tube, or from a horizontal section of it. It first leads forwards and upwards, then a little backwards, and, lastly, its osseous portion leads downwards, forwards, and inwards. By drawing the auricle upwards and backwards we can partly straighten the canal; and with a strong light directed into it we can see down to the membrana tympani. Its general curvature is convex upwards and concave downwards; and, from the obliquity of the membrana tympani, its lower wall is longer than the upper. A vertical section of the tube is of an oval form, the long axis being in that direction; it is dilated at its tympanic end, particularly on its inferior wall, and the narrowest parts of the tube are its commencement and its centre, where the cartilaginous and osseous portions join. The former can be separated by dissection from the latter, and is rather fibrous at the line of junction. This cartilage is not prone to the ossific change; it is somewhat of a triangular form, but curved so as to form about two-thirds of a cylinder. The base is below and behind, attached to the mastoid process; the apex is before, connected to the base of the tragus near the root of the zygoma; one side is attached to the anterior and lower border of the osseous tube by fibrous tissue, and the other is connected to and continuous with the base of the tragus; in fact, this portion of the tube appears as a continuation of the tragus. The superior and posterior part of the canal is formed by dense fibro-cellular tissue, which extends from the margin of the concha to the upper and posterior part of the osseous canal. Two or three fissures exist in the forepart of this cartilaginous meatus (incisuræ Santorini); their direction is transverse or oblique, and they are closed by dense fibrous tissue, in which Santorinus has described muscular fibres, which he supposed capable of shortening and contracting the tube. The parotid, much cellular tissue, and sometimes a lymphatic gland, are in contact with this portion of the meatus, and small nerves and vessels enter it through the fissures: through one of these, also, deep-seated abscesses in this region sometimes open, and the matter may continue to discharge for a long time through the external meatus. The *bony portion* of the meatus is wanting in the child; a mere tympanic ring supplies its place; hence the meatus is much shorter at that age, and the membrana tympani can be more easily seen, and is more exposed to injury or accident. From this ring an osseous lamina gradually arises, and which for some years continues distinct from the temporal bone; as it increases it

forms a sort of sheath for the styloid process, and continues separated from the anterior part of the glenoid cavity by the fissure of Glaser. This lamina also increases within or beneath the tympanic ring; and, therefore, in the full grown bone it forms not only the bony meatus, but also a portion of the lower wall of the tympanum. In the old subject there is frequently a foramen in this bony portion of the meatus. The external orifice of the meatus is of an oval form, but very variable in size: in old persons it is often set round with coarse hairs: the tragus partly covers and protects it. The internal or tympanic extremity of the tube is nearly circular, and directed obliquely downwards and inwards. The auditory canal is lined by the integument continued from the auricle and concha; it becomes extremely fine, vascular, and sensitive, and is covered by fine hairs. The cutis ceases at the margin of the lower extremity; but the cuticle is continued over the membrana tympani, from which it readily separates by maceration or putrefaction, and can then be drawn out of the meatus like a thimble or *cul de sac*. The skin, from a little distance within the external orifice to within a quarter of an inch of the tympanum, is perforated by numerous small openings, the orifices of the sebaceous follicles, and of the *cerumenous glands*. The latter are most numerous about the centre, or the constricted portion of the tube, that is, where the cartilaginous and osseous portions meet. These glands are small, oval bodies, of a pale yellowish colour, and highly vascular; each consists of a convoluted cæcal tube, one extremity opening on the skin. These glands secrete the *cerumen*, or ear-wax, a yellow-brown, viscid substance, of an intensely bitter taste and slightly aromatic odour. When first secreted it is thin, yellowish, and milky, but soon concretes and hardens; it defends the passage from the entrance of foreign bodies, and may also serve to diminish the force of the undulations or vibrations of the air in their course to the membrana tympani.

SECTION VII.

MIDDLE EAR, OR TYMPANUM.

THE tympanum is the space within the membrana tympani, and external to the osseous parietes of the vestibule and labyrinth, in front of the mastoid cells, and communicating anteriorly with the Eustachian tube. It is of a very irregular form, and presents a rugged, uneven surface; is bounded externally by the membrana tympani, and on all other sides by the petrous bone. It contains air and a little fluid; is traversed by the chain of small auricular bones and by fine nerves and vessels. Its perpendicular and antero-posterior diameters are nearly equal, and about half an inch in extent, or somewhat less; its transverse diameter, that is a line leading from the membrana tympani

inwards to the vestibule, is only a quarter of an inch, or rather less. The walls of the cavity are lined by a fine mucous membrane, continuous through the Eustachian tube with that of the nose and pharynx. This membrane is also reflected around the different parts which are contained in the cavity. We shall first examine the membrana tympani, which, with the bone to which it is attached, forms the outer side or wall of the tympanum, and separates it from the meatus externus.

Membrana tympani is situated at the inner and lower extremity of the meatus, separating it from the cavity of the tympanum or drum, the outer wall of which it forms; it is a thin, dry, semitransparent membrane, nearly circular, the vertical diameter a little longer than the transverse or antero-posterior. In the infant it is more round; in the adult rather oval: it presents in the dead body an irregularly concave surface towards the meatus, and a convex one towards the tympanum. It is covered by the cuticle, continued from the parietes of the meatus, beneath which the proper fibrous tissue is inserted into the circular osseous groove which separates the meatus from the tympanum. This groove is placed obliquely, the lower part of its circumference being more internal or mesial than the superior; consequently the outer or concave surface of the membrane has an oblique aspect downwards and outwards, and forms an angle of 45° with the lower wall of the meatus, which latter, therefore, is longer than the superior. The inner surface of the membrana is directed upwards and inwards, adheres intimately to the handle of the malleus bone, and is lined by the mucous membrane continued from the pharynx through the Eustachian tube to line the drum. This attachment of the process of the malleus occupies more than the upper half of the vertical diameter of the membrane; and as this process is directed obliquely inwards, even to its very point, it appears to draw the membrane partially inwards, so as to present a funnel-formed cavity towards the meatus. In dry preparations this is uniformly the appearance of these parts; but when examined in the recent state, or during life, with the assistance of the "speculum auris," this form is not so distinct; the manubrium of the malleus rather makes a slight projection above the centre of the membrane, and is convex towards the meatus, while the general surface is unequally concave. From a mould taken of this surface in the recent state, I have observed very plainly this uneven appearance, and would infer that the general surface is concave towards the meatus, with a slight prominence leading from above the centre upwards to its superior margin. As, however, the membrane is vibratile, and yields to slight impressions, it is by no means improbable that after death it becomes more depressed, and, therefore, more convex towards the drum and concave towards the meatus, than it was during life. I recommend the student to make the following examination of this part, which can be done with little difficulty or trouble. Procure the head of a fœtus or infant; make a vertical section of the cranium and face; remove all unnecessary parts; dissect off the auricle and external

meatus on a level with the tympanic ring; wash off the cuticular lining, and the membrana tympani will be fully and distinctly exposed. At this age it is larger in proportion than in the adult, and its aspect is almost directly downwards. Its central depression or concavity is deeply marked; and a little above this the manubrium of the malleus is distinctly prominent and convex, and its upper portion so thinly covered as to appear to be partially external to the fibrous lamina of the membrana. Its direction also, in respect to the membrane, is nearly vertical, but inclines a very little backwards; that is, when the head is turned in such a manner as to bring the parts fully into view; but if it be held in its proper position, with the zygoma horizontal, then, in consequence of the downward aspect of the membrane, the manubrium will be found to pass nearly in a horizontal line from the upper and outer border of the tympanic ring inwards towards the mesial line and a little downwards to the centre of the membrana. I believe an erroneous idea generally prevails as to the direction of this bony process, in consequence of the habit of regarding it in dry preparations, and especially in models, in which latter I have not yet seen it properly represented. In the adult, however, the manubrium is somewhat more vertical than in the fœtus, as in the former the membrane does not look so directly downwards as in the latter, the aspect being gradually altered from the horizontal to the oblique by the remarkable change of growth which occurs in the lower part of the tympanum and in the meatus externus. Next introduce a blowpipe into the Eustachian tube, and gently inflate the tympanum; the mobility and elasticity of the membrana are then beautifully seen, while its transparency admits of your observing through it the corda tympani, and the long crus of the incus, parallel but posterior to the manubrium of the malleus. At each distension of the cavity the membrane bulges outwards, not uniformly, but at either side of the manubrium and in the superior half. Very little change occurs in the central depression, or in the lower half, beyond a general vibration; and no force can swell out the membrane into one general convexity, or even into a plane surface, but the slightest distension causes a swell superiorly at each side of the manubrium. When the tympanum is thus distended, the fibres of the membrana are seen very distinctly running, in curved or arched lines, convex towards the meatus, towards the depressed centre, and towards the deeper surface of the manubrium. It appears to me that it is this fulness of these curved fibres, together with the prominence of the white manubrium and the strong illumination produced by the rays of light concentrated by the polished speculum, which have induced some to suppose that the membrana tympani is, during life, convex towards the surface, a condition which is the normal state in birds, there being in this class but one ossiculum auditus (columella or stapes), which supports the membrane, and retains in it that convex state, which is one of the sriking anatomical peculiarities of the feathered race.

Mr. Wilde has made an examination of this membrane in the living

ear, and has published the result of his researches in an excellent practical memoir in the Dub. Jour. of Med. Sci., vol. xxiv. No. 74, p. 421. He states: "The appearance of this membrane, when seen in life, by the speculum, is greyish, white, and semitransparent; within it is seen the manubrium of the malleus, proceeding from above downwards and slightly forwards, about half-way across the membrane, and dividing it into two portions, both of which are distinct from the purse-like projection of the fibro-mucous membrane behind the tubercle of the malleus, or 'membrana flaccida,' described by Shrapnell, which seems to me only rudimentary in man, but is well developed in some of the lower animals, the sheep in particular. The anterior and posterior divisions of the true membrane, as separated by the handle of the malleus, are of different curves and degrees of tension, and the whole membrane does not form a concavity on its external aspect, but its upper or anterior portion is flat or slightly concave, while that part below and behind the malleus is convex towards the external aperture. This lower portion is also more glistening than the upper or anterior, and, when viewed through the speculum, a bright spot of light shines upon its most convex portion, which is a little behind and below the point of the malleus. This peculiar curve I have again and again demonstrated to several members of the profession, and I believe the general external concavity ascribed to this membrane by anatomical writers is a *post mortem* appearance."

The *membrana tympani*, though thin and semitransparent, consists of three distinct tissues, an external or epidermoid, already noticed, a middle or fibrous, and an internal or mucous. The middle or *fibrous lamina* is that on which the strength and form of this septum depend; to it the handle of the malleus is intimately attached. When carefully examined, either recent or dry, the fibres are very distinctly seen, pursuing a radiated arrangement and converging from the circumference towards the centre, or rather towards the malleus, into the whole length of which they are inserted. Therefore, this portion of the membrane, which corresponds to the upper half of its vertical diameter, is the strongest: the circumference is also strengthened by a ligamentous ring attached to the bone. Some describe this membrane as consisting of two fibrous laminæ; the external one as composed of the radiating or converging fibres, the deeper layer being less evidently fibrous, and the fibres taking a different course from the superficial. No such accurate division, however, can be effected in the human membrane, although in the vicinity of the malleus, and towards the circumference, where the tissue is thicker, it may be partially separated into layers; the deeper stratum appears to be composed chiefly of vessels. The fibrous layer of the tympanum is stated by many writers to be muscular: this opinion has been corroborated by the assertion of Sir E. Home, that in the elephant the muscular structure is very distinct (Phil. Trans. An. 1823). From recent examination of it in this animal, I do not feel disposed to concur in this statement, as the fibres appear white, tense, and shining, like those of true white fibrous tissue.

A small, oblique, valvular opening (hiatus Rivini) has been described as existing in this membrane between its circumference and the manubrium of the malleus; most probably, however, this is an abnormal appearance, and only observed in some few cases, as a very careful examination of this part in the recent state does not disclose it. The membrane, also, is almost uniformly impervious to air; and when removed from the body I find it will retain water or quicksilver when placed on either surface. In the elephant, near the point of the malleus, there is an appearance of a small, oblique slit, in consequence of the elevation of the lining membrane by that bone, but it is closed towards the meatus. The vessels of the membrana admit of injection in the fœtus, either from the arteries or veins, and present a very beautiful, delicate, and radiated arrangement. It is most probable that they belong to the lining mucous membrane, rather than to the proper fibrous tissue. The membrana tympani serves to close the lower extremity of the external meatus, and to separate it from the tympanum, and is thus interposed between the external air and that which fills this cavity. It transmits the vibrations it sustains from the external impulses or undulations of the air to the chain of bones and to the air and fluid within the tympanum, through which these are carried to the internal or sentient part of the organ. The membrane also admits of relaxation and tension, which changes are effected by the motions of the small bones in the tympanum, to which we shall allude when we have examined the other parietes of the cavity.

The *tympanum* may be opened either by cutting away the upper or lower part of the petrous bone opposite the cavity, or by removing the membrane just described, which forms the outer part of this chamber. This cavity is a small space, of a very irregular form, about a quarter of an inch in extent from back to front, and less than the third of an inch from without inwards. It is bounded externally by the membrana tympani; internally by the petrous bone, which contains the labyrinth or the essential part of the organ, and which is separated from it by the membrana vestibuli, in the same manner as the tympanum is divided from the meatus by the membrana tympani. It is bounded behind by the mastoid portion of the temporal bone, containing cells with which it communicates. Anteriorly it leads into the Eustachian tube; above and below it is closed by bone. Its internal or vestibular side presents several objects for observation. At its upper part is situated the oval or rather kidney-shaped foramen, *fenestra ovalis*, or *vestibuli*. This opening is directly opposite the membrana tympani; it is convex above, more straight below: its long axis is transverse, and inclined a little downwards and forwards. In the dry bone it leads into the vestibule, but in the recent state it is closed by a membrane, composed, like the membrana tympani, of three laminæ, viz., the lining of the vestibule, the lining of the tympanum, and an intermediate fibrous tissue. The base of the stapes bone also closes this opening, and is fixed between the fibrous layer and the tympanic mucous lining. This foramen is placed in a fossa beneath the

curved ridge, or the aqueduct of Fallopius, which contains the portio dura nerve. Below the foramen ovale is the bony projection of the *promontory*, which corresponds to the first turn of the cochlea, and on the surface of which are delicate grooves, diverging above, and converging below to a common canal, which opens upon the inferior surface of the petrous bone, between the foramen caroticum and lacerum posticum, and transmits the small nerve of Jacobson from the glosso-pharyngeal nerve. Behind the fenestra ovalis is the bony *pyramid*, the apex of which is directed forwards and outwards, and is perforated by a small canal which leads to some extent into this hollow process, which contains a small muscle called stapedius. Below and rather behind the promontory is the *foramen rotundum*, or *fenestra cochleæ*, which in the dry bone is open, but in the recent state is closed by a membrane of the same nature as that of the fenestra vestibuli. In front of the fenestra ovalis, and above its transverse axis, is the opening of the canal which contains the tensor tympani muscle, or internal muscle of the malleus. This canal leads forwards and towards the mesial line, and is immediately above the Eustachian tube, separated from it by a thin, concave, osseous plate, named cochleariform process.

The upper wall of the tympanum is spongy or porous; a number of small vessels pass through it to the dura mater, which adheres closely to this part of the bone; a fact of some practical importance in case of suppuration within the tympanum, or of caries of the temporal bone. On this surface is a pit or depression, for the head of the malleus and for the top and short leg of the incus.

The inferior wall of the tympanum is rough and narrow, and formed by the continuation of the external auditory plate and vaginal process.

The posterior wall presents at its upper part a large, irregular opening, which, both in the dry bone and in the recent state, leads into the mastoid cells. There is first one large cell, and this leads into an irregular series of others, which occupy the mastoid process; they are lined by mucous membrane, and are filled with air, analogous to the frontal and other sinuses which communicate with the nose. These cells do not exist in the fœtus; a depression, however, corresponds to the place of their future development. Below the mastoid opening is the small orifice from the aqueduct of Fallopius, close to the posterior part of the circumference of the membrana tympani, for the passage of the chorda tympani nerve.

The anterior wall of the tympanum tapers off into the Eustachian tube, above which are the cochleariform osseous plate and the canal for the tensor tympani muscle. This canal, as it leads backwards into the tympanum, is situated on its inner wall, and terminates in an opening, which is directed outwards or towards the membrana tympani. Cruveilhier not unaptly compares these two canals, one above the other, to a double-barrelled gun.

The *Eustachian tube* is a narrow canal, about an inch and a half long, leading from the tympanum obliquely forwards, downwards, and inwards towards the back of the nose, where it opens on the side of the

pharynx, and on a level with the inferior spongy bone, behind and above the lower meatus of the nose, and above the velum and the tonsil. Its tympanic orifice is small compared to its nasal, which is large, trumpet-like, oval, and dilatable; it is composed of osseous, cartilaginous, fibrous, and mucous tissues. The first or tympanic portion is chiefly osseous, and is situated in the angle between the petrous and squamous bones; the remainder of the canal is bounded above by the groove between the petrous bone and the spinous portion of the sphenoid; to this groove the sides or walls of the tube are attached. The outer wall is composed posteriorly of cartilage, and anteriorly of fibrous membrane, which is partly covered by the tensor palati muscle; the inner side, and in part the upper surface, is formed by a curved cartilaginous plate, which is attached to the petrous bone and to the root of the internal pterygoid process, and which becomes thick anteriorly towards the guttural orifice, where, when dissected, it appears divided into two angles, the anterior attached by fibrous tissue to the root of the internal pterygoid plate; the posterior is thick, semilunar, and prominent, with its convexity upwards and backwards, and admitting of motion in that direction. The narrowest part of the tube is where the osseous and fibro-cartilaginous portions meet. The mucous membrane which lines it is very fine and delicate, excepting near the anterior orifice, where it acquires all the characters of that of the fauces. This orifice presents a large oval figure, with prominent edges, directed obliquely downwards, forwards, and inwards. The *use* of this tube is to admit the external air into the tympanum, whereby the membrana tympani is enabled to support the external atmosphere, and can vibrate freely between the cavity and the meatus. The temperature of the air also within the tympanum is raised to a certain degree, which could not have been the case had it entered directly from the external meatus. It also conducts the secretions from the cavity of the tympanum and from its own walls downwards into the fauces.

The tympanum also presents another small opening or canal, anteriorly and inferiorly, which leads to the inner side of the fissure of Glasser, and transmits the corda tympani. The course of this nerve through the cavity may now be observed; it enters the tympanum at its posterior part, close to the circumference of the membrana tympani, and nearly on a level with its transverse diameter; it then passes in a curved manner forwards and downwards, convex upwards, between the handle of the malleus and the long leg of the incus, and escapes through the foramen and canal at the lower and anterior part of the tympanum, already described. The cavity of the tympanum is traversed by a chain of small bones, one of which is attached externally to the membrana tympani, and another to the membrana fenestræ vestibuli, whereby the impulse impressed upon the former is conveyed to the latter. We shall next examine these bones, with their ligaments and muscles.

Ossicula auditus are three, or, according to some, four in number, and are named, from their fancied resemblance to other bodies, *mal-*

leus or hammer, *incus* or anvil, *stapes* or stirrup. The fourth, or *orbicular*, is by many considered as a mere epiphysis to the long leg of the incus. All these bones are very hard, and are very early developed in the fœtus.

Malleus is immediately within the membrana tympani, and connected to it; it presents a head, neck, handle, and long and short process. The *head* is in the recess in the upper part of the tympanum, above the membrana, and in front of the incus; it is smooth and round above, but concave below, or somewhat saddle-shaped for articulation with the incus. Below the head is the flattened *neck*, from which arise two processes; one is the *external* or *short*, and directed outwards to the upper part of the membrana tympani, which it supports; the other is the *gracilis*, or process of Rau, a delicate spine, about half an inch long, arising from the anterior part of the neck, ends in a broad, flat extremity, which rests in the Glasserian fissure, and gives attachment to a fibrous cord, by some described as a muscle under the name of laxator tympani; it is most probably, however, only a ligament. The *manubrium*, or handle, descends from the neck nearly vertical, or a little inwards; is at first compressed from the side corresponding to the articular surface, adheres intimately to the radiating fibres of the membrana tympani, becomes very slender, and descends as low as the centre of that membrane, where it ends in a flat or blunt extremity, a little curved, concave outwards.

Incus is placed internal and posterior to the malleus, and bears some resemblance to a bicuspid tooth; it presents a body or head, and a short and long crus. The *body* is directed upwards and forwards, is lodged in the recess of the tympanum, and receives the head of the malleus in its deep concave surface. The *short* or superior *crus* is thick and conical, and directed horizontally backwards in the recess in the tympanum, and occupies the opening into the mastoid cells. The long or inferior crus descends vertically in the tympanum, nearly parallel to the handle of the malleus, but on a plane internal and posterior to it, and separated from it by the chorda tympani; its lower end is bent inwards, like a hook, and is convex outwards. At its extremity is the round tubercle, which is sometimes united to it like an epiphysis, but is sometimes separable from it, and is named os orbiculare, or lenticulare.

The *stapes*, or stirrup, is placed horizontally between the crus of the incus or orbicular bone and the fenestra ovalis, to the membrane of which its base is attached. Its *head* presents a small cavity for articulation with the orbicular bone, or with the crus of the incus; its *base* is a thin plate, closing the fenestra ovalis. Of its two *crura* the posterior is the longer and more curved.

The articulations between these bones are furnished with synovial membranes and capsular ligaments, and are further secured in their position by *three ligaments*. One extends from the head of the malleus to the upper wall of the tympanum; another connects the short process of the incus to the opening of the mastoid cells; and a third

extends from the margin of the fenestra ovalis to the margin of the base of the stapes. A fourth might be added, extending from the process of Rau through the Glasserian fissure.

The muscles of the tympanum are only two in number, the stapedius and the tensor tympani.

Stapedius muscle *arises* within the pyramid, escapes from its point by a small tendon which passes forwards, downwards, and a little outwards, and is *inserted* in the back part of the neck of the stapes. Its action must be to press the back part of the base of the stapes against the fenestra; at the same time it draws inwards the crus of the incus, and rotates the malleus so as to draw inwards the manubrium, and thereby make tense the membrana tympani: it must also serve to fix the stapes, and retain it *in situ*. Some consider it as a mere ligament between the stapes and the petrous bone, as it resembles a white fibrous cord rather than a muscle. I may observe that in the elephant it is well developed, and there can be no doubt of its being a true muscle.

Tensor tympani, or internal muscle of the malleus, is a very distinct and long fibro-muscular cord, chiefly lodged in the bony canal already described, above the cochleariform process and the Eustachian tube, to which it is parallel in the greater part of its course. It *arises* from the cartilage of that tube and from the adjacent portion of the sphenoid bone, behind its spinous foramen; also from the sides of the bony canal, in which it is enclosed. The fleshy fibres proceed backwards, and end in a tendon which enters the forepart of the tympanum, and is then reflected at a right angle outwards, like the canal in which it is enclosed, and is *inserted* into the inner, anterior, and superior portion of the handle of the malleus, below the processus gracilis, and opposite the root of the short process. *Use.*—To draw the handle of the malleus inwards and forwards, whereby the membrana tympani is drawn inwards and made more tense. In this motion the processus gracilis may be considered as an axis on which the whole malleus moves, the head being directed backwards and outwards, and the manubrium inwards and forwards. The incus being connected with the head of the malleus, and moving on its short crus, as on an axis, follows the malleus outwards, while its long crus is directed inwards, and presses the stapes against the membrana vestibuli, and renders it more tense; this latter effect being still further secured by the action of the stapedius muscle, as before described.

Two other muscles are described by some writers, but it is more than doubtful whether any such exist, ligamentous fibres being described as muscular; they have been named laxator tympani major, or anterior or external muscle of the malleus, and laxator tympani minor, or superior muscle of the malleus. The *laxator major* extends from the processus gracilis of the malleus through the glenoid fissure, and is continuous with the fibrous tissue of the spinous portion of the sphenoid bone and of the internal lateral ligament of the maxillary articulation. It possesses all the characters of a ligament, fixing the process of Rau in its situation, and when the latter is short an exten-

sion of this cord supplies its place. The *laxator minor* is nothing more than a fibrous cord descending from the upper part of the tympanic ring to the handle of the malleus, below the short process. As the membrana tympani can be made more tense by the two muscles first described, their relaxation must allow the membrane to fall into a corresponding state; there is, therefore, no apparent use or necessity for laxator muscles. This remark, together with the apparent ligamentous structure of the two last described cords, induce us to regard them as mere ligaments, and to consider the true muscles of the ossicula as only two in number, and as tensors of the membrana tympani and the membrana vestibuli.

The tympanum is lined by a fine membrane, which, being continuous through the Eustachian canal with that of the pharynx, belongs to the mucous class. In this cavity, however, it becomes extremely delicate, and, being intimately united to the periosteum, is properly a fibro-mucous membrane; it covers all the irregularities on the walls of the cavity; is reflected around the bones, muscles, and nerves which traverse it; lines the inner side of the membrana tympani, the outer side of the membrana vestibuli, closes the fenestra cochleæ, also the space between the crura of the stapes, and is continued into the mastoid cells. It is not prolonged into the labyrinth or internal ear, but forms a perfect septum between it and the tympanic cavity; its continuity through the Eustachian tube with the gastro-pulmonary surface is of practical moment.

SECTION VIII.

INTERNAL EAR OR LABYRINTH.

THIS is the essential part of the organ of hearing: it lies deeply buried in the petrous bone, and consists of a number of curiously formed channels and spaces wrought out of the osseous structure, and containing delicate membraneous tubes filled with fluid; on these the terminal branches of the sentient nerve are expanded. The *labyrinth* consists of two portions, an osseous and a membraneous. The *osseous labyrinth* consists of three distinct compartments: one in the centre, named the vestibule; one behind this, composed of three semicircular canals; and one in front of it, named the cochlea. Both the anterior and posterior compartments communicate with the vestibule; and the meatus auditorious internus communicates with each of these by minute foramina for the transmission of the auditory nerves.

The *meatus internus* should be first examined; it is shorter and smaller than the external; is scarcely a quarter of an inch in length, and is a little wider at its cerebral than at its aural end; lined by the dura mater, it leads from the cranium directly outwards, and ends in

a *cul de sac*, which is subdivided into two by a horizontal bony crest. The superior and smaller depression presents posteriorly some small foramina, which open on the inner side of the vestibule, and transmit auditory filaments into that chamber; and anteriorly the large opening of the superior and internal extremity of the aqueduct of Fallopius for the passage of the facial nerve. The lower and longer depression corresponds anteriorly to the base of the cochlea, and presents a spiral canal answering to the turns of that tube, and is perforated by numerous apertures, of which one is larger than the others, and leads into a canal in the axis or modiolus of the cochlea. The posterior part of this *cul de sac* presents a superficial cribriform fossa, over the hemispherical depression of the vestibule. Through these various minute foramina, the fibrillæ of the mollis or auditory nerve, enter the labyrinth, and are expanded on the membranes within it.

The *vestibule*, or central cavity of the labyrinth, is a very small space placed between the fenestra ovalis and the meatus auditorius internus. Its diameter in this transverse direction is about the eighth of an inch, and its vertical and antero-posterior diameters are longer, or about the fifth part of an inch; its form is very irregular, being extended or dilated somewhat in three situations, namely, superiorly, and inferiorly both before and behind. These dilatations are called its *ventricles* or *cornua;* one is named superior cornu, another inferior and posterior, and the third inferior and anterior. In each of these cornua there are certain openings to be observed. The vestibule presents on all sides a number of foramina, some large and distinct, others very minute. On its external or tympanic wall is seen the fenestra ovalis, perfectly closed by membrane and by the base of the stapes; the transverse or long axis of this opening is about the tenth of an inch; its vertical is much less; its margin projects inwards towards the vestibule. The inner or cerebral wall of the vestibule corresponds to the bottom of the meatus auditorius internus, is cribriform (*macula cribrosa*), and transmits some fibrillæ of the auditory nerve and some fine capillary vessels. In the *posterior* and *lower horn* are seen three distinct foramina, the orifices of the semicircular canals. In the *superior cornu* are the other two openings of these tubes. In the *inferior* and *anterior cornu* is a distinct oval opening, which leads downwards and forwards into the vestibular scala of the cochlea. Thus the vestibule presents seven large foramina, viz., the fenestra ovalis, fenestra cochleæ, and the openings of five semicircular canals. In addition to these there are several smaller foramina, namely, first, those in the cribriform lamina for the auditory nerves; second, the *aqueductus vestibuli*, which opens in a sulcus on the posterior wall, internal to the common opening of the semicircular canals; this aqueduct first bends round this common opening, and then turns at a right angle downwards, and, descending through the petrous bone, opens upon its posterior surface, behind the meatus internus. It transmits a small vein, and its lining membrane is continuous with the dura mater. In the anterior horn is a depression (*fovea hemisperica*), cribriform for the passage of

nerves, and corresponding to the posterior division of the *cul de sac* of the meatus internus. This depression is separated from another smaller depression, also cribriform (*fovea elliptica*), by a prominent bony ridge (*eminentia pyramidalis*). The several eminences and depressions in this region have been described with an unnecessary degree of minuteness, not likely to lead to any physiological conclusions.

Semicircular canals are three bony tubes imbedded in the petrous bone, behind the vestibule, and communicating with it: they are curved so as to form nearly three-fourths of a circle; their calibre is not quite round, but they are compressed laterally, therefore a vertical section of any of them presents an elliptical orifice. They open by each extremity into the vestibule; but, as two of them unite by their adjoining extremities, they present only five openings in this chamber. Their diameter is about one-twentieth of an inch, but they are a little wider at their orifices, where one extremity of each is dilated into a sort of sinus or ampulla, of which there are three. Of these canals two have a perpendicular and one an horizontal direction; they are distinguished by the names of superior or anterior vertical, inferior or posterior vertical or oblique, and the horizontal. The *superior vertical* is convex upwards, runs transversely across the petrous bone, and its projection is seen upon its upper surface, particularly in the fœtus. The outer extremity opens by an ampulla in the superior horn of the vestibule, and the inner joins the upper crus of the posterior vertical or oblique canal, and opens by a common orifice in the posterior horn of the ventricle. The *posterior vertical or oblique* is in and parallel to the posterior part of the petrous bone; is convex upwards and outwards; one extremity opens in the ampulla in the posterior horn, and the other in the common canal with the last. The *inferior or horizontal canal* is shorter than either of the vertical; is convex outwards; one end opens in the ampulla in the upper horn, the other in the posterior horn. The external extremity of the vertical, the inferior of the oblique, and the anterior of the horizontal, are the three ends of the canals which present ampullary dilatations.

The *cochlea* is the most anterior part of the labyrinth, and is a very complicated apparatus. It is resembled to the snail-shell; is situated in the anterior portion of the petrous bone on the inner side, and in front of the tympanum; is of a conical form; its apex is directed forwards, outwards, and downwards, and its base corresponds to the bottom of the meatus internus. We may suppose it to be a tapering tube, closed at its smaller extremity, coiled round a central pillar, and this tube subdivided by a partition into two semicylindrical tubes. It presents for our notice the tube, the lamina spiralis, the axis or modiolus, and the scalæ. The *tube* is about an inch and a half long and the tenth of an inch in diameter at its commencement, and one-twentieth at its termination. It describes two turns and a half, in a direction from below upwards and from without inwards; the second turn lies, at its beginning, within the first, but near its end rises above it. The *axis* or *modiolus* is a conical tube, whose summit is expanded like a

funnel; *arises* from the base of the cochlea, opposite the bottom of the meatus internus, and is directed almost horizontally outwards: it occupies the centre of the cochlea, the coils of which and of the lamina spiralis twine around it. The whole of the axis is concealed by the tube of the cochlea; its base or origin is pierced with foramina for the auditory nerves; it becomes very thick opposite the first turn, and thinner afterwards. Its apex is expanded into a process named *infundibulum*, which is arched over and covered in by the blind apex of the tube or the cupola. This terminal portion is rather of a semifunnel form, the cavity turned towards the lower part of the cochlea. The modiolus does not appear to be a distinct structure, but rather the space circumscribed by the inner wall of the tube of the cochlea. Consequently, we find that it appears of a larger diameter in the space corresponding to the first turn of the cochlea, and that it diminishes in proportion as the coils of the cochlea become contracted; therefore, the diameter of the modiolus as it ascends within the second coil is much diminished. The infundibuliform expansion of the apex, which looks downwards and towards the apex of the cochlea or the cupola, is best seen by opening the cochlea from its under surface. The centre of the modiolus is traversed by a number of canals for branches of the auditory nerves and blood-vessels. These canals open by foramina on its surface, and correspond to fine canals on the lamina spiralis. One of these canals is larger than the rest, and is named the *tubulis centralis modioli*, and passes upwards to the infundibulum.

The *lamina spiralis* is a very thin plate of bone, whose breadth is increased in the recent state by membrane; it is wound spirally, like the thread of a screw, round the modiolus, into which its inner margin is inserted. Its outer margin in the dry bone is free, but in the recent state the membrane is continued from it to the outer wall of the tube, which it thus divides into two semicylindrical tubes, termed *scalæ*, and between which it forms a perfect partition. The breadth of the osseous portion of this lamina decreases as it ascends in the tube; and, if we suppose it unrolled from off the modiolus and extended, it would represent an isosceles triangle, the base below, the apex above. The latter, which is very narrow, stands out from the modiolus in the form of a hook (the *hamulus of the lamina spiralis*). This hamulus is attached to the inner surface of the apex of the cochlea; its inner or concave border is opposite the concavity of the infundibuliform termination of the modiolus, is free and unattached to it, and thus leaves a circular opening, which communicates with the two scalæ. This will be more particularly noticed presently. The membraneous portion of this lamina which completes the septum is, on the contrary, broader above than below, and, if separated and unrolled, would also represent an isosceles triangle, with the base above corresponding to the apex of the former, and its apex below at the base of the osseous triangle. This lamina spiralis, both in its osseous and membraneous portions, is composed of two thin plates, between which the cochlear nerves and vessels are distributed.

The two secondary cavities, into which the cochlear tube is divided by the lamina spiralis, are called *scalæ*. One is superior and external, and is named the *vestibular scala*, because it directly communicates with the vestibule; the other is larger, is internal and inferior, and is named *scala tympani*, because it communicates with the tympanum through the fenestra rotunda. In the recent state, however, this communication is closed by membrane. A section of either of these scalæ, made at right angles to its axis, is of a semicircular form. Although these scalæ are separate through the entire of their extent, yet they communicate with each other near the summit of the cochlea, over the hamulus, by a small opening common to both, named by Breschet *helicotrema*. The manner in which this communication comes to exist is this. The osseous lamina spiralis is inserted by its concavity into the modiolus; but superiorly it parts from it, and its inner or concave edge stands out like a beak from the central axis. This beak or hamulus corresponds to the infundibulum, and thus the two concavities leave a space between them which is the helicotrema, and by means of which the two scalæ, though previously perfectly separated, communicate with each other.

Near the termination of the scala tympani, at the fenestra rotunda, is a small foramen, the opening of the *aqueduct of the cochlea;* the other end of which presents an expanded opening upon the lower border of the petrous bone, near the jugular fossa: it is merely a canal for a small vein.

The *membrane lining the labyrinthic cavity.*—This is not to be confounded with the membraneous labyrinth itself, from which it is not only perfectly distinct, but separated by a fluid. The lining membrane is extremely delicate, and of a fibro-serous character. One surface is closely adherent to the bone, and acts the part of an internal periosteum. The other or free surface is smooth, and secretes a semi-fluid, the *perilymph* or *aqua Cotunnii.* The foramen rotundum is closed by three membranes; externally by the mucous lining of the tympanum, a central proper membrane, and an internal reflection from the membrane under consideration, which is from thence continued into the scala tympani, from which it is prolonged, through the helicotrema, into the scala vestibuli, and so into the vestibule and semicircular canals. The lamina spiralis, by this arrangement, receives a covering from this fibro-serous membrane. One surface is covered by the membrane of the scala tympani, the other by that of the scala vestibuli. At the external free margin of the lamina spiralis these two membranes meet, and are extended to the outer wall of the tube, thus completing the partition between the two scalæ. The cochlea is richly supplied with nerves, and the spiral lamina is the principal seat of their distribution. The nerves having escaped from the sides of the modiolus by the apertures already noticed, diverge between the bony plates and the two layers of membrane of which the spiral lamina is composed.

The *membraneous labyrinth* is not so extensive as the osseous labyrinth, as it does not enter the cochlea; it is also much smaller than

that portion of the osseous labyrinth to which it corresponds, and from the walls of which it is separated by the perilymph. The membraneous labyrinth is itself filled by a fluid which might be termed the fluid of Scarpa; it is called the endolymph by Breschet. The membraneous labyrinth consists of, first, the common sinus; second, the sacculus; and, third, the membraneous semicircular canals.

First. The *common sinus*, or *vestibular ventricle*, is an elongated, laterally compressed pouch, which occupies the posterior part of the vestibule; the semicircular tubes are continuous with it, and open into it by five orifices; it floats in the liquor Cotunnii or perilymph, and is distended by the liquor Scarpæ or endolymph.

Second. The *sacculus vestibuli* is much smaller than the sinus; is round, and situated inferior and anterior to the sinus to which it adheres, but whether they communicate or not has not been determined.

Third. *Membraneous semicircular canals* have precisely the same form as the osseous tubes, and present the same number of ampullæ or ovoid vesicles. They are of course smaller than the bony canals within which they are contained, and from the walls of which they are separated by the perilymph; they are themselves distended by endolymph. A question has arisen as to whether there exists anything in the human ear analogous to the solid calcareous concretions found in the internal ear of the osseous fishes, and which have been named *otolithi*. It would appear from the researches of Breschet that such are represented in the ear of man by a powder composed of carbonate and phosphate of lime, to which he has given the name of *otoconia*. This powder is collected into two masses observable on the sinus and saccule. Huschke describes the grains as crystalline, small, six-sided columns: others consider them as oval. W. Jones found that the greater number had their longest diameter equal to that of the globules of the human blood, or about 1-3000th of an inch. Breschet regards them as of service in communicating to the nervous expansion a more vivid and energetic impression than a simple liquid could effect. The development of these bodies bears a considerable relation to the medium which the animal inhabits, being solid and stony in the aquatic and pulverulent in the ærial.

As the visual apparatus is supplied with different nerves, possessed of different properties or endowments, so is the acoustic. The essential or the special nerve of sense is the portio mollis of the seventh pair. Sensibility to the whole organ, and motor power to the muscles of the ossicula auditus, and a sympathetic connexion with the velum palati, with the nose and eye, and with the system generally, are imparted by the connexion between the fifth pair, the sympathetic, the glosso-pharyngeal, and portio dura nerves; filaments from which form a delicate net-work in the tympanum, named the tympanic plexus; while the external ear and meatus are also partly supplied from the cervical plexus. These nerves have been already individually examined (*see* Nervous System); we shall here consider them collectively, and in reference only to this organ.

The *auditory nerve* has been named portio mollis from its softness. Having arisen in the manner already described (page 527), it enters the meatus auditorius internus, and, having arrived at the situation where this passage is interrupted by a bony septum, divides into two branches, an *anterior* larger branch for the cochlea, a *posterior* smaller for the vestibule and semicircular canals. Breschet states that the neurine filaments, in penetrating into the interior of the several membraneous pouches, are accompanied by a sheath furnished by the pouch itself. The membrane is here folded inwards on the nerve, forming an internal projection or imperfect septum, more remarkable in the ampullæ than in the saccule or sinus. The nerves of the ampullæ then divide into numerous fine branches, which, forming a nervous membrane, covers the septum and adjacent wall of the ampullæ. In the case of the sinus and saccule, the nerve is first expanded in a fan-like form, and, having penetrated the membrane, resolves itself into a nervous layer like the retina, which lines these cavities.

The *vestibular nerve*, or the posterior division, immediately separates into three sets of fasciculi, superior, middle, and inferior. The superior pass through the minute foramina of the pyramidal eminence into the superior ventricle of the vestibule, and are expanded on the sacculus communis and on the ampullæ of the perpendicular and horizontal semicircular canals. The middle set pass through the macula cribrosa into the anterior ventricle, and expand on the sacculus proprius: and the posterior set pass through the posterior wall of the vestibule, and are lost on the ampullary dilatation of the oblique semicircular membraneous canal.

The *cochlear nerve* resembles a flat tape rolled on itself lengthways. It passes downwards to the depression at the bottom of the internal meatus, corresponding to the base of the axis; it here divides into a number of fine filaments, which enter the small bony canals leading from these foramina into the substance of the axis, and, bending nearly at right angles, pass between the osseous plates forming the lamina spiralis. The first filaments are the longest; they gradually diminish in length according as the spiral lamina upon which they are distributed contracts in breadth. The nerve divides into numerous minute branches, which anastomose with one another, and spread out into a delicate nervous membrane, or, according to Treviranus and Gittsche, terminate in the form of papillæ.—(*See* Breschet's *Recherches Anat. and Physiol. sur l' Organe de l' Ouie.* Paris, 1836.)

Blood-vessels of the labyrinth are derived principally from the arteria auditiva interna, a branch either of the basilar or of the superior cerebellar artery. Its presence is constant, but its precise origin uncertain. It enters the internal meatus along with the seventh pair, and divides into two branches, the cochlear and the vestibular; the former, passing into the modiolus, gives off one branch, the arteria centralis modioli, which passes through the central canal of the axis as far as the apex of the cochlea. The other branches pass through the spiral tract of holes, and radiating anastomose at the external margin of the

osseous zone. From the loop thus formed more numerous branches arise, run parallel for a short distance, and, uniting, form the second anastomosing loop, from which capillary branches run, which ultimately terminate in a venous sinus lodged between the layers of the outer portion of the membraneous spiral lamina. The vestibular artery supplies the vestibule and semicircular canals; a few tubular branches are also very generally derived from the posterior auricular and occipital arteries.

The absorbents of the labyrinth have not been demonstrated; their existence is inferred from analogy.

The *facial* or *portio dura nerve* enters the meatus internus along with the auditory, and is said to communicate with it at the bottom of this canal (*see* page 540). I have lately seen this communication very distinctly in the elephant. From the superior depression in the meatus this nerve enters the aqueduct of Fallopius, which leads first forwards and outwards to the hiatus Fallopii, where it is joined by the superior petrosal branch of the Vidian, and presents a ganglionic enlargement. It then bends at an acute angle backwards and a little downwards to the tympanum, forming an eminence on its posterior wall, above the fenestra ovalis, and finally descends vertically to the stylo-mastoid foramen. In this course, therefore, through the aqueduct, it makes two bends or turns; one is abrupt and angular, and in a horizontal plane, close to the superior surface of the petrous bone, which covers it, but which can be easily removed. The second is a gradual and round turn from the upper to the inner and posterior wall of the tympanum. From its ganglionic swelling at the junction with the Vidian one or two delicate filaments pass backwards into the meatus towards the portio mollis.

The *chorda tympani* may be regarded either as proceeding from this ganglion, or as the continued petrosal nerve from the Vidian. It accompanies the portio dura nearly to the stylo-mastoid hole, then leaves it in an acute angle, ascends in a bony canal which opens into the tympanum by a small foramen behind the pyramid, and close to the tympanic ring; then passes forwards, invested by mucous membrane, between the handle of the malleus and long crus of the incus, across the tympanum, communicating with delicate filaments of the fifth nerve on the membrane, and escapes from the lower and anterior angle of the cavity by a fine bony canal by the side of the Glasserian fissure in the glenoid fossa. In the aqueduct the portio dura also sends off a fine filament to the stapedius muscle.

The *tympanic plexus* is a delicate net-work, described by Breschet and Arnold, and chiefly formed by the tympanic branch of the glosso-pharyngeal, named the nerve of Jacobson. This arises from the petrous ganglion of the glosso-pharyngeal, enters the tympanic canal, which opens on the lower surface of the petrous bone, between the carotid foramen and jugular fossa; it leads upwards into the tympanum, and opens into the groove on the promontory, and from the upper part of this groove leads upwards and forwards between the tensor tympani

muscle and the aqueduct of Fallopius, and opens on the upper surface of the petrous bone, anterior and external to the hiatus Fallopii. This nerve, shortly after its origin, is joined by a filament from the pneumogastric and from the superior cervical ganglion of the sympathetic. In the tympanum its filaments separate and reunite in the tympanic plexus. This sends branches to the membrana, the fenestra ovalis, and to the lining of the tympanum; also branches to the Eustachian tube, some of which pass out of this tube into the carotid canal, and communicate with the carotid plexus of nerves. The continued tympanic nerve then enters the superior part of the tympanic canal, escapes from it into the superior petrosal groove, and passes forwards between the petrous bone and spinous portion of the sphenoid. It is now named lesser superior petrosal nerve, and joins the Otic ganglion on the side of the inferior maxillary nerve. From this ganglion a small filament passes to the tensor tympani muscle.

From a review of the complex structure of the ear we may infer the uses of the several parts. The auricle collects and concentrates the sounds which fall upon it; and, by the motions of the head and spine, it can be turned in every direction to receive them. In animals this is chiefly effected by the muscles which move this part. The meatus externus conducts and reflects from its sides the sonorous undulations to the membrana tympani, which is thereby thrown into vibrations, and these are transmitted by the chain of bones to the membrana vestibuli, and partly to that of the foramen rotundum, through the air and fluid which the tympanum contains. The Eustachian tube, by admitting air into this chamber, favours these vibrations, as well as the motions of the ossicula: it may also allow the escape of such sonorous impulses as strike on the walls of the labyrinth, and which might produce an echo or confusion of sound. The mastoid cells may also contribute to this effect, as well as lighten the bone. Finally, the impressions impinge on the membraneous labyrinth on which the sentient nerves are expanded, and these convey the impressions to the sensorium. Sonorous undulations, also, which strike the bones of the head and face, and the teeth, are transmitted through these solid structures to the temporal bone, especially to the cochlea, on which numerous auditory nerves are expanded.

PART IV.

ANATOMY OF THE OSSEOUS SYSTEM.

UNDER THIS HEAD WE MAY CONSIDER THE ANATOMY OF THE BONES, LIGAMENTS, AND JOINTS.

CHAPTER I.

DESCRIPTION OF THE BONES.

SECTION I.

GENERAL OBSERVATIONS ON THE OSSEOUS SYSTEM.

THE osseous structure is the hardest in the body; it is composed chiefly of phosphate of lime, with a little carbonate deposited in a cartilaginous substance, which is perfectly organized, and well supplied with blood-vessels for its nourishment and growth.

The bones present great variety of figure, and are commonly classed into the *flat*, *long*, and *irregular*. They support and protect the softer tissues, give the general form to the whole body, as well as to its different parts; and they also serve as the passive organs of locomotion, affording a series of levers by means of which the muscles effect the various motions and actions of the body.

When all the bones are connected by their ligaments, the collection is called a *natural skeleton;* when united by art an *artificial skeleton.* The skeleton is divided into the trunk and extremities.

The *trunk* consists of the middle part and two extremities. The middle of the trunk is formed by the vertebral column and the thorax. At the upper extremity of the trunk is the head, at the lower the pelvis.

The *vertebral column* consists of twenty-four vertebræ, which are divided into three classes according to the three regions, viz., seven cervical, twelve dorsal, and five lumbar.

The *thorax* or *chest* is formed before by the sternum, which in the adult consists of two pieces, with the xiphoid appendix; on either side by the twelve ribs; and behind by the dorsal vertebræ.

The *head* comprises the cranium and the face. The *cranium* or *skull* is composed of eight, or, according to some, of eighteen bones, viz., the frontal, the two temporal, the two parietal, the occipital, the ethmoid, and the sphenoid. To these may be added the ten following, viz., the two small turbinated bones of the sphenoid or of Bertin, and the four auricular bones in each temporal bone, which latter have been already described in the anatomy of the ear.

The *face* is divided into the upper and lower jaw. The *upper* consists of thirteen bones, viz., the two superior maxillary, two palatine, two lachrymal, two nasal, two malar, two inferior turbinated bones, and the vomer. To these may be added the sixteen teeth. The *lower jaw* consists of the inferior maxillary bone, which contains sixteen teeth. Some consider the os hyoides as an appendix to the bones of the face: this bone, however, has been already noticed in the description of the larynx.

The *pelvis* is the lower extremity of the trunk; it consists of the sacrum, the os coccygis, and the two ossa innominata.

The *superior* or *thoracic extremities* are composed each of four parts: the shoulder, which consists of two bones, the clavicle and scapula; the arm, of the humerus; the forearm of two, the radius and ulna; and the hand, which is subdivided into the carpus, metacarpus, and fingers. The carpus consists of eight small bones, the metacarpus of five, and the fingers of fourteen, each consisting of three phalanges, except the thumb, which has only two.

The *inferior* or *abdominal extremities* are each divided into three parts: the thigh, which consists of but one bone, the femur; the leg, which consists of three, the patella, tibia, and fibula; and the foot, which is divided into three parts, the tarsus, metatarsus, and toes. The tarsus consists of seven irregular bones, the metatarsus of five long bones, and the toes of fourteen, each consisting of three phalanges, except the great toe, which has only two.

In the adult skeleton, therefore, the number of essential bones amounts to two hundred, namely: eight in the cranium, fourteen in the face, twenty-four in the spine, twenty-six in the thorax, four in the pelvis, sixty-four in the upper extremities, and sixty in the lower. If to these we add the two bones of Bertin, the eight ossicula auditus, and the thirty-two teeth, the total will be two hundred and forty-two, excluding, of course, the os hyoides and the sesamoid tubercles. This number is, however, variously stated by writers, some bones being separated into more parts by some authors than by others. Thus some consider the sternum as consisting of three pieces, and each os innominatum also of three; others, on the contrary, diminish this number

by regarding the sternum as one, the sacrum and coccyx as one, also the occipital and sphenoid bones as one.

Although bone is the principal constituent of the human skeleton, yet cartilage is also extensively employed in some parts as auxiliary to, and in others as a substitute for it. In the earlier periods of embryonic life it is almost the sole agent in forming its outline, as true bone is not produced in the first instance; the skeleton, at that period, being like all other parts, made up of elementary cells connected together by a soft blastema. These cells soon become cartilaginous, and in this tissue ossification commences by many points, rapidly extends, and gradually imparts the stability and firmness necessary in the framework of the future being. Some parts also retain more or less of cartilage through life, and in some situations and organs it is permanently employed instead of true bone. In the cartilaginous fish the skeleton is wholly composed of it, and in many other animals also it is largely employed in its formation. As the human skeleton, then, is formed partly of bone and partly of cartilage, these two tissues must be intimately connected and cooperate in function; we shall, therefore, consider them together, although they differ from one another in many essential respects.

Cartilage is found in different situations in the animal body. In the first place it forms, in the young being, the greater portion of the skeleton, imparts to it sufficient firmness, and preserves its proper form, while it serves as the nidus for the deposition of bone. Such cartilage is termed *temporary*. Secondly, it covers the articular ends of the long and irregular bones, and forms an important element in the joints. Such are named *encrusting cartilages;* they are also called *permanent*. In some situations these answer the office of bone, as the costal cartilages in the forepart of the thorax, and are even superior to it, on account of their elasticity. The parietes of the larynx, trachea, and bronchi, also the external auditory meatus, and the septum and alæ nasi, are formed of cartilage, which in these situations is thin and expanded, and has been named by some *membraniform cartilage*. Thirdly, in some situations the true cartilaginous tissue is intermingled with fibrous tissue, and is then named *fibro-cartilage;* this tissue is composed of fasciculi of white fibres, the interstices being filled with true cartilage cells, connected together by cellular tissue. These fibro-cartilages present great diversity in structure and consistence according as one or other element predominates; they are elastic, like cartilage, but stronger, and more tough and resisting; they are found in different situations, and answer different purposes; they contribute to form thecæ and trochleæ for tendons; they adhere circumferentially to the margins of some articulations, and thereby deepen their cavity. Such are named cotyloid, or glenoid. Others are *interarticular*, that is, not adhering to, but interposed between the ends of the bones in certain joints: others of this class adhere to the opposed surfaces, as in the sterno-clavicular articulation, the pubic symphisis, and between the bodies of the vertebræ. The Eustachian tubes, the external ears

or auricles, the palpebræ, and the epiglottis, all belong to this tissue, and owe their consistence and elasticity to its presence. The epiglottis also possesses some yellow elastic tissue.

Cartilage, when examined in a mass, appears of a white or pearly hue, especially the articular and the temporary cartilages; but the permanent, the membraniform, and the fibro-cartilages, often present a yellowish tint; it is smooth, in many situations polished and glistening, and opaque, but, when divided into thin laminæ, is semitransparent. It is a very dense and strong tissue, but admits of being cut with a sharp knife; it yields to pressure or torsion, but is resilient and highly elastic. These properties peculiarly adapt it for covering the articular ends of the bones, rendering the motions of the joints light and easy, and breaking or lessening the effects of those concussions to which the body is necessarily exposed. The same properties retain the parietes of the larynx, trachea, and meatus auditorius, in a permanently open state.

When a thin lamina of cartilage is examined with magnifying powers, it is found to be composed principally of a clear, homogeneous, or hyaline substance, or matrix, which contains a number of minute cells scattered through it at irregular intervals. These cells or cartilage corpuscles are of different forms, oval, oblong, polygonal, and more or less flattened. Their parietes, in some instances, are indistinct, and the cells appear as hollowed out of the matrix; in others they are membraneous, and blended with the connecting cellular tissue. The cells contain nuclei and nucleoli; some also have oil globules and some granular matter; their average diameter is 1-1500th part of an inch; they are sometimes isolated, sometimes grouped in clusters. In the temporary cartilages those cells near the new bone are larger than those near the surface; the latter are long, slender, and parallel to the long axis of the cartilage. At first the matrix appears more homogeneous or structureless, but, as the ossific changes are about to occur, the cells enlarge, become more distinct, contain oil globules, and the intercellular tissue appears opaque, yellowish, and fibrous. In the articular or encrusting cartilage the cells near the surface are flattened and parallel to it; those deeper or nearer the bone are narrow, oblong, and vertical; hence, when an articular cartilage is cut or broken in a line perpendicular to the surface, the fracture appears striated or columnar. This arrangement must render the cartilage more resistant and elastic in that direction in which weight and pressure are most likely to operate. The free surface of these articular cartilages is generally considered as covered by a fine epithelium, continued from the synovial membrane. This structure, however, cannot be demonstrated by dissection or maceration; it is rather inferred from analogy and from pathological appearances. This membrane can be traced from the margins of the bones over the borders of the articular cartilage, but the eye can follow it no further. The articular cartilages have no tendency to ossify; but in cases of chronic rheumatism or chronic arthritis, the consequence of injury or disease, they are frequently ab-

sorbed, and the bone becomes covered by a hard, ivory, porcellaneous, or enamel-like coating, which is often grooved or channelled in the direction in which motion took place. In the costal and laryngeal cartilages the cells are of large size ; those near the surface are flat, and parallel to it ; those more internal are oblong and radiating. The matrix is clear, except where fibres have been developed ; it is there opaque and yellowish. These cartilages are prone to the ossific change. The aural and nasal cartilages are much less dense ; they are more opaque and yellow, more flexible and elastic, and are very seldom changed to bone. The matrix of the cells is very fibrous, the fibres interlacing in every direction. The same structure prevails in the fibro-cartilages, which bodies possess great strength and toughness, combined with flexibility and elasticity ; neither have these any tendency to ossify.

Cartilage, according to Schwann, is developed in the following manner. A transparent intercellular tissue, or blastema, is first formed, much softer than the future matrix. In this, nucleated cells are seen at a very early period ; these increase in size and number ; their growth is chiefly endogenous, that is, young cells are produced within others, whilst the parietes of the latter become increased in thickness, or become blended with the matrix. The intercellular or hyaline tissue, at first but small, increases in quantity and consistence. In this, new cytoblasts are developed, from which proceed new cells with nuclei ; and in some situations the matrix becomes fibrous.

All cartilages, except the articular, are covered by a fibrous membrane named perichondium. This adheres very intimately to the tissue, and in the fibro-cartilages is prolonged into its interstices. Nerves cannot be traced by dissection into cartilage, and it appears to possess but little sensibility. In disease, however, of the articular cartilage, pain is often excruciating ; in such cases, however, it is not improbable that the osseous and synovial tissues are either directly or sympathetically engaged. In the normal state cartilages appear nearly extravascular ; they are nourished by the vessels of the adjoining textures. In the joints a vascular circle surrounds the margin of the articular cartilage, but the vessels are not prolonged into it. In the temporary cartilages, when the ossific process is in progress, red vessels can be traced through the former, and these freely admit injection. In thick cartilages, as in those of the ribs, canals may be seen which contain blood-vessels, particularly if ossification be in progress.

Cartilage contains about one-fourth part of its weight of water ; when dry it is transparent, and of an amber colour ; its solid portion consists of chondrin and gelatin, and small proportions of different mineral substances. Cartilage is resolved, by long boiling, into the proximate animal element named chondrin, which has a close analogy to gelatin, but is distinguishable from it. Like it, it is soluble in boiling water, and partially coagulates on cooling, and dries into a transparent glue ; but these latter changes are less perfect, and require a longer time than in the case of pure gelatin ; neither is it precipitated when

in solution, by tannic acid, but is by acetic acid, alum, and acetate of lead, substances which do not affect gelatin. Fibro-cartilages always, and the temporary cartilages only after ossification has commenced, yield gelatin as tendons do under long-continued boiling. The ashes of incinerated cartilages yield in 100 parts: carbonate of soda, 35.07; sulphate of soda, 24.24; chloride of sodium, 8.23; phosphate of soda, 0.92; sulphate of potash, 1.20; carbonate of lime, 18.37; phosphate of lime, 4.06; phosphate of magnesia, 6.91; oxide of iron, 1.00.

Bone is the firmest and hardest material in the body, and contains less fluid in its composition, except, perhaps, some portions of the epidermoid tissues; it is opaque and whitish, with more or less of a reddish tint, which varies in different situations and at different ages. The more dense and old the bone is, the whiter is its colour; the softer and younger it is, the more the red or vascular hue prevails; if dried, without previous maceration, it retains the red colour, but otherwise it becomes white. Bones, though very firm, possess a certain degree of flexibility and elasticity, and much more in the young than in the old. The ribs retain these properties through life. Bones are covered by a compact fibro-cellular membrane, named periosteum; this adheres closely to them, is prolonged into their tissue, and serves as an extensive surface for the minute divisions of the nutrient arteries.

The physical properties of bone depend on the peculiar combination of an inorganic earthy material with the animal or organized texture. These two ingredients can be separated and examined distinctly. By slow and careful calcination all the animal matter of a bone may be burned out, and a white, brittle, earthy mass will remain, of the form of the original, but much lighter, about one-third of the weight being lost. Long-continued boiling, also, will extract the greater portion of the animal matter, and the earthy will remain of the form of the original. By macerating a bone for a short time in dilute muriatic or nitric acid, all the saline and earthy parts will be dissolved out, and the residual animal matter will present a tough, flexible, and elastic substance, somewhat like cartilage, retaining the shape and size of the bone. The firmness and density of bone, therefore, depend on the earthy ingredients; but the cohesion between the latter, and the general flexibility and elasticity of the whole, depend on the animal matter. In young bones the latter prevails, in old ones the former; hence the latter are more liable to fracture than the former. The proportion of these elements varies also in different bones in the same individual; thus the petrous bones abound in the earthy material; the long bones of the limbs and the flat bones of the head possess more of it than the vertebræ or ribs; and the humerus and femur more than the bones of the forearm and leg. The earthy ingredients of bone constitute, on an average, about two-thirds of its weight, or about 66 parts in 100. The 66 parts of bone-earth consist of about 51, phosphate of lime; 11, carbonate of lime; 2, fluoride of calcium; 1, phosphate of magnesia; and 1, soda and chloride of sodium. The animal matter amounts, on an average, to about 34 in 100 parts, and resembles cartilage in some

respects; it differs from it, however, in being more soft and flexible, and being resolved by boiling chiefly into gelatin instead of chondrin.

Bones present upon their surface numerous foramina and various irregularities. The foramina are chiefly for the transmission of blood-vessels: one or two of some size may be observed in the shafts of the long bones, slanting obliquely into them, and dividing into numerous canals, which lead to the medulla. The artery which this foramen conducts is incorrectly named the "nutritious artery of the bone;" it ought rather to be of the "medullary membrane." This canal in the humerus, tibia, and fibula, slants downwards, but in the femur, ulna, and radius, upwards. The whole surface of a bone is studded with minute holes, which transmit small vessels and fibres of the periosteum; and around the articular ends of bones are several large openings for the entrance of vessels.

The irregularities on the surface of bones are either grooves or pulleys, or processes, such as spines, crests, tubercles, &c. These are for the attachment of ligaments and muscles, and are better marked in the adult and in the male than in the child or the female; they bear a ratio to the general muscular development, and greatly depend on the previous habits of the individual, as to labour or muscular exertion, or the contrary. Most of the long bones consist for many years of three or more pieces, the shaft and the epiphyses. These separations admit of ossification taking place in a greater number of situations; they also insure increase in length and development in proper proportions in the different regions of the bone. The form of the different bones is too variable to admit of any accurate arrangement; they are, however, generally classed into long, flat, and irregular.

The *long bones* are placed in the extremities; they are very strong and hard, more or less cylindrical. Their centre or shaft is small, and composed of a shell of dense, compact tissue, which is partly hollow within, and filled with fat or marrow, thereby combining strength and lightness, and affording sufficient space for the muscles and other soft parts; whereas the ends are expanded into large and irregularly shaped surfaces, which are covered by smooth, encrusting cartilage, and articulate with other bones. The shafts are not perfectly cylindrical or straight; they are usually a little twisted or curved, as if they were bent when in a soft and growing state; and they generally present a prominent ridge or spine on the concavity, or on that side of the curve in which the bone would be most likely to yield under weight or pressure. The long bones support the weight of the body, and serve as levers whereby the muscles execute the various motions of the limbs. The humerus and femur, tibia and fibula, radius and ulna, are the longest of this class; the phalanges of the fingers and toes are the shortest.

The *flat bones* are those of the cranium and pelvis, also the scapulæ and the ribs. The latter, though long, yet are flattened, and resemble in structure the bones of this class. The flat bones are thin, and composed of two plates or tables of compact tissue and an intervening

osseous reticular texture, named diploe. The tables in the cranial bones are much more dense than in the others, and the inner is so hard as to be named vitreous. The flat bones assist in bounding cavities and protecting important organs; they also present an extended surface for muscular attachment.

The *irregular bones* are the vertebræ, those of the carpus and tarsus, of the base of the skull and of the face, and are very variable in form and texture. They are generally composed of reticular tissue, covered by a thin, compact lamina. Those of the face are more dense and compact than the others. These bones afford strength and solidity of support, as in the head; in other situations they also admit of slight and divided motions, and obviate or diminish the shocks and concussions to which the frame is constantly exposed.

If any bone be divided, the section exhibits two forms of *osseous tissue*, the compact and the cancellated. The *compact* is on the external surface, in the form of a hard, dense lamina, of considerable strength and resistance, but varying in different bones. The *cancellated* presents a loose, spongy texture, and is composed of fine bony plates or laminæ, meeting and crossing in every direction, so as to form a reticular or cancellated net-work, the cells communicating freely. The strongest bars or laminæ run perpendicular to the surface, that is, in the direction best adapted to resist weight or pressure. The compact tissue always encloses the cancellated (the turbinated bones in the nose are an exception), and is continuous with it, so that the two tissues are essentially the same; and, though apparently so different, yet they only differ in the degree of condensation. The most compact tissue, when examined with magnifying powers, is by no means a homogeneous solid, but is full of minute cells or spaces, and it gradually shades off into the cancellated, which occupies the central portion and the expanded extremities of the long bones. In the flat bones the compact tissue is in the form of two plates or tables, the cancellated tissue or the diploe intervening; and the irregular bones consist of a mass of the cancellated, invested by one continuous lamina of compact.

The canals in the interior of the shafts, and the cells in the cancellated tissue, are lined by a fine membrane, which secretes and supports the *medulla*. Like the periosteum, it is very vascular, and contributes to the support and nourishment of the bone. These two membranes not only cover the external and internal surface of the bone, but also accompany the nutrient vessels along the canals, which traverse even the most compact portions, and are continuous with each other. The medulla, or marrow of bones, is a soft, oily, or adipose secretion, lodged in the fine vesicles of the membrane; it serves to fill the spaces in the bone which are left for the purpose of lessening its weight. In birds these spaces in most of the bones are filled with air; in the human subject the cells and sinuses in some of the bones of the head and face are similarly occupied. In the fœtus the bony cells are filled with a reddish serous fluid instead of marrow. As bone is so

highly organized a tissue it must be furnished with blood-vessels; these are numerous, and admit of injection and demonstration; they divide on the periosteum, and enter the bony tissue by many branches, which ramify through it in every direction. Large branches can be traced into and through the cancelli in the extremities of the bone. In the compact tissue capillary vessels run in those minute tubes, named Haversian canals, which branch through the bone, and inosculate with each other and with the cells in the cancelli. The large vessel which slants obliquely through the shaft divides into ascending and descending branches; these end in anastomosing capillaries, which supply the medullary membrane and the interior of the bone. The larger veins in bones usually occupy distinct canals, which are larger than the arterial, and present occasional dilatations like sinuses. In the irregular bones, as the vertebræ, and in the flat bones of the cranium, the venous canals can be very distinctly traced in the cancellated structure, as accurately described by Breschet, and open on the surface by distinct foramina. Although nerves cannot be followed into the osseous structure, yet there can be no doubt of their existence in it, and this opinion is confirmed by the pain which attends disease on the surface or in the substance of a bone.

Osseous tissue consists essentially of a vascular membrane containing a minute capillary net-work of blood-vessels. This membrane is involuted into numerous canals and cells; its surface is thereby extended to a great degree, and the nutrient vessels conducted through every part of the bone. The bony particles, when examined under high magnifying powers, appear to be as very minute granules cohering together. These granules are aggregated into spiculæ, and various other forms. Between these are numerous pores, which extend from the surface as minute canals into the substance; these anastomose with adjacent ones, and here and there dilatations or *lacunæ* exist. From these other canals pass off still deeper, and join similar lacunæ, and thus permeate the entire bone, running in every direction, and communicating freely with each other. These lacunæ have been most minutely described by Mr. Tomes (*see* Encyclop. of Anat. and Phy., art. "Osseous Tissue;" also Todd and Bowman's Physiology of Man, page 110). Their figure is that of a flattened oval; their length is about 1-1500th of an inch; and they are about half as wide, and one-third as thick. The tissue, thus studded by thousands of these lacunæ, which are mostly parallel to the surface, admits of being easily split into parallel laminæ, particularly in old bones, after maceration in dilute acid. This lamellated structure is generally very evident near the external and internal surfaces of the long bones; they are partly concentric, but here and there the lamellæ run into one another. In some of the flat bones, after long maceration and drying, the lamellæ can often be easily separated by a needle, breaking the connecting rods or Haversian tubes, which permeate the bone and communicate with the lacunæ. In sections of long bones concentric rings can often be separated by the same process. All this apparently complex arrangement

appears to depend on the disposition of the vascular membrane, and the necessity of extending it through all parts of the texture. The entire vascular surface in any of the long bones may be considered as "consisting, first, of the outer surface or the periosteum; second, of the inner surface or medullary membrane; third, of the Haversian surface. The exterior or periosteal layer derives its nourishment from the periosteum; the lacunæ of this layer face that surface, and the pores of the superficial ones open upon it. The lacunæ of the medullary laminæ face that surface towards the medullary canal. This layer is variously folded to form the plates and fibres of the cancelli. The Haversian surface is an involution of the outer and inner surfaces, and unites these with one another. When a vessel enters the compact tissue from the external surface, it carries with it a sheath of bone from the periosteal layer. The laminæ of this sheath face inwards towards the vessel, and, wherever the latter penetrates, it is accompanied by this sheath from the periosteal layer, or by offsets from it; and when it enters the medullary canal its sheath expands into the medullary membrane."—*Phys. of Man*, page 111. An analogous arrangement exists in the cancellated tissue; each cancellus may be regarded as a small medullary cavity, containing medulla and a vascular membrane. The plates of bone forming its walls consist of fine lamellæ, among which lacunæ are scattered, and, in some, fine Haversian canals. This delicate organization and extended vascular arrangement form a striking contrast between the cartilaginous and osseous tissues. The temporary cartilages possess the form and preserve the outline of the skeleton; these continue to grow and increase in size, but the processes, grooves, and other irregularities, are not so well marked as in the future bone. Interesting changes occur in the progress of the conversion of these cartilages into bone; these constitute the *process of ossification*, and are necessarily involved in much obscurity. They have been accurately observed and minutely described by J. Tomes (Encyc. of Anatomy, art. "Osseous tissue;" also in Todd and Bowman's Phys., p. 115; and in Quain's Anat., vol. ii. p. cxlvii.) Although ossification usually occurs in cartilage, it is not to be inferred that the latter is actually converted into bone; the latter may be formed independent of the former, as in adventitious bony deposits, and in the flat bones of the head, also, there is but very little cartilage developed, and the ossific process chiefly occurs between membranes. In the temporary cartilages of the long bones, about the period of the ossific change, the cartilage cells or corpuscles are found to become arranged in nearly parallel rows or columns in the length of the bone, having between them intercellular spaces. At the ends of the columns the cells are flattened; the cells or corpuscles themselves are also separated by intercellular tissue; the parietes of the cells increase, but their central portions diminish to mere nuclei, or small granular cavities. The osseous tissue is deposited in the form of minute granules in all the intercellular tissue, which thereby becomes more dense and opaque. This is the first stage. In the second the parietes of the cells become

osseous and granular, and their central cavity disappears; and the third stage consists in the absorption of the osseous matter between the cells. By this change the columns are converted into tubes, marked by indentations, contractions, and dilatations, corresponding to the cells. These elongated tubes are the rudimentary Haversian canals, and they communicate with other similar tubes, and thus a free system of anastomoses is established. The central nuclei or cavities of the cells disappear, and there remain small spherical granules, like lymph globules, of a reddish tint. These form that reddish, semifluid mass found in young bones. These globules are considered by Todd and Bowman as a sort of blastema, for the development of blood-vessels. After the formation of the osseous tubes, small cells or lacunæ become developed, which communicate with the former. In the epiphyses an analogous change takes place; the cartilage cells or corpuscles are arranged in clusters, with intercellular tissue; ossific matter is deposited in the latter around and between these cells, and thus the large extremity of the bone is formed. In the flat bones, although the process appears to be, as it really is, between membranes, yet it is essentially the same. There is an intervening fibrous and granular tissue, apparently composed of cellular and white fibrous tissue, with numerous corpuscles or cells. The osseous granules are deposited in the intercellular tissue in the form of minute fibres, which extend in radiating directions, at the same time crossing and interlacing, so as to form a reticular texture. It also increases in thickness, and by degrees the more compact tables are formed and the numerous canals containing blood-vessels. Along the margins the membraneous tissue in the more advanced stages is thick and dense, and resembles a thin lamina of cartilage. Once ossification has commenced, it gradually extends by a repetition of the same changes; new cartilage cells, with intercellular tissue, become developed on the surface; ossific matter is deposited, and canals and lacunæ formed, and an appearance of laminated arrangement is produced; the laminæ, first formed on the inner surface of the early cancelli, are pushed outwards by succeeding ones, while a general increase takes place from interstitial growth and from addition to the surface; while at the same time longitudinal extension takes place in the cartilage between the shaft and epiphysis. While this general augmentation in size is in progress, the internal cancelli become enlarged, and open into each other, so as to form the medullary canal, with which the surrounding cancelli communicate; the medullary membrane becomes developed, and fat vesicles are formed, and a large vessel, the nutrient artery, is permanently distributed to it.

The process of ossification commences at a very early period of embryonic life, but not in all parts of the skeleton at the same time. So soon as the end of the first month, the clavicle and lower jaw are partly ossified; at the end of the second it has commenced in the shafts of the long bones of the limbs; also in the ribs, in portions of the vertebræ, of the base of the skull, and of the pelvis. From this on to the period

of birth it not only advances in these, but also extends to the other cartilages of the skeleton; and there are only a few in which the process has not commenced previous to that period, such as the patellæ, and some of those of the carpus and tarsus. The ossific process, also, proceeds much more rapidly in some bones than in others, and in some portions of particular bones. In the long bones ossification advances in the shaft much more quickly than in the epiphyses; and many years elapse before the latter are united to the former. By this plan strength is early imparted to the shafts, so as to support the muscles; and longitudinal extension, and increase in the general height is facilitated. The cavity of the cranium, of the spinal canal, the foramen magnum, and many other parts, are constituted by the slow union of several osseous pieces, whereby an equable increase in size is secured; and the sutures in the flat bones answer a similar purpose to the epiphyses in the long ones. In some bones the ossific process commences in one point, and extends from that in all directions; in others it commences in several points, and at a distance from each other. These peculiarities will be noticed in the descriptive account of the individual bones.

SECTION II.

THE VERTEBRÆ.

As the spine forms the foundation or the basis of support for all parts of the frame, it claims priority of attention; it is also the distinctive character of that large division of the animal creation named *vertebrata*, and, together with the cranium, which may be regarded as an expanded prolongation of the vertebral column, contains the great nervous centre, or the cerebro-spinal axis, on which depend so many of the superior characters of this great division of the animal kingdom.

The *vertebræ* are twenty-four in number; they belong to the class of irregular bones, are placed one above the other, and connected by ligaments so as to form one strong, yet flexible column, situated in the middle and back part of the trunk, extending from the head to the sacrum, and enclosing the spinal cord and the roots of the spinal nerves. The sacrum and coccyx, from their likeness to the true vertebræ, have been named the "false vertebræ." All the true vertebræ agree in the general outline, which is as follows. Each vertebra consists of a body and of several projections or processes. The *body* occupies the anterior central part; it is thick and spongy, and rather circular or oval; its upper and lower surfaces are flat, or slightly concave, and give attachment to the intervertebral ligaments. The margin of each is tipped with a compact white substance, and the lower surface is rather larger than the upper. Anteriorly it is transversely convex, and grooved horizontally, particularly on either side,

and is also very porous. Posteriorly it is concave, so as to form part of the spinal canal or foramen. This surface is perforated by large foramina for the escape of the venous canals, which ramify through the bone. The processes of each vertebra are nine, two lateral or the laminæ, two transverse, four oblique or articulating, and one spinous.

The *lateral processes* or *laminæ* arise, one on each side, by a sort of *pedicle* from the posterior part of the body; they pass backwards, bounding the sides of the spinal hole, and unite posteriorly in the spinous process; they are broad behind, but narrow where they join the body, being grooved out above and below into a notch. The inferior of these is the larger. The laminæ form the lateral and posterior portions of the spinal arch or foramen for the spinal cord. The roots of these laminæ, or the pedicles, are considered by some as separate portions; they form the common point of support for the other processes, and separate the superior from the inferior notch. These *notches*, when the vertebræ are joined, form the intervertebral holes for the passage of the spinal nerves.

The *spinous process* is the most projecting part of the vertebra in the posterior median line; its base is bifurcated, and passes into the two laminæ; its apex generally ends in a point or tubercle. The whole series of these processes presents the longitudinal prominent crest posteriorly named *spine.* Each process receives the insertion of tendons, and serves as a lever for the extensor muscles of the column.

The *transverse processes* arise from the roots of the laminæ, or rather from the pedicles, and are directed outwards on each side; they serve for the attachment of tendons, and in the dorsal region they also support the ribs.

The *articular* or *oblique processes* are four in number; they arise from the roots of the transverse, or from the pedicles; two ascend, two descend. They are covered with cartilage, and articulate with the corresponding processes of the vertebræ above and below. The two superior are directed more or less backward, and the two inferior more or less forward; their direction is rather vertical, therefore contrary to that of the surfaces of the bodies, beyond the level of which they extend, so that their articulations correspond to the intervertebral ligaments.

The *spinal hole* or *canal* is bounded by the body and processes; it is more or less triangular.

The *processes* are of a more compact structure than the body, which is very light and cellular. A vertebra is generally developed by three points of bone, one for the body, and one for each side for the laminæ and articulating processes: sometimes a fourth point is deposited in the root of the spinous. This process is seldom found ossified in the fœtus, but remains cartilaginous for some time. In addition to these three principal ossific nuclei there are several accessory points or epiphyses, namely, one for the summit of the spinous and of each transverse process, and one for each surface of the body. These latter form thin plates, the rim or margin of which project horizontally beyond

the front and sides of the bone. The primary nuclei appear very early in uterine life. From the lateral are gradually formed the articulating, the transverse, and the spinous processes. About five or six years of age the laminæ join the bodies; the accessory epiphyses do not appear until fourteen or fifteen years of age, and are not completely joined to the body until twenty-five. These are the general characters of all the vertebræ, but each of the three classes presents some peculiarity.

The *lumbar vertebræ* are five. These are the largest in the column. The *body* of each is very broad transversely compared with its height, and is deeper before than behind. Its upper and lower surfaces are flat, and bordered with hard, projecting edges, which render it concave from above downwards on its forepart and sides. The *laminæ* are thick, broad, but short. The *notches*, particularly the lower, are very large. The *spinous process* is broad, flat, and square, and ends not in a point, but in a thick, rough border. The *articulating processes* are oval, strong, and vertical. The superior are concave, look inwards and a little backwards; the inferior are convex, look outwards, and a little forwards; are nearer to each other than the former, and are, therefore, received into those of the vertebra below. The *transverse processes* are long, thin, and horizontal, or directed slightly backwards, and are anterior to those of the dorsal vertebræ, but posterior to those of the cervical. They are sometimes tipped with a tubercle or epiphysis, like a rudimentary abdominal rib. Some consider all these transverse processes as lumbar or abdominal ribs, and regard as true transverse processes, analogous to those in the dorsal region, those small, flattened tubercles which project upwards and backwards from the superior articular processes. These are also sometimes named posterior transverse processes. The spinal foramen is triangular, and larger than in the back. The body of the fifth lumbar vertebra is cut off very obliquely below, so as to be much deeper before than behind. Its transverse processes are short, thick, strong, and rounded. The inferior articular processes are flat, directed forwards, and are further asunder than in the other vertebræ.

*Fig. 75.**

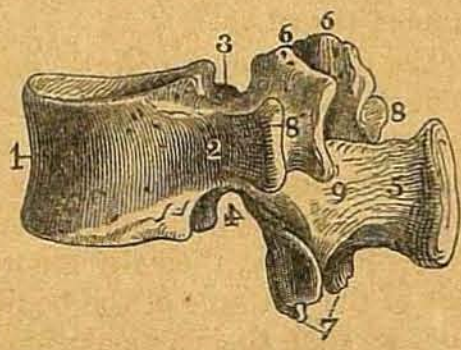

The *dorsal vertebræ* are twelve in number, and of an intermediate size between the cervical and lumbar: they decrease from the first to the fourth, and then increase to the last, so that the fourth and fifth are the smallest. The *body* is thicker behind than before, and, in most, longer from before backwards than transversely, flat above and

* Lateral view of a lumbar vertebra. 1. The body. 2. The lamina or pedicle. 3. The superior intervertebral notch. 4. The inferior intervertebral notch. 5. The spinous process. 6. The superior articular processes. 7. The inferior articular processes. 8. The transverse process. 9. Tubercle projecting from the articular process, which gives attachment to the sacro-lumbalis and longissimus dorsi muscles.

below (except that of the first, whose upper surface is concave from side to side); convex anteriorly, and very concave posteriorly. On either side it presents two small depressions or notches, covered with cartilage: the superior is the larger. When the vertebræ are conjoined, two of these notches form an oval depression for the head of each rib. The *laminæ* are broad and thick; the *notches* are large, and anterior to the oblique processes; the inferior is much larger than the superior; the *transverse processes* are long and large, and directed backwards. On the front of each, near the end, except of the two last, there is a small depression covered with cartilage for articulating with the tubercle of the rib. The *oblique processes* are vertical, the superior directed backwards, the inferior forwards. The *spinal hole*, or canal, is small and oval. The *spinous processes* are long, of a prismatic or triangular form, bent downwards very much, and imbricated; also tubercular at their extremities. The first vertebra has the body long transversely, and on either side a full depression above for the head of the first rib, and half of a similar cavity below for the upper part of the head of the second rib. Its spinous process is thick, long, and horizontal, and its articular processes are oblique. The tenth has also a full depression on its body for the tenth rib; the eleventh and twelfth in like manner: these two last also want the articulating depressions on the transverse processes, and they somewhat resemble the lumbar vertebræ in the shape of their body, and inferior articular processes.

Fig. 76.*

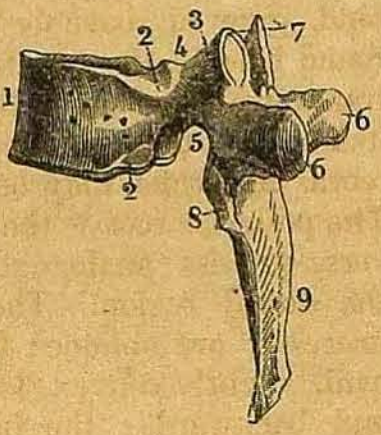

The *cervical vertebræ* are seven in number, and smaller than the others. Their *body* is long transversely, a little deeper before than behind. The lower surface is concave from behind forwards; the upper is larger or broader, and concave from side to side. The structure is more compact than in the dorsal and lumbar. The *laminæ* are long and narrow, sharp and small superiorly, round and large inferiorly, so as to overlap those

Fig. 77.†

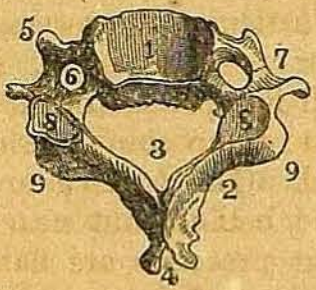

* A lateral view of a dorsal vertebra. 1. The body. 2. 2. Articular depressions for the heads of the ribs. 3. The lamina. 4. The superior intervertebral notch. 5. The inferior intervertebral notch. 6. The extremity of the transverse process, marked by an articular depression for the tubercle of a rib. 7. The superior articular processes directed backwards. 8. One of the inferior articular processes looking forwards. 9. The spinous process.

† The superior surface of the fourth cervical vertebra. 1. The upper surface of the body, concave from side to side. 2. The lamina. 3. The spinal hole. 4. The spinous process. 5. The transverse process, perforated near its base by 6. The vertebral hole. 7. The superior intervertebral groove or notch. 8. The superior articular process. 9. The posterior surface of the inferior articular process.

below. The *spinal hole* is large and triangular. The *notches* are small, and anterior to the articular processes in all, except on both surfaces of the atlas, and of course on the upper surface of the second. They are nearly all of equal size above and below. The *spinous process* is short, horizontal, and bifid. The *transverse process* is short, bifid, grooved above for the nerves, and perforated near its base by a round hole for the vertebral vessels. It is on a plane anterior to the transverse processes of the back or loins, and appears, on account of its foramen, to have a second or anterior root from the body of the vertebra, and which may be considered as the rudiment of a cervical rib. The posterior root is the true transverse process, analogous to those in the dorsal region. The *articular processes* are oblique; the superior oval, slightly convex, look upwards and backwards; the inferior, also oval, are concave, and directed downwards and forwards.

Fig. 78.*

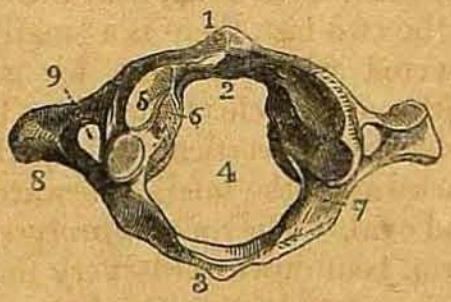

The first cervical vertebra, or *atlas*, differs from the remaining, in being a mere bony ring, without any distinct body or spinous process. The anterior or smaller portion of this ring is tubercular before, but presents posteriorly a smooth, concave, oval, and articulating surface, which receives the odontoid process of the second vertebra. The superior and inferior margins of this ring give attachment to ligaments. The posterior arch of the ring of the atlas is round and thick, with a tubercle instead of spine, for the attachment of the recti muscles. The *spinal hole* is very large, and divided into two by the transverse ligament, which arises from two tubercles placed on the inner side of the superior articulating processes. The anterior portion, small, receives the tooth-like process of the second vertebra; the posterior forms the spinal canal. The *laminæ* are thick and round behind, but near the articulating processes are flattened and grooved above for the vertebral artery and first cervical or suboccipital nerve, and below for the second

Fig. 79.†

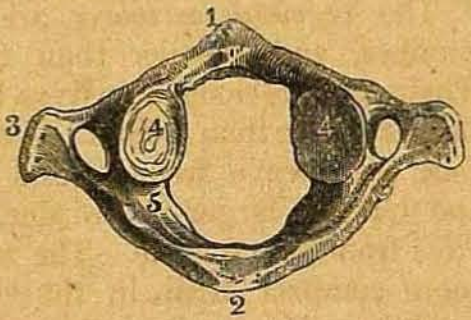

* The superior surface of the atlas. 1. The anterior tubercle projecting from the anterior arch. 2. Articulating surface on the posterior surface of the anterior arch for the odontoid process of the second vertebra. 3. Posterior tubercle projecting from the posterior arch. 4. The spinal hole. 5. Superior articular surface. 6. Tubercle for the attachment of the transverse ligament. 7. Groove for the vertebral artery and first cervical nerve. 8. The transverse process. 9. The vertebral foramen.

† The inferior surface of the atlas. 1. The anterior tubercle. 2. The posterior tubercle. 3. The transverse process. 4. The inferior articular surfaces. 5. The intervertebral notch or groove for the second cervical nerve.

cervical nerve. Before these notches are the *articular processes.* The superior are horizontal, concave, oval from before backwards, look upwards and inwards, and receive the occipital condyles; the inferior are nearly flat or slightly concave, circular, and inclined a little inwards and downwards. The *transverse processes* are long, and end in an obtuse point; the anterior root is slender, the posterior is long and large. The hole between these is larger than in the other vertebræ, and is directed upwards and backwards. From this a groove for the vertebral artery winds backwards round the superior articular process. In the adult the atlas is very compact. In the fœtus its ossification takes place from five points, one for the anterior arch, two for the posterior, and one for each lateral part.

The *axis*, or second vertebra, is remarkable for the depth of its *body*, which has anteriorly a central ridge between two depressions for muscles; and from its upper part there rises, by a sort of a neck constricted posteriorly, a large, round, dentiform (*odontoid*) process, the forepart of which is received into the small articulating cavity on the anterior arch of the atlas, while posteriorly it presents a small, smooth convexity, which moves against the smooth surface of the transverse ligament of the atlas. The apex is rather pointed; to it and to the sides of this process the lateral or check ligaments are attached. The *laminæ* are very strong. The superior *notches* are behind, the inferior before the articular processes. The *spinal hole* is large and heart-shaped. The *spinous process* is forked and very strong; its under surface is channelled. The superior *oblique processes* are slightly convex, nearly horizontal, and look a little outwards; they are situated rather on the body of the bone and at each side of the odontoid process, on a plane anterior to the other articulating processes of the spine. The inferior are smaller, flat, and look downwards and forwards. The *transverse processes* are short, arise from the outside of the superior articular processes, are bent downwards, and are not bifid. The hole is directed obliquely upwards and outwards. This vertebra in the fœtus has an additional or fourth point of ossification in the odontoid process. It is articulated directly with the atlas and the third vertebra, and indirectly with the occipital bone.

Fig. 80.*

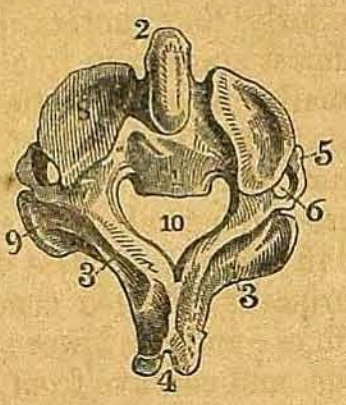

The *seventh* cervical vertebra is large; its spine is very prominent, and not bifid. Its transverse process is seldom perforated, as in the other cervical vertebræ. When there is a foramen in it it transmits

* The upper surface of the axis, or second cervical vertebra. 1. The posterior surface of the body. 2. The odontoid process. 3. The laminæ. 4. The spinous process. 5. The transverse process. 6. The vertebral foramen. 7. The superior intervertebral notch. 8. The superior oblique or articular process. 9. The inferior articular process. 10. The spinal hole.

the vertebral vein, and not the artery. In this vertebra an additional point of ossification is found in the pedicle which connects the processes to the body; this sometimes increases beyond the transverse processes of the vertebral column, so as to resemble a supernumerary or a cervical rib.

Thus each class of the vertebræ is distinguished from the others by certain characters impressed upon the bodies and processes of each; so that, from an inspection of any one of these parts only, even when detached, we can determine to which class the bone belonged. Thus the *body of a lumbar* may be recognised by the following. It is large, the transverse diameter is greater than the antero-posterior, and one-third more than the vertical; deeper before than behind; the upper and lower surface flat or slightly concave. The *body of a dorsal* is of intermediate size between the lumbar and cervical; the antero-posterior diameter equal to, if not longer than, the transverse; deeper posteriorly than anteriorly; very concave behind, but prominent and almost angular in front; flat above and below; and, above all, two small depressed facettes on the posterior part of each upper and lower border for the heads of the ribs. The *body of a cervical* is small, compact, and firm, on a lower level compared with the processes; flat before and behind; thicker at each side than in the middle, deeper before than behind; greatest diameter transverse; and, above all, the upper surface is rendered concave from side to side by two lateral lips or ridges; and the lower surface is smaller, a little convex from side to side, and concave from before backwards, in consequence of the greater depth in front; so that these bodies fit into each other, and are thereby secured against displacement.

In the *lumbar and dorsal vertebræ* the *pedicles* are strong, and directed backwards; in the *cervical* they are directed outwards, and grooved above for the superior intervertebral foramen or notch. The superior and inferior *notches* are nearly equal in the cervical, but in the dorsal and lumbar the inferior notch, or that beneath each pedicle, is much larger than the superior. The size of the *intervertebral foramina*, and the depth of these notches, are also proportioned to the size of the spinal nerves and ganglions, and to the venous canals which pass through them.

The *laminæ of a lumbar* are very thick, strong, and short, and their vertical diameter is the greatest. Those of a *dorsal* exhibit much the same characters, but in a less degree; and those of a *cervical* are narrow and long, thinner above than below, and placed very obliquely. That of the upper vertebra overlaps or imbricates that of the lower, and thereby protects the side of the spinal canal from injury or penetration. This imbrication is increased in extension of the neck and head.

The *transverse* or *costiform processes of a lumbar* are long and thin, directed outwards and a little backwards. Those of a *dorsal* are on a plane posterior to the lumbar; are very long and thick, directed

outwards, backwards, and a little upwards; enlarged at their outer end, and there presenting anteriorly and superiorly a small cartilaginous depression for the tubercle of the rib. Those of a *cervical* are short and bifid, directed outwards, forwards, and a little downwards; are on a plane anterior to those of the lumbar and dorsal, and on a level with the body, so as to form a broad surface of support for the various organs in the neck. They are pierced near their base by a foramen for the passage of the vertebral artery and vein, with their accompanying nerves from the sympathetic, and are deeply grooved superiorly for the passage of the spinal nerves.

The *oblique* or *articulating processes in a lumbar* are strong and cylindrical. The superior are concave, look inwards and backwards; the inferior are closer to each other, are convex, look forwards and outwards, and are received into the former. Projecting from the superior are the flattened tubercles, named by some the posterior or true transverse processes. Those of a *dorsal* are plane, vertical laminæ; the superior directed backwards and a little outwards, the inferior forwards and a little inwards. Those of a *cervical* are very oblique; the superior looking upwards and backwards, the inferior downwards and forwards; this form and aspect admit of considerable motion.

The *spinous process of a lumbar* is a broad, square, vertical plate, thick below and behind, projecting horizontally backwards. That of a *dorsal* is long, prismatic, or triangular, grooved below, sharp above, directed obliquely downwards and backwards, and ending in a tubercle. These processes overlap or imbricate, and thereby resist extension. That of a *cervical* is short, bifid, triangular, grooved below, and nearly horizontal.

The *spinal hole* or *canal* is largest in the *neck*, particularly in the transverse direction, and of a triangular form, the base in front. In the *back* it is smaller, and circular or oval. In the *loins* it is larger than in the back, but less than in the neck, and is somewhat triangular; but these bodies of the vertebræ are a little concave posteriorly. The dimensions of the canal are proportioned partly to the size of the cord and of the nerves connected with it, and partly to the degree of motion enjoyed in each region.

The column is covered *anteriorly* by the anterior common ligament, and in the neck by the recti and longi muscles; in the back by the last-named muscles above, below by the vena azygos, aorta, &c.; and in the loins by the crura of the diaphragm, the aorta, vena cava, and sympathetic nerves. The anterior surface in the neck is convex forwards and broad, being formed both by the bodies and transverse processes; narrow and concave forwards in the back, and again convex and broad in the lumbar region. *Posteriorly* the column presents, in the median line, the spinous processes, short, horizontal, and separate in the cervical and lumbar, but close and bent over one another in the dorsal region. On each side of these are the vertebral grooves, which are wide in the neck, but deep and narrow in the back and loins. These during life are filled

by the extensor muscles, and, therefore, the spinal region presents a very marked contrast with its condition in the skeleton. In the former there is a median groove or channel, at the bottom of which is the row of spinous processes, and on either side is a thick, longitudinal convexity, formed by the extensor muscles, and covered by the trapezius and latissimus dorsi; whereas in the skeleton the spinal ridge projects in the median line beyond the lateral grooves. These great lateral muscular convexities afford considerable protection to the posterior aspect of the column against external injury or violence. The sides of the column are separated from the posterior surface in the neck and loins by the articular processes, and in the back by the transverse processes. Each side presents to our view portions of the bodies of the vertebræ, with their deep transverse or lateral grooves, and those in the back with the articular fossæ for the ribs; and posterior to these the intervertebral holes, the transverse and oblique processes, and the laminæ. The apertures between the latter are closed in the recent state by the yellow ligaments, and covered by muscles. Outside the posterior grooves in the neck and loins lie the oblique or articular processes; but in the back are the transverse processes, which in this region are on a plane posterior to those in the neck and loins. The intervertebral, or the holes of conjunction in the dorsal and lumbar regions, are before the transverse processes; but in the neck between them, and in the back they are behind the cavities for the heads of the ribs; and they are all anterior to the oblique processes, except those between the atlas and the axis.

The length of the vertebral column is generally about a third of that of the whole body. The lumbar and cervical regions are nearly equal, and each about half the length of the dorsal; the

Fig. 81.*

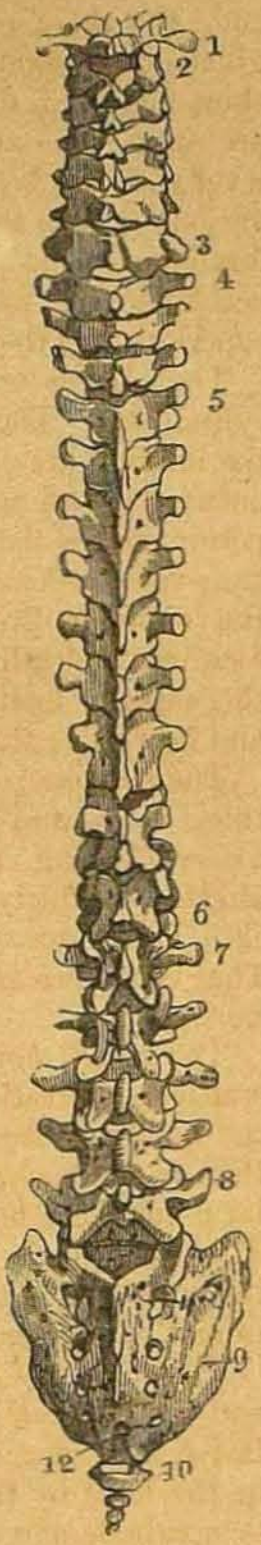

* The vertebral column, sacrum, and coccyx, seen upon their posterior surface. 1. The atlas, or first cervical vertebra. 2. The axis, or second cervical vertebra. 3. The seventh cervical vertebra, or vertebra prominens. 4. The first dorsal vertebra. 5. The fourth dorsal vertebra. 6. The twelfth or last dorsal vertebra. 7. The first lumbar vertebra. 8. The fifth or last lumbar vertebra. 9. The posterior surface of the sacrum. 10. The coccyx, consisting of four pieces. 11. One of the posterior sacral foramina. 12. The inferior aperture of the sacral canal.

latter commonly measures from ten to twelve inches, and each of the former about five or six. Its general form is that of a pyramid, the base below; but when accurately examined it will be found to represent *three pyramids.* The *first* has its apex in the third cervical vertebra, surmounted by the axis and atlas, and its base is in the first dorsal, which is also the base of the *second* pyramid, whose apex is in the fifth dorsal; where also is the apex of the *third pyramid*, whose base is at the sacrum; the vertebræ diminishing in size about the fourth and fifth dorsal. The column is convex anteriorly in the neck, concave in the back, and convex in the loins. These curvatures are caused partly by the different thickness of the bodies of the vertebræ before and behind, but principally by that of the intervertebral ligaments in these three situations. A perpendicular line passed through the centre of the apex and base of the column will be found anterior to the dorsal, and posterior to the cervical and lumbar vertebræ. In the dorsal region there is generally a lateral curvature also, which is usually concave to the left side. This direction of this curve has been by some ascribed to the pressure of the aorta on the left side; by others, and with more probability, to the effect of muscular action, for as the muscles of the right arm are the most used, the points of the spine to which these are attached will be drawn towards that side. In the several violent exertions also, such as pulling forcibly, the body is usually bent to the left side. It has been remarked by some that this curvature is either totally absent or reversed, that is, convex towards the left side, in those persons who are named left-handed, whose left arm is more powerful and dextrous, and, therefore, more used, than the right.

*Fig. 82.**

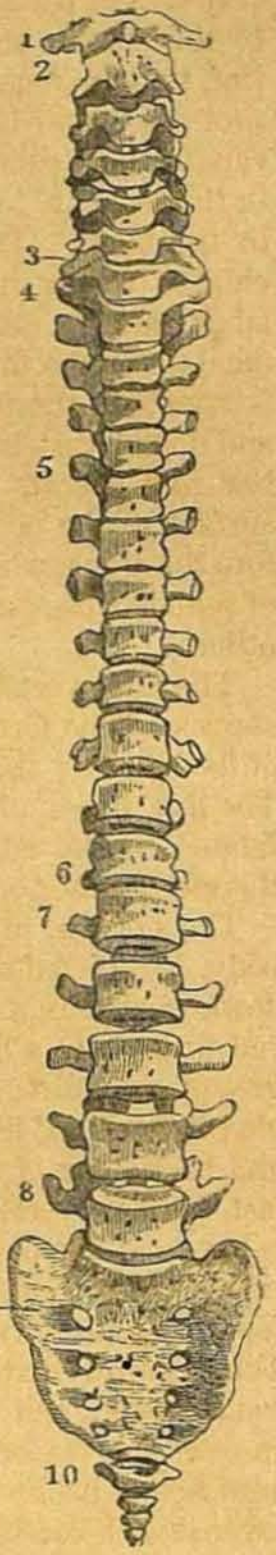

The spine supports the head and chest, and combines strength with lightness and flexibility. It serves as the centre of all the motions of the

* The vertebral column, sacrum, and coccyx, seen upon their anterior surface. This plate exhibits the general pyramidal form of the vertebral column, as well as the secondary pyramids. 1. The atlas, or first cervical vertebra, forming the summit of the vertebral column. 2. The axis or second cervical vertebra. 3. The seventh or last cervical vertebra. 4. The first dorsal vertebra. 5. The fifth dorsal vertebra. 6. The twelfth or last dorsal vertebra. 7. The first lumbar vertebra. 8. The fifth or last lumbar vertebra, articulated to the sacrum, and forming the base of the vertebral column. 9. The sacrum. 10. The coccyx.

trunk, and transmits the weight it bears to the sacrum and pelvis; it gives insertion to numerous muscles, and lodges and protects the medulla spinalis in the spinal canal. This canal is large and triangular in the neck and loins, round and contracted in the back. The spinal column in the child is longer in proportion than in the adult, and is nearly straight or perpendicular: in the fœtus the pyramidal figure is reversed, the base being in the cervical and dorsal vertebræ, the apex in the lumbar and sacral. The epiphyses on the surface of the bodies do not exist; therefore the spine, when dried, presents a series of rounded osseous nodules, one below the other.

The false vertebræ are the sacrum and coccyx. The former consists in the child of five pieces; the latter of three or four. The five bones of the sacrum are consolidated in the adult into one, which is, therefore, described as one bone.

The *sacrum*, in the erect position of the body, is directed obliquely backwards and downwards; is a little curved, the lower end being bent a little forwards. The degree of curvature, however, is very variable; it is placed like a wedge in the upper and back part of the pelvis, between the last lumbar vertebra above, the coccyx below, and the ossa innominata on either side. Of a triangular form, the *base* or superior extremity resembles a vertebra, looks upwards and forwards, is very broad transversely, and presents in the middle an oval surface or body cut off obliquely from before backwards and upwards, and covered with cartilage for articulation with the last lumbar vertebra. Its anterior projecting edge is named the *promon-*

Fig. 83.*

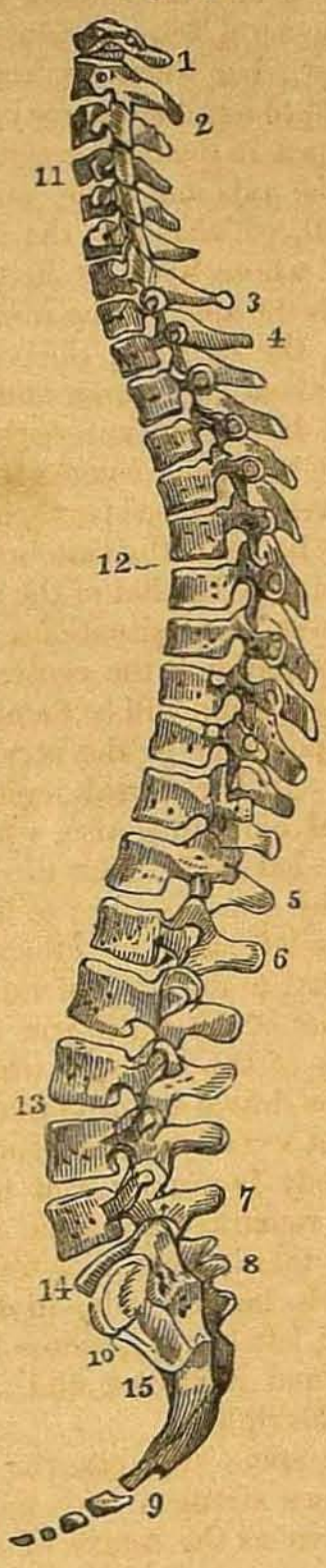

* Lateral view of the vertebral column, sacrum, and coccyx, to shew the curvatures. 1. The atlas, or first cervical vertebra. 2. The axis, or second cervical vertebra. 3. Spinous process of the seventh cervical vertebra, or the vertebra prominens. 4. The first dorsal vertebra. 5. The twelfth or last dorsal vertebra. 6. The first lumbar vertebra. 7. The fifth or last lumbar vertebra. 8. Tuberosities on the posterior surface of the sacrum, corresponding to the spinous processes of the vertebra. 9. The coccyx, composed of four pieces. 10. Lateral articulating surface of the sacrum, or facies auricularis. 11. Convexity presented anteriorly by the cervical region of the vertebral column. 12. Concavity presented anteriorly by the dorsal region of the column. 13. Convexity forward

tory. Behind it is the triangular aperture of the sacral or spinal canal, and on each side is a smooth convex surface (or transverse process) directed outwards and forwards, and continuous with the iliac fossa. The lumbo-sacral nerve and the psoas muscle lie in front of it; it constitutes a portion of the upper or false pelvis on each side. On either side of the spinal canal is the *oblique* or *articular process*, concave, and looking backwards and inwards to receive the articular process of the last lumbar vertebra. Anterior to each is a groove, or notch, which contributes with that in the last vertebra to form the last of the holes of conjunction for the passage of the last of the lumbar spinal nerves. Behind the oblique processes are the laminæ, which are sharp, and give attachment to the last of the ligamenta flava. The inferior extremity, or *apex*, is directed downwards, and sometimes a little forwards, and presents a small, transverse, oval, convex surface, to articulate with the coccyx, behind and on each side of which is a small notch for the last sacral nerve. The *anterior surface* is concave from above downwards, and a little so from side to side, marked by four transverse lines, which indicate its original division into five pieces resembling so many vertebræ (hence sometimes called false vertebræ). The first of these divisions is convex, the remaining are concave. External to these lines, on either side, are the four *anterior sacral holes;* the two upper large, the two lower small; they are all round and smooth, communicate with the sacral canal, and transmit the anterior sacral nerves, veins, and arteries; grooves lead outwards from these, along which the nerves run. These holes are analogous to the intervertebral foramina, and the intermediate grooved bone to the transverse processes in the vertebral column above. External to them is a smooth, depressed surface, which gives attachment to the pyriform muscle. The *posterior* or *spinal* or *cutaneous surface* is narrower than the anterior; is convex and very rough, presenting in the median line four horizontal eminences analo-

Fig. 84.*

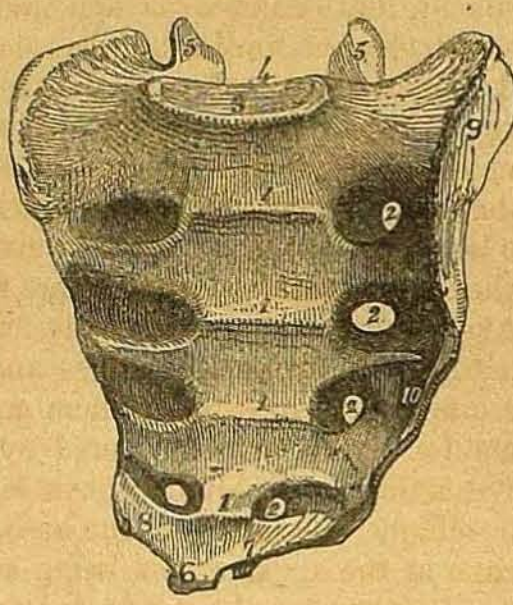

in the lumbar region of the vertebral column. 14. The sacro-vertebral angle, or promontory of the sacrum. 15. Concavity presented by the anterior surface of the sacrum.

* The anterior surface of the sacrum. 1. 1. The four transverse lines, indicating its original division into five pieces. 2.2. The anterior sacral foramina. 3. The promontory of the sacrum. 4. The articular surface for the body of the last lumbar vertebra. 5. 5. The oblique or articulating processes. 6. The inferior extremity or apex of the sacrum. 7. One of the sacral cornua. 8. The notch for the last sacral nerve, which is converted into a foramen by the coccyx. 9. The ear-shaped surface, which articulates with the ilium. 10. The thin edge which gives attachment to the sacro-sciatic ligaments.

gous to the spinous processes, which are often united into one ridge. The first process is generally prominent and distinct, the three next are joined into one ridge, but the lower part of the fourth and fifth spines are deficient, as well as their laminæ, so that the spinal canal appears as a mere triangular channel, which is only closed behind by ligament, and bounded on each side by two tubercles or *cornua*, which descend to meet similar but less developed processes from the coccyx, and convert the notches in the two bones into foramina for the passage of the last sacral nerves. These cornua are sometimes joined by bone to the base of the coccyx. At either side of the median spine is a shallow, rugged groove, the continuation of the vertebral grooves for the lodgment of the tendinous and fleshy fibres of the extensor muscles of the spine. In these grooves are the four posterior holes, opposite to, but smaller and more irregularly formed than the anterior; they transmit the posterior sacral nerves and some blood-vessels. Internal to these foramina, or between them and the spinal ridge, is a row of small tubercles, which are considered by some as representing the consolidated articular or oblique processes, being in a line with the true superior oblique processes on the base of the bone, and with the sacral cornua at the apex, which, being attached to the coccyx, may be considered as inferior oblique processes. Others regard these tubercles as the analogues of the posterior transverse of the vertebræ above. External to these foramina is another row of five tubercles analogous to the anterior transverse processes of the lumbar vertebræ, and these form the bounding line between the posterior surface and the side of the sacrum; these tubercles give attachment to ligaments. The *sides*, or iliac surfaces of the sacrum, are uneven and triangular, consisting of two portions, one superior, broad, and irregular, covered with cartilage for articulation with the ilium; the other inferior, thin, and attached to the greater and lesser sacro-sciatic ligaments. The upper or articulating portion presents anteriorly an irregular surface of a crescentic or ear-shaped form, convex forwards, and directed obliquely outwards, backwards, and a little downwards, and is covered by a thin lamina of cartilage, which is connected to a corresponding surface on the ilium; behind is a very rugged surface for the attachment of the posterior long and short sacro-iliac ligaments.

The *sacrum*, though very thick, is yet light and spongy, and covered by a thin lamina of compact substance; it is long and narrow in the male, broad and short, and more curved inferiorly, in the female. In the latter it is about four inches and a half long; its breadth above is nearly the same, but below only half an inch. Its form and curvatures, however, are very variable, and we cannot always determine to which sex a detached sacrum belongs. The sexual characters are uncertain, and are very differently stated by different writers. In the fœtus the sacrum is nearly straight, and consists of five pieces, in each of which ossification commences in several points. The three superior divisions have five points each, viz., one for the body, one for each lamina, and one for each lateral portion. The two lower

portions have three points each, viz., one for each body and one for each lateral portion. Numerous epiphyses are added during the progress of growth; they all become consolidated into one bone about twenty-six years of age.

The *ossa coccygis* are analogous to the caudal vertebræ of animals; are placed at the extremity of the sacrum, and consist of three or four, and rarely of five pieces, which in the old are often united into one or two, but in the young and adult are always distinctly divisible into three parts. We may describe these, however, as forming a single bony piece, which in the adult is triangular, and serves to prolong the curve of the sacrum anteriorly. The *base* above is broad, with a smooth, oval surface adapted to the sacrum, and on either side of this posteriorly is a small horn or process, which is also connected to the sacrum by bone or ligament. Beneath this is a notch for the last sacral nerve. The *apex* is irregularly tubercular, and gives attachment to the muscles of the rectum. The *anterior* or *pelvic* surface is smooth, supports the rectum, and is marked by two or three transverse lines, which indicate its original division into distinct pieces. The *posterior* or *spinal* surface is rough, for the attachment of muscles, and is also marked by transverse ridges and tubercles. The superior of the latter are prolonged to meet the cornua of the sacrum. The *sides* of the coccyx are thin and irregular, marked by grooves and notches, which give attachment to muscles and ligaments. The coccyx is soft and spongy; its ossification commences by four or five points; it becomes united to the sacrum earlier in the male than in the female, and is longer in the former than in the latter.

SECTION III.

THE HEAD.

THE *head* stands at the upper extremity of the vertebral column; is of a spheroid figure, compressed on the sides; it contains the brain and the principal organs of sense, and is divided into the cranium and the face.

The *cranium*, or skull, may be considered as an expansion of the vertebral canal; is of an oval figure, the narrow extremity before; it contains the brain, and is formed of eight bones, the frontal, two parietal, two temporal, the occipital, sphenoid, and ethmoid. These bones are all closely united by sutures. In some of these are small bones, called ossa triquetra or Wormii. The sutures will be described after the bones have been examined. The frontal is considered as common to the cranium and face; but the temporal, ethmoid, and sphenoid, are equally entitled to this distinction. The anterior region of the skull is named sinciput or forehead; the posterior, occiput; the lateral, the temples; the upper part, the vertex or bregma; and the lower, the

base. The frontal, occipital, ethmoid, and sphenoid bones, occupy the median line; the others are lateral and symmetrical; but the single bones also are composed of parts perfectly similar on each side of the median line.

Fig. 85.*

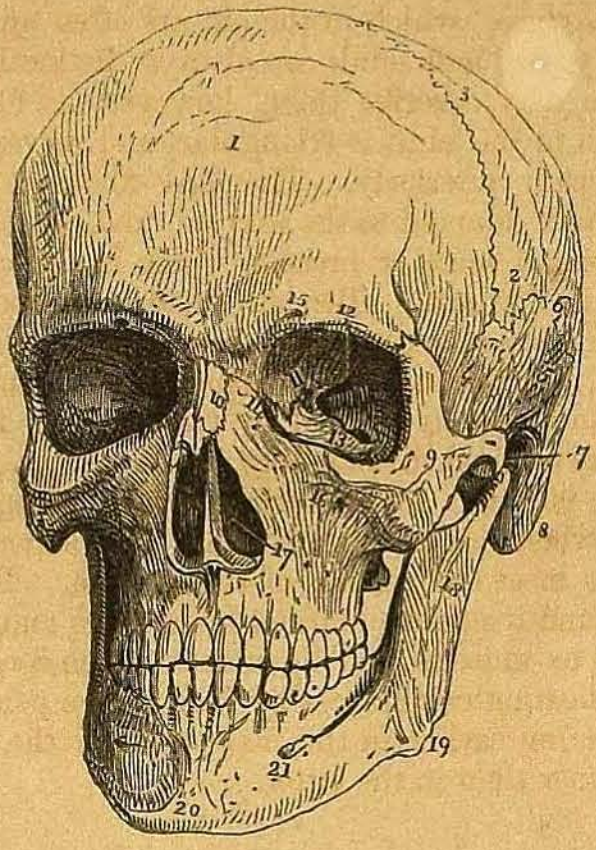

Regarding the cranial cavity as a prolongation of the spinal, completing the receptacle for the great nervous centre, the occipital bone claims our first attention.

The *occipital bone* is curved, and of a rhomboidal figure, placed at the posterior and inferior part of the cranium. It presents two surfaces, an external or posterior or basilar, and an internal or cerebral. The *external surface* is cutaneous in the superior, and basilar in the inferior half; it is convex and smooth above, and presents near the centre the great *protuberance*, of very variable size; to it the cervical ligament is connected. From each side of it leads the *superior transverse ridge*, to which the occipito-frontales and trapezii muscles are at-

* Anterior view of the skull. 1. The superior portion of the frontal bone. 2. The anterior inferior angle of the parietal bone. 3. The coronal suture. 4. The temporal surface of the great wing of the sphenoid bone. 5. The squamous portion of the temporal bone. 6. The squamous suture. 7. The external auditory meatus. 8. The mastoid process or the temporal bone. 9. The malar bone. 10. The ossa nasi. 11. The optic foramen. 12. The foramen lacerum orbitale superius. 13. The spheno-maxillary fissure. 14. The lachrymal fossa, the commencement of the nasal duct. 15. The supraorbital foramen. 16. The infraorbital foramen, situated in the canine fossa. 17. The opening of the anterior nares, divided into two parts by the septum. 18. The ramus of the lower jaw. 19. The angle of the lower jaw. 20. The symphysis of the lower jaw. 21. The mental foramen.

tached; midway between this and the foramen magnum is the *inferior transverse ridge*, to which, and to the space between it and the foramen magnum, the recti postici and obliqui superiores are attached; into the rough surfaces between the two transverse ridges the complexi and splenii capitis are inserted. From the tuberosity a spine leads down

Fig. 86.*

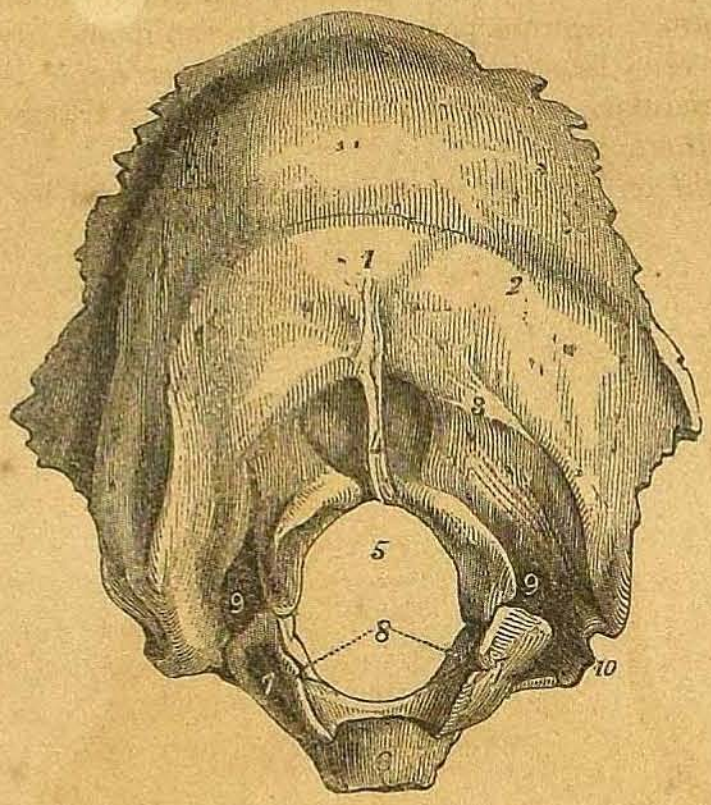

vertically in the median line as far as the *foramen magnum*. This latter is of an oval figure, and transmits the medulla spinalis and its membranes, the vertebral vessels, and the suboccipital and spinal accessory nerves. It is larger internally than inferiorly. In front of this is the *basilar process*, which is very thick and strong; it passes forwards and a little upwards into the base of the skull, to join the sphenoid bone. Its sides are rough, and contiguous to the petrous bones; it is also rough inferiorly, for the attachment of muscles and the mucous membrane of the pharynx, the roof of which it bounds. Near the forepart of the foramen are the two *condyles*, smooth and oblong processes, covered with cartilage, looking downwards and outwards, and converging anteriorly. Their anterior and inner edges are the deepest, their long axis is from before backwards, in which direction, as also from

* The external or posterior surface of the occipital bone. 1. The external or posterior protuberance. 2. The superior transverse ridge. 3. The inferior transverse ridge. 4. The external occipital spine or crest. 5. The foramen magnum. 6. The basilar process. 7. 7. The condyles. 8. Rough depression for the insertion of the lateral ligaments of the odontoid process. 9. The posterior condyloid fossa and foramen; the anterior condyloid foramen is concealed in this view by the edge of the condyle. 10. The jugular eminence.

side to side, they are convex. They are uneven internally near their centre, for the insertion of the lateral ligaments from the odontoid process; they are articulated to the atlas. Behind each of these is a fossa, in which there is generally a small foramen, through which a vein and small artery pass into the jugular fossa; and before them is another fossa, in which there is always a foramen, or a short canal, for the passage of the ninth pair of nerves. External to each condyle is the *jugular eminence*, or *transverse process*, semilunar, bounding posteriorly the foramen lacerum posterius basis cranii, and giving attachment to the rectus lateralis muscle. The *upper angle* is acute; the *edges* very irregular, as also along the sides; ossa triquetra are often entangled in the notches.

The *internal* or *cerebral surface* is concave, lined by dura mater,

Fig. 87.*

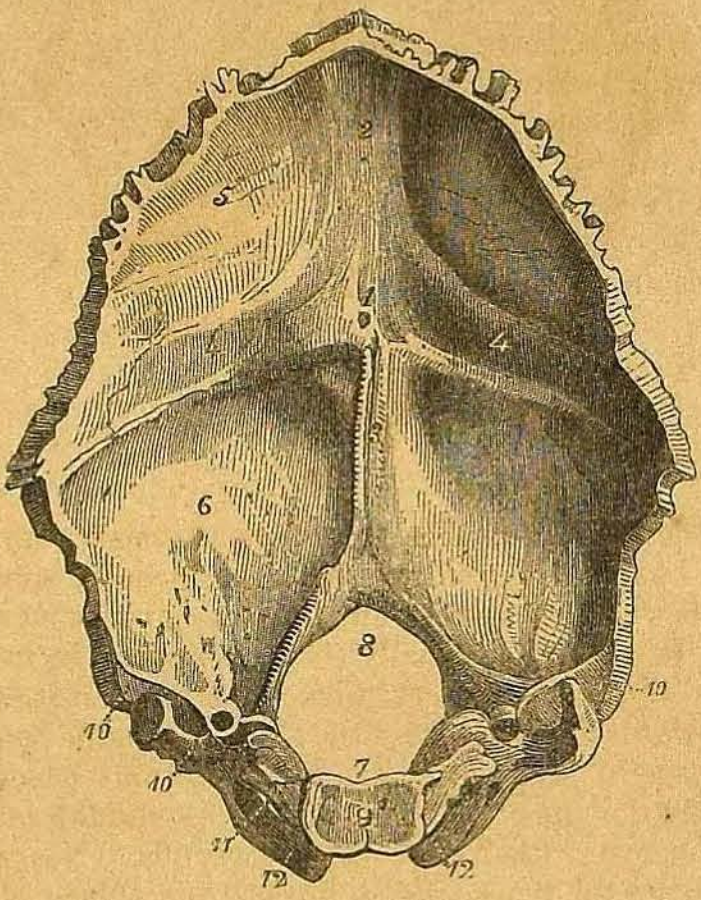

* The internal or cerebral surface of the occipital bone. 1. The internal occipital protuberance, on which rests the Torcular Herophili. 2. The superior vertical ridge, for the falx cerebri, and groove for the superior longitudinal sinus. 3. The inferior vertical ridge, for the fax cerebelli, and groove for the occipital sinuses. 4. The transverse ridge deeply grooved for the lateral sinus: to this ridge the tentorium is attached. 5. Fossa for the posterior lobe of the cerebrum. 6. Fossa for the cerebellum. 7. The upper surface of the basilar process, grooved for the pons Varolii. 8. The foramen magnum. 9. Rough surface of the basilar process which joins the body of the sphenoid bone. 10. 10. Termination of the groove for the lateral sinus. 11. The anterior condyloid foramen. 12. The condyles.

and marked by two lines, which cross about the centre or opposite the tuberosity, where there is also an internal prominence. These lines bound four fossæ; the two superior receive the posterior lobes of the cerebrum, and are marked by their convolutions; the inferior are smooth, and lodge the hemispheres of the cerebellum. To the vertical ridge is attached the falx cerebri above and the falx cerebelli below; the lower extremity of the latter is bifurcated, the upper half is grooved for the longitudinal sinus. To the transverse ridges the tentorium is attached; they are grooved for the lateral sinuses: the right groove is generally the larger. The basilar process is concave from side to side, and slanting from above downwards; it supports the pons Varolii and the basilar artery. On either margin of it is a slight groove for the inferior petrosal sinus. On each side of the foramen magnum, and towards its forepart, is a slight projection corresponding to the anterior condyloid canal. More posteriorly, and above the jugular process, is a groove for the lower extremity or termination of the lateral sinus. This bone is joined to six bones, viz., the two parietal, two temporal, the sphenoid, and the atlas. Its processes are six, namely, two condyles, two jugular, the basilar, and the tuberosity. Its foramina are five proper and two common: the proper are the magnum, the two anterior, and two posterior condyloid; the common are the foramina lacera postica basis cranii. These foramina are completed by the petrous bone; each is divided into two by an osseo-fibrous septum, the small anterior portion transmits the eighth pair of nerves, and the large posterior one, or thimble-like fossa, lodges the lateral sinus as it ends in the jugular vein. The occipital bone presents four angles. The superior is acute, and joins the two parietal bones. The inferior angle, or basilar process, is united to the sphenoid, and the two lateral angles are obtuse, and fit into the angles between the posterior and inferior angles of the parietals and the mastoid portions of the temporal bones. The occipital bone is firm and hard, is composed of two tables and intervening diploe. The external table is thick, but the internal, though thinner, is harder, and more brittle or vitreous; the two tables are so close in the fossæ that the bone is diaphanous. The spongy tissue prevails in the basilar process and condyles. It is developed from four points, one for the basilar process, one for each condyle, and one for the upper and back part.

Were we to adopt the transcendental doctrine of the anatomy of the cranium, namely, that its several bones are but expanded and modified vertebræ, we ought to consider the sphenoid and ethmoid bones as next in succession. As, however, it will be more convenient for the student to examine the parietal, frontal, and temporal first, we shall describe them in this order.

The *parietal bones* are symmetrical, and form the upper and lateral parts of the cranium; each is nearly square, convex, and smooth externally, and presents about the centre the *protuberance*, which is better marked in children. Below this is the curved *temporal ridge*,

continuous with the process of that name on the os frontis; to this the temporal aponeurosis adheres. Below this it is rough for the attachment of the temporal muscle. Of the four *edges* the *upper* or parietal is the longest; it is thick and serrated, and, with the opposite bone,

Fig. 88.*

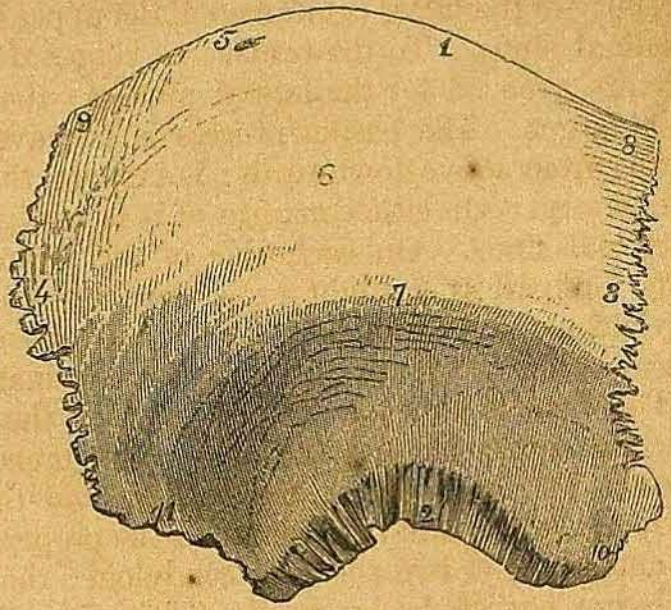

forms the sagittal suture. The *anterior* or frontal *edge* is also serrated, to join the os frontis in the coronal suture; it is slightly concave, and bevelled off externally above and internally below, to meet a corresponding arrangement on the border of the frontal bone. The *posterior* or occipital *edge* is very irregular, slightly convex, and joins the occipital bone in the lambdoid suture. In this suture small bones called ossa Wormii, or triquetra, are often found. The *inferior* or temporal *edge* is the shortest; it is concave and thin, and joins the temporal bone by the squamous suture. Of its four *angles*, the *anterior superior* is nearly right. In the child this is deficient, and the fontanelle exists. The *superior posterior angle* is somewhat rounded. Near this in general is a foramen, which transmits small vessels from the pericranium to the dura mater. The *inferior anterior* is long and curved, and joins the sphenoid bone. The *inferior posterior* is very irregular, and joins the mastoid portion of the temporal bone. The cerebral surface is marked by the convolutions of the brain, and by the branches of the middle artery of the dura mater. This vessel is in a groove, sometimes in a perfect canal or tube in the anterior inferior angle, and from this the branches pass upwards and backwards; a

* The external surface of the right parietal bone. 1. The upper or sagittal border. 2. The inferior or squamous border. 3. The anterior or coronal border. 4. The posterior or lambdoidal border. 5. The parietal foramen. 6. The parietal protuberance. 7. The temporal ridge. 8. The anterior superior angle. 9. The superior posterior angle. 10. The inferior anterior angle. 11. The inferior posterior angle.

large one ascends a little posterior to the coronal edge. Along the superior border is a groove, which, with that in the corresponding bones, lodges the longitudinal sinus: and near this in the adult skull are irregular depressions for the glandulæ Pacchioni, or the granulations

Fig. 89.*

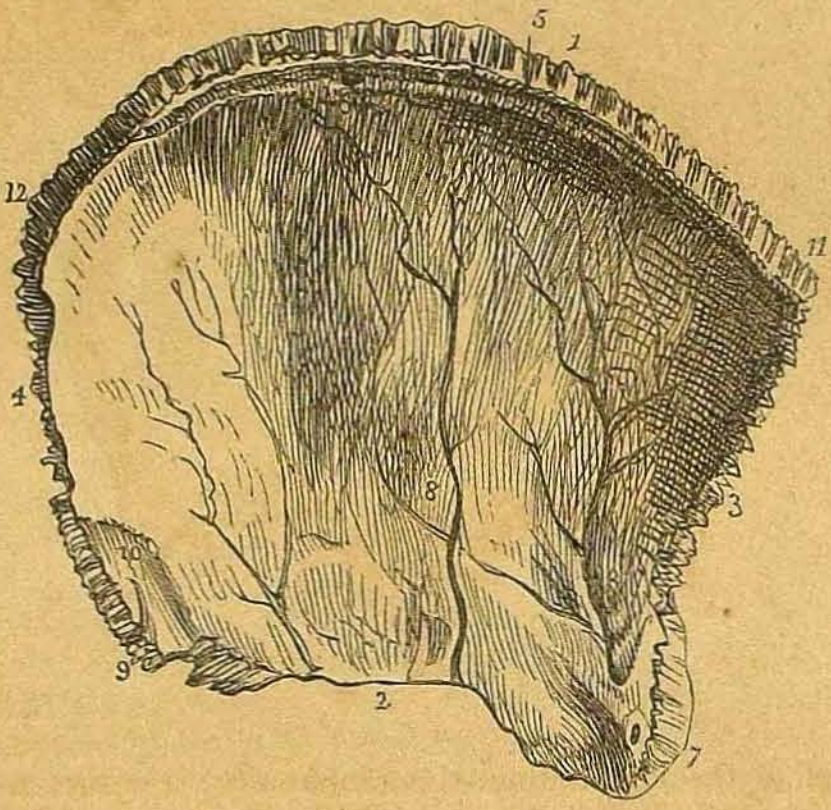

of the dura mater. The posterior inferior angle is grooved, and lodges part of the lateral sinus. The structure of the parietal bone is similar to that of most of the other bones of the cranium, viz., two tables and an intervening diploe, with the venous canals. It is developed from one point of ossification, which is in the parietal prominence; the four angles continue for some years unossified. It is joined to five bones, viz., the frontal, sphenoid, temporal, occipital, and to its fellow.

The *frontal bone* is somewhat the shape of one of the bivalve shells; is situated at the upper and anterior part of the skull; forms the forehead, part of the temples, of the orbits, and nose; it is of a semicircular form, convex and smooth anteriorly, concave posteriorly, and irregular below. It may be divided into the *superior* or *frontal* portion,

* The internal or cerebral surface of the left parietal bone. 1. The superior or sagittal margin. 2. The inferior or squamous margin. 3. The anterior or coronal margin. 4. The posterior or lambdoidal margin. 5. Part of the groove for the superior longitudinal sinus. 6. The internal aperture of the parietal foramen. 7. The anterior inferior angle of the bone. 8. 8. Grooves for the branches of the middle meningeal artery. 9. The posterior inferior angle. 10. Portion of the groove for the lateral sinus. 11. The anterior superior angle of the bone. 12. The posterior superior angle.

and the *inferior* or *orbital*. The *external surface* of the frontal bone presents in the median line a longitudinal depression; in some not very distinct; in others there is an elevation. This corresponds to the line of union of the two pieces of which the young bone consisted; it

Fig. 90.*

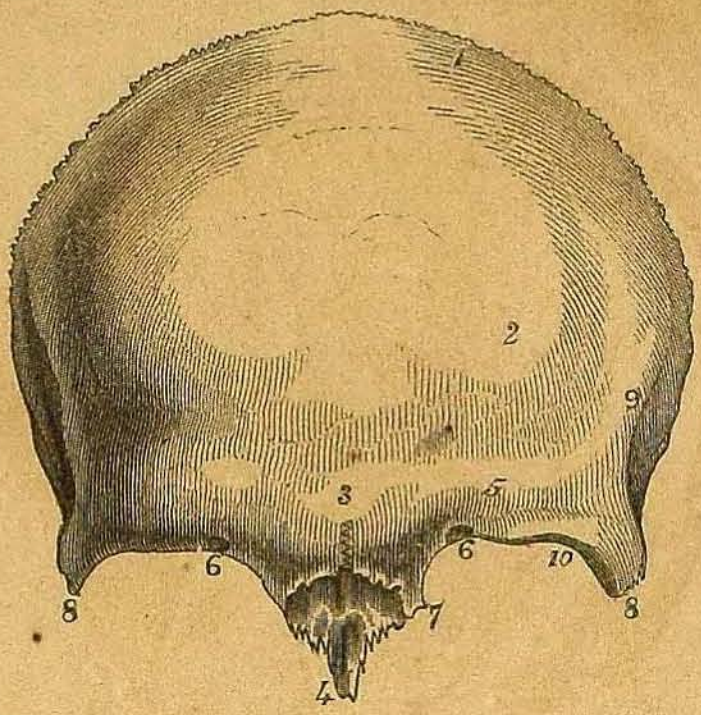

is parallel to the longitudinal sinus internally: a suture frequently exists in it, particularly below. At the lower part of this line is the *nasal prominence*, longer in the old than in the young. The bone here is frequently very porous; it terminates in a rough edge for articulation with the nasal and superior maxillary bones. From the centre of it projects the *nasal spine* or *process*, which supports the nasal bone before and the ethmoid bone behind. On each side of this is a groove, which forms part of the superior nasal fossæ. On either side of the median line of the frontal bone, and proceeding from above downwards, we observe, first, a smooth surface, covered by the occipito-frontalis muscle; second, the frontal eminence, which is particularly prominent in the young. Beneath this a slight depression, bounded below by the *superciliary arch*, towards the inner third of which is the supraorbital hole, or notch completed into a hole by a ligament, and which transmits the supraorbital nerve and vessels. From this notch a small foramen leads obliquely into the diploe of the bone. Immediately above the internal third of this arch is the prominence of the frontal sinus, and below it is the edge of the orbit, at each extre-

* The anterior or external surface of the frontal bone. 1. The coronal margin of the frontal bone. 2. The frontal eminence. 3. The nasal prominence. 4. The nasal spine. 5. The superciliary arch. 6. The supraorbital hole. 7. The internal angular process. 8. The external angular process. 9. The temporal ridge. 10. The margin of the orbit.

mity of which are the *angular processes.* The *external* is prominent, and joins the malar bone; the *internal* is thin and broad, covers some cells, and joins the unguis and the nasal process of the superior maxillary bone. Above and behind the external angular,

Fig. 91.*

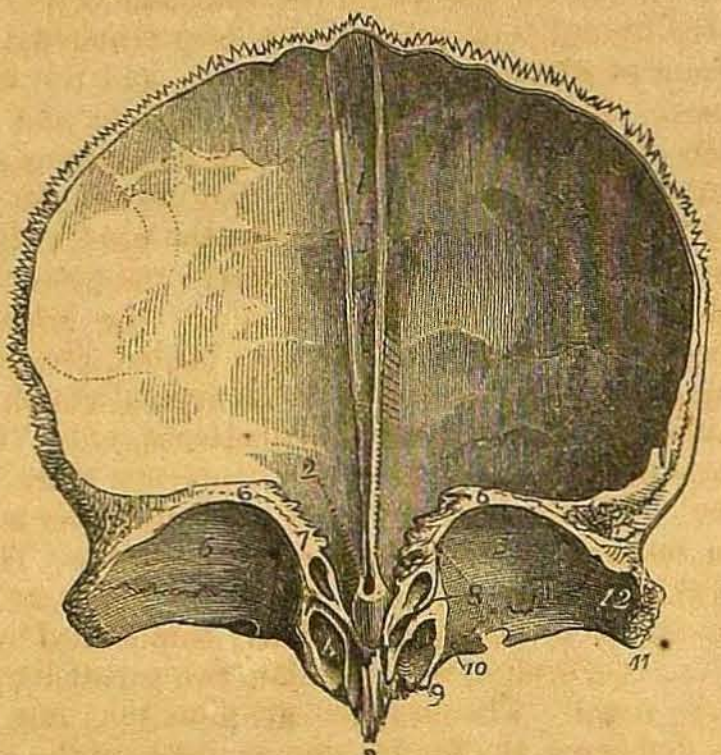

is the *temporal ridge* or *process*, which is prominent below, and leads upwards and backwards to join a similar ridge on the parietal bone; this separates the forehead from the temple, and gives attachment to the temporal muscle and fascia. On the cerebral or internal surface of this portion of the frontal bone we observe in the median line a groove for the longitudinal sinus. Inferiorly the edges of this groove unite into a ridge to which the falx adheres, and which extends down to a small hole, the foramen cæcum, which is between this bone and the ethmoid; this foramen transmits a small vein from the nose, and lodges a process of dura mater. On either side of this median line is the frontal fossa, corresponding to the protuberance externally; also numerous irregularities, or depressions and eminences, corresponding to the convolutions and sulci of the brain; these are named the mammillary eminences and the digital impressions; in some of the latter the bone is

* The internal or posterior surface of the frontal bone. 1. The groove for the superior longitudinal sinus. 2. The foramen cæcum. 3. The nasal spine. 4. Orifice of the frontal sinus. 5. The inferior surface of the orbital process. 6. The posterior edge of the orbital process. 7. 7. The internal cellular edges of the orbital processes; the space between the internal edges is the ethmoidal notch. 8. The anterior and posterior internal orbital foramina. 9. The internal orbital process. 10. The depression for the cartilaginous pulley of the superior oblique muscle. 11. The external angular process. 12. The depression for the lachrymal gland.

often very thin. The circumference of the os frontis is thick, rough, and serrated, to join the parietal bones. The tables are cut unequally, the internal being deficient above and in the middle, the external below, so that it rests on or binds down the two parietal bones above, and supports or is overlapped by these below. Below the temporal process it is bevelled off; is thin and rough, and is inserted under and between the laminæ of the ala of the sphenoid bone. The *inferior portion* of the frontal bone presents the deep ethmoidal notch in the centre, in front of which is the *nasal spine*, and the orifices of the frontal sinuses. Its edges are cellular, to unite to and communicate with the cells of the ethmoid bone. Along its margins are two foramina, the anterior and posterior orbital; they are common to this and to the ethmoid bone; the anterior transmits the nasal twig of the ophthalmic nerve and anterior ethmoidal artery; the posterior, the posterior ethmoidal artery. On either side are the *orbital processes*, smooth, concave, and triangular, the apex behind, presenting near the external angular process a fossa for the lachrymal gland, and near the internal a slight depression for the cartilaginous pulley of the superior oblique muscle of the eye; instead of a depression there is sometimes a small spine. The cerebral surface of these processes is convex, but very uneven, marked by the brain and blood-vessels. Their posterior margins are thin, and cut obliquely to support the lesser wings of the sphenoid bone. The processes of this bone, enumerated by anatomists, are eleven, viz., two orbital, four angular, two superciliary, two temporal, and one nasal. The foramina are nine, viz., one, the foramen cæcum; two and three, the frontal sinuses, between the nasal and internal angular processes; four and five, the supraorbital; six and seven, the anterior; and eight and nine, the posterior internal orbital; these last, as well as the foramen cæcum, are often common to this and the ethmoid bone. The os frontis is joined to four bones of the cranium, viz., the two parietal, the sphenoid, and ethmoid; and to eight bones of the face, viz., the nasal, superior maxillary, lachrymal, and malar. The structure is thick towards the nasal protuberance and superciliary ridges, but very thin in the orbital plates. It is composed of two compact laminæ and an intervening diploe. By the absorption of the latter, and the greater separation of the plates, the cavities called the *frontal sinuses* are formed. These do not exist in childhood; in the adult their size is very variable; they generally extend from each side of the ethmoid notch upwards and outwards for one-third of the superciliary arch, and sometimes much further; they are generally separated by a septum; each opens by the infundibulum into the middle meatus of the nose; they are lined by a delicate fibro-mucous membrane, and are filled with air; and while they thus effect an extension of surface, they do not increase the general weight of the cranium. They may contribute in a secondary manner to the sense of smelling, also to the resonance of the voice. The corresponding projections in the superciliary regions materially affect the facial angle and the expression of the countenance. This bone is developed from two points of ossification,

one in each frontal prominence; from this, ossification extends in rays, which unite in the middle line, but occasionally a suture remains between them: this has been said, but without sufficient foundation, to be more frequent in women than in men.

The *temporal bones* are situated in the lateral, middle, and inferior parts of the skull, of a very irregular shape, thin above and before, and thick behind and below. Each may be divided into three portions, the squamous, the mastoid, and the petrous. The *pars squamosa* is the superior division; it is flat, thin, and scaly, forms part of the tem-

*Fig. 92.**

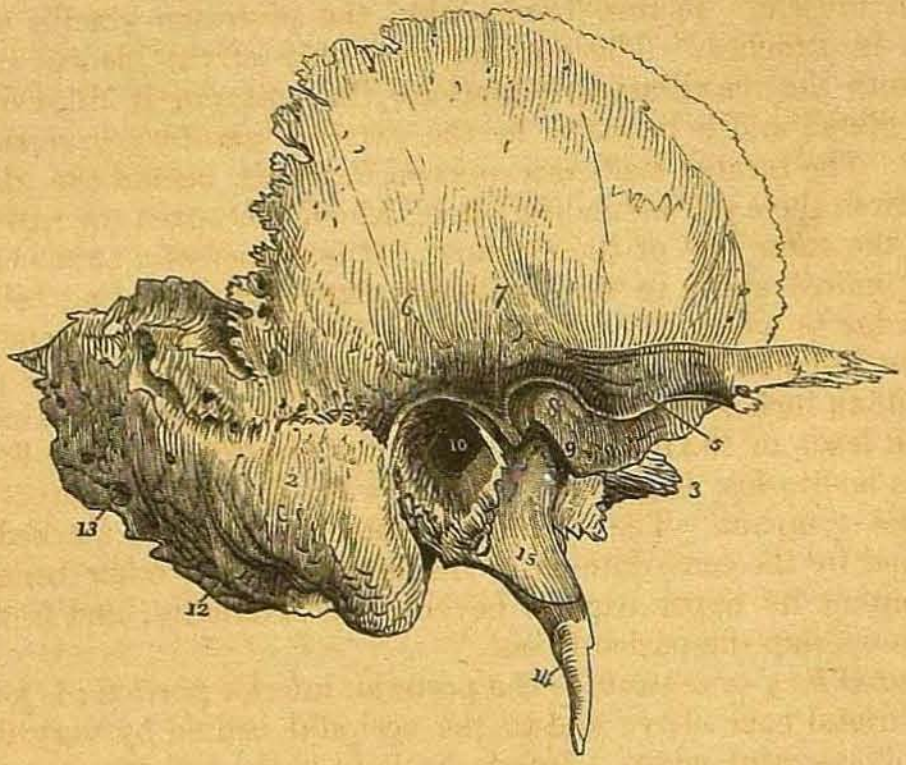

poral fossa; is bounded above by a semicircular edge, and below by the *zygomatic process*, which is horizontal, and arises by two roots, one of which is anterior, and covered by cartilage; is narrow externally, broad internally, and runs transversely in front of the glenoid cavity, with a little obliquity backwards, its inner end being on a plane posterior to its outer; the other root passes horizontally backwards, and bifurcates; one portion turns into the glenoid fissure, the other is gradually lost above the mastoid process. Where these two roots of the zygoma, the one transverse, the other horizontal, unite, there is a small

* The external surface of the temporal bone of the right side. 1. The squamous portion. 2. The mastoid portion; the number is placed upon the mastoid process. 3. The extremity of the petrous portion. 4. The zygomatic process. 5. The anterior or transverse root of the zygoma. 6. The posterior or horizontal root. 7. The inferior division of the posterior root, sometimes called the middle root of the zygoma. 8. The articular or glenoid cavity. 9. The Glasserian fissure. 10. The meatus auditorius externus, surrounded by the auditory process. 11. The digastric groove. 12. Groove for the occipital artery. 13. The mastoid foramen. 14. The styloid process. 15. The vaginal process.

tubercle to which the external lateral ligament of the lower jaw is attached. The zygoma thence bends forwards and downwards, slightly curved, convex outwards, and ends in a serrated edge which joins and rests on the malar bone. Between the root of the zygoma and the squamous plate there is a smooth trochlea, over which the posterior part of the temporal muscle moves. Behind the transverse root of this process is the articular or *glenoid cavity*, which is crossed by the *Glasserian fissure*. This fissure leads inwards and forwards; into it the capsular ligament of the lower jaw is inserted, and near its centre is a small hole, the opening of the canal through which the corda tympani nerve passes, also the ligament incorrectly named laxator tympani muscle. In this fissure, also, the processus gracilis of the malleus is attached. The anterior part only of the glenoid cavity enters into the maxillary articulation; the posterior is filled by the parotid gland, and is bounded by the *external auditory process and meatus*. The meatus leads inwards and forwards, behind the glenoid cavity, from the external auditory hole, which is between the two divisions of the outer root of the zygoma. It is formed of a twisted plate of bone, united above to the squamous plate, but presenting below a rugged edge to which the cartilage of the ear is attached. The meatus takes a curved direction forwards, inwards, and a little downwards; it is about half an inch long, and narrower in the centre than at the extremities; it leads to the membrana tympani: its external rough lip, or processus auditorius, is grooved internally for the attachment of the membrana tympani. The squamous plate internally is marked by vessels and by the convolutions of the brain, like the other bones of the cranium; its upper edge is bevelled off internally, and is very rough, to overlap the parietal bone.

The *mamillary* or *mastoid* is the posterior inferior portion; is joined to the parietal bone above and to the occipital behind by very thick and deeply-serrated edges. Inferiorly it is prolonged into a rough, nipple-like process, the *mastoid;* internal to which is a groove for the digastric muscle, and another internal and partly behind it for the occipital artery. Above and behind it is a hole through which a vein and small artery pass. This process is very rough and porous; the diploe is hollowed out between the two tables into cells which communicate with the tympanum. It gives attachment to the sterno-mastoid muscle. The cerebral surface is deeply grooved for the lateral sinus.

The *petrous portion* passes from the junction of the mastoid and squamous forwards and inwards, and a little upwards, into the base of the skull; it is of a triangular form, the base behind, and very irregular, with a deep notch which assists the occipital bone in forming the foramen lacerum posterius. The apex is anterior, contiguous to the body of the sphenoid bone, and completing with it the foramen lacerum anterius, which in the recent state is filled up with cartilage. This bone is peculiarly hard and rugged; it presents three surfaces, an inferior, superior, and posterior. On its *inferior* or basilar surface we remark,

in front of the foramen lacerum posterius, a minute hole which leads to the cochlea, and is named the *aqueduct* of the *cochlea*. More anteriorly and externally is the *styloid process*, which descends obliquely inwards and forwards, and gives attachment to three muscles and two ligaments; it is surrounded at its root by a plate of bone most prominent anteriorly and externally; this is the *vaginal process*, it separates the glenoid fossa from the carotid foramen. Behind and outside the styloid process, between it and the mastoid, is the *stylo-mastoid hole*, or the lower end of the aqueduct of Fallopius; this transmits the portio dura, or the facial nerve. In front of the styloid process, and a little internal to it, is the *carotid hole*, which leads into a canal that winds forwards, upwards, and inwards, and which opens within the cranium, above the foramen lacerum anterius, by the side of the body of the sphenoid bone; it transmits the carotid artery and branches of the sympathetic nerve. In front of the carotid hole is a flat, rough surface, to which the muscles of the velum and pharynx are attached. Internal to the styloid process and stylo-mastoid foramen is a vertical ridge or spine, named *jugular*, which joins the corresponding portion of the occipital bone. Internal and posterior to this ridge, in the posterior border of the bone, is the deep *jugular fossa*, which, with that in the occipital, completes the *foramen lacerum posticum*. The upper part of the jugular spine separates a smaller portion of this fossa from the remainder. Through it passes the eighth pair of nerves, and through the larger

*Fig. 93.**

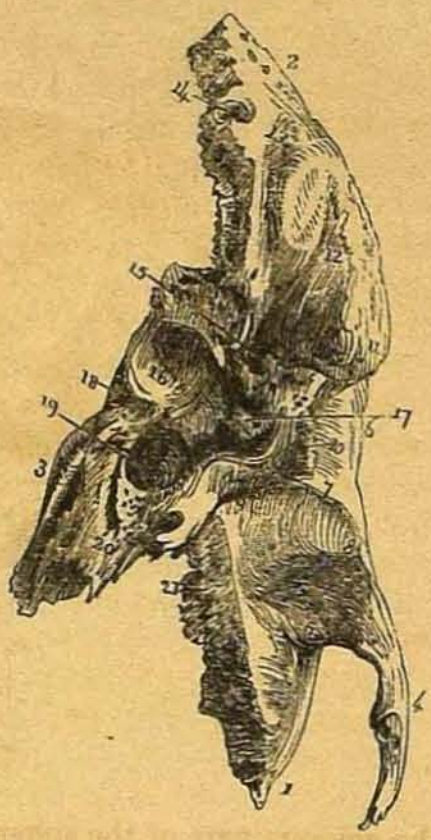

* The inferior surface of the temporal bone. 1. The squamous portion. 2. The mastoid portion. 3. The petrous portion. 4. The zygomatic process. 5. The anterior or transverse root of the zygoma forming the eminentia articularis. 6. The superior division of the posterior root. 7. The inferior division of the posterior root. 8. The tubercle to which the external lateral ligament of the lower jaw is attached. 9. The Glasserian fissure crossing the glenoid cavity. 10. The auditory process. 11. The lower extremity of the mastoid process. 12. The digastric groove. 13. The groove for the occipital artery. 14. The mastoid foramen. 15. The stylo-mastoid foramen. 16. The jugular fossa. 17. The styloid process, bounded externally and anteriorly by the vaginal process. 18. The aqueduct of the cochlea. 19. The carotid foramen, in the posterior margin of which is a small opening which admits the nerve of Jacobson, or the tympanic branch of the glosso-pharyngeal nerve. 20. The rough surface to which the levator palati is attached. 21. The angle between the squamous and petrous portions, into which the spinous part of the sphenoid bone is wedged; in it are found the bony orifice of the Eustachian tube, and immediately above it the canal for the transmission of the tensor tympani muscle. The thin plate of bone which separates these openings is termed the processus cochleariformis.

and posterior part the jugular vein. The lower portion of the jugular spine separates the jugular from the carotid foramen; and upon this intervening bone is the small triangular opening of the *aqueduct of the cochlea;* also the orifices for the transmission of the tympanic branches of the glosso-pharyngeal and pneumogastric nerves. The apex of the petrous bone is very irregular; it lies in the foramen lacerum anterius; the internal or superior opening of the carotid canal is in it. Into the angle between the petrous and squamous portions

Fig. 94.*

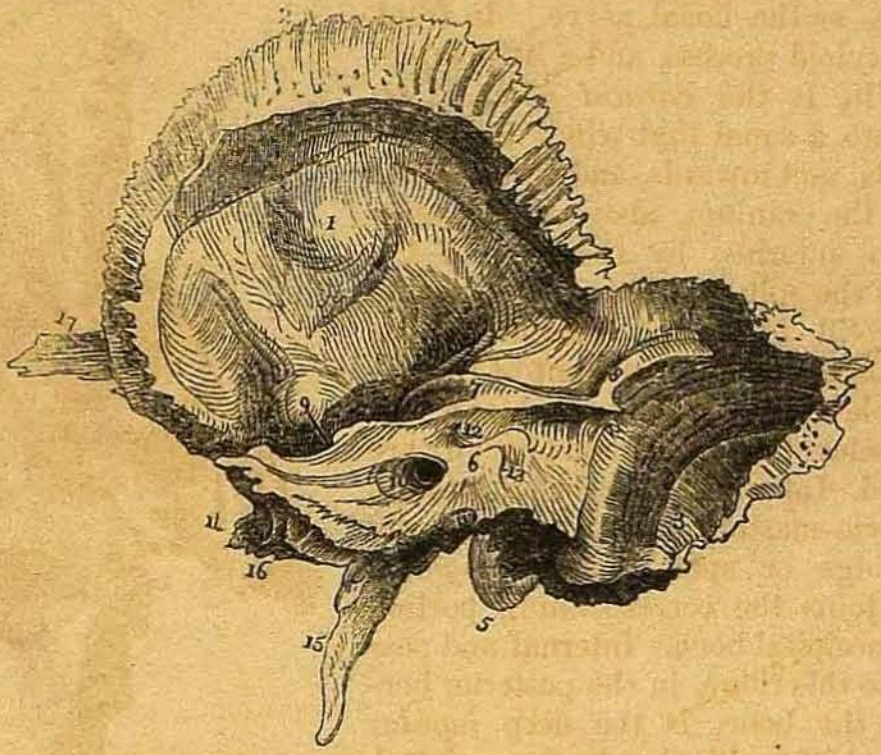

the spinous part of the sphenoid bone is wedged. In this angle there are two holes or canals separated by a thin lamina of bone, named *cochleariform process.* The upper canal transmits the tensor tympani muscle; the lower is the extremity of the bony part of the Eustachian tube; both these canals lead backwards and outwards into the tympanum. The *cerebral surface* of the petrous bone presents a prismatic form; a sharp, grooved, angular ridge, to which the tentorium cerebelli is attached, separates its two surfaces; one looks

* The internal surface of the right temporal bone. 1. The squamous portion. 2. Its upper edge bevelled off to overlap the parietal bone. 3. The mastoid portion; the number is placed immediately behind the internal orifice of the mastoid foramen. 4. The groove for the lateral sinus. 5. The extremity of the mastoid process. 6. The petrous portion of the temporal bone. 7. The eminence marking the situation of the superior semicircular canal. 8. The ridge to which the tentorium is attached. 9. The notch for the passage of the fifth nerve over the border of the petrous bone, near to its apex. 10. The meatus auditorius internus. 11. The opening of the aqueduct of the cochlea. 12. The small depression lined with dura mater. 13. The slit in which the aqueduct of the vestibule ends. 14. The termination of the carotid canal. 15. The styloid process. 16. The extremity of the petrous bone which gives origin to the levator palati and tensor tympani muscles. 17. The zygoma.

forwards and upwards, the other backwards and inwards. The superior petrosal sinus is lodged in the groove on the angle of the bone, between it and the tentorium. On the *superior surface* we observe anteriorly a depression, sometimes a notch, which corresponds to the Casserian ganglion of the fifth pair of nerves. Leading from this is a delicate groove which conducts to a small opening, the *hiatus Fallopii*, through which the superior branch of the Vidian nerve passes in order to enter the aqueduct of Fallopius. The remainder of the surface is marked by the convolutions of the brain and by the eminence of the superior semicircular canal. On the *posterior surface* is the *meatus auditorius internus*, a short canal, about a third of an inch long; through it pass the two portions of the seventh pair of nerves; it is directed forwards and outwards, is lined by dura mater, and is terminated abruptly by a vertical bony process, beneath which is a sort of cribriform plate: through this the auditory nerves pass, and above this the portio dura enters the *aqueduct of Fallopius*. The latter is a very long canal, which leads outwards and downwards behind the tympanum; the hiatus Fallopii, and some canals from the tympanum, open into it: it ends in the stylo-mastoid foramen. Behind the meatus is a small depression lined by the dura mater, and posterior to this is a narrow, short slit, in which the *aqueduct of the vestibule* ends: from this slit a groove descends to the jugular opening. The petrous bone contains within it the ossicula and the complicated apparatus of the organ of hearing, which have been already described (page 665). The temporal bone is connected to five bones, the parietal, malar, sphenoid, occipital, and inferior maxillary, and in some to the os hyoides. The processes enumerated are six, viz.: the mastoid, auditory, zygomatic, styloid, vaginal, and cochleariform. The holes are ten proper and two common. The proper are the external auditory, glenoidal, stylomastoid, aqueductus cochleæ, carotid, Eustachian, hiatus Fallopii, internal auditory, and aqueductus vestibuli. The common are the foramen lacerum anticum and posticum or jugulare. In the fœtus it consists of two portions, the squamous and petrous; the latter is large and well developed, and the ossicula auditus which it contains are perfect, and nearly as large as in the adult. The mastoid portion is not formed; the styloid process is cartilaginous, and is distinct from the rest of the bone. The external auditory meatus is wanting; a bony ring supplies its place, and encircles the tympanum.

The *ethmoid bone* is situated in the notch between the orbital plates of the frontal bone, and forms the roof and part of the sides of the nostrils. It is so named from its cribriform or sieve-like appearance; it is of a cuboid figure, and composed of many thin, brittle, semitransparent laminæ, placed in every direction so as to form cells; these enlarge the surface of the nose without increasing the size or weight, for this bone is remarkably light. It consists of a superior cribriform plate, a middle perpendicular lamina, and two lateral symmetrical portions. The *superior* or *cerebral surface*, or *cribriform plate*, is broad and somewhat square; it is covered by the dura mater. In its posterior edge is a notch, which receives a process of the sphenoid bone.

Along the middle line is a hard ridge, which anteriorly rises into a remarkable process, the *crista galli*, to which the beginning of the falx is attached. This process ends before in two short *alæ*, which join the os frontis, and which often assist in bounding the foramen cæcum. On either side of this process is a channel deeper before than behind; these lodge the bulbs of the olfactory nerves. Anterior to each of these, and nearer to the process, is a small slit, which transmits the nasal branch of the ophthalmic nerve. This entire surface is perforated by numerous holes; about ten or twelve of these are large, and are placed over the lateral parts of the bone; the remainder are very small, and are on either side of the median line; they each lead into a small vertical canal lined by dura mater. From the inferior surface of this plate there descend the *nasal lamella* in the middle, and a large spongy cellular mass on either side. The *nasal lamella* is in the median line; it is thick above and behind where it joins the sphenoid, thin below where it joins the vomer and nasal cartilage, and very thick before, where it unites to the nasal process of the os frontis and to the nasal bones. Its sides are marked by the canals for the olfactory nerves, short and oblique before, vertical and very long in the middle and behind; they descend for about half the depth of the plate, and there end in mere grooves. On either side of this septum is a deep channel, which forms the roof of each naris. On each side of this we observe an irregular bony structure, which consists of three parts, an internal curved lamina (the superior turbinated bone), a middle range of cells, and externally towards the orbit a smooth, square plate, the os planum. First, the *turbinated* or *spongy bone* is a very thin plate, descending at first vertically, and then bending outwards, and rolled upon itself for nearly half a turn. In the posterior extremity of this is a depression or sort of cleft, which is called the superior meatus of the nose. This channel or meatus extends along the posterior half of the ethmoid; it is closed before, except in a small aperture which leads into the posterior ethmoid cells. The portion of the turbinated plate which extends above this cleft is

*Fig. 95.**

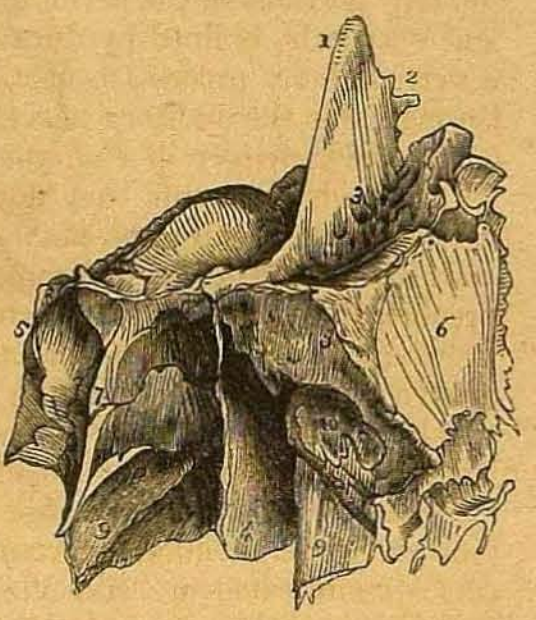

* The ethmoid bone, seen from above and behind. 1. The crista galli. 2. One of the anterior wings which join the frontal bone. 3. The cribriform plate. 4. The perpendicular or nasal lamella. 5. The lateral masses. 6. The os planum, or orbital process. 7. The superior turbinated bone. 8. The superior meatus of nose. 9. The middle turbinated or spongy bone. 10. The posterior ethmoidal cells.

named *superior spongy* or *turbinated bone*, and that below this fossa *middle spongy bone;* it is larger than the upper portion, more curved, and very concave outwardly. Beneath this is a deep fossa named the middle meatus of the nose. Second, the *ethmoid cells* are external to the turbinated plates, bounded above by the cribriform plate, and externally by the os planum and os unguis; the cells are about twelve or fourteen in number, and are divided by a bony septum into an anterior and posterior set. The *posterior* are small, and opens into the superior meatus, and sometimes one of the uppermost communicates with the sphenoid sinus, or opens into the fossa of its turbinated plate. The *anterior* cells are larger and more numerous; they open into the middle meatus. One of the most anterior is curved into a sort of tube, the *infundibulum*. Into this the frontal sinus opens above, and it terminates below, before the orifice of the great maxillary sinus or antrum. All these cells are lined by the pituitary membrane, which, however, is less vascular and thick than that on the nasal lamella and turbinated bones. On this membrane, particularly that covering the superior spongy bone and the square surface before it, the external olfactory canals chiefly end. From the lower surface of the ethmoidal cells thin plates often descend very irregularly to join the superior maxillary. External to the cells on each side is, third, the *os planum*, or orbital plate, very smooth and polished, articulated above to the frontal, before to the lachrymal, behind to the sphenoid, and below to the maxillary and palate bones: the upper border has often a notch or two, which assist the frontal in forming the internal orbital holes. The ethmoid bone contributes to form the base of the cranium, the nose, and the orbits: it has little or no cellular tissue in its composition, except in the crista galli and in the turbinated plates. In the latter the compact tissue is in the centre, and covered by the spongy. It is developed by three points of ossification, one for the central lamella and one for each side; the latter appear first; the turbinated plates are not distinct until five years of age. It is joined to two bones of the cranium, the frontal and sphenoid, and to eleven of the face, the nasal, superior maxillary, lachrymal, palate, inferior spongy, and the vomer.

Fig. 96.*

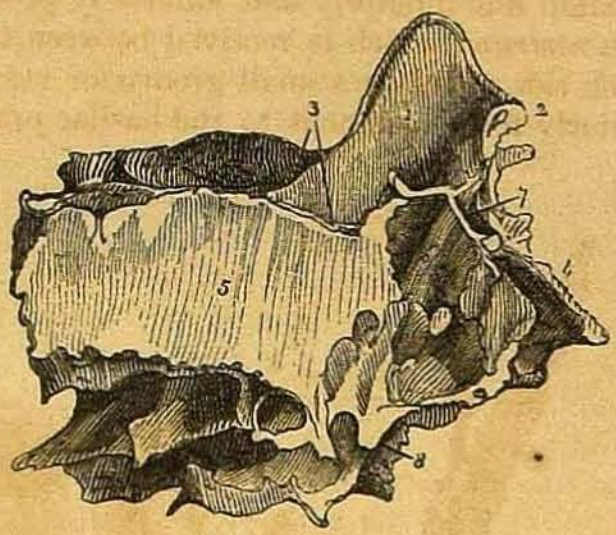

* A lateral view of the ethmoid bone. 1. The crista galli. 2. Its arms or wings. 3. The channels in which are lodged the olfactory nerves. 4. The anterior edge of the perpendicular or central lamella. 5. The os planum, or orbital plate. 6. The anterior ethmoidal cells. 7. The infundibulum. 8. The middle meatus of the nose.

The *sphenoid bone* is so named from the manner in which it is wedged into the base of the skull, in the middle of which it is placed; it is articulated to all the bones of the cranium, and to many of those of the face; it is of a very irregular form, and has been compared to a bat, to which it bears some resemblance, particularly if the ethmoid remain attached. It may be divided into a body and processes. The *body* is in the centre, and resembles a square box. From its median line inferiorly and anteriorly proceeds the *azygos process*, or the *rostrum*, which is received between the layers of the vomer. On each side of this is a small groove for vessels; it is flat and rough posteriorly for attachment to the basilar process. Its centre is hollowed

*Fig. 97.**

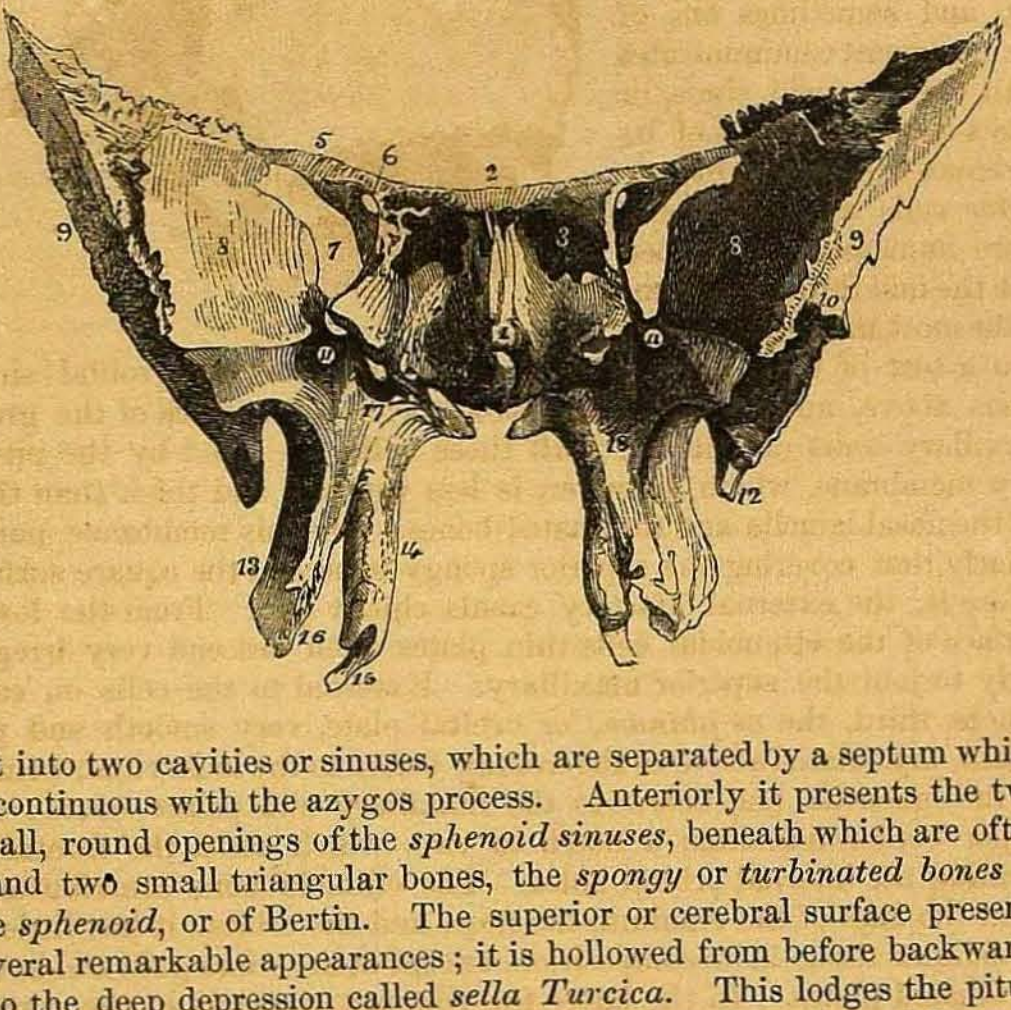

out into two cavities or sinuses, which are separated by a septum which is continuous with the azygos process. Anteriorly it presents the two small, round openings of the *sphenoid sinuses*, beneath which are often found two small triangular bones, the *spongy* or *turbinated bones* of the *sphenoid*, or of Bertin. The superior or cerebral surface presents several remarkable appearances; it is hollowed from before backwards into the deep depression called *sella Turcica*. This lodges the pituitary body, and is perforated by several holes, through which small vessels pass to the sinus. Posteriorly it is bounded by a thin plate

* The anterior view of the sphenoid bone. 1. The azygos process. 2. The ethmoidal process. 3. The openings of the sphenoidal cells. 4. The turbinated bones of the sphenoid. 5. The lesser wing. 6. The foramen opticum. 7. The foramen lacerum orbitale. 8. The orbital process of the great wing. 9. The temporal process. 10. The pterygoid crest. 11.11. The foramen rotundum. 12. The spinous process of the sphenoid. 13. The external pterygoid plate. 14. The internal pterygoid plate. 15. The hamular process. 16. The notch which receives the palate bone. 17. The anterior opening of the Vidian canal. 18. The groove which assists in forming the posterior palatine canal.

which rises perpendicularly, and has a slight knob at each angle, named *posterior clinoid processes*, to each of which the extremity of the convex edge of the tentorium cerebelli is attached. Anterior to

Fig. 98.*

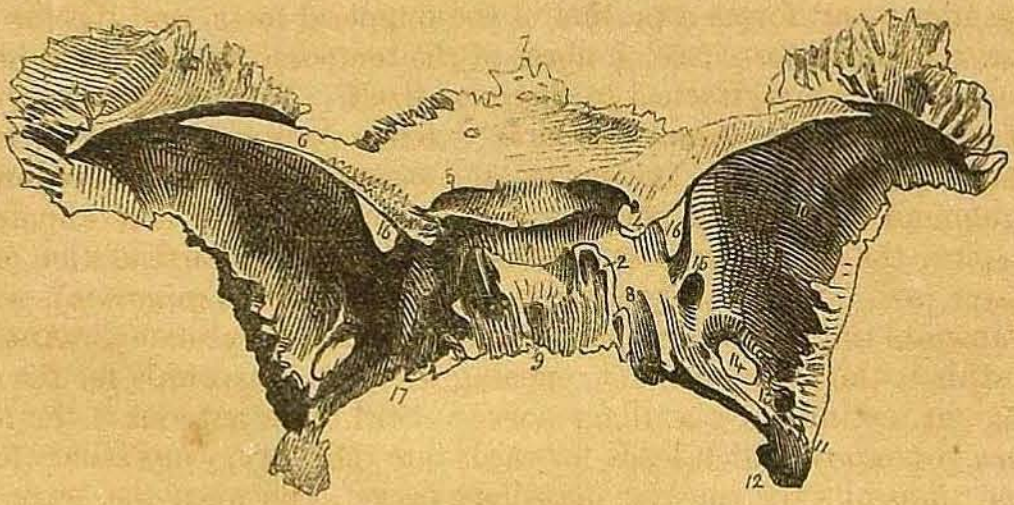

the sella is the flattened or slightly grooved surface for the optic commissure. This leads outwards to each optic foramen. The eminence supporting this groove is named the *olivary process*. Behind this, or between it and the pituitary fossa, is a tubercle on each side, named *middle clinoid processes*, or *process*, as some consider it. Behind the optic foramina are the *anterior clinoid processes*, two thick tubercles to which the extremity of the concave edge of the tentorium is attached. Each of these is perforated by the *optic foramen*, which is transversely oval, and transmits the ophthalmic artery and the optic nerve. Sometimes the anterior is united to the posterior clinoid process by bone, and sometimes to the olivary process. From each anterior clinoid process there extends forwards and outwards a thin plate of bone, the *transverse spine* or lesser wing, or wing of Ingrassius. This is united anteriorly to the frontal bone, and forms part of the orbit; it ends in a point; its posterior edge is thick and rounded; the sphenoidal fold of the dura mater is attached to it, and both occupy the fissure of Sylvius, on the base of the cerebrum, between its anterior and middle lobes. Each side of the sella Turcica is grooved by the carotid artery. From the forepart of the body of the sphenoid extends a small plate to join the ethmoid bone, the *ethmoidal process*. From each side of the body,

* The superior or cerebral surface of the sphenoid bone. 1. The sella Turcica. 2. The posterior clinoid process. 3. The olivary process. 4. The anterior clinoid process. 5. The optic foramen. 6. The lesser wing. 7. The ethmoidal process. 8. Groove for the internal carotid artery. 9. The rough surface to which the basilar process of the occipital bone is attached. 10. The cerebral surface of the great wing. 11. The spinous process. 12. The styloid process of the sphenoid bone. 13. The foramen spinosum. 14. The foramen ovale. 15. The foramen rotundum. 16. The foramen lacerum orbitale. 17. The angle which receives the apex of the petrous portion of the temporal bone; the posterior orifice of the Vidian canal lies in this angle.

the *great ala* is continued outwards, forwards, and upwards; it presents three surfaces, one anterior, smooth, and square, forms part of the outer wall of the orbit, and is named *orbital process;* another is elongated and concave, and, together with the temporal bone, supports the middle lobe of the cerebrum; the third, or external surface, is named the *temporal process.* This is divided into two by a *crest;* the upper part forms a portion of the temporal fossa, and the lower of the zygomatic fossa; some fibres of the temporal and external pterygoid muscles are attached to the crest itself. From the posterior part of each wing the *spinous process* extends backwards, and curves a little downwards and outwards, and occupies the angle between the squamous and petrous portions of the temporal bone; it terminates in a spine, the *styloid process*, on the inner side of the articulation of the lower jaw. Near this process is a small foramen (*spinosum*), which transmits the middle or spinous artery of the dura mater. Anterior to this is the *foramen ovale*, opening directly downwards for the passage of the inferior maxillary nerve. Still more anterior is the *foramen rotundum*, which leads forwards into the pterygo-maxillary fossa, and transmits the superior maxillary nerve. Between the lesser and great wing is a long slit, the *foramen lacerum orbitale*, wide internally, narrow externally, where the frontal bone sometimes assists in closing it; it transmits the third, fourth, first branch of the fifth and the sixth nerves, also filaments of the sympathetic, and the ophthalmic vein and a small artery. From the angle between the body and great ala the *pterygoid* plate descends perpendicularly (fig. 97); internally it bounds the posterior naris, externally the external pterygoid muscle is attached to it; anteriorly the palate bone is connected to it, posteriorly it is hollowed into the *pterygoid fossa*, which lodges the internal pterygoid muscle, and in a small depression internal to this the tensor palati muscle. This fossa thus divides this process into two plates; the *external* is broad and rough, the *internal* is longer and narrower, and ends in the *hamular* process, a small, delicate hook, convex inwards, concave outwards, and covered by a bursa; round this the tendon of the tensor palati muscle turns. In the inferior notch between these plates the palate bone is received. Above the internal pterygoid plate is the *Vidian hole* or canal. This opens anteriorly on the inner side of the foramen rotundum into the spheno-maxillary fossa, and posteriorly, very small, into the foramen lacerum anterius: it transmits the Vidian nerve and vessels. The structure of the sphenoid bone is very compact, except the body, which is cellular: the latter about ten years of age undergoes the process of absorption, whereby the cavities called the *sphenoid sinuses* are gradually formed. These open on each side into the upper and back part of the nose. In front of them in the adult is a small, curved plate of bone, the *sphenoidal turbinated bone;* it is of a pyramidal form, the base anteriorly connected to the posterior ethmoid cells, the apex posteriorly, and joined to the forepart of the sinus. It lies above the *spheno-palatine foramen*, a hole which is below the body of the sphenoid, and between

the orbital processes of the palate bone. This hole leads from the nose to the spheno or pterygo-maxillary space. These superior spongy bones are wanting in the child, and even sometimes in the adult. The sphenoid is articulated to the seven bones of the cranium and to five of the face, viz., the two malar, two palate, and the vomer, and in some cases to the superior maxillary by the pterygoid plates; the palate bones, however, in general intervene. The processes enumerated are twenty-eight, viz.: five clinoid, one olivary, one ethmoidal, two lesser wings, the azygos, two spongy or triangular, two great wings, two temporal, two orbital, two spinous, two styloid, four pterygoid, and two hamular. The foramina are fourteen proper and eight common. The proper are two optic, two lacerated orbital, two round, two oval, two spinal, two Vidian, and the two sinuses. The common are the two foramina lacera antica basis cranii, two spheno-maxillary fissures, one in each orbit, bounded by the orbital plates of the sphenoid, malar, maxillary, and palate bones, two spheno-palatine, and two posterior palatine canals between the pterygoid processes and the superior maxillary tuberosities. At birth the sphenoid bone consists of three pieces; one is the body to which the clinoid processes and lesser wings are attached; the lateral pieces consist of the pterygoid processes and the great wing of each side.

The bones of the cranium are connected to each other by *suture*, that is, the edge of each is serrated or cut into irregular teeth-like processes, which indigitate or lock into each other, so as to unite the two edges in a very strong and motionless manner. The indentations are irregular and oblique in very thick bones, but where the edges are thin the suture is more straight and even; they are more distinct in the young than in the old, and on the outer than on the inner surface of the cranium. There are seven sutures noticed by most anatomists (some, however, unnecessarily enumerate a greater number): the sphenoidal, ethmoidal, coronal, sagittal, lambdoid, and the two squamous.

The *sphenoidal suture* is very extensive; it follows the irregular edge of the sphenoid bone, and connects it to the occipital, the temporal, inferior angle of the parietal, the frontal, and the ethmoid.

The *ethmoidal* suture, in like manner, encircles the ethmoid bone, and connects it to the frontal. The *frontal* or *coronal suture* proceeds from the upper extremity of the sphenoidal, about an inch behind the external angle of the os frontis; ascends vertically, inclining a little backwards, and then descends to the same point on the opposite side; it connects the frontal and parietal bones by serrated edges, alternately bevelled in the manner before explained.

The *sagittal suture* leads from the superior angle of the occipital bone directly forwards between the two parietal to the centre of the coronal suture; it is deeply serrated about the centre, and is sometimes continued along the median line of the frontal bone down to the nose.

The *lambdoid suture* extends on either side from the posterior extremity of the sagittal suture downwards and forwards to the mastoid

process of the temporal bone; and a suture, named the *additamentum of the lambdoid*, continues down between the back part of this process and the occipital and petrous bones as far as the foramen lacerum posterius. The lambdoid suture is very rough, and frequently contains ossa triquetra of very irregular size; it connects the occipital and the two parietal bones. The additamentum is an harmonic suture, that is, it is very little serrated, but presents uneven, thick edges; it connects the occipital to the mastoid and petrous portions of the temporal bone: the mastoid hole is frequently in it; it nearly corresponds to the lateral sinus.

The *squamous suture* on each side is continued from the extremity of the sphenoidal, in an arched direction, upwards and backwards as far as the inferior angle of the parietal; it is then continued, under the name of *additamentum of the squamous suture*, directly backwards for about an inch. The structure of the squamous differs from that of the other sutures; the bones are not serrated, but are thin and scaly, and overlap each other; it unites the temporal to the parietal, but the additamentum is serrated, and connects the inferior angle of the parietal to the upper part of the mastoid portion of the temporal bone, it corresponds to a portion of the lateral sinus internally. A small os triquetrum is sometimes found at the anterior part of this suture, and seldom in any other situation, except in the lambdoid suture.

SECTION IV.

OF THE SKULL IN GENERAL.

THE *outer* surface of the skull presents four regions. The *superior*, or the vertex, is smooth and even, and has no remarkable appearance deserving more particular attention. The *lateral* regions are each divided into two, the anterior or temporal, and the posterior or mastoid; the meatus auditorius externus intervenes. The *inferior* region extends from the nasal notch, in the frontal bone, to the occipital protuberance, and is bounded laterally by the zygomatic arches and by a ridge, which is continued from these processes round the skull with but little interruption. This region may be divided into three portions, anterior, middle, and posterior. The *anterior* basilar region extends from the superciliary ridges of the frontal bone to the roots of the pterygoid processes of the sphenoid; it presents the nasal spine and process of the os frontis, the ethmoid bone, the orbital plates of the os frontis, bounded by their angular processes before, and by the orbital plates of the sphenoid behind. In this division are the supra-orbital, the anterior and posterior orbital holes, the openings of the frontal and ethmoidal cells, the optic and lacerated holes of the orbits, the Vidian canals, and the foramina rotunda. The *middle* division

extends from the roots of the pterygoid to the styloid processes of the temporal bones; it presents the azygos process of the sphenoid, the basilar process of the occipital, the anterior points of the petrous portions of the temporal bones, the spinous processes of the sphenoid, and the glenoid cavities of the temporal bones. The holes in this division

*Fig. 99.**

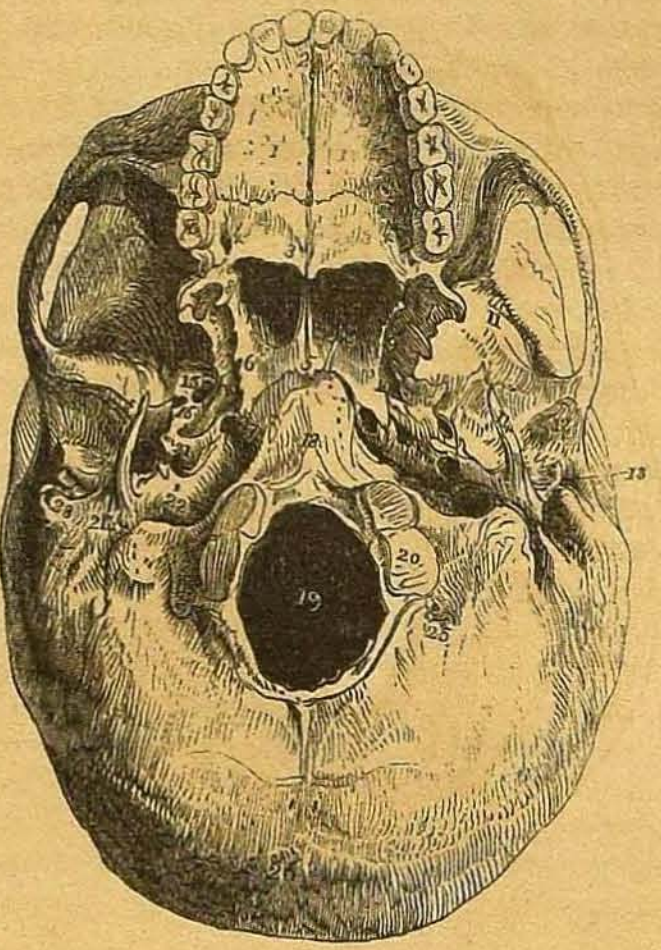

are the oval, spinous, carotid, external auditory, and glenoidal; the Eustachian tubes are external to it. The *posterior* division extends from the styloid processes of the temporal to the tuberosity of the occipital bone; it presents the foramen magnum, the two condyles, the jugular ridges, the styloid processes of the temporal bones, sur-

* The inferior or external surface of the base of the skull. 1. The palate plate of the superior maxillary bone. 2. The foramen incisivum. 3. The palate process of the palate bone. 4. The posterior palatine foramen. 5. The vomer separating the openings of the posterior nares. 6. The internal pterygoid plate. 7. The external pterygoid plate. 8. The hamular process. 9. The pterygoid fossa. 10. The scaphoid fossa. 11. The zygomatic fossa. 12. The glenoid fossa. 13. The meatus auditorius externus. 14. The styloid process of the temporal bone. 15. The foramen ovale. 16. The foramen spinosum. 17. The foramen lacerum anterius basis cranii. 18. The basilar process of the occipital bone. 19. The foramen magnum. 20. One of the condyles of the occipital bone. 21. The carotid foramen. 22. The foramen lacerum posterius. 23. The mastoid process. 24. The stylo-mastoid foramen. 25. The posterior condyloid foramen. 26. The great protuberance of the occipital bone.

rounded by the vaginal processes, the mastoid processes, the digastric grooves, the inferior and superior transverse arches, the spine, protuberance, and depressions of the occipital bone. The foramina in this division are the stylo-mastoid, mastoid, magnum, lacera postica, anterior and posterior condyloid, aqueductus cochleæ, and the tympanic foramina in the petrous bone.

Fig. 100.*

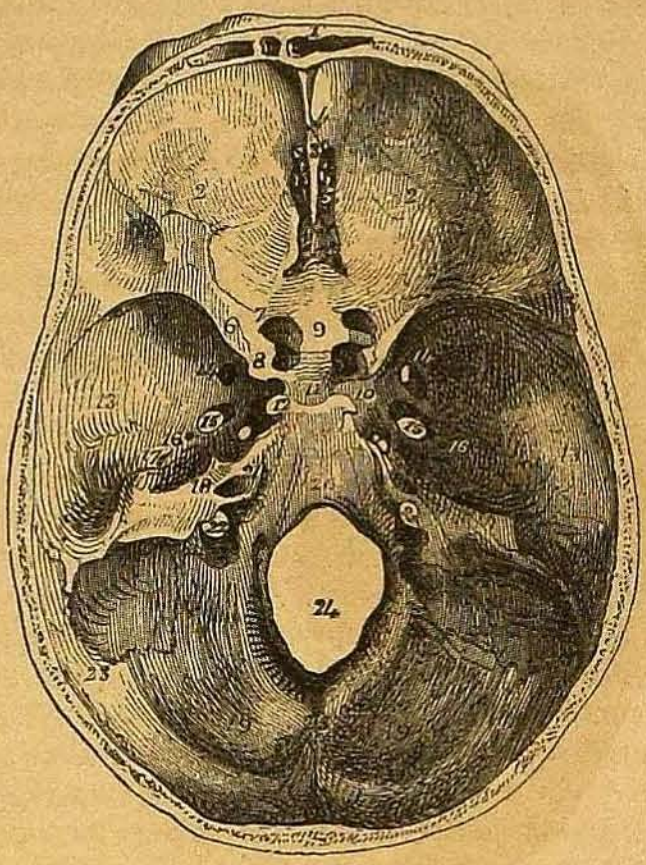

The skull is divided internally into the arch or vault and the base. On the vault is to be observed the sulcus for the longitudinal sinus, the frontal crest, the grooves for the middle arteries of the dura mater, the depressions for the convolutions of the brain, and for the granulations or glandulæ Pacchioni. The base of the skull is very uneven, and presents on each side of the median line three regions or *fossæ* on dif-

* The internal or cerebral surface of the base of the skull. 1. Frontal sinuses laid open. 2. The anterior fossa; the figure is placed on the orbital plate of the frontal bone. 3. The crista galli. 4. The foramen cæcum. 5. The cribriform lamella of the ethmoid bone. 6. The lesser wing of the sphenoid. 7. The foramen opticum. 8. The anterior clinoid process. 9. The middle clinoid process and olivary eminence. 10. The carotid groove. 11. The sella Turcica. 12. The posterior clinoid process. 13. The middle fossa of the base of the skull. 14. The foramen rotundum. 15. The foramen ovale. 16. The foramen spinosum. 17. The hiatus Fallopii. 18. The groove for the superior petrosal sinus. 19. The posterior fossa of the base of the skull. 20. The basilar process of the occipital bone. 21. The meatus auditorius internus. 22. The jugular foramen. 23. The groove for the lateral sinus. 24. The foramen magnum. 25. The ridge upon the occipital bone to which the falx cerebelli is attached.

ferent planes, viz., the *anterior* or *frontal*, the *middle* or *spheno-temporal*, and the *posterior* or *occipital*.

The *first* is formed of the orbital plates of the frontal bone, the cribriform plate of the ethmoid, and the lesser wings of the sphenoid. The foramina in this division are the cæcum, olfactory, internal orbital, and optic.

The *second* division is bounded before by the lesser wings of the sphenoid bone, on the sides by the squamous portions of the temporal, and behind by the superior angles of the petrous portions of the same bone, and by the posterior clinoid processes of the sphenoid. In the middle is the sella Turcica; on each side of which, but below it, is a groove for the carotid artery and for the cavernous sinus, and below this is a shallow groove for the superior maxillary nerve. Further out on each side are the cavities to lodge the middle lobes of the brain, and on the superior surface of the petrous bones are seen the juttings of the vertical semicircular canals. The foramina in this division are the foramina lacera orbitalia superiora, rotunda, ovalia, carotica, spinosa, lacera basis cranii anteriora, and innominata or hiatus Fallopii.

The *third* or occipital region is bounded before by the basilar process and by the posterior surface of the petrous bones, and behind by the occipital; it presents the basilar process, the foramen magnum, the perpendicular ridge of the occipital crossed by the transverse, by which this bone is divided into four fossæ. On the superior angle of each petrous bone is a shallow groove for the superior petrosal sinuses; the transverse occipital ridge presents a deep one for the lateral sinuses, which last are continued over the inferior angles of the parietal bones, and thence descend inwards along the mastoid portions of the temporal bones, and then again groove the occipital, and pass forwards on it to the posterior foramina lacera. The perpendicular ridge is grooved above for the longitudinal sinus, which terminates sometimes in the left, but more frequently in the right lateral sinus. The vertical ridge, below the tentorium, gives attachment to the falx minor, and is slightly grooved for the occipital sinuses. The foramina in this division are the foramina auditoria interna, aqueductus vestibulorum, foramina lacera postica, foramen magnum, foramina condyloidea antica and postica.

SECTION V.

THE BONES OF THE FACE.

The *face* is divided into the upper and lower jaw. The latter consists of but one bone, the inferior maxillary; the former is composed of thirteen bones, six pair and one single. The six pair are the malar, superior maxillary, lachrymal, nasal, palatine, and inferior spongy.

The single bone is the vomer. These thirteen bones, however, are so intimately joined that the upper jaw might be regarded as a single bone, like the lower.

The *malar* or *cheek bone* is placed at the outer and under part of the orbit, and forms the prominence of the cheek. It is of an irregular square form; is very strong and compact, convex externally, and covered by the skin and orbicularis palpebrarum; it presents one or two small holes for vessels and nerves. Its upper and outer edge is named *external orbitar process*, and joins the frontal bone; its inner end, or the *maxillary process*, is cut off obliquely and serrated, and attached to and overlaps the maxillary bone. Its anterior edge between these two processes is round, smooth, and concave; it forms about one-third of the base or circumference of the orbit. Behind this the malar bone is smooth, and forms part of the temporal fossa; from its posterior surface a thin plate extends into the cavity, and is named *internal orbital process* or *plate;* this is notched posteriorly, and forms the anterior boundary of the spheno-maxillary fissure; this process is connected to the superior maxillary bone internally, and to the sphenoid bone externally. The lower edge is thick and uneven, gives attachment to the masseter muscle, and it ends posteriorly in the *zygomatic process*, which passes backwards, and terminates in a serrated edge, which supports the zygomatic process of the temporal bone. The malar bone is thick, strong, and cellular; it is well developed in the fœtus: ossification commences early, and from one point. It is joined to four bones, the frontal, sphenoid, temporal, and superior maxillary. The processes are five, the superior, inferior, and internal orbital, the malar, and zygomatic. The foramina are two or three proper, and one common, viz., the spheno-maxillary fissure, or the foramen lacerum orbitale inferius.

The *superior maxillary bone* is of a very irregular figure, and attached to all the bones of the upper jaw; it forms the greater part of the front of the face, and a portion of the orbit, of the nose, and of the palate. It may be divided into the body and processes. The *body* is concave anteriorly, to form the infraorbital or canine fossa, in the upper part of which is the infraorbital hole. This fossa is bounded externally and above by a rough, serrated, triangular surface, the *malar process*, which is smooth and hollowed out behind for the temporal muscle. Springing from the inner and upper part of the body is the *nasal process*, of a pyramidal form, perforated by one or two small holes for vessels, serrated above to join the os frontis, prominent below, slightly grooved anteriorly to receive the nasal bone and the alar cartilage, and deeply grooved behind to form part of the lachrymal fossa and duct: its internal surface forms part of the nasal fossa, and is connected to the ethmoid bone above. Below this is a channel that leads to the middle meatus; and inferior to this is a crest for the inferior spongy bone. Between the nasal and malar processes is the *orbital plate*, of a triangular form, the base joined to the ethmoid, lachrymal, and palate bones. This process looks obliquely outwards and forwards; its outer and posterior edge bounds the spheno-maxillary fissure. The

infraorbital canal, which runs along it in a direction forwards and inwards, lodges the vessels and nerves of that name. This canal divides anteriorly into two; the smaller is the *anterior dental*, which descends in the anterior wall of the antrum, where it terminates by communicating with the anterior alveoli; the other, or the proper *infraorbital canal*, is wider, and ends in the *infraorbital hole.* The edge of the bone above this hole is round, to form part of the contour of the orbit, behind which the inferior oblique muscle of the eye arises. Behind and below this plate is the *tuberosity.* This is more prominent in the young, as it contains the last molar tooth, after the protrusion of which it diminishes. Near this are three or four small holes, the *posterior dental canals*, which lead to the posterior alveoli. Beneath the orbital plate the body of the bone is excavated into a large cavity, the *antrum Highmorianum*, of a somewhat triangular figure, the base towards the nose, the apex towards the malar process. This is the largest sinus connected with the nose; it is sometimes divided by septa, as well as by the anterior dental canal, into two or more cells. The infraorbital canal runs along its roof; through the floor one or two of the molar alveoli project, and sometimes open; the canine fossa is in front of it, and the tuber bounds it behind. This cavity is lined by the membrane of the nose. In the skeleton the opening in its base is very large and irregular, but in the natural state it is contracted by the ethmoid and lachrymal bones above, by the palate bone behind, and by the inferior spongy bone below, also by the lining membrane of the nose; it opens by one or two small oblique openings into the middle meatus of the nose, anterior to which is the *infundibulum*, a deep groove leading from the frontal sinus and the anterior ethmoid cells downwards, backwards, and inwards, and opening into the middle meatus. The body of the bone is bounded below by a strong horizontal plate, the *palatine process*, the upper surface of which is smooth and concave, and forms the floor of the nose; the lower is rough, and

Fig. 101.*

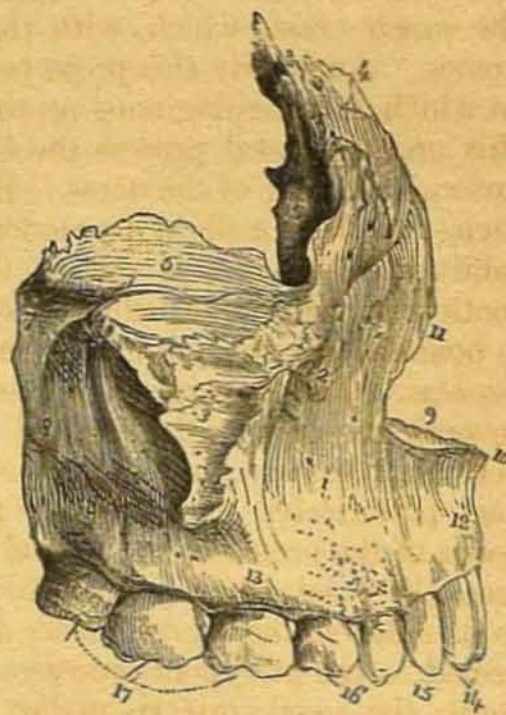

* The external surface of the superior maxillary bone. 1. The canine fossa. 2. The infraorbital hole. 3. The malar process. 4. The nasal process. 5. The groove which forms part of the lachrymal fossa and duct. 6. The orbital plate. 7. The commencement of the infraorbital canal. 8. The tuberosity of the superior maxilla. 9. The nasal crest of the palatine process. 10. The nasal spine. 11. The concavity forming the lateral margin of the anterior nares. 12. The incisive or myrtiform fossa. 13. The alveolar process. 14. The two incisor teeth. 15. The canine tooth. 16. The two bicuspidati. 17. The three molares.

forms the roof of the mouth, and is deeply grooved near the alveolar arch for the posterior palatine nerves and vessels: it is thick before, thin and serrated behind to join the palate bone; internally it is thick and rough, and joins the opposite bone by a suture, in the anterior part of which is the anterior palatine canal, which opens inferiorly on the palate by the *foramen incisivum*, and superiorly by two distinct holes, one in each nostril. This internal edge is raised so as to form the *nasal crest*, which, with that of the opposite side, receives the vomer. Anteriorly this projects so as to form the anterior *nasal spine*, to which the cartilaginous septum of the nose is attached. Between this and the nasal process the bone is very concave, and forms the anterior opening of the nares. Beneath the nasal spine, and above the incisor teeth, is a slight depression (*myrtiform*), in which the depressor labii superioris muscle arises; the prominent alveolus of the canine tooth separates the myrtiform from the canine fossa. The palate plate is bounded anteriorly and externally by the curved *alveolar edge* or *process*. This is very thick, particularly behind, and is divided into several, generally eight, conical cavities for the teeth: the partitions between these are formed of dense cellular texture, which is less compact posteriorly. The superior maxillary bone is connected to two bones of the cranium, the frontal and ethmoid, and seven bones of the face, the nasal, lachrymal, malar, palate, inferior spongy, vomer, and to its fellow of the opposite side, also to the teeth: it is sometimes connected to the pterygoid processes of the sphenoid. The processes are eight, the nasal, orbital, malar, tuberosity, alveolar, palatine, nasal crest, and nasal spine. The foramina are two proper and four common; the proper are the infraorbital and foramen incisivum. The common are the spheno-maxillary fissure, the foramen antri, the posterior palatine hole or canal, the anterior nares, and the nasal or lachrymal duct. This bone is of great transverse breadth, and is well developed in the fœtus, with the exception of the alveoli and sinus, the former commence about the end of the first year, the latter about the seventh, but a depression corresponding to it exists at birth. Ossification commences in the embryo at a very early age by four points: two in the orbital plate, one at each side of the infraorbital canal, one in the palate plate, and one in the incisor portion of the alveolar arch and anterior portion of the palate. This latter portion remains partly distinct from the rest of the bone for two or three years, and is rudimental of its permanent state in many animals, in which it is named os incisivum or intermaxillare.

The *palate bone* is situated at the outer and back part of the nose, between the pterygoid processes and the superior maxillary bone. It is of a very irregular figure, and may be divided into four parts: first, the horizontal or palate plate; second, the nasal or perpendicular plate, at the lower and outer angle of which is, third, the pterygoid process; and, fourth, at the upper extremity of the nasal is the orbital portion. The *palate process* or plate is nearly square, flat, and rough below, smooth above, and concave from side to side to form part of the floor of the nose. Posteriorly it has a thin edge, to which

the velum palati is attached ; its anterior border is serrated and cut off obliquely to join and rest upon the palate plate of the maxillary bone; its inner edge rises into a *crest* to support the vomer, and is continued posteriorly into the *posterior nasal spine.* Its centre is thinner than its edges. The *nasal process*, or vertical plate, is broad and thin ; rises at right angles from the palatine ; it rests partly on the maxillary bone. Its inner or nasal surface forms part of the nasal fossa, and is marked by two depressions, which assist in forming the lower and middle meatus of the nose : the ridge between these supports the lower spongy bone, and to that above the upper depression the middle spongy bone is attached. Externally it is uneven and grooved for the posterior palatine vessels and nerves. The anterior edge of this plate is thin and brittle, and prolonged for some way over the antrum ; the posterior edge joins the pterygoid processes. The *tuberosity*, or the *pterygoid process*, arises from the lower and outer angle, is thick and wedge-shaped, inclines backwards, outwards, and downwards, and presents three fossæ, one at each side for each pterygoid plate, and one in the middle, which assists in forming the pterygoid fossa. The innermost of these fossæ is the deepest. This process is perforated by one or two small holes which lead from the palatine canal. At the upper extremity of the nasal plate are the *orbital* and *sphenoidal processes*, separated from each other by a deep notch. The *orbital* is the larger and anterior of the two ; it is triangular, and bent a little outwards ; it appears in the most remote part of the floor of the orbit, where it is joined to the maxillary bone by one edge, to the ethmoid and sphenoid by the second, while the third enters into the spheno-maxillary fissure. The sphenoidal or posterior orbital process is smaller, and is articulated to the body and spongy plate of the sphenoid bone, and assists in closing the sphenoid sinus. Both these processes are cellular ; the cells communicate with those of the ethmoid and sphenoid bones. The notch between these two processes forms the spheno-palatine hole. The palate bone is joined to six bones, the maxillary, inferior spongy, vomer, sphenoid, and ethmoid, and to the opposite palate bone. It is composed of thin, compact substance, and is well formed in the fœtus. Its processes are seven : palate, nasal, pterygoid,

Fig. 102.*

* A posterior and internal view of the palate bone. 1. The superior surface of the horizontal or palate plate. 2. The internal surface of the nasal or perpendicular plate. 3. The pterygoid process. 4. The orbital process. 5. The spine or crest which articulates with the opposite bone and supports the vomer. 6. The posterior nasal spine. 7. The ridge which supports the lower spongy bone. 8. The depression which receives the internal pterygoid plate. 9. The depresssion which receives the external pterygoid plate. 10. The groove which assists in forming the pterygoid fossa. 11. The sphenoidal process. 12. The spheno-palatine hole.

orbital, sphenoidal, posterior nasal spine, and crest. Its foramina are one proper and three common. The proper is the posterior palatine hole or holes; the common are the posterior palatine or pterygo-maxillary canal, the spheno-maxillary fissure, or the foramen lacerum orbitale inferius, and the spheno-palatine hole; the latter is above the nasal plate, below the body of the sphenoid, and between the orbital and sphenoidal processes of the palate bone; it transmits the nasal nerve and artery from the spheno-maxillary fossa into the nose.

The *inferior spongy* or *turbinated bone*, placed on the lower part of the outer side of the nose, elongated from before backwards, broad before, pointed or conical behind, presents a wrinkled or a rugged surface; is convex inwards, or towards the nose; concave outwards; its lower edge is loose, spongy, and curled outwards; the upper edge is uneven, thin, and joined to the unguis and to the maxillary and palate bones. It is connected to the unguis by a thin *pyramidal process*, which completes the nasal duct; it is also in general united to the descending oblique process of the ethmoid. It is composed of very thin, brittle substance, marked with pores and little spines. It forms the floor of the middle and the roof of the lower meatus. Ossification commences from a central point: this is small in the fœtus. It is connected to four bones.

The *os unguis*, or *lachrymal bone*, is placed at the inner and forepart of the orbit, below the os frontis, behind the nasal process of the superior maxillary, and before the os planum; it is of an oval shape, and very thin: it covers the anterior ethmoidal cells. Externally it is divided by a perpendicular ridge, which terminates below in a little hook-like process into two unequal plates. The posterior or *orbital plate* is short and broad, and slightly concave; the anterior or *lachrymal plate* is very concave, long, and narrow, and forms part of the lachrymal or nasal fossa and duct. Its internal or nasal surface presents a vertical groove corresponding to the ridge on its orbital surface; its posterior portion is rough and slightly convex, and covers the anterior ethmoid cells: the anterior portion is very convex, and enters into the middle meatus. The os unguis is joined above to the internal angular and orbitar processes of the os frontis; behind to the os planum of the ethmoid, below to the orbitar plate of the maxillary, before to the nasal process of the same, and before and below to the inferior spongy bone; its structure is very thin, but very compact. Ossification commences early from a single point, and is complete at birth. It is joined to four bones.

The *nasal bones* are situated beneath the nasal process of the frontal and between the nasal processes of the superior maxillary bones; they are small and narrow, thick above, thin and expanded below: they form the bridge of the nose. The external surface of each is slightly concave from above downwards, convex from side to side, and perforated with one or two small holes; the internal surface is concave and grooved for the nasal nerves. The superior margin is thick and deeply denticulated, to join the nasal process and spine of the frontal and the nasal plate of the ethmoid bones. Its external edge is grooved,

and joins the nasal process of the superior maxillary; its inner edge is flat, to join with its fellow, and both are a little grooved posteriorly; and its lower edge is very thin and irregular, joins the alar cartilages, and is notched for the passage of the nasal branches of the ophthalmic nerves. It is composed of two compact plates, with intervening diploe above. Ossification begins in one point. It is joined to four bones.

The *vomer*.—This azygos bone resembles a ploughshare; it stands in the median line, although it often bends a little to one side, is thin and flat, and covered by the pituitary membrane. It presents four edges. The upper or sphenoidal, the thickest and shortest, is hollowed to receive the azygos process. The anterior is slightly grooved posteriorly, to receive the ethmoidal lamina; anteriorly it joins the nasal cartilage. The posterior or pharyngeal is sharp, smooth, and unattached, and separates the posterior nasal openings. The inferior or palatine edge is the longest, and is received between the laminæ of the nasal crest of the maxillary and palate bones; it is attached to the two maxillary, the two palate, the ethmoid, and sphenoid bones; also to the turbinated bones of the latter. Its structure is compact, but thin and transparent. Ossification commences from a single point, and in its lower portion; it appears at first as a groove or two lamellæ, between which the septal cartilage is lodged. Ossification advances from below upwards, and the lamellæ unite, except superiorly, where they receive the sphenoid and ethmoid azygos processes.

The *inferior maxillary bone*, or the lower jaw, is the largest of the facial bones, of a semicircular figure, situated at the lower part of the face, and extending along its sides and back part to the base of the skull; it is divided into the body or chin, the sides, the rami, and the processes. The *body* is the anterior prominent portion, with a vertical ridge in the centre; the *symphysis*, or the line of union of the two symmetrical pieces of which in infancy it consisted. Inferiorly the body projects into the *mental process* or *chin*. Above this on each side is a depression for the muscles

Fig. 103.*

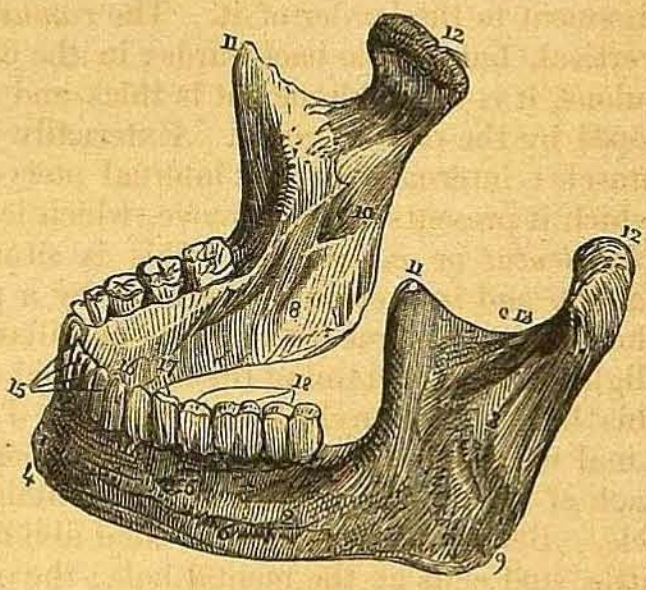

* The inferior maxillary bone. 1. The symphysis. 2. The side. 3. The ramus. 4. The mental process. 5. The mental foramen. 6. The external oblique ridge. 7. The internal oblique line. 8. The groove for the mylo-hyoid nerve. 9. The angle. 10. The inferior dental hole. 11. The coronoid process. 12. The condyle. 13. The sigmoid notch. 14. The alveolar process. 15. The four incisors. 16. The canine tooth. 17. The two bicuspides. 18. The three molares.

of the lower lip; external to which, and looking backwards, is the oval oblique opening of the dental canal, called the *mental hole*, through which a vessel and nerve of the same name pass. Posteriorly the body of the bone is concave, and lined above by the mucous membrane. In the middle it presents, in the line of the symphysis, a chain of eminences, to the superior of which the frænum linguæ adheres, to the middle the genio-hyo-glossi, and to the inferior the genio-hyoidæi muscles. Above and on each side of these are depressions for the sublingual glands, and at the lower border are two depressions for the digastric muscles. The *sides* of the maxilla have a direction backwards and outwards; on their outer surface is an oblique line, which passes backwards and upwards to the anterior edge of the coronoid process; it gives attachment before to the platysma and depressor anguli oris, and behind to the buccinator muscles. Internally, also, is an oblique line, parallel to, but more prominent than the external; to this is attached the mylo-hyoid muscle anteriorly, and the superior constrictor of the pharynx and intermaxillary ligament posteriorly. Beneath this *mylo-hyoid line* is a slight groove, which contains the mylo-hyoid nerve, and below this an oblong depression for the submaxillary gland. The lower edge or base of the jaw is rounded, thick before, thin behind, and grooved opposite the second molar tooth for the facial artery. The upper or alveolar edge is broad posteriorly, and bent a little inwards; it has usually sixteen alveoli, which, as in the upper jaw, vary in form according to that of the teeth. The *angle* of the jaw is nearly a right one in the adult, but in the fœtus is very obtuse; its margin is often a little everted; the masseter adheres to it externally, the internal pterygoid internally, and the stylo-maxillary ligament to the border of it. The *ramus* ascends in the adult nearly vertical, but a little backwards; in the child, and in the old or edentulous, it is very oblique: it is thick and round posteriorly, and enveloped by the parotid gland. Externally it is covered by the masseter muscle; internally by the internal pterygoid, above the insertion of which it presents a deep groove, which leads to a large hole, the *inferior dental* or *maxillary*. This is situated near the centre of the ramus, and is protected internally by a prominent spine, into which the internal lateral or temporo-maxillary ligament is inserted. A slight groove, containing the mylo-hyoid nerve and vessels, leads from this hole to the mylo-hyoid muscle. The dental hole leads into a canal which traverses the side of the bone beneath the alveoli, with each of which it communicates; it contains the dental nerve and vessels. Below the incisors this canal divides; one portion turns back a little, and ends at the mental hole; the other continues forwards beneath the incisor teeth. This canal is nearer the inner surface of the jaw behind, and the outer surface before. The ramus ends above in a notch and two processes, the anterior or coronoid, the posterior or condyloid. The *sigmoid notch* is traversed by the masseter nerve and vessels. The *coronoid process* is triangular; the apex is inclined a little outwards and backwards; it is embraced by the insertion of the

temporal muscle, which descends lower on its internal surface. The root is grooved anteriorly for the attachment of the buccinator muscle. The *condyle* is an oblong, convex process, supported by a neck, which is most depressed anteriorly for the insertion of the external pterygoid muscle. The condyle is curved forwards, and most convex in that direction; its long axis is transverse, but is directed obliquely backwards and inwards, so that its internal extremity is posterior; it is also higher than the external: its posterior surface is nearly straight or flat, and almost free from cartilage. By these processes the lower maxilla is articulated with the temporal bones. On the external edge of each is a tubercle for the insertion of the external lateral ligament. The lower jaw in the fœtus always consists of two symmetrical pieces, which become united about the end of the first year. Each angle is very obtuse, and the condyles are directed more upwards than in the adult. Ossification occurs in it earlier than in any other part of the skeleton, even before the clavicle. In each lateral portion it commences by a central point; if examined in the embryo of five or six months an additional or separate point is also to be found in the inner part of the alveolar arch on each side.

As the teeth are intimately attached to the maxillary bones, and apparently are allied to the osseous more than to any other structure, their description and general anatomy may now be examined. They are not, however, to be considered as parts of the skeleton, inasmuch as they have not appeared in the very young, and are frequently absent in the very old; neither, critically speaking, do they constitute any portion of the osseous system, but rather appertain to the digestive apparatus, being the mechanical instruments employed in the prehension, separation, and mastication of the food, the incisors cutting and dividing it, the canine tearing it, and the molars bruising and grinding it. In man the teeth also assist in speech, certain articulate sounds (dental consonants) being produced by the point of the tongue striking against these bodies during expiration. In zoological science the teeth serve as an important element in the classification of the animal kingdom; their peculiar form and structure indicate the nature of the food on which the animal is to subsist; and as the digestive organs must be so modified as to convert the numerous varieties of nutriment into chyle, and as the limbs must be adapted for its prehension, so the teeth must bear an intimate relation to the entire organization, as well as to the habits of the animal.

Teeth differ from bone in many essential points. First, the greater portion of every fully-formed tooth is naked and exposed to the air, whereas all parts of a bone are invested by periosteum or by cartilage. Second, the central cavity in a tooth contains a vascular pulp instead of medulla. Third, the surface and intimate structure of a tooth are more compact, less vascular, and less organized, and with less of the animal and more of the mineral ingredients, than bone. Fourth, their diseases and powers of recovery differ from those of bone. Fifth, their duration is less than that of the general system, and they are changed

or renewed once during life, the first set being temporary and deciduous, and succeeded by one which is permanent, but whose duration seldom equals that of the skeleton. Sixth, as to their development and growth. The matrix of a tooth is a vascular bulb or papilla enclosed in a membraneous sac, which at first is only a depressed follicle, a mere indentation or prolongation of the gastro-pulmonary mucous membrane, and hence the stages of dental growth are distinguished by the terms papillary, follicular, and saccular, instead of, as in the case of bone, gelatinous, cartilaginous, and osseous. In order to acquire a knowledge of dental structure and development, the student should not only examine preparations in the museum, but also make careful dissections of the maxillary bones of the fœtus and infant at different ages. Although Hunter and Blake have ascertained many most important facts connected with these subjects, and the more modern writings of Purkinjie, Retzius, Muller, Goodsir, Nasmyth, and others, have added considerably to our knowledge, yet it must be admitted that dental anatomy is still, in many points, imperfect and uncertain.

We shall first consider the form and structure of the teeth.

The *teeth* are small, hard bones, thirty-two in number in the adult, sixteen in each jaw; their form is generally conical, the apex in the alveoli. In each tooth we distinguish the crown, neck, and root. The *crown* is external to the alveolus; it has no periosteum, but is covered by a firm, white, vitreous substance, named enamel. The *neck* is surrounded by the gum, and the *root* is firmly held in the alveolus by a mode of connexion called *gomphosis;* it is covered by the periosteum, which lines the alveolus, and which is reflected upon it from the point to the neck. The root or fang of each tooth is perforated by a small hole for the nutrient nerve and vessels. The teeth are divided into three classes, the incisores, the canini, and the molares.

The *incisores* are four in each jaw. The crown of these is sharp and wedge-shaped, convex before, and thickly covered with enamel. The neck is constricted, and the root is conical, but flattened upon each side. Those in the upper are stronger and larger than those in the lower jaw; the former are broader; their edge is like a chisel, cut off posteriorly; the latter are more vertical, and bevelled off anteriorly; they are not so sharp as those in the upper jaw; their roots are larger. The middle incisors in the upper jaw are much larger than the lateral, but in the lower the lateral are a little larger than the middle.

The *canine teeth*, or *cuspidati*, are two in each jaw, or one on each side of the lateral incisors. The crown is conical, a little blunt, convex before; their root is single, but very long, and larger than those of the incisors, flattened at the sides, and grooved. Their alveoli are often very prominent.

The *grinders*, or *molares*, are twenty in number, ten in each jaw. The crown of these is broad and irregular; the roots are more or less divided. The two first molar on each side in each jaw are called *bicuspidati*, and are of an intermediate size between the canine and poste-

rior molars. They have only two tubercles on the crown, which is rather round. The fangs in some are single, but usually double; the lower are smaller than the upper, and the tubercles on the crowns are not so deeply separated. The first lower bicuspid frequently wants the inner tubercle, and resembles a canine. The posterior grinders are the true molar or *multicuspidati*, three on each side in each jaw. These are large; the crown is somewhat square, has four, and sometimes five tubercles; the neck is thick and round; the root has three or four divisions, and each is perforated by a small hole. The crowns of the lower are rather larger than those of the upper; the latter are vertical, but the former are inclined a little inwards. The fangs of the lower are usually two, but very broad and strong, placed anteriorly and posteriorly, often much curved, flattened before and behind, grooved, and often bifid. The first and second upper have usually three roots, one internal, two external; sometimes they have four. The first molar is generally the largest; the last, or dens sapientiæ, is the smallest; its crown is short, and has only three tubercles, two external and one internal. The root, though often single, is grooved, and sometimes presents three partial divisions in the upper and two in the lower. These last teeth, however, are very variable as to size and other characters, and occasionally even are not protruded, particularly in the upper jaw.

Every tooth, when divided, presents an external shell or cortex, and an internal cavity which extends beneath the crown, partly corresponding to it in form, contracts as it descends through the root into a fine tube, which ends in a minute foramen. In the young and growing tooth this cavity is large, and contains a soft, vascular pulp or bulb; in the course of time it is much diminished by surrounding osseous or ivory deposit, and in the adult or aged contains little more than a vascular lining membrane. The parietes of this cavity, though very firm, are perforated by numerous minute pores, which lead into the solid texture of the tooth. The substance of a tooth consists of three elements: enamel, ivory or dentine, and crusta petrosa or cement. The enamel covers the crown; the ivory forms the greater portion of the body and root; and the crusta, in the form of a thin lamina, invests the root only, though, according to Nasmyth, it is also prolonged over the crown and enamel. In the compound teeth of the herbivora this ingredient enters largely into their composition, forming with the enamel vertical plaits, which alternate with plaits of ivory or dentine, and present their margins to the grinding surface, which is thereby always retained in a rough state, as the three substances wear unequally, the enamel being the hardest, and the crusta the softest.

Enamel covers only the exposed portion of the tooth, is thickest on the most prominent parts of the crown, that is, on the cutting edges and grinding points; it becomes thin towards the neck, where it ends in an abrupt line within the margin of the gum. It is of a milk-white colour, extremely hard and brittle, can strike fire with steel, resists the file or saw, and is, therefore, peculiarly well adapted to withstand

friction and pressure: heat soon renders it friable, and after a long time blackens it; whereas this latter change soon occurs in ivory, as it contains much more of an animal basis. If, therefore, a section of a tooth be exposed for a short time only to a strong, clear heat, the blackened ivory and the unchanged enamel become separated by a well marked line of distinction. It is composed of minute fibres or prisms, arranged in close parallel lines, marked with fine transverse striæ, placed perpendicular to the ivory, to which they are intimately attached. A delicate membrane is said by some to intervene, and to be demonstrable after maceration in a dilute acid. In a longitudinal section the fibres become apparent, taking a wavy, but still a parallel course, and under magnifying powers appear to be composed of minute, hexagonal, crystalline cells, connected in a linear order, and filled with calcareous substance. When enamel has been steeped in dilute acid, the salts are removed, and a very small portion of delicate animal tissue remains, the membraneous cells in which the mineral matter had been contained. The chemical composition of enamel is, in 100 parts: phosphate of lime, 85.3; fluate of lime, 3.2; carbonate of lime, 8; phosphate of magnesia, 1.5; membraneous matter, water, and soda, 2. This preponderance of the earthy materials accounts for the durability of the enamel during life, as well as for its almost imperishable character in animal remains.

Ivory or *dental bone*, or *dentine*, is the chief constituent of a tooth; is of a yellowish white colour; its fracture presents a soft, silky, fibrous appearance. Though not so hard as enamel, it is much harder and closer in texture than bone. At first view it appears a homogeneous solid, but, if examined in a young tooth, or when steeped in weak acid, it presents a fibrous and reticular texture, and under high magnifying powers the fibres are found to be minute tubuli, arranged in a different order from those of the enamel. These tubes commence in the walls of the cavity, which are cribriform, and take a serpentine and radiating course towards the surface, or towards the enamel, subdividing and ramifying with great minuteness, the interstices being filled with fibrous substance, on which the ivory is deposited in lines parallel to the tubes; and the tubes themselves contain small, opaque bodies, supposed to be the nuclei of the ivory cells. Retzius has delineated these tubes in a very beautiful manner, and described them as dividing soon after they leave the central cavity in a dichotomous manner, and also giving off numerous fine offsets, some of which anastomose, and some can be traced into small cells, like those in bone, thus presenting a close analogy, in the elementary structure, of dentine and true bone. He has also observed that the arrangement of these tubes differs in different classes of animals. The chemical composition of ivory or dental bone is, in 100 parts: phosphate of lime, 61.95; fluate of lime, 2.10; carbonate of lime, 5.30; phosphate of magnesia, 1.25; soda and chloride of sodium, 1.40; cartilage and water, 28.

Crusta petrosa, or *cement*, is a thin, osseous lamina, coating each root or fang from its point to the enamel at the neck. It is thin in the

young, but increases in thickness in the aged, and sometimes even forms an exostosis on the roots, and partly fills up the cavity in the fang and in the body of the tooth. It is not so vascular as bone, but resembles it in other respects, containing the same anastomosing tubuli and calcigerous corpuscles. The minute tubes and cells in this substance communicate with those in the dentine; accordingly, when the pulp has disappeared, or if the central cavity be wholly obliterated, the dental tubes may receive a supply of fluids from without, that is, from the crusta petrosa, which derives its vessels from the periosteum. In the compound teeth of the herbivora it is very abundant, filling up the interstices between their different crowns or divisions.

Although no vessels can be seen permeating this dental structure, yet it cannot be wholly extravascular or inorganic; most probably the minute tubuli absorb some fluid from the pulp in the central cavity, and circulate it through the general tissue. In young animals fed on madder the dentine becomes coloured, like the rest of the osseous system; and even in old animals the same change of colour will occur if this food be long continued. In jaundice also, of long duration, the teeth have sometimes acquired a yellowish tint; and occasionally these bodies shew some power in repairing the effects of disease, a new lamina of crusta, or even of ivory, being sometimes thrown out upon a carious surface.

The *dental pulp*, *papilla*, or *bulb*, is of the same form as the cavity which encloses it. It consists of a delicate, soft, membraneous, reticular texture, very vascular and sensitive. The vessel which supplies it is a small branch of the dental artery; it enters the canal in the fang, and forms a capillary net-work on the pulp; the nerve accompanies the artery, and is derived from the dental branch of the superior or inferior maxillary nerve. The reticular tissue of the pulp is described by Mr. Nasmyth as consisting of a congeries of nucleated cells, in which the calcareous salts are deposited from the blood, and which are converted into ivory upon the surface, and as one set of cells is removed another set is produced from the capillary net-work. The pulp is larger in the very young tooth than subsequently, and, together with the dental capsule, is mainly concerned in those processes of development and growth which we shall next consider.

The development of the teeth commences at a very early period of intra-uterine life. According to the researches of Goodsir (Edinburgh Med. and Surg Jour., Jan., 1839), the process may be divided into four stages, the papillary, follicular, saccular, and eruptive. The rudiments of these organs have been observed by him in an embryo of the sixth week, whose weight was only fifteen grains, and length little more than half an inch. He states that about the sixth week the upper maxillary bone presents a deep, narrow groove within the external alveolar margin; this is the *primitive dental groove*, and is lined by the mucous membrane. About the seventh week a small papilla appears on its floor, near its posterior part; this is the germ of the anterior deciduous molar. In the eighth week that for the canine,

and in the tenth those for the incisors appear, and, next, that for the posterior deciduous molar. This is the *papillary stage*, and is followed by the *follicular*, which is not completed until the fourth or fifth month ; this is effected by delicate processes, extending from the sides of the dental grooves over each papilla, and meeting before and behind it, so as to enclose it in an open follicle. The first is formed around the anterior molar, and the rest soon follow. The papillæ now begin to change their form, and to assume that of the future teeth. The follicles next become closed by small membraneous processes, extending from their edges across the openings. The incisors have two of these opercula, the canine three, and the molars four or five. When these opercula have adhered to the margins of the follicles, the latter are converted into sacs, and the *saccular stage* commences ; this continues from about the fourth month to the completion and eruption of the teeth, which occur at different periods of infantile life : the incisors about the seventh or eighth month after birth, the canine and bicuspides still later, and the last molar or wisdom tooth not until the twentieth year. It is during the saccular stage that the most important and interesting phenomena in dental growth occur, namely, the enlargement of the papilla into a pulp or bulb, the formation of the dentine and enamel, the changes in the maxillary bones, and the ossification of the alveolar processes.

Soon after the commencement of the saccular stage of the deciduous teeth the rudiments of the second or permanent set are developed. About the fourteenth week the deep portion of the primitive dental groove is closed in, and contains the sacs and papillæ of the ten milk teeth ; the upper or superficial portion of the groove remains open, and is now named *secondary dental groove*. In this commence the rudiments of the permanent teeth. At first a small crescentic depression is observable behind the opercula of the milk sacs ; this increases, and forms the *cavity of reserve*. These cavities are lined by an inflection of the mucous membrane, and at the bottom of each a small papilla is formed ; they gradually recede from the surface, and are thereby converted into follicles, and finally into closed sacs, which lie to the inner side and in close contact with the former set, and enclosed in the same submucous tissue. The necks of these sacs, by which they originally communicated with the general mucous membrane, continue as obliterated cords leading to the surface of the gum, internal to the deciduous teeth. These cords have been named the *gubernacula*, or itinera dentium ; from which, however, we are not to infer that these cords answer any such office as their name would imply. The primitive dental groove, behind the posterior deciduous molar, does not close so soon as the anterior portion, and in it are developed about the fifth month the follicle and papilla of the anterior permanent molar. After its follicle has closed, the dental groove closes over it, leaving a space between the gum and the sac of this tooth ; in this is a cavity of reserve of mucous membrane for the second permanent molar, and one also for the third or the wisdom tooth. As the deciduous sacs, as

well as the anterior permanent ones, increase in size more rapidly than the bones can elongate, this cavity for the permanent molars is pressed backwards into the maxillary tuberosity above, and into the root of the coronoid process below; but in a few months after birth, as the jaws increase in size and length, the first permanent molar returns to its proper level in the dental range, the cavity of reserve behind then dilates into the space the first molar occupied, and in it is developed the papilla for the second permanent molar. In the course of time, as the jaws further elongate, this tooth advances and descends, and the remainder of the cavity of reserve dilates behind for the third permanent molar or wisdom tooth. Before we allude to the fourth, or the eruptive stage of either set of teeth, we have to consider the mode of growth of these bodies in the dental sacs. As soon as the pulps assume the shape of the future teeth, they form upon their surface the ivory or dental bone; this process commences about the fourth or fifth month of intra-uterine life, and the ivory is deposited on the most prominent points of the teeth, that is, upon the cutting edges and grinding points. The number of points on each tooth is variable; on the incisors there are three, on the canine one, on the bicuspides two, and on the molars four or five points. In the fœtus at birth, and for some time previous to it, the border of each maxillary bone presents a groove or channel, covered by a dense and whitish fibrous tissue, adhering to and continuous with the gum on either side. On raising this we find imperfect bony and membraneous septa between the alveoli, and into each of the latter a prolongation from this fibrous lamina extends, enclosing each dental follicle in a distinct sac, which is perforated at the bottom for the passage of the nutrient vessels and nerves. If any one of these dental bags be examined, it will be found to resemble a serous sac, and to contain a little fluid. The external or parietal layer is fibro-cellular, lines the alveolar depression, is connected to its periosteum, and is reflected from the bottom of it, around the vessels and nerves, over the pulp, on which it forms the tunica propria, and which is highly vascular. This lamina was originally, that is, in the follicular stage, mucous membrane; the pulp itself rises from the fundus of the sac where the vessels enter, and carries before it this vascular tunica propria. On the surface of the pulp the ivory or dental bone is deposited; the more superficial of the nucleated cells which it contains become elongated, and are disposed vertically on the surface; and as these become calcified those beneath become similarly arranged, and so on until the tooth acquires considerable thickness, and the greater part of the pulp is ossified. The process commences in points or spots varying in number in the different teeth; in the molars by four or five, in the bicuspides by two, in the canine by one, and in the incisors by two or three. All these points increase in size and thickness, and coalesce so as to form a deep hollow shell, the extreme margin of which is thin and elastic, like horn, but the centre is thick and stratified, the inner laminæ being the last formed and the longest, as they extend to the root or fang. This shell encloses the pulp all

around, except on its under surface, where the vessel and nerve enter it; it then begins to contract around the future neck and fang, and, as the latter elongates, the whole mass appears to rise towards the gum; at first there is no process of the pulp answering to the root, but as the cavity of the tooth is diminished the pulp is elongated, and sinks into the alveolus, and continues to deposit the dentine around it; the alveolus now contracts, and grasps the neck and commencing root, and adheres to the latter through the investing membrane; an alveolar edge gradually rises up along with the tooth, so that the latter does not really sink so much into the bone as it appears to do. If more than one root is to be formed, the opposite margins of the ivory shell extend across the pulp, meet in the middle, and divide the cavity into two or more openings or tubes, through each of which portions of the pulp extend, and around each ivory is produced. During this process the dental sacs are large, and contain a quantity of granular matter, which is gradually absorbed; and when the ivory shell is formed, the interior of the parietal layer of the dental sac has a villous and vascular appearance, like mucous membrane, with a thin layer of granular matter upon it, which may be considered as a sort of epithelium lining the interior of the opercula of the original follicles. This surface, therefore, is the matrix of the enamel, or is the enamel organ, and it is impossible that this substance can be produced from the pulp, or from its vessels, as the former is now enveloped in the ivory shell. The enamel, therefore, is produced by the calcification of the nucleated prismatic cells contained in the granular epithelium lining the opercula of the dental sacs; it is deposited at first, and in greater quantity, upon the most prominent points of the tooth, but soon forms a coating all over the crown and around the body, as far as the neck, where it is thin and ends abruptly, there being none upon the fang, as there the outer wall of the sac has become adherent to the root, and of course leaves no space for enamel deposit. The enamel appears to be deposited upon the ivory in minute crystalline, calcareous particles, at first not very hard or compact, but these soon solidify and adhere most intimately to the ivory, abutting on its surface, its fibres or prisms being in a different direction to that of the dental tubes and fibres. According to some a delicate membrane can be detected between the ivory and enamel in a tooth some time steeped in dilute acid; and Purkinjie conceives that the ivory is deposited between the pulp and its investing capsule, while the enamel is formed external to the latter by the enamel organ.

The *crusta petrosa*, or cement, forms a thin coating around the root or fang, and is formed by the lower or alveolar portion of the dental sac, which invests and adheres to the root, and is converted into this substance. According to Nasmyth (Med. Chir. Trans., vol. xx.), the inner layer of the upper portion of this capsule remains adherent to the crown, and forms upon the enamel a thin coating of crusta, which, however, is soon worn off.

The *eruptive stage* commences when these several parts of the tooth

are completed, and appears to result partly from the elongation of the fang causing the elevation of the tooth, and partly from the absorption of the superincumbent structure, which at last gives way at some small point; the tooth then protrudes, and the sac again assumes its open or original follicular form. This opening encircles the neck of the tooth, and forms a closely fitting collar around it, and is continuous externally with the gum. The protrusion of the tooth rapidly increases, and more so than can be ascribed to the elongation of the fang mechanically raising it, by pressing against the bottom of the alveolus; on the contrary, indeed, there is an interval left beneath the root to admit of its growth and completion, and, therefore, the elevation of the tooth would appear to depend partly on a shortening or contraction of the dental sac. Prior to the eruption of the milk teeth, the septa between them have become ossified, and perfect alveoli have been formed. During this period, also, the sacs of the ten anterior permanent teeth, which at first were connected to the submucous tissue of the deciduous sacs, have been retiring in an opposite direction, and sinking deeper in the bone, and become enclosed in osseous cells, which gradually extend beneath the fangs of the temporary teeth, and are separated from them by their distinct alveoli; and the fibrous cords extend from the necks of the temporary sacs along the sides of the alveoli to the surface of the gum. The permanent sacs at first receive their vessels from those of the gum, but afterwards from the temporary sacs; and as they retire into their own cells these new vessels enter into new dental canals, which become permanent. In the course of a few years, and after all the temporary teeth have appeared, the further elongation of the jaws admits of space for the first true molar to protrude; this usually occurs between the seventh and eighth year. At this age there are fifty-two teeth in the head, viz.: twenty deciduous, twenty permanent beneath these, and the twelve posterior molars: and when all the anterior permanent teeth have become enlarged they press upon the anterior wall of their alveoli, which soon undergo absorption, and then each tooth comes a little forwards into the lower part of the alveolus of the milk tooth: the fangs of the latter are absorbed and gradually wholly removed, and then the crown falls out of the sac, and the permanent tooth supplies its place. The absorption of the milk root, however, is not to be attributed wholly to the pressure of the permanent tooth against it, for it often occurs long before the permanent tooth has entered its alveolus. Neither the deciduous nor permanent teeth appear at perfectly regular periods. The four central incisors usually protrude about seven or eight months after birth; those of the lower jaw first: the lateral incisors follow about the ninth or tenth month; about a year or a year and a half the anterior molars, and then the canine; between the second and third year the posterior molars appear. There is no certain rule as to the priority of those of the upper and lower jaw, except in respect to the incisors, and in general the development on each side proceeds *pari passu*. About the seventh year, as was before mentioned, the first

permanent molar appears, nearly about the time when the first incisors are replaced by the permanent. After all the incisors are changed, the anterior and posterior temporary molars are successively shed and replaced by the permanent bicuspides; the canines are not changed before the tenth or eleventh year. About the twelfth or thirteenth, the second permanent molars appear; and the last, or dentes sapientiæ, seldom before eighteen or twenty, but occasionally at a much later period.

SECTION VI.

THE THORAX OR CHEST

Is formed posteriorly by the twelve dorsal vertebræ, already described, laterally by the twelve pairs of ribs, and anteriorly by the costal cartilages and sternum.

The *sternum* is situated at the forepart of the thorax, in the median line, and in an oblique direction from above downwards and forwards, its superior end being much nearer to the spine than its inferior; flat and elongated, broad and thick above, narrow in the middle, and thin and pointed below; its average length is six inches, and a little more in the male than in the female: it has been resembled to a sword, the upper piece named manubrium or handle, the middle gladiolus, and the lower extremity ensiform or xiphoid cartilage. Although it can often be separated in the adult into these three pieces, we shall first describe it as one bone. Its *anterior surface*, flat or slightly convex, is covered by the skin, and gives attachment to the pectoral aponeurosis and to the tendons of the sterno-mastoid muscles, and is marked by transverse lines, which indicate its original division into six pieces. Of these lines the two uppermost, especially the first, are the most prominent. Its *posterior* surface is smooth and slightly concave, covered by

Fig. 104.*

Fig. 105.†

* The posterior surface of the sternum. 1. The posterior surface of the first piece of the sternum which gives attachment to the sterno-hyoid and sterno-thyroid muscles. 2. The second piece of the sternum, giving attachment inferiorly to the triangularis sterni or sterno-costalis muscle. 3. The posterior surface of the xiphoid cartilage or appendix, to which the anterior fibres of the diaphragm are attached.

† The anterior surface of the sternum. 1. The upper piece of the sternum. 2. The middle piece. 3. The xiphoid appendix, or ensiform cartilage. 4. An

a thick and glistening periosteum, and marked by transverse lines corresponding to, but less prominent than those in front: the sterno-hyoid and thyroid and triangulares sterni muscles are attached to this surface; the pericardium also has a cellular connexion to it. The *superior* or *cervical end* is thick and broad, and very concave transversely. This semilunar concavity or notch corresponds to the root of the neck, and is occupied by the interclavicular ligament; at each angle of it is the articular cavity for the clavicle, covered with cartilage, and directed outwards and backwards, slightly convex from before backwards, and concave from within outwards. The *inferior* or *abdominal end*, or *xiphoid process*, is the smallest portion, thin, and usually cartilaginous in part; is very variable as to form and size, sometimes pointed, sometimes bifid, thick or thin, turned forwards or backwards, and sometimes perforated by a central hole. To it are attached the linea alba, the abdominal aponeuroses, and the costo-xiphoid ligaments. The *sides* or *lateral edges* of the sternum are thick and uneven, marked by the articular depressions for the seven costal cartilages, and by intervening semilunar notches. The superior depression is shallow, and immediately beneath the clavicular surface; its edges are often continuous with the first costal cartilage: the remaining depressions are angular and deep, and correspond to the transverse lines; hence these sockets are more distinct in the young than in the old; they are all covered with cartilage, and separated by semilunar notches, which are larger above than below, as the inferior cartilages are closer to each other than the superior.

Ossification commences rather late in the sternum, and proceeds slowly and variably: a cartilage of the same form exists in the embryo of the fourth or fifth month, and ossific development occurs at least in six different parts. In the manubrium, it commences about the fifth month, in one central or in two lateral or symmetrical nuclei, which soon unite. In the body or middle portion there are four central nuclei, but sometimes double; these ossific points are nearly opposite the costal cartilages. The ossification of the xiphoid appendix seldom occurs before three or four years; it commences in its upper part, and slowly extends downwards. These six pieces do not unite for many years. The four divisions of the middle portion are joined together about twenty-four years of age; the fourth and third first join, then the second joins the third, and, lastly, the first joins the second. The xiphoid appendix is seldom ossified to the middle portion before the fortieth year, and the body and manubrium are never wholly united until old age, and even then seldom completely so. Of the three pieces into which the adult bone can be separated, the first, or the manubrium, presents the clavicular articulating surface on each side, also the socket for the first, and half the socket for the second

oblique surface for articulation with the clavicle. 5. The notch which receives the cartilage of the first rib. 6. The notch formed partly by the first and partly by the second piece of the sternum for articulation with the cartilage of the second rib. 7. The depression for the cartilage of the third rib. 8, 9, 10, 11. Depressions which receive the cartilages of the fourth, fifth, sixth, and seventh true ribs.

costal cartilage; the second portion, or gladiolus, presents on either side six notches, one to complete the socket for the second cartilage, one for each of the four following, and half a one for the seventh, the remainder being made up by the xiphoid appendix. A foramen often exists in the lower part of the middle division, of very variable size; it is closed by membrane, and is probably the result of some arrest in development. Two small osseous appendices are occasionally found in the fully developed sternum, one at each side of and behind the semilunar notch in the upper border of the manubrium. They have been named *presternal* or *suprasternal points*, and are regarded by some as the sternal ends of non-developed cervical ribs, and by others as the analogue of the fourchette bone in birds. The sternum is articulated to sixteen bones, viz., the clavicles and the seven true ribs of each side; it is maintained in its situation wholly by the latter, and its upper end supports the clavicles and the superior extremities; it completes the anterior wall of the thorax, and affords immediate protection to the heart. It consists of a spongy, vascular diploe, invested on each surface by a lamina of compact tissue. Its nutrient vessels enter numerous foramina in its posterior surface.

The *ribs* are twelve on each side; they extend in an arched manner from the vertebræ towards the sternum, to which the seven superior are attached by separate cartilages; these are the *true* or the *vertebro-sternal ribs*. The five inferior, with their cartilages, do not reach the sternum, but are connected anteriorly to each other, and to the cartilage of the last true rib, and are named *false* or *vertebro-costal*, or *asternal*. The two last of these are sometimes called *floating* or *vertebral* ribs. The length of the ribs gradually increases from the first to the eighth, and then diminishes to the last; the breadth gradually diminishes from the first to the twelfth, but in each rib, except the two last, it is greatest near the sternum. The first rib is nearly horizontal, the succeeding gradually incline downwards, so as to be lower before than behind. The *external surface* of the *body* or shaft is convex and smooth, and gives attachment to different muscles; the internal is concave, and lined by the pleura. The *upper border* is round and smooth, and gives attachment to the intercostal muscles. The *inferior* forms a wider curve than the superior, is thin, and marked with a groove on its inner side; deep posteriorly, and superficial anteriorly; its edges give attachment to the intercostal muscles; posteriorly it lodges the intercostal vessels; it disappears anteriorly. The *posterior end* of a rib presents a head, neck, and tuberosity. The *head* is round, and divided by a ridge into two articular surfaces, the inferior of which is the larger; these are received into the depressions in the dorsal vertebræ: an interarticular ligament is attached to the middle ridge. The head is supported by the *neck*, which is thick, round, and strong, and lies in front of the transverse process, to which its posterior surface is connected by the middle costo-transverse ligament. On its upper border is a ridge or crest, to which the anterior or internal costo-transverse ligament is attached. Beyond

or external to the neck is the *tubercle*, which looks backwards and downwards, and is divided into two portions. The internal is smooth for articulation with the transverse process of the inferior of the two

Fig. 106.*

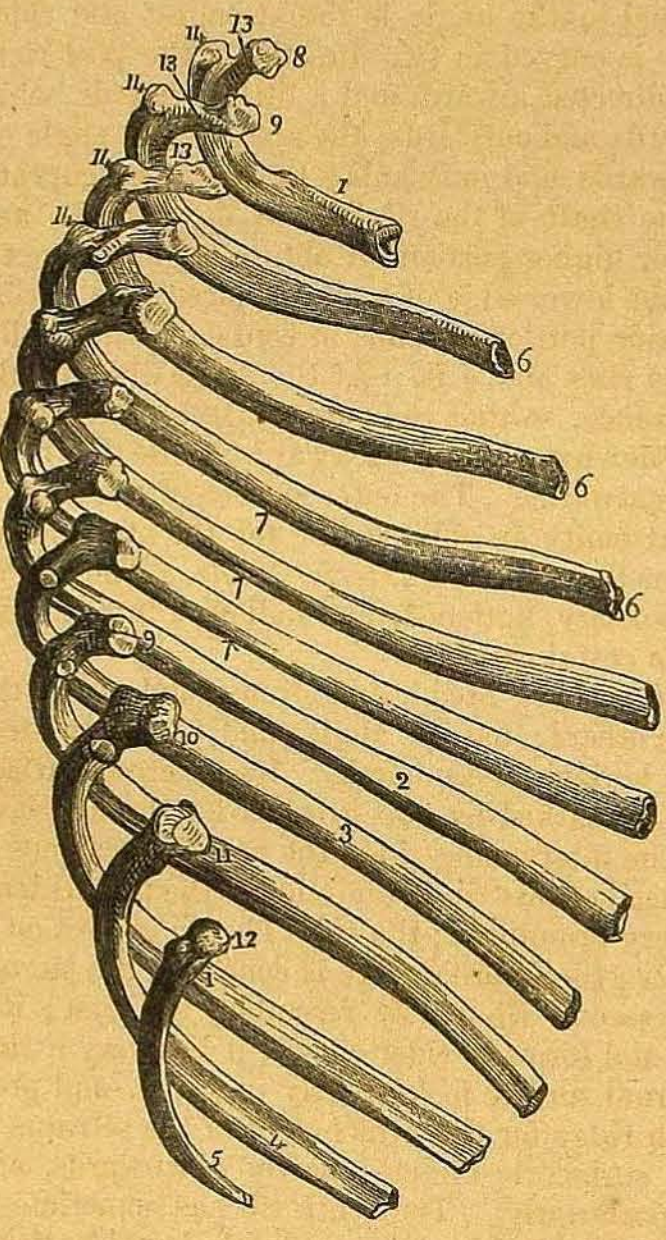

vertebræ, to whose bodies the head of the rib is connected. The external is rough, for the insertion of the external costo-transverse ligament. External to the tubercle, and on the posterior surface, is a

* View of the internal surface of the ribs. 1. The first true rib. 2. The seventh or last true rib. 3. The eighth or first false rib. 4 and 5. The eleventh and twelfth or floating ribs. 6. The anterior extremity of the rib. 7. The inferior margin of the rib, grooved internally for the intercostal vessels and nerve. 8. The head of the first rib, presenting a single articular surface. 9. Heads of the ribs from the second to the ninth inclusive, presenting two articular facettes, separated from each other by a ridge. 10. 11. 12. The heads of the tenth, eleventh, and twelfth ribs, each presenting a single articular surface. 13. The neck of the rib. 14. The tubercle of the rib.

rough line, which marks the turn or *angle* of the rib. This ridge gives insertion to the tendon of the sacro-lumbalis muscle; it descends obliquely forwards; it is close to the tubercle on the first, but the distance between these increases in the succeeding ribs to the eleventh: the angle is not distinct on the twelfth. That portion of the rib behind or internal to the angle is the strongest and thickest: at this point the bone is curved in two directions, the posterior or vertebral portion being directed inwards and a little forwards, while the shaft is directed forwards and outwards; the apex of this angle of curvature is directed backwards and outwards; by the other curvature the anterior part or the shaft of the rib is bent downwards, and forms with the posterior or higher portion an obtuse angle, convex downwards; hence, when the lower edge of a rib is placed on a horizontal surface, only the anterior portion remains in contact with it; all that part behind the angle rises above it. At the angle the rib also presents a twisted appearance, so that the outer surface of the vertebral portion has an aspect downwards and backwards, while that of the shaft looks upwards and outwards. The outer surface of the shaft presents near its anterior extremity an oblique line for the attachment of muscles; this line is sometimes named *anterior angle*. The anterior or *sternal end* is thick, spongy, flattened, and hollowed into an oval pit for the insertion of the costal cartilage.

The *first rib* is short, broad, and strong, and nearer the axis of the chest than the others; has no angle, and is not twisted, but represents nearly a horizontal semicircle. Its external surface is directed upwards, and is marked by two grooves for the subclavian vein and artery; into the intervening ridge the anterior scalenus muscle is inserted. The head of this rib is undivided; the neck is long and round; the tubercle very prominent; the shaft has no groove on its inferior or external border; the internal edge is concave; the sternal end is very strong. The second rib partly resembles the first; it is, however, much longer, and forms a wider curve; it has very little angle or torsion; its external surface looks partly upwards, and presents near its centre a rough ridge for the attachment of the serratus magnus muscle; its inner surface is directed partly downwards, and presents a short groove posteriorly. The tenth rib has sometimes but one articular surface at its head to join the tenth dorsal vertebra. The eleventh and twelfth also have each but one articular surface on the head; they have neither tubercle, angle, nor groove; they are short and thin, and pointed anteriorly. The ribs are formed of a cellular structure, covered by a compact and strong lamina, which often presents a scaly appearance; in form they resemble the long bones, but in tissue the flat or irregular. In the young the cancellated structure prevails, but in the old the compact; hence in the former they are more resisting and elastic, and in the latter more brittle, and, therefore, more liable to fracture. The nutrient arteries enter the bones on their inner or pleural surface, and their canals uniformly are directed obliquely backwards in the shafts, although the intercostal arteries are

running forwards, but in the vertebral extremities the vessels pursue irregular and variable directions. Ossification commences in the ribs at a very early period of uterine life, even in the second month, and rather sooner than in the vertebræ: there are three points of ossification, one for the head, another for the tubercle, and the third for the body or shaft; the latter is the primitive and the principal one, the two former are epiphyses, and do not appear till the fifteenth year, and are not joined to the rest of the bone until the twenty-fifth. The two last ribs want these epiphyses. In the fœtus the ribs are straight, their posterior curvature less developed; their shafts continue forward more in a direct line, and do not slant downwards, as in the adult; their angles do not project posteriorly so as to enlarge the thorax in that direction, and, therefore, the lungs do not extend into those hollows on either side of the spine which become subsequently developed. In some cases there are thirteen ribs on one or both sides, these supernumerary bones being developed either from the anterior transverse process of the last cervical, or of the first lumbar vertebra. More rarely there is a deficiency in the number; in such a case the first rib may be only rudimental, or two adjacent ribs may be united together.

The *costal cartilages* must be considered as part of the skeleton of the thorax; they are of the permanent class, and are twelve in number, and of nearly the same form as the shafts of the ribs, which they serve to prolong anteriorly, and, being extremely elastic, contribute to the general functions of the cavity. The costal end of each is broader than the sternal; the former is convex, and received into the depression in the end of the rib; the latter, also convex, into the angular fossa, on the border of the sternum. Their anterior surface is flat or slightly convex, covered by and attached to the great pectoral muscle. Their posterior surface is smooth and concave, and partly lined by pleura. Their margins bound the intercostal spaces, and give attachment to the internal lamina of intercostal muscles. The first is very broad, but short; the length increases in the succeeding to the seventh, and then decreases to the last: the first descends a little, the second is nearly horizontal, the succeeding ascend more and more. Those of the three superior false are blended together, and those of the two last are short, pointed, and unattached, except to the abdominal parietes. The costal cartilages are the strongest and longest in the body; they are flexible and elastic, and have a great tendency, particularly the four or five superior, to ossification; the costal end is more prone to this change than the sternal; they then become opaque and very compact. In their natural state they appear destitute of vessels, nerves, or any organic texture, but are enveloped by a vascular membrane.

The *thorax*, which is composed of the foregoing bones and cartilages, resembles, when the arms are detached, a truncated cone, the base below, the apex above, flattened before and behind; in some, and often from the effect of dress, it is of an ovoid form, being con-

tracted at the lower part and wide in the middle. The anterior wall is flattened, leads obliquely downwards and forwards, and is shorter

Fig. 107.*

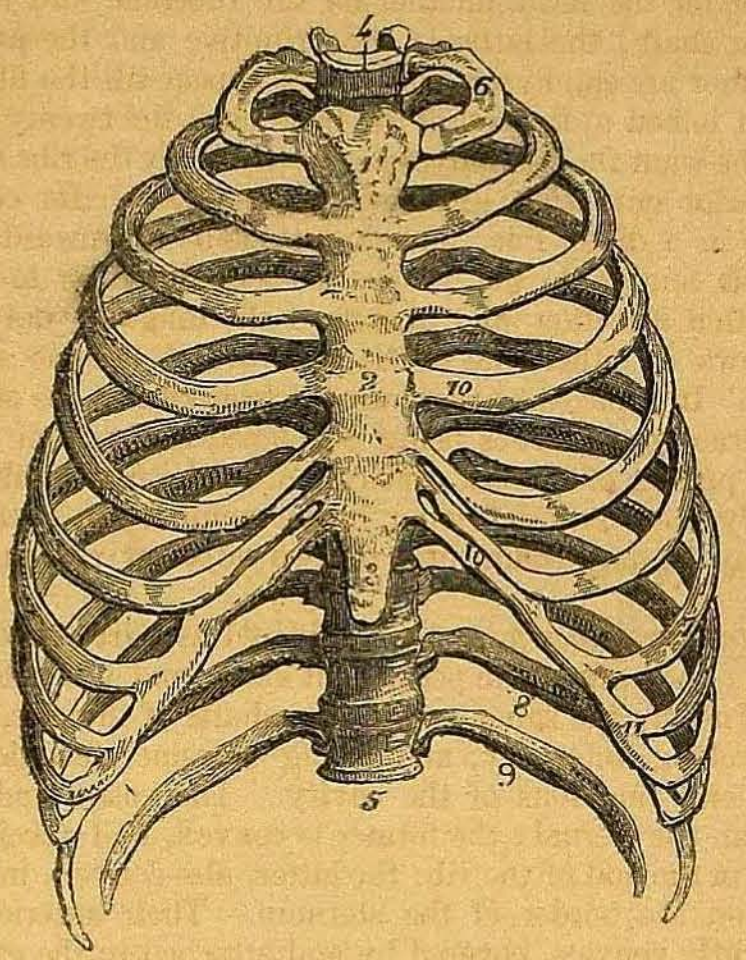

than the posterior, which is more vertical, and rendered very irregular by the vertebral grooves, and the angles of the ribs. The sides are convex, particularly behind. The intercostal spaces are short, but wide above, long and narrow in the middle, and again short below; they are broader before than behind. The apex is small, transversely oval, and very oblique from behind forwards and downwards. It is bounded by the first ribs, sternum, and vertebral column, and is also contracted by the clavicles: the trachea, œsophagus, and the cervical vessels and nerves pass through it. The base in the skeleton is undefined; it is very large, also transversely oval, and very oblique from before backwards and downwards. It is bounded by the xiphoid cartilage, the conjoined cartilages of the false ribs, and the vertebral co-

* Anterior view of the thorax. 1. The manubrium or upper piece of the sternum. 2. The second or middle piece. 3. The xiphoid or ensiform cartilage. 4. The body of the first dorsal vertebra. 5. The body of the twelfth or last dorsal vertebra. 6. The first rib. 7. The seventh or last true rib. 8. and 9. The last two false ribs, sometimes called floating ribs. 10. The costal cartilages of the true or sternal ribs. 11. The costal cartilages of the superior three false ribs blended together.

lumn; it presents a great notch anteriorly, divided into two by the xiphoid cartilage, and posteriorly a small notch on each side of the vertebral column. The axis of this opening is directed downwards and forwards; it is closed by the diaphragm. The axis of the chest is oblique from above downwards and forwards, in consequence of the oblique direction of the sternum; hence, if a line be made to ascend perpendicularly from the base, it will pierce the upper part of the sternum, and not pass through the apex of the cavity. The axis of the cavity, therefore, is not vertical, but leads from above downwards and a little forwards, on account of the obliquity of the anterior wall. The dimensions, and even the form of the chest, vary in different individuals and at different ages, and under a variety of circumstances, normal and abnormal. No accurate estimate of these can be formed from its examination in the skeleton, as the diaphragm which forms its inferior boundary has an extended range of motion, and enlarges or diminishes the cavity in proportion as it descends or ascends (*see* Diaphragm, page 290). Its capacity may be considered as a medium between that of the cranium and abdomen, and bears a tolerably exact ratio to the size of the lungs. Its parietes combine the elements of solidity and mobility, and are thereby fitted not only to protect the heart and lungs, but also to admit of the respiratory motions. The lateral parietes of the thorax also contribute inferiorly to the protection of the abdominal viscera, the extent varying according to the degree of elevation or descent of the diaphragm. The thorax is larger, deeper, and longer in the male than in the female; in the latter it is shorter, but often broader inferiorly than in the former. The thorax presents three diameters, the antero-posterior, the transverse, and the vertical; and these of course must differ in different parts of the cavity. The *antero-posterior* is longer below than above, and is shorter in the middle line, in the situation of the heart and great vessels, than at either side, where the chest is expanded on a plane posterior to the bodies of the vertebræ. The *transverse diameter* is greatest between the eighth ribs of opposite sides. The *vertical* is the longest of the three, and is of greater extent on either side than centrally, as the lateral fleshy portions of the diaphragm, which are beneath the lungs, descend much lower than the central tendon which supports the heart. This diameter is subject to greater alterations than either of the others, but they are all increased during inspiration, and diminished by expiration. All these arrangements correspond in an obvious manner with the function of the enclosed organs. In the fœtus, before respiration has commenced, the form of the thorax presents a striking contrast with that of the adult. The cavity is short, and very broad below, flat behind, and compressed upon the sides. The antero-posterior diameter is considerable in the median line, to accommodate the heart and thymus gland, but not so much so on either side, as the posterior concavities formed by the angles of the ribs are not developed. The upper orifice is longer from before backwards than transversely. The vertical diameter is shorter, as the ribs descend less

obliquely, and pass round rather in horizontal curves. The intercostal spaces are less, and the bones are more close together. The base or lower circumference is of greater transverse breadth, the ribs of opposite sides being here separated and a little everted to accommodate the great size of the liver. Immediately after birth, when respiration has commenced, the thorax becomes considerably expanded, and the peculiarities just alluded to gradually disappear, until about the period of puberty, when again a considerable increase in size occurs, and the thorax acquires the adult form and character. The motions of the ribs and their cartilages we shall consider when speaking of their ligaments.

SECTION VII.

THE PELVIS

Is the irregularly circular-shaped cavity at the lower end of the trunk, bounded by the sacrum and coccyx posteriorly, and by the ossa innominata laterally and anteriorly; it contains some of the abdominal

Fig. 108.*

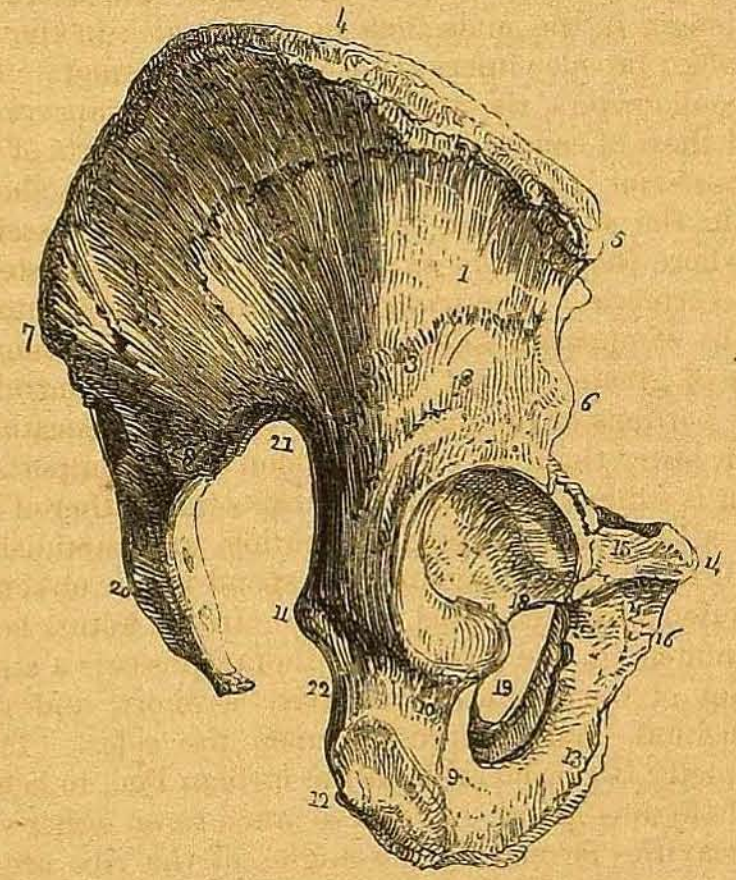

* A lateral view of the pelvis, shewing the os innominatum of the right side. 1. The external surface of the os ilium. 2. The superior curved line. 3. The

viscera and many of the urinary and generative organs; it also supports the spinal column above, and transmits the weight to the thigh-bones, on which it rests below. The sacrum and coccyx have been described at page 709. As each os innominatum is divisible in early life into three bones, the ilium, ischium, and pubis, it appears advisable to describe each of these separately in the first instance, and afterwards to consider them as united into a single bone, in which condition they are found after puberty.

The *os ilium* is situated at the upper and outer part of the pelvis, and forms that projection commonly called the hip. It is broad, flat, and triangular, the base above, bounded by a semicircular crest, which ends before and behind in processes or tubercles named spinous; the apex below, forming the upper and outer part of the acetabulum: it may be divided into the body, ala, and processes. The *body* is the inferior constricted portion, which presents three surfaces: one, external, smooth, and concave, forms the upper and outer portion of the acetabulum; the second is anterior, small, triangular, and united to the pubis; the third is posterior, and joined to the ischium. The *ala* is the broad, fan-like, semicircular portion, which ascends from the body, inclines outwards and a little forwards. Its *external surface* or *dorsum* is rough and irregularly convex and concave; bounded above by the crest, and below by a prominent arch, which separates it from the body, or from the acetabulum; anteriorly this surface is concave, then very convex; more posteriorly, and above the acetabulum, it is hollowed out into a considerable concavity (external iliac fossa of some), and, lastly, its posterior portion is again convex; it is marked by two curved semicircular lines, a superior and inferior. The *superior* is very long, and usually well marked; commences at the crest, about two inches behind the anterior superior spine, and bends downwards and backwards to the posterior part of the great sciatic notch; to this line, and to a great portion of the bone above it, the glutæus medius muscle is attached. The superior posterior part of the ilium is also marked and subdivided by a short, *oblique ridge*, leading from the back part of the crest, about two inches in front of the posterior superior spine, backwards and downwards, to the posterior inferior spine. To this ridge (by some named superior), and to the rough surface above it, the glutæus maximus is attached. The *inferior semicircular line* commences at the notch above the anterior inferior spine, curves backwards and downwards to the forepart of the great sciatic notch. From this ridge, and from the surface be-

inferior curved line. 4. The crest of the ilium. 5. The anterior superior spinous process. 6. The anterior inferior spinous process. 7. The posterior superior spine. 8. The posterior inferior spine. 9. The ischium. 10. The groove for the tendon of the obturator externus muscle. 11. The spine of the ischium. 12. The tuberosity of the ischium. 13. The ramus of the ischium. 14. The os pubis; the number is placed at the angle. 15. The horizontal ramus of the os pubis. 16. The descending ramus of the os pubis. 17. The acetabulum. 18. The great notch in the acetabulum. 19. The thyroid or obturator foramen. 20. A lateral view of the sacrum. 21. The great sacro-sciatic notch. 22. The lesser sacro-sciatic notch.

tween it and the superior, the glutæus minimus arises. Below this line the bone swells into its prominent body, to form the upper and outer part of the acetabulum. To this prominent surface the glutæus minimus is partly attached, and from it the external tendon of the rectus and part of the capsular ligament arise.

The *internal surface* of the ala is divided into three parts. One, superior and anterior, is the *iliac fossa*, which looks upwards, forwards, and inwards; it gives origin to the iliacus internus muscle, and presents the opening of an oblique canal for the nutritious artery of the cancellated structure and medulla; it forms the sides of the upper or false pelvis, and supports the abdominal viscera. The second forms about the posterior third of the bone; is rough, and divided into two parts, the posterior of which is very uneven, for the attachment of the sacro-iliac ligaments. The anterior is somewhat semicircular, convex forwards, of the form of the external ear, and is covered by a lamina of cartilage, which articulates with the corresponding surface of the sacrum by synchondrosis. The third is smooth and small, and is the only portion of the ilium that enters into the side of the true pelvis: this pelvic portion of the ilium is above the sacro-sciatic notch, and is separated from the iliac fossa by a rounded edge, which is continuous behind with the promontory of the sacrum, and before with a sharper ridge on the pubis. This line is named *ilio-pectinea;* into the posterior portion of it the iliac fascia is inserted, and into the anterior the same fascia, together with the psoas parvus and the third insertion of Poupart's ligament or Gimbernaut's ligament. The iliac portion of this line is remarkably strong, and much thicker than the bone above; these strong, rib-like lines extend from the ilio-sacral symphisis on each side in a direction towards each cotyloid cavity; they form a powerful support to the sacrum, and receive from it the superincumbent weight of the trunk, and transmit the pressure to the acetabula and to the heads of the thigh bones.

The *processes* are, first, the *crest*, which in the young subject is an epiphysis; it forms the upper border of the ala; is curved inwards before and outwards behind; is convex above, and alternately convex and concave from before backwards, like an italic *S;* it gives attachment to the three layers of abdominal muscles, also to the latissimus dorsi and fascia lata of the thigh externally, and to the iliac fascia internally. Second, *anterior superior spine* is the prominent projection at the upper and forepart of the crest and ala; it gives attachment to Poupart's ligament and to two muscles, the sartorius and tensor vaginæ femoris. Between this and the next process is a notch. Third, *anterior inferior spine* is above the outer part of the acetabulum; it gives attachment to one head of the rectus femoris muscle. The notch between these processes is occupied by the sartorius and iliac muscles and an external cutaneous nerve. Internal to the inferior spine is a superficial groove, along which the psoas and iliac muscles pass. This groove is bounded internally by the *ileo-pectinæal eminence*, which is common to and formed by the union of the ilium and pubis. Fourth,

the *posterior superior spine* is the posterior termination of the crest, below which is a notch: and, fifth, the *posterior inferior spine.* These two processes give attachment to muscles and to the sacro-iliac and sciatic ligaments. Beneath the inferior the bone is arched to form the upper boundary of the sacro-sciatic notch.

The *ischium* is placed at the lower, outer, and back part of the pelvis, and presents a body and processes. The *body* forms the outer, lower, and back part of the acetabulum, more than two-fifths of which it forms, and presents a prominent line or border. Beneath this is a horizontal groove, which lodges the tendon of the obturator externus, in its course to the trochanteric fossa; and from this a rough ridge leads down to the tuber of the bone, and gives attachment to the quadratus femoris muscle. The anterior part of the body is thin and sharp, and bounds the obturator or thyroid hole inferiorly and externally; the posterior part joins the ilium, and bounds the sacro-sciatic notch anteriorly. The processes are, first, the *spine*, which arises from near the middle of the posterior part, just below the sacro-sciatic notch; it projects backwards and inwards, gives attachment to the superior gemellus and to the lesser sciatic ligament, with which it bounds the great sciatic notch inferiorly, and converts it into a large foramen. Below the spinous process, between it and the following, is the smooth pulley round which the tendon of the obturator internus muscle turns. Second, the *tuberosity* which is beneath this pulley. On this rough and broad process the body rests in the sitting posture; it is covered with cartilage, and marked by three flattened facets; to the anterior the semimembranosus muscle is attached, to the two posterior the biceps and the semitendinosus; to the outer the adductor magnus, inferior gemellus, and quadratus femoris; its inner edge is sharp, and projects a little into the cavity of the pelvis. To this and to a corresponding edge on the ramus a portion of the great sciatic ligament is attached, so as to form a grooved surface to support the pudic vessels and nerves. Between the spine and tuberosity is the lesser sciatic notch, which is converted into a foramen by the great sciatic ligament, which bounds it posteriorly; the pulley bounds it in front. Third, the *ramus* ascends from the tuber forwards and inwards, and joins that of the pubis; it is flat, narrow, and a little everted; one border is thin, and bounds the thyroid hole inferiorly and internally, the other is thick, and in part bounds the lower aperture of the pelvis. To it are attached the crus of the penis or of the clitoris, and its compressor muscle.

The *os pubis* is situated at the forepart of the pelvis, and is smaller than the ilium or ischium. It may be divided into its body and processes. The *body* is the most external portion, is thick, and forms the internal and superior part of the acetabulum, above which it joins the ilium in the ileo-pectinæal eminence, and below it is united to the body of the ischium; its posterior surface is smooth and flat, and forms the anterior wall of the pelvis. From the body the first process proceeds, the *horizontal ramus*, forwards and inwards, smooth and concave superiorly, and covered by the pectinæus; smooth also

posteriorly towards the cavity of the pelvis, and grooved beneath, where it bounds the obturator foramen, and gives passage to the obturator vessels and nerve. A sharp ridge separates its superior from its posterior surface: this ridge is the anterior part of the linea innominata or ileo-pectinæa, which forms the brim of the true pelvis. Into the pubic portion of this line the pectinæus muscle, Gimbernaut's ligament, and the fascia lata, are inserted. Anterior and external to this ridge, the ramus is slightly concave, and supports the femoral vessels; external to which is the ileo-pectinæal eminence, and still more externally and on the ilium is the groove for the psoas and iliac muscles. At the internal extremity of this ramus and of this line is the second process, the *tuberosity* or *spine*. This is a prominent tubercle into which Poupart's ligament is inserted. From this spine the third process, the *crest*, leads transversely inwards; it is about an inch in length: the rectus abdominis and pyramidalis muscles, also the conjoined tendons of the transversalis and internal oblique, are attached to it. At its internal end is the fourth process, the *symphisis*. This descends nearly vertical, is rough and oval, and is joined to the opposite one by an intervening fibro-cartilage. As the symphisis turns down from the transverse crest there is the *angle* of the pubis. From the lower part of the symphisis descends the fifth process, the *inferior* or *descending ramus*, in an oblique direction, backwards and outwards, to meet the ramus of the ischium; this with the ramus of the opposite pubis forms the *arch of the pubis;* the outer edge of the ramus assists in bounding the thyroid hole.

When these three bones are conjoined, as they are in the adult, they constitute the *os innominatum*, or *haunch bone*, the form of which must be very irregular. It is articulated posteriorly to the sacrum, and anteriorly to its fellow in the symphisis pubis; it forms the side and front of the pelvis, and presents externally, a little below its centre, the acetabulum for the head of the femur. From this cavity the three portions diverge, the ilium passing upwards and backwards, the pubis inwards, forwards, and then downwards, and the ischium first downwards, then upwards and inwards, to join the pubis. The middle portion, or that corresponding to the acetabulum, is narrow and somewhat twisted, so that the inner surface of the upper or iliac portion looks upwards, forwards, and inwards, while the same surface of the lower or pubic and ischiatic portions looks backwards, upwards, and inwards. The *superior border* of the os innominatum is bounded by the crest of the ilium, curved, and terminating before and behind in the spinous processes, already described. The *anterior border* extends from the anterior superior spinous process of the ilium to the symphisis pubis; is formed by the ilium externally and pubis internally, and is irregularly convex and concave; below the anterior superior spine is the notch which contains the sartorius muscle; then the inferior spinous process, internal to which is the wide groove for the psoas and iliac muscle; next is the ileo-pectinæal eminence, internal to which is the smooth and slightly concave surface of the pubis, which supports

the femoral vessels and the pectinæus muscle; of a triangular form, the apex internally at the spine or tubercle, and bounded posteriorly by the ilio-pectinæal ridge. Internal to the spine is the crest leading inwards to the angle at the symphisis. The *posterior border* of the os innominatum extends from the superior posterior spine of the ilium to the tuberosity of the ischium; it is very irregular, and presents first a notch; then the posterior inferior spine; below this the great sciatic notch, bounded below by the spine of the ischium; beneath which is the lesser sciatic notch, or pulley, for the obturator internus tendon, and lastly, the tuber ischii. The *inferior border* extends from the tuber ischii obliquely upwards, forwards, and inwards, to the angle at the upper edge of the symphisis pubis. The *internal* or *pelvic surface* presents, superiorly and posteriorly, the rough surface for the attachment of the sacro-iliac ligaments; anterior to which is the auricular-shaped surface for articulation with the sacrum. The remainder of this inner surface is divided into a superior and inferior portion by the ileo-pectinæal line, which is round posteriorly, and formed by the ilium, and sharp in its anterior or pubal portion. Above this line is the iliac fossa; below it the bone is smooth and concave posteriorly, and anteriorly it presents the obturator foramen, between the pubis and ischium. The *external surface*, in its superior portion, looks backwards, outwards, and downwards; is irregularly convex and concave; and is marked by the glutæal semicircular lines. The anterior inferior portion looks downwards, outwards, and forwards, and presents the acetabulum with its prominent margin, and more internally the obturator foramen, and inferiorly the tuber ischii, between which and the acetabulum is the groove for the external obturator tendon; and, lastly, to the inner side of the obturator hole, the rami of the ischium and pubis, leading upwards and inwards to the oval symphisis, and presenting a flat surface, narrow in the centre, and marked with a rough line at this point of union.

The *acetabulum* is formed by the junction of the bodies of the three bones in different proportions; the ischium constitutes a little more than two-fifths, the ilium somewhat less than two-fifths, and the pubis the remainder, or one-fifth. It is surrounded by a prominent border, which presents a deep notch or deficiency internally, and two smaller notches or grooves, one superiorly, the other inferiorly and externally. The *great notch* is opposite the thyroid hole, between the ischium and pubis, but chiefly in the former bone; it is at the anterior and inferior part, and is converted into a foramen by a ligament extended over it from the pubis to the ischium: it may serve to admit of more free adduction of the limb; it also allows the articular vessels to enter the joint. A rough surface, perforated by nutrient foramina, and the only part uncovered by cartilage, leads from it to the centre of the cavity; to this and to the edges of the notch the articular ligament and a quantity of adipose tissue are connected. The cotyloid cavity looks outwards, downwards, and forwards; the upper and outer portion, by which the weight of the head and trunk

are transmitted to the thigh, is the deepest; it is shallow at the lower and internal part. The pubis bounds it anteriorly and internally, the ilium superiorly, and the ischium posteriorly; it is of a hemispherical form, and about two inches and a half in diameter; its prominent margin, uneven and notched, gives attachment to the glenoid fibro-cartilaginous brim which contracts the orifice and deepens the cavity.

The *obturator* or *thyroid foramen* is situated at the inner side of the acetabulum, and on an inferior level. In the male it is oval; in the female it is smaller and triangular, the narrow part below; its long diameter is oblique from above downwards and outwards; the edge is thin and uneven, and interrupted superiorly by a groove which leads from within the pelvis obliquely forwards, downwards, and a little inwards. Through this canal the obturator nerve and vessels pass. The remainder of the opening is closed by a strong fibrous membrane, to the surfaces of which, and of the adjacent bone, the obturator internus and externus muscles are attached. It is bounded above by the pubis, externally and inferiorly by the body and ramus of the ischium, and internally by the united rami of the pubis and ischium. Superiorly it presents two lips; the anterior is continuous with the external half of its margin, the posterior with its inner half; the inner passes backwards and the outer forwards, and the obturator groove is between them. Around the pelvic or internal margin this bone is depressed into a fossa for the internal obturator muscle.

The *pelvis*, which is thus made up of the ossa innominata, the sacrum, and ossa coccygis, may next be examined as one great portion of the skeleton, placed in an inclined position between the spine and the lower extremities, and bounding a large cavity, wide and open above into the abdomen, and contracted below towards the perinæum. Internally this cavity is imperfectly divided by the brim or the linea ileo-pectinæa into two regions, the superior or false, the inferior or true pelvis. Externally the pelvis presents in front the symphisis and crests of the pubes, the ileo-pectinæal eminences; beneath these the acetabula and the thyroid holes, and more externally the anterior spinous processes of the ilium; laterally the dorsum of the ilium, marked by its curved lines; and posteriorly the sacral spines in the median line, external to which are the sacral foramina; beyond these, on each side, a rough surface for the attachment of ligaments and muscles; and, lastly, the great sacro-sciatic notches, bounded by the sacrum, ilium, and ischium. The *superior* circumference or *base* of the pelvis, which is inclined upwards and forwards, is formed on each side by the crest of the ilium; posteriorly by the promontory of the sacrum, on each side of which is a deep notch, filled by muscles; anteriorly by the iliac spines, ilio-pubal eminences, the intervening grooves, and crests and symphysis of the pubes. The *lower* or *perinæal* circumference, or strait or apex or outlet of the pelvis, is directed downwards and a little forwards; bounded by the rami of the pubes, the rami and tubera ischii, the coccyx, and in the recent state by the sacro-sciatic ligaments of each side; but when the latter have been

removed, as in the artificial skeleton, then this strait presents three great notches: first, the arch of the pubis, triangular, and placed beneath the symphisis; the second and third are placed between the

Fig. 109.*

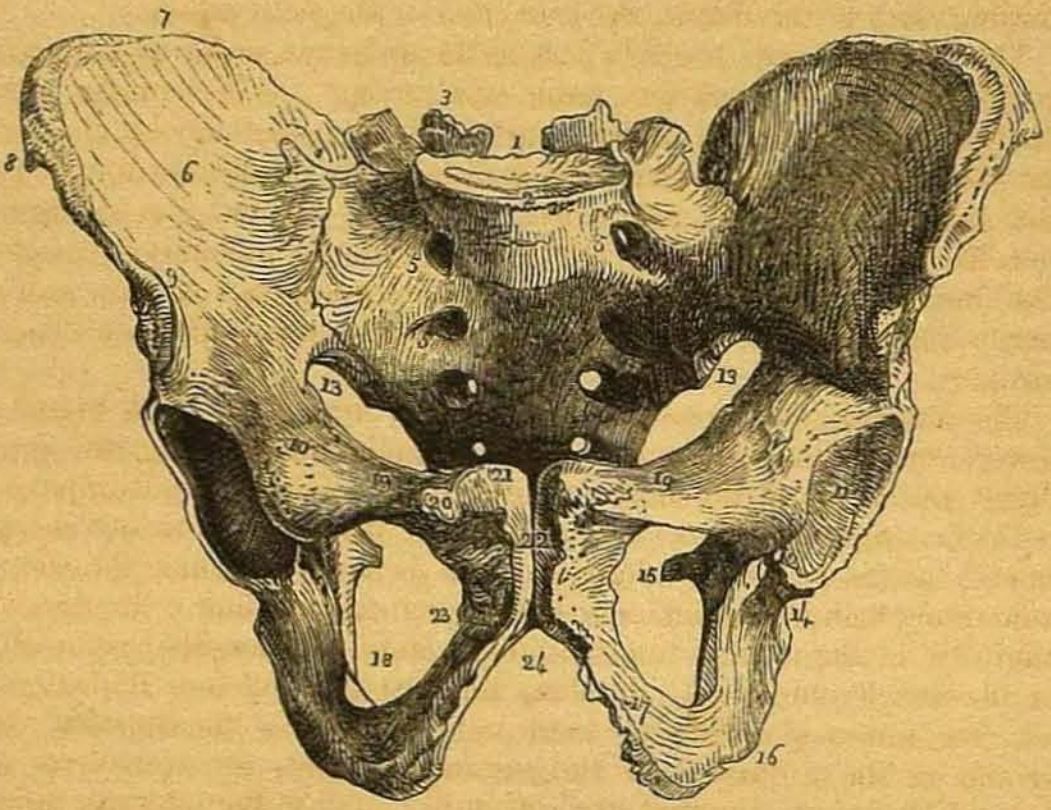

sacrum and os innominatum of each side, very large in the dried bones, but in the recent state they are divided by the sciatic ligaments each into two, the *greater* and the *lesser*. The *greater* or *superior sacro-sciatic notch*, or foramen, is bounded above and before by the ilium, behind by the sacrum, and below by the spine of the ischium and by the lesser or anterior sacro-sciatic ligament, which extends from this process to the sacrum. This notch transmits the pyriform muscle, the glutæal, sciatic, and pudic vessels and nerves. The *lesser* or inferior sacro-sciatic notch, or foramen, is a small triangular space, between the spine and tuber ischii, and completed above by the anterior, and below by the posterior or great sacro-sciatic ligament; it transmits the tendon of the internal obturator muscle in its passage to

* An anterior view of the pelvis. 1. The base of the sacrum. 2. The promontory of the sacrum. 3. The oblique or articular process. 4. The anterior surface of the sacrum. 5. The anterior sacral foramina. 6. The iliac fossa. 7. The crest of the ilium. 8. The anterior superior spinous process. 9. The anterior inferior spinous process. 10. The ileo-pectinæal eminence. 11. The acetabulum or cotyloid cavity. 12. The inferior notch in the acetabulum. 13. 13. The great sacro-sciatic notch. 14. The groove for the tendon of the obturator externus. 15. The spine of the ischium. 16. The tuberosity of the ischium. 17. The ramus of the ischium. 18. The thyroid or obturator foramen. 19. The horizontal ramus of the os pubis. 20. The tuberosity or spine of the os pubis. 21. The crest. 22. The symphisis. 23. The descending ramus of the os pubis. 24. The arch of the pubis.

the trochanteric fossa, also the pudic vessels and nerves in their returning course into the pelvis.

The *internal surface* of the pelvis is divided into two by the prominent line before mentioned, the linea ileo-pectinæa, which leads around from the symphisis and spines of the pubes to the promontory of the sacrum; below this line is the *true*, above, the *false* pelvis.

The *false pelvis* is properly part of the abdomen, and is too imperfect in the skeleton to merit the name of a cavity. It is bounded anteriorly by the abdominal muscles and tendons, posteriorly by the lumbar vertebræ and lumbar muscles, and laterally by the iliac alæ, which look upwards, inwards, and a little forwards, support the intestines, and direct the weight partly forwards against the abdominal parietes. The longest diameter of this region is the transverse, and its axis is nearly vertical, or a little oblique from above downwards and backwards.

The abdominal or *upper strait* or *inlet* of the true pelvis is bounded posteriorly by the promontory of the sacrum, anteriorly by the symphysis and crests of the pubes, and on either side, where it expands, by the ileo-pectinæal line. Its form is somewhat oval, or rather heart-shaped, as the pubic boundary in front is narrower than the sacral promontory behind, which encroaches upon the opening. It presents anteriorly in the median line the pubic, and on either side posteriorly the ilio-sacral symphisis. It offers for measurement four diameters: first, the antero-posterior or sacro-pubic, which is the shortest, on account of the projection of the sacrum; second, the transverse or iliac, which crosses the first at right angles, and is the longest; third and fourth, the oblique, leading from one ilio-sacral articulation to the opposite ilio-pubal eminence, or cotyloid wall.

The *true* pelvis, which is beneath this strait, is a sort of curved canal, longer than the false pelvis, and wider about the centre than at either end; with smooth walls, concave posteriorly from above downwards, concave anteriorly in the transverse direction, and on either side nearly plane. The sacrum and ossa coccygis form its posterior boundary, nearly five inches in length; the anterior or pubic wall is much less, from an inch and a half to two inches; on either side it becomes wide and deep, about four inches and a half, and presents anteriorly the thyroid or obturator foramina, closed by fibrous membrane, external to which there is a slight convexity corresponding to the bottom of the acetabulum, and more posteriorly the sacro-sciatic notches, which extend upwards to within an inch of the linea innominata, and downwards, in the skeleton, to the outlet or lower orifice of the pelvis, but in the recent state are separated therefrom by the great sacro-sciatic ligaments, which extend from the sacrum and coccyx to the tubera ischii, and form part of the lateral boundaries of the outlet. Each side slants a little downwards and inwards; the cavity is, therefore, smaller below than above. The true pelvis is placed in an oblique direction, its upper orifice looking forwards, and the inner surface of the pubes upwards, so as to support the abdominal

viscera: a line, passed horizontally from the upper border of the symphisis pubis backwards, will meet the middle, or rather the lower end of the sacrum. The lower orifice or outlet looks forwards and downwards; is smaller, but admits of change of form and size more than the upper. If the planes of the two openings of the true pelvis be produced anteriorly, they will unite about two inches in front of the symphisis, at an acute angle, the base of which will be the sacrum and coccyx. The outlet or perinæal strait is bounded anteriorly by the symphisis and rami of the pubes and ischia, laterally by the tuberosities of the ischia and by the sciatic notches, and posteriorly by the sacrum and coccyx, to the borders of which those notches extend. This plane presents three eminences and three notches: the eminences are the coccyx posteriorly and the tuber ischii on either side; the notches are the pubic arch before and the sciatic notches laterally and posteriorly. This opening, however, when viewed with the ligaments attached, presents a very different appearance; it is then much more contracted, and has a lozenge or diamond form; the coccyx and symphisis being the posterior and anterior angles, and the tubera the lateral, the margins formed posteriorly by the great sciatic ligaments, and anteriorly by the rami of the ischium and pubis. This strait also presents four diameters, the antero-posterior, the transverse, or that between one tuber ischii and the other, and the two oblique, leading from the centre of each great sciatic ligament to the opposite tuber ischii. The oblique and transverse are nearly equal, about four inches; the antero-posterior is nearly the same, but variable on account of the mobility of the coccyx. The axes of the two orifices of the true pelvis are not the same; that of the superior, if produced, would pass anteriorly through the abdominal muscles, between the pubis and umbilicus, and posteriorly it would rest against the lower end of the sacrum. The axis of the lower strait, if produced from below upwards, would impinge against the promontory of the sacrum; these lines, therefore, will decussate near the centre of the pelvis, and form an obtuse angle forwards. The axis of the cavity itself cannot be parallel to that of either of the openings. The *pelvic axis* is represented by a curved line passing through the centre of the upper plane, and descending through the cavity, parallel to the curve of the sacrum, and escaping through the centre of the lower plane. The axis of the inlet corresponds to a line passing through its centre, and directed from beneath the umbilicus downwards and backwards to the lower part of the sacrum; the axis of the outlet to a line directed from the promontory of the sacrum, downwards and forwards, through the centre of its plane.

The *female pelvis* differs from that of the male in several circumstances; it is wider and larger, but not so deep; the alæ of the ilium are more expanded, the prominence of the sacrum is less, the inlet and outlet are rounder and wider, the sacrum is broad and more concave, the pubic arch more round and open, the symphisis pubis is not so deep, the obturator holes are smaller and triangular, the sciatic

tuberosities are directed more outwards, and the acetabula are more distant from each other, and all the bones are more thin and delicate. The *male* pelvis is deeper, narrower, and the bones are more solid and strong. The dimensions of the male and female pelvis are given by Meckel as follows, tom. i. p. 473 :

	In the Male.		In the Female.	
	Inch.	*Lines.*	*Inch.*	*Lines.*
The transverse diameter of the great pelvis between the anterior superior spinous processes of the ilia,	7	8	8	6
Distance between the cristæ of the ilia,	8	3	9	4
Transverse diameter of the superior strait,	4	6	5	0
Oblique diameter of the superior strait,	4	5	4	5
Antero-posterior diameter of the superior strait,	4	0	4	4
Transverse diameter of the cavity,	4	0	4	8
Oblique diameter of the cavity,	5	0	5	4
Antero-posterior diameter of the cavity,	5	0	4	8
Transverse diameter of the lower strait or outlet,	3	0	4	5
Antero-posterior diameter of the lower strait or outlet,	3	3	4	4

The latter may be increased to five inches from the mobility of the coccyx.

In the fœtus the pelvis is very small and deep, and narrow transversely ; the true and false are nearly in the same perpendicular line ; the acetabula are nearer the middle line, and look more outwards ; they are not beneath the pelvis, as in the adult ; hence the thigh-bones in the infant cannot support or balance the weight of the trunk. The iliac alæ are flat, and the plane of the inlet is very oblique.

The ossa innominata are composed of two thin but compact laminæ, with an intervening diploe ; the latter is nearly wanting in the iliac fossæ, where the bones are transparent, as well as in the rough surfaces in the cotyloid cavities.

In the fœtus each os innominatum is *developed* from three points of ossification, one for the ilium, one for the ischium, and one for the pubis : these points are all in or near to, and soon unite in the acetabulum. About twelve years of age additional points are added, one for the crest, one for the tuber ischii, and sometimes one for the anterior inferior spine of the ilium, and sometimes one for the angle of the pubis ; also one of a Y form, in the acetabulum, between the three primitive pieces. These several ossific points are not completely united before twenty-three or twenty-four years of age. In some females, also, a plate of bone or epiphysis rises as a spine from the crest of the pubis, and occasionally grows so large and remains so moveable as to resemble the rudiments of a marsupial bone.

SECTION VIII.

THE BONES OF THE EXTREMITIES.

The *extremities*, or limbs, are four in number, two superior or thoracic, and two inferior or abdominal. The superior serve as instruments for prehension, tact, defence, and offence, and are connected to the thorax each by one articulation only. The inferior are longer and stronger, and serve as pillars for support, and as passive agents in locomotion; they are connected to the pelvis each by one articulation also. The upper and lower extremities, though intended for different purposes, yet present several analogies as to form and arrangement. We shall first consider the inferior.

The *inferior extremity* is divided into three parts, the thigh, leg, and foot; the latter is subdivided into the tarsus, metatarsus, and toes. The thigh has one bone, the femur; the leg three, the patella, tibia, and fibula; the tarsus seven, the astragalus, calcaneum, cuboid, scaphoid, and three cuneiform; the metatarsus five, and the toes fourteen: thirty bones in all. Some consider the os innominatum a part of the inferior extremity, as the shoulder is of the upper; the ilium and ischium being analogous to the scapula, and the pubis to the clavicle.

The *femur* is the longest and strongest bone in the system, and is longer in man, in proportion, than in any other animal; from the pelvis it is directed obliquely downwards and inwards: this obliquity is greater in the female than in the male; it consists of the body or shaft, and two extremities.

The *body* is slightly twisted, thick above, very broad below, contracted and nearly cylindrical in the centre, arched, convex, and smooth before, and concave behind, with a rough, projecting ridge down the centre, named the *linea aspera*, very strong and peculiarly hard along the middle third of the bone; is parallel to its axis, and strengthens the concave surface of the bone so as to resist its flexion under longitudinal compression; it is more rugged above than below, and divides at either end into two ridges; these pass superiorly one to each trochanter, that to the inner being the shorter, that to the outer broader, longer, more vertical, rough, and prominent: the inner line, however, may be traced forwards, around the lesser trochanter, to the anterior intertrochanteric line. Between these two branches is a flat, triangular surface, in the middle of which is a ridge to which some fibres of the quadratus femoris are attached; the inferior divisions lead, one to either condyle; that to the inner is much less prominent than that to the outer. These inferior divisions are longer than the superior, separate further, and enclose a flat, triangular space, the popliteal. The linea aspera is very prominent about the centre, and presents two lips and an interstice for the attachment of different muscles. The anterior surface of the femur is broader and flatter towards either end than in the centre; it is a little concave superiorly; the

sides are slightly flattened, and the external is somewhat narrower than the internal, particularly above. Above the middle of the linea

Fig. 110.*

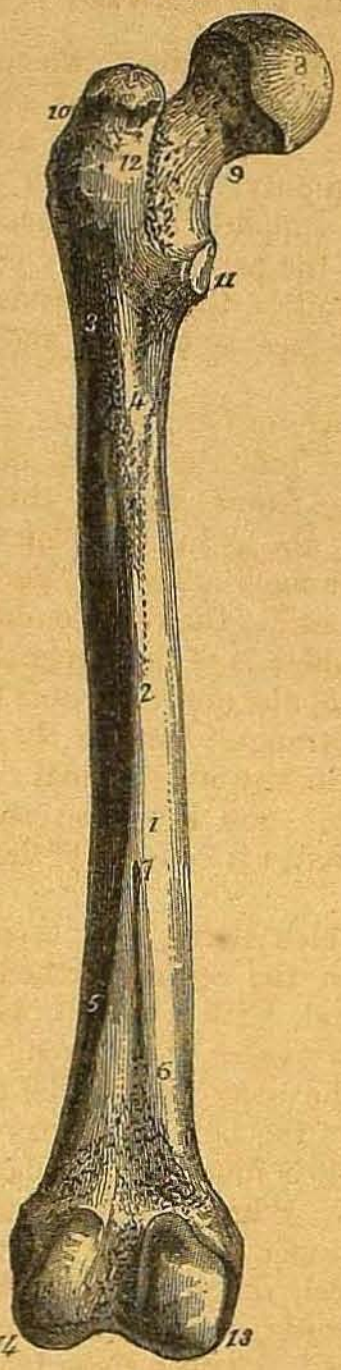

Fig. 111.†



* A posterior view of the left femur. 1. The body or shaft. 2. The linea aspera. 3. The superior external branch of the linea aspera, extending upwards to the great trochanter. 4. The superior internal branch passing towards the lesser trochanter. 5. The inferior external division of the linea aspera descending to the external condyle. 6. The inferior internal division, extending to the internal condyle. 7. One of the nutritious foramina. 8. The head. 9. The neck. 10. The great trochanter. 11. The lesser trochanter. 12. The posterior intertrochanteric line. 13. The internal condyle. 14. The external condyle. 15. The deep notch which separates the condyles posteriorly.

† An anterior view of the left femur. 1. The shaft or body. 2. The head. 3. The depression for the insertion of the ligamentum teres. 4. The neck. 5. The

aspera one or two holes may be seen to enter obliquely upwards; these transmit the nutritious or the medullary vessels of the bone; to the linea aspera, in the middle of the thigh, the vastus externus, the adductor tendons, and the vastus internus, are attached; to its superior external branch, which leads to the great trochanter, and is very long and rough, the adductor magnus, glutæus maximus, and vastus externus, are attached. The internal branch, short and not very distinct, leading to the lesser trochanter, gives attachment to the adductor brevis, pectinæus, vastus internus, and some of the fibres of the iliacus internus. To the lower and external branch of the linea aspera the vastus externus and short head of the biceps are attached, and to the lower and internal the vastus internus and adductor magnus adhere. These lines continue as low as the condyles; the internal is smooth, and nearly obliterated near its middle for the passage of the crural artery.

The *upper* or *pelvic extremity* of the femur presents three eminences, the head for articulation with the cotyloid cavity, and the trochanters for the insertion of muscles. The *head* is of a globular figure, and forms a considerable segment of a sphere; it is directed upwards, inwards, and a little forwards: a little below its centre there is a rough, oval depression for the insertion of the round or articular ligament. With the exception of this depression the head is covered throughout with cartilage; it is supported by a strong, elongated process, of a pyramidal form,—the *neck*, which forms an angle, more or less obtuse, with the shaft of the bone. The direction of this process is upwards, inwards, and a little forwards; it is flattened before, smooth, concave, and longer behind; it is stronger, and can, therefore, better resist force or pressure in the direction of its vertical diameter than in its antero-posterior; is thicker at the shaft than at the head; its lower edge is longer and firmer than the upper, which is thick and short. A rough, irregular line separates the head from the neck, beyond which the articular cartilage of the former does not extend; its upper and its anterior surfaces are each perforated by numerous foramina for vessels. At its juncture to the shaft two rough lines extend inwards and downwards from the great to the lesser trochanter, one on the fore, the other on the back part of the bone; into these the capsular ligament is inserted. The neck is short in the child, long and oblique in the adult male; it is shorter and more horizontal in the female, forming nearly a right angle with the shaft: in old age, also, it often becomes shortened and depressed by interstitial absorption, so that the head sometimes sinks below the level of the great trochanter, and becomes nearly contiguous to the shaft.

The *great trochanter* is continuous with the external side of the

great trochanter. 6. The digital fossa of the great trochanter. 7. The lesser trochanter. 8. The anterior intertrochanteric line or ridge. 9. The external condyle. 10. The internal condyle. 11. The tuberosity for the attachment of the external lateral ligaments of the knee-joint. 12. The groove which receives the tendon of the poplitæus muscle. 13. The tuberosity for the attachment of the internal lateral ligament.

shaft, and nearly in a line with its axis, and on a little lower level than the head; it is thick, rough, and square; externally it is broad and convex, and prominent beneath the skin: the tendon of the glutæus maximus moves over this surface and an intervening bursa; a prominent ridge bounds it below, to which some fibres of the vastus externus are attached. Internally it presents a pit, or digital cavity, which receives the tendons of the external rotators of the limb, namely, the pyriform, gemelli, and obturators. The summit of the trochanter is thick and rough; is curved a little inwards, so as to overhang the digital fossa. Into it, and into an oblique ridge on its outer surface, the glutæus medius is inserted; the anterior edge is broad, and presents superiorly a depression for the attachment of the glutæus minimus. Into the posterior, which is round and thick, the quadratus femoris is inserted.

The *lesser trochanter* is a conical tubercle at the posterior and inner side of the shaft, considerably below the level of the great trochanter, and below the base of the neck; it looks backwards and inwards; the tendons of the psoas and iliac muscles are inserted into it behind its apex; a small bursa is sometimes connected to it anteriorly, and another posteriorly.

The inferior or *tibial end* of the femur is very large and broad, flattened before and behind, and divided into two eminences or *condyles*, which are separated posteriorly by a deep notch, and continuous anteriorly with each other and with the shaft, through the trochlea, for the patella. The *condyles* articulate with the tibia. The *external* is larger, and projects more forward than the internal; its articulating surface is also broader, and ascends higher. Externally it is rough, and presents a tuberosity which gives attachment to the external lateral ligament of the knee-joint; this is less prominent than the internal tubercle. Beneath it is a groove which receives the tendon of the poplitæus muscle in the flexed position of the joint. Internally this condyle presents a rough surface, towards the posterior part of which the anterior crucial ligament is inserted; it is very convex behind, flat before, and broad below. Above and behind it arise the outer head of the gastrocnemius and plantaris muscles. The *internal condyle* is narrower, less prominent before, but prolonged more behind; it is also longer than the external, and therefore descends lower when the femur is vertical, but both are nearly on a level when the bone is in its ordinary oblique direction. On its inner side is the tubercle for the attachment of the internal lateral ligament of the knee and for the adductor tendon. To its outer side, which is rough, the posterior crucial ligament adheres. Both condyles are more convex behind than before; they are separated posteriorly by a deep, uneven notch, which lodges the crucial ligaments, and is deprived of articular cartilage. Anteriorly they are continued into each other, and unite in a *trochlea* on which the patella moves, and which is convex from above downwards, and concave from side to side, higher externally than internally, and chiefly formed on the external condyle. The femur is arti-

culated superiorly with the ilium, inferiorly with the tibia, and anteriorly with the patella. Like all long bones, it is composed of compact tissue in the centre, and cancellated at the extremities; the compact has a fibrous appearance. The whole shaft is traversed by a distinct medullary canal, which is crossed by numerous bony laminæ. The femur is *developed* by five points of ossification, one for the shaft, one for the tibial end, one for the head, and one in each trochanter. Ossification commences in the shaft so early as the beginning of the second month, and the ossific point in the lower end is constantly present (according to Cruveilhier) during the last fifteen days of fœtal life: that in the head of the bone commences during the first year after birth; the neck extends from the shaft, and is not a distinct portion. Ossification commences in the great trochanter about the third year, and in the lesser about the twelfth. The lower extremity of the femur is the only epiphysis in which ossification commences before birth, and it is the longest to continue separate, not being united to the shaft until after the twentieth year.

The bones of the *leg* are the patella, tibia, and fibula.

The *patella* or *rotula*, or knee-cap, is a small bone in front of the knee-joint, triangular or heart-shaped, the base above, the apex below; its anterior surface is convex and covered by skin, a bursa, and some tendinous fibres; it is marked by several longitudinal lines, and presents a very fibrous appearance. The posterior surface is covered with cartilage, and divided by a prominent vertical line, which descends a little inwards, into two lateral portions. Of these the external is larger and deeper than the internal. Beneath these is a small, triangular, depressed surface, into which the ligament of this bone is inserted. The upper edge is round, and cut off obliquely backwards and downwards; to it the extensor tendons are attached. The patella is of a cellular structure, covered by a compact lamina, which is very dense, and traversed by longitudinal striæ; it is developed from a single point of ossification, and remains for a long time cartilaginous; it commences between the second and third year, and is completed about the fourteenth. It is articulated with the condyles of the femur, and connected to the tibia by a powerful ligament; it protects the forepart of the knee, and serves as a medium of connexion between the extensor tendon and the leg. When the limb is extended it is moveable, and may rise above the trochlea; when flexed, it is fixed and prominent.

Fig. 112.* *Fig.* 113.†

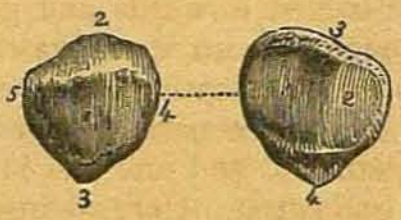

The *tibia*, next to the femur, is the longest bone in the skeleton; it

* The anterior surface of the left patella. 1. The anterior convex surface. 2. The base. 3. The apex. 4. Its external border. 5. Its internal border.

† The posterior surface of the same bone. 1. The large concave facette which articulates with the external condyle of the femur. 2. The smaller facette, which joins the internal condyle of the femur. 3. The base. 4. The apex.

occupies the anterior and inner part of the leg; its direction is vertical, whereas that of the femur is obliquely downwards and inwards; the tibiæ of opposite sides are parallel. Its upper extremity is thick, and expanded from side to side; the circumference somewhat circular or oval, convex on the front and sides, but slightly grooved behind. On either side is a *protuberance;* that on the internal is the more prominent for the insertion of the internal lateral ligament and for the tendon of the semimembranosus muscle, one portion of which is attached to a groove on its posterior aspect. A little behind the external tuberosity is a small rounded surface, looking downwards and a little backwards and outwards; it is covered with cartilage for articulation with the head of the fibula. On the anterior part of the head is a convex, triangular surface, directed forwards and downwards, pierced with many vascular holes, and terminating in a tubercle, to the upper part of which a bursa adheres, and into the lower the ligamentum patellæ is inserted.

Fig. 114.* *Fig.* 115.*

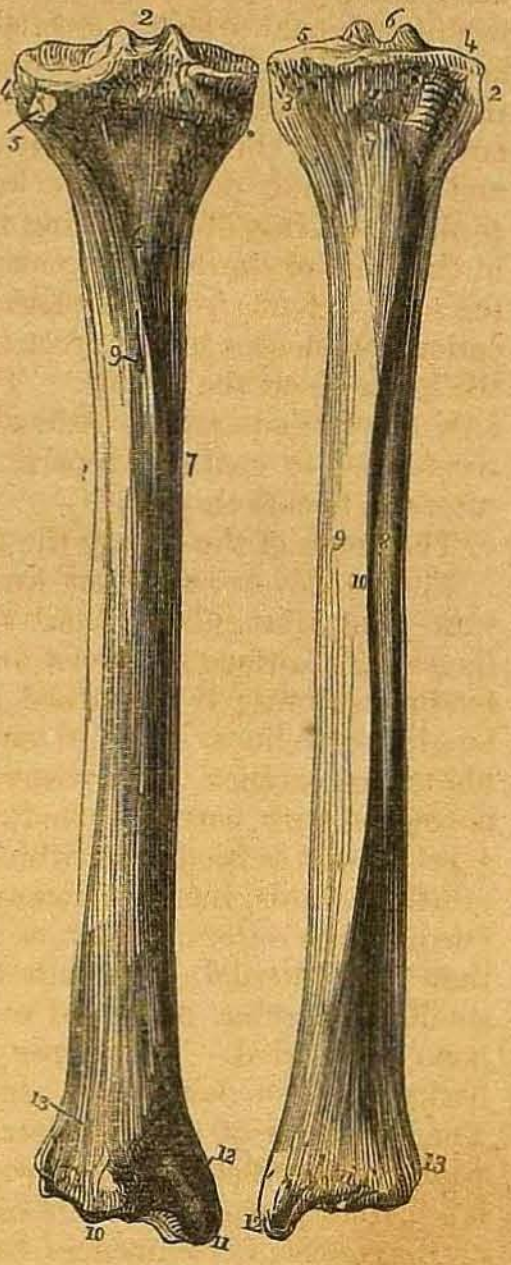

The upper or femoral surface of the tibia presents two concave or articulating surfaces or *condyles*, or rather glenoid cavities, covered with cartilage for articulating with the femur. The *internal* is oval, and the deeper of the two; it is also

* The posterior surface of the left tibia. 1. The head. 2. The spine. 3. The internal tuberosity. 4. The external tuberosity. 5. The surface for articulation with the head of the fibula. 6. A rough ridge to which the poplitæus muscle is attached. 7. The internal border of the shaft. 8. The external border. 9. The oblique orifice of the vascular canal. 10. The lower extremity of the tibia. 11. The internal malleolus. 12. The groove for the tendons of the tibialis posticus and flexor digitorum longus. 13. A rough surface, which receives the lower end of the fibula.

† An anterior view of the left tibia. 1. The head of the tibia. 2. The external tuberosity. 3. The internal tuberosity. 4. The external superior articular surface. 5. The internal superior articular surface. 6. The spine. 7. The tubercle. 8. The external surface of the shaft of the bone. 9. Its internal or subcutaneous surface. 10. The anterior edge or crest of the tibia. 11. The lower extremity of the tibia. 12. The internal malleolus. 13. The surface which articulates with the lower extremity of the fibula.

larger from before backwards. The *external* is nearly circular, very superficial, and inclined obliquely downwards and outwards. These are separated by a *spine*, which is of a pyramidal form, inclines upwards and inwards, and is surmounted by two tubercles; it is nearer the back than the forepart of the bone: a large, flat, depressed surface lies anterior to it, and a smaller depression behind it: the semilunar cartilages and the crucial ligaments are inserted into these.

The *body* or shaft of the tibia is triangular; its size diminishes from the head for about two-thirds down, it then increases somewhat towards its lower end; its inner side is convex above, a little concave below, directed obliquely forwards, and covered superiorly by the tendinous expansions of the sartorius, gracilis, semitendinosus and membranosus; the remainder of it is subcutaneous. The external side appears a little twisted; it is concave above to support the tibialis anticus muscle, convex below, to support the tendon of that muscle, as also those of the extensors. The posterior surface, which is also broader above than below, is slightly convex, and presents superiorly a prominent line passing obliquely downwards and inwards for the insertion of the poplitæus, and for the origin of the solæus and the deep flexors. Near this line is the opening of the large canal that leads the vessels to the medullary membrane, slanting obliquely downwards and forwards. The tibia presents three edges; one is anterior, and commences from the tuberosity; it is very prominent about the middle, but less so above, and rounded below: this line is subcutaneous; it is twisted like the tibia itself, and is commonly called the crest or the shin. The inner edge is thick and round, and more distinct below than above; the outer edge is thin, and gives attachment to the interosseous ligament; it is less distinct and bifurcated below.

The lower or *tarsal end* of the tibia is somewhat square, presents an anterior convex edge, covered by the extensor tendons; a posterior nearly smooth edge, traversed by a groove for the tendon of the flexor pollicis longus; externally is a concave, triangular surface, rough above for ligaments, more smooth and cartilaginous below to receive the lower end of the fibula; internally a thick, flattened, perpendicular process, the *internal malleolus* or ankle, convex and subcutaneous, bent a little inwards, and prominent beneath the skin; it lies anterior to the superior internal tuberosity or condyle, on account of the twisting of the bone. The outer side of this process is smooth and cartilaginous, and joined at right angles to the cavity at the lower end of the bone; it is articulated to the side of the astragalus; its anterior edge is convex, and gives attachment to ligaments; its posterior edge is grooved superficially for the tendons of the tibialis posticus and flexor communis: this groove is sometimes double. The extremity of this process is broad, and descends lower before than behind; it gives origin to the internal lateral ligament of the ankle. The lower surface of the tibia is quadrilateral, concave from before backwards, and somewhat convex from side to side, being traversed from before backwards by a very superficial ridge or prominence. This surface is

broader externally; it is bounded internally by the internal malleolus, and externally by the fibula. The tibia is articulated to the femur, the fibula, and astragalus. Ossification commences in three points, one for the shaft, and one for each extremity; the tubercle at the upper end of the crest and the malleolus are sometimes found as epiphyses.

Fig. 116.* *Fig.* 117.†

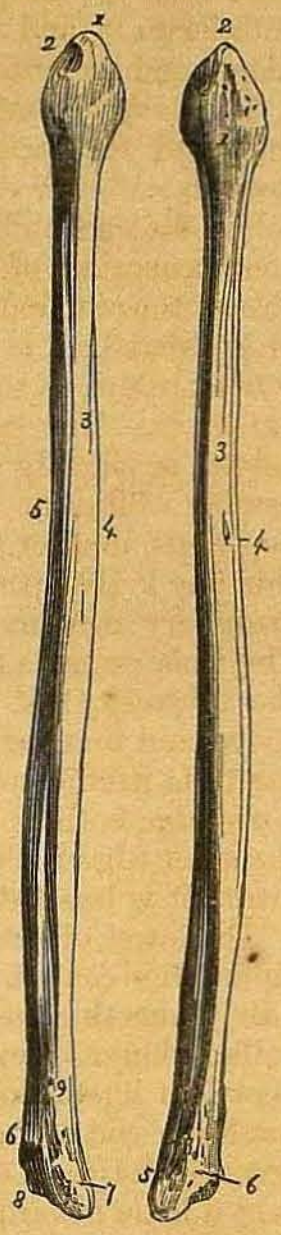

The *fibula* is very slender, and nearly as long as the tibia; it is placed at the outer side of the leg, nearly vertical, its lower end inclined a little forwards; below it is directly to the outer side of the tibia, but above it is also somewhat posterior to it. The superior or *femoral end* is small and circular, and presents a slight cavity forwards, upwards, and inwards, to articulate with the tuberosity on the external condyle of the tibia. Behind this is a slight pyramidal projection; its whole circumference is rough for the insertion of ligaments which attach it to the tibia, also for the external lateral ligament of the knee-joint and for the tendon of the biceps; below this the bone is round and slender, like a *neck;* the *body* then becomes triangular, is a little curved backwards and inwards above, but is twisted forwards below. This is divided into two portions by the internal edge, into which the interosseous ligament is inserted; the anterior portion gives attachment to the extensors, and the posterior, which is larger, is grooved for the tibialis posticus. Its external surface is covered by the peronei muscles; the posterior surface gives attachment to the solæus above and to the flexor pollicis below. In this surface we perceive the orifice of the vascular canal leading downwards; the internal edge, which is turned a little forwards, gives attachment to muscles above and to the interosseous ligament below; the external edge is turned backwards, and gives attachment to the solæus, flexor pollicis, and peronei muscles; and the anterior sharp edge to the extensor digitorum and the peronei. Inferiorly this edge turns for-

* An anterior view of the left fibula. 1. The femoral end or head of the fibula. 2. The surface which articulates with the external tuberosity of the tibia. 3. The shaft of the fibula. 4. Its external border. 5. The internal border. 6. The lower extremity of the fibula, a rough surface which is received into the triangular concavity at the lower end of the tibia. 7. The external malleolus. 8. The surface which articulates with the astragalus. 9. A triangular, concave surface, which is subcutaneous.

† The posterior surface of the left fibula. 1. The head. 2. The pyramidal spine which surmounts the head. 3. The posterior surface of the shaft. 4. The orifice of the principal vascular canal. 5. The external malleolus. 6. The groove for the peroneal tendons.

wards and bifurcates, enclosing a triangular surface, which is subcutaneous. The *lower* or *tarsal end* is larger than the head; it is elongated into a long, oval process, the *external malleolus* or *ankle*. This is larger, longer, and more prominent than the inner ankle, descends lower, and is on a plane posterior to it; it is convex and subcutaneous externally; internally it is smooth and triangular, a little concave from behind forwards, and convex in the perpendicular direction; it articulates with the astragalus. Above this is a triangular, rough surface to articulate with the tibia. Anteriorly this process is rough, but thin, for the origin of ligaments; its posterior edge is broader, and grooved for the peronæal tendons, internal to which is a depression for the origin of the posterior external lateral ligament of the ankle-joint. From the point of this process the external lateral ligament arises; the fibula is articulated at both ends to the tibia and below to the astragalus. Ossification commences in three points.

Fig. 118.*

The *foot* is composed of twenty-six bones, which are arranged in three parts, the tarsus, metatarsus, and toes. The bones of the *tarsus* are seven: astragalus, calcaneum, navicular, cuboid, and three cuneiform, internal, middle, and external. These seven bones are arranged in two rows. The first is composed of the astragalus and os calcis, which are not placed transversely, but one above the other obliquely. The astragalus only enters the ankle-joint, from which it is directed forwards, inwards, and a little downwards. The os calcis forms the projection of the heel, and rests upon the ground; its direction is forwards, outwards, and a little upwards. The second row consists of five bones; the cuboid bone externally forms it alone, but on the inner side it presents

* The superior or dorsal surface of the left foot. 1. The calcaneum or os calcis. 2. The superior articular surface of the astragalus. 3. The anterior extremity or head of the astragalus. 4. Its external articular surface, which meets the fibula. 5. Its internal facette, which articulates with the internal malleolus. 6. The navicular or scaphoid bone. 7. The cuboid bone. 8. The internal cuneiform bone. 9. The middle cuneiform bone. 10. The external cuneiform bone. 11. The first or internal metatarsal bone. 12, 13, 14, 15. The second, third, fourth, and fifth metatarsal bones. 16. The first phalanx of the great toe. 17. 17. The first phalanges of the second, third, fourth, and fifth toes. 18. 18. The second or middle phalanges of the external four toes. 19, 20, 20. The last or ungual phalanges of the toes.

two short transverse rows, the navicular forming the posterior and the three cuneiform bones the anterior.

Fig. 119. *

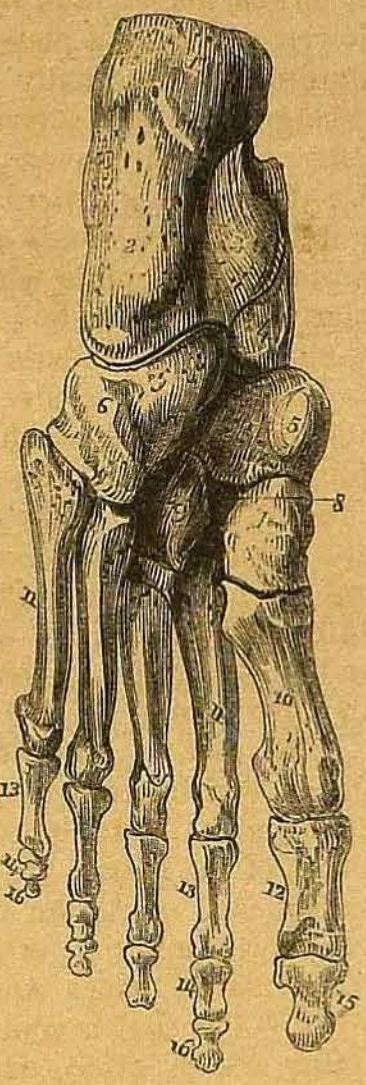

The *astragalus* is next to the calcaneum in point of size; it is of an irregular twisted shape, somewhat cubical, larger above and to the outside than internally or posteriorly; is situated at the upper and middle part of the tarsus, where it is wedged between the two malleoli. Its *superior surface* presents in its two posterior thirds a large, pulley-like, articular surface, which is convex from behind forwards, and concave transversely, the reverse to the form of the end of the tibia: it is inclined a little backwards, is broader before than behind, and more prominent externally than internally. Anterior to this surface is a rough depression, the *neck* of the bone, for the insertion of ligaments. *Inferiorly* it presents two articular surfaces for the os calcis: one is posterior and external, broad and concave; the other is anterior, internal, and convex. These surfaces are separated by a deep groove, which is narrow behind, broad before, and directed forwards and outwards. Strong interosseous ligaments pass from this groove to the os calcis. The *posterior surface* of the astragalus is narrow, and slightly grooved in an oblique direction downwards and inwards for the tendon of the flexor pollicis; it also presents externally a pointed eminence, to which the external posterior lateral ligament of the ankle-joint is attached. The *anterior extremity* is a smooth, round head, supported by a neck, perforated by small holes for vessels; the head, directed forwards, inwards, and downwards, is articulated with the navicular bone, and rests upon the calceo-scaphoid ligament. The *external side* presents a triangular, smooth surface, concave from above downwards, and a little convex from before backwards: it is

* The inferior or plantar surface of the left foot. 1. The posterior surface of the calcaneum or os calcis. 2. Its inferior surface. 3. Its internal surface. 4. A portion of the head of the astragalus. 5. The inferior surface of the navicular or scaphoid bone. 6. The inferior surface of the cuboid bone. 7. The internal cuneiform bone. 8. The middle cuneiform bone. 9. The external cuneiform bone. 10. The first or internal metatarsal bone. 11. The second, third, fourth, and fifth metatarsal bones. 12. The first phalanx of the great toe. 13. The second phalanges of the external four toes. 14. The second or middle phalanges. 15. The last or ungual phalanx of the great toe. 16. 16. The last phalanx of the second, third, fourth, and fifth toes.

articulated with the fibula. The *inner side* is rough for ligaments, except a cartilaginous surface near the upper part, which is smaller than

Fig. 120.*

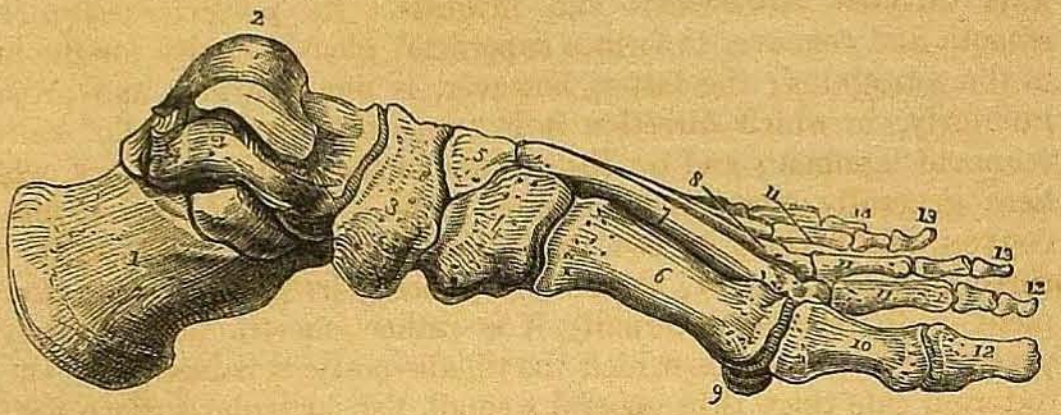

that on the outer side, and broader before than behind: this is articulated with the internal malleolus. Both these malleolar surfaces are continuous with the trochlea on its upper surface. It is articulated with the tibia and fibula, the os calcis, and the scaphoid.

The *calcaneum*, or *os calcis*, is the largest bone in the tarsus, at the lower and posterior part of which it is placed; it is elongated posteriorly into a process called the heel. Its *upper surface* presents two articulating surfaces to support the astragalus. The posterior is convex, broad, and directed forwards and outwards; the anterior is internal, narrow, and concave. These are separated by a deep, rough, transverse sulcus, into which strong ligaments are inserted; internal to this the bone is uneven, and projects into a sort of process into which the internal lateral ligament of the ankle-joint is inserted. The *inferior surface* is smaller than the superior, and is nearly flat; it presents two small tubercles for the attachment of muscles and ligaments. The *posterior extremity* is slightly convex, smooth above, and covered by a bursa, and rough below for the insertion of the tendo Achillis. The *anterior extremity* is smaller, and presents an articular surface for the cuboid bone, which is concave from above downwards, and convex from side to side. *Externally* it is rather flat, being marked with two shallow grooves for the peroneal tendons, separated by a spine; into this surface the external lateral ligament of the ankle-joint is inserted. *Internally* it is broad, and hollowed out into an arch through which the flexor tendons and that of the tibialis posticus, also the plantar vessels and nerves, pass. The tendon of the flexor pollicis runs in a distinct groove. At the anterior part of this surface is a prominence which supports the anterior articulation between the

* A lateral view of the left foot, to shew its arched form. 1. The calcaneum. 2. The astragalus. 3. The navicular or scaphoid bone. 4. The internal cuneiform bone. 5. The middle cuneiform bone. 6. The first or internal metatarsal bone. 7. The second metatarsal bone. 8. A portion of the upper surface of the three other metatarsal bones. 9. The sesamoid bones of the great toe. 10. The first phalanx of the great toe. 11. The first phalanges of the other toes. 12. The last or ungual phalanx of the great toe. 13. The second and third phalanges of the four other toes.

astragalus and os calcis; beneath it run the flexor tendons. The os calcis is attached above to the astragalus, and before to the cuboid.

The *navicular* or *scaphoid bone* is situated about the middle of the tarsus, and at its upper and internal part; of an oval form, its long axis directed downwards and inwards. Its *posterior surface* is smooth and concave, to form a superficial glenoid cavity for the head of the astragalus; the latter, however, is much larger, and projects inferiorly, in which direction it is supported by the strong, calceo-scaphoid ligament, and by the tendon of the tibialis posticus, which here generally contains a sesamoid bone. The *anterior surface* is convex, and divided by two vertical ridges into three surfaces for the three cuneiform bones; the circumference is irregular for the attachment of ligaments; internally it is rather smooth, but inferiorly it presents a tubercle into which the tibialis posticus is inserted. On its external side there is in general a small, flat, articular surface for the cuboid bone. The scaphoid is articulated to five bones, viz., the astragalus, the three cuneiform, and the cuboid; it is also connected to the calcaneum by a strong ligament.

The *cuboid bone* is situated at the outer and anterior part of the tarsus, external to the navicular and anterior to the calcaneum; although of a cubical form, it is thicker and longer internally than externally. Its *upper surface* is flat and rough, for the attachment of ligaments and muscles. The *lower surface* is irregular, rough, and tubercular behind, for the calceo-cuboid ligament, and grooved before for the tendon of the peroneus longus. Its *posterior surface* is smooth, concave transversely, but convex from above downwards. This slightly pulley-like surface is articulated with the calcaneum. *Anteriorly* it presents two articular surfaces. The internal is square, and supports the fourth metatarsal bone; the external is triangular, and supports the fifth. The *external side* is narrow, smaller than the others, and marked by the commencement of the peroneal groove. The *internal* is rough posteriorly, but presents anteriorly two articulating surfaces, the posterior for the scaphoid, and the anterior for the external cuneiform bone. The cuboid is articulated with the calcaneum, the scaphoid, the external cuneiform, and the two external metatarsal bones.

The *cuneiform bones.* These three wedge-shaped bones are situated at the anterior part of the tarsus, between the scaphoid and the three internal metatarsal bones. The first, or the *internal*, is the largest of the three, its base is below, and its long axis is from above downwards. It is articulated posteriorly to the scaphoid bone, anteriorly to the first, and externally to the second metatarsal bone, and to the middle cuneiform; inferiorly it presents a tubercle for the insertion of the tibialis anticus, and for a portion of the tendon of the tibialis posticus. The *middle cuneiform* is the smallest, and is wedged in between the two others; its broad surface is towards the dorsum, its narrow towards the sole of the foot. It is also articulated behind to the scaphoid, and before to the second metatarsal bone. The third, or *external cuneiform* bone, is situated between the last and the cuboid bone. It is articulated

anteriorly with the third metatarsal bone; posteriorly with the scaphoid, internally with the middle cuneiform and with the second metatarsal bone, and externally with the cuboid and with the fourth metatarsal bone. All the bones of the tarsus are composed of a soft, spongy, vascular tissue, covered by a compact but thin lamina; they are each developed from one point of ossification, except the calcaneum and the astragalus, which commence each in two points.

The *metatarsus* is the second division of the foot, and consists of five long bones, parallel, and separated by interosseous spaces. Its posterior border is connected to the tarsus by an irregular, transverse line of articulation; convex forwards, concave backwards. The base of the second bone, or that next the great toe, extends to a plane posterior to that on either side of it, and interrupts the regularity of this transverse line.

The *metatarsal bones* are five in number. The *first*, or internal, is the shortest and thickest, convex above, concave and sharp below; its posterior end is oval, concave, and rests on the internal cuneiform bone; the anterior end, round and smooth, supports the first or great toe. This extremity is grooved below, and lodges the sesamoid bones: the peroneus longus is also inserted into it. The *second* is the longest of the metatarsal bones; its tarsal end is wedged in between the three cuneiform bones, and is articulated to each of them. The outer side of its base is also joined to the third metatarsal bone; its anterior extremity or head is round, and supports the second toe; it is marked internally and externally by the depressions for the lateral ligaments: a groove separates the head from the body of the bone. The *third metatarsal bone* is a little shorter than the second, but of the same form; its base rests on the third cuneiform bone. The *fourth metatarsal bone* is a little shorter; it rests on the cuboid bone, and the inner side of its base also rests against the third cuneiform bone. The *fifth* is the shortest, except the first; it rests on the cuboid bone, and presents externally a styloid process, directed backwards and outwards, for the insertion of the peroneus brevis. The heads of all the metatarsal bones are round, like those of the metacarpal; the bases flat, and somewhat square, to articulate with the tarsus; the sides of their bases are also flat, to join one another. All these bones possess a similar structure, and resemble the class of long bones.

The *toes* are five in number. The first, or the great toe, has only two phalanges; all the others have three; there are, therefore, fourteen phalanges in all. The *first phalanges* are longest; they are convex above, concave below; their posterior end is larger, and presents, as in the hand, a round concavity for the head of the metatarsal bone; the anterior end is convex from above downwards, and concave from side to side, so as to form a ginglymoid joint with the second phalanx. The *second phalanges* are very short: the great toe has none. The posterior end of each presents the trochlear surface, is a little concave from above downwards and convex transversely, being divided by a vertical ridge: the anterior extremity is smaller than that of the first phalanx. The *third phalanges* are all very small, except

that of the great toe; they are of a pyramidal form, and support the nails, their posterior extremity being very large, and similar to that of the middle phalanges; their anterior end is tubercular, and attached to the cellulo-vascular texture at the extremity of each. At the base of the first phalanx of the great toe there are in general two *sesamoid bones*, into which the small muscles of this toe are inserted; frequently, also, there is another at the base of the second phalanx; sometimes one is found at the first joint of the second toe, and another at that of the fifth.

SECTION IX.

THE SUPERIOR EXTREMITIES.

EACH *superior* or *thoracic extremity* consists of the shoulder, arm, forearm, wrist, and hand; the whole limb comprises thirty-two bones, the sesamoid not included. The shoulder is composed of the clavicle and scapula; the arm, of the humerus; the forearm, of the radius and ulna; the wrist, of the eight small carpal bones; the hand, of the five metacarpal and fourteen phalangeal bones.

The *clavicle* is the long bone extending from the summit of the sternum obliquely across the first rib upwards, backwards, and outwards, to the acromion process of the scapula; is curved somewhat like an italic *ſ*, particularly in the male; in the female it is straighter and longer, in proportion, than in the male; it presents two extremities and a body or shaft. The *sternal end* is a thick, triangular, articulating surface, inclined forwards and downwards, concave from before backwards, large above and before, small and pointed below and behind; the circumference is rough for the attachment of ligaments. The *body* is nearly cylindrical towards the sternal, but flat and expanded towards the acromial end; smooth above, and mostly subcutaneous. Inferiorly it is rough, and presents, about an inch from the sternal end, a ridge or process for the

Fig. 121.*



Fig. 122.†

* The superior surface of the left clavicle. 1. The internal or sternal extremity. 2. The surface which articulates with the upper piece of the sternum. 3. The body. 4. The acromial extremity. 5. The anterior border. 6. The posterior border.

† The inferior surface of the left clavicle. 1. The sternal end. 2. The surface which articulates with the upper piece of the sternum. 3. The body. 4. The ridge for the rhomboid or costo-clavicular ligament. 5. The acromial or sca-

rhomboid or costo-clavicular ligament; internal to which there is sometimes a small, articulating surface, which rests on the cartilage of the first rib. External to this is a groove for the subclavian muscle. In this also is a foramen for the nutritious vessels, and near the scapular end is a tubercle and rough ridge leading outwards and forwards; to these the coraco-clavicular ligaments are attached. Its anterior edge is convex in the inner half, and gives attachment to the great pectoral muscle. The outer half is concave; to it the deltoid is attached. The posterior edge is smooth, and concave in the inner half towards the great vessels, but rough and convex externally for the attachment of the trapezius muscle. The *acromial end* of the clavicle passes over the coracoid process upwards and backwards; is flat and broad, rough above and below, and perforated by vessels; it presents at its termination a small, articulating surface for the acromion scapulæ. This surface is oval from before backwards, and cut obliquely from above and from without downwards and inwards; its aspect is outwards, forwards, and downwards, and is on a plane rather above the articulating surface of the acromion scapulæ: its circumference is rough for the attachment of ligaments. The clavicle serves to support the scapula, and to prevent it from falling too much forwards or inwards; it thereby allows it a greater freedom of motion; it also serves as a fixed point for certain muscles, and it protects the vessels and nerves of the upper extremity. It is articulated to the scapula and sternum, and sometimes to the cartilage of the first rib: it is very perfect in the fœtus, and is developed from a single point of ossification: it has no perfect epiphysis, although in the young subject there is an osseous crust at each extremity, which is at first separable from the rest of the bone.

The *scapula* is situated at the upper, lateral, and posterior part of the chest, and extends from the second to the seventh rib. It is irregularly flat and triangular; it presents an internal and an external surface, three edges, and three angles. The internal or anterior surface, or *subscapular fossa*, looks towards the ribs, is slightly concave, and divided by three or four prominent lines into several broad grooves, which are filled by the fasciculi of the subscapular muscle, the aponeurosis of which is attached to those lines. The latter are not parallel to the ribs, but run obliquely upwards and forwards, while the ribs incline downwards and forwards. Above and below these is a smooth, flat surface, to which the serratus magnus is attached. The external or posterior surface, or dorsum, is convex, and divided transversely into two unequal parts by a ridge or *spine*, which commences about the upper third of the posterior border, from a smooth, polished, flat, triangular surface, over which the trapezius muscle glides: the spine then proceeds forwards, and becomes more elevated, flattened above and below, and bounded by a long, irregular, undulated margin, which is rough

pular end. 6. A ridge for the attachment of the coraco-clavicular ligaments. 7. An articulating surface for the acromion scapulæ. 8. The anterior border. 9. The posterior border.

above for the attachment of the trapezius, and below for that of the deltoid muscle. A vascular hole is observed on its upper and under surface. This spine is a little contracted anteriorly and externally, and terminates in an eminence named the *acromion process.* This surmounts the shoulder-joint, and is about an inch above it; it is flattened in a direction contrary to that of the spine. Its external surface

Fig. 123.*

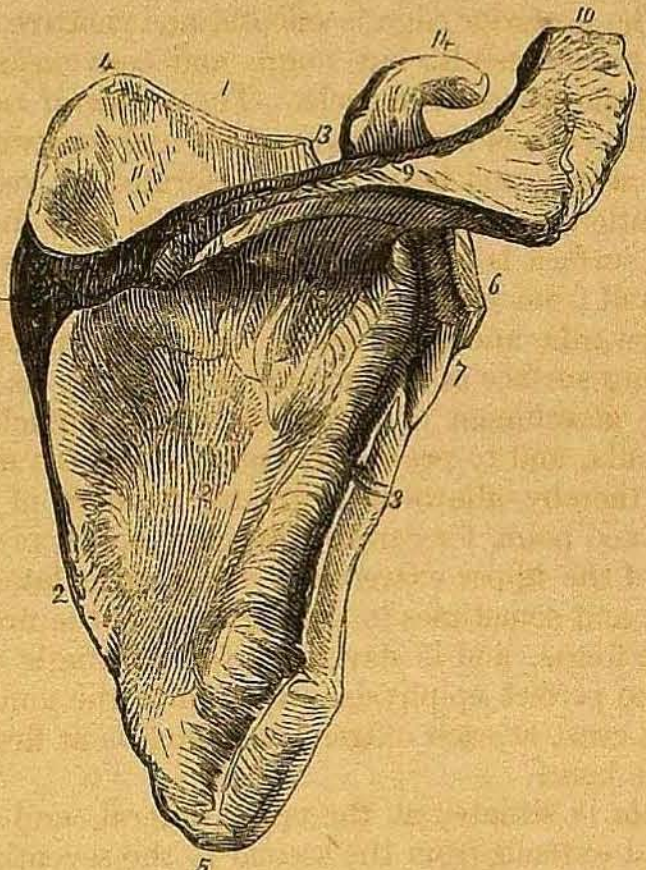

looks a little upwards and backwards, is convex, rather rough, and covered by the integuments. Its inferior or internal surface is smooth and concave; its upper edge is directed backwards, gives attachment to the trapezius, and presents near its termination a small and nearly horizontal, oval, articulating surface for the clavicle. The aspect of this surface is a little oblique upwards, inwards, and backwards; the lower edge gives attachment to the deltoid; its apex is rounded for the insertion of the triangular, or coraco-acromial ligament. Above the spine is the *supra-spinata fossa*, which is wider behind than before; this is filled by the supra-spinous muscle. The *fossa infra-*

* A posterior view of the right scapula. 1. The superior border. 2. The posterior border or base of the scapula. 3. The anterior or inferior border. 4. The superior posterior angle. 5. The inferior angle. 6. The glenoid cavity which articulates with the head of the humerus. 7. The neck of the scapula; the long head of the triceps is attached to the ridge opposite the number. 8. The flat, triangular surface over which the tendon of the trapezius glides. 9. The spine of the scapula. 10. The acromion process. 11. The supra-spinous fossa. 12. The infra-spinous fossa. 13. The supra-scapular notch. 14. The coracoid process. 15. A vascular foramen for one of the nutritious arteries.

spinata is larger, is convex above, and concave and grooved inferiorly. Between this and the inferior costa is a raised surface extending from the inferior angle to the glenoid cavity. This surface is divided into two by an oblique line; the posterior portion is flat and somewhat square, and gives attachment to the teres major muscle, the anterior to the teres minor. Into the ridge between these is inserted an aponeurosis common to these two muscles. The *superior* or *cervical* border, or *costa* of the scapula, is the shortest and thinnest. At its forepart is a notch which is converted into a hole by ligament, and sometimes by bone; it is traversed by the supra-scapular nerve, and sometimes by the vessels of that name. To this costa the supra-spinatus, subscapular, and omo-hyoid muscles, are attached. From the anterior part of this border, in front of the notch, arises the *coracoid process*, which is long and narrow, and directed at first upwards and forwards, and then downwards; is convex and rough above for the attachment of the conoid and trapezoid ligaments, smooth and concave below; it overhangs the inner and upper part of the glenoid cavity: the pectoralis minor is inserted into it anteriorly, the biceps and coraco-brachialis into its summit, and the triangular ligament into its external border. The *base* of the scapula, or the posterior or vertebral edge, is the longest margin of the bone; is convex, and nearer the spine above than below: the spinati muscles adhere to its outer lip, the subscapular to its inner, and the rhomboid to its middle. About one-fourth from its upper extremity is a blunt projection formed by the smooth, triangular root of the spine. At the union of the base and upper costa is the *superior posterior angle*, which is embraced by the levator anguli muscle. The *anterior* or inferior or external or *axillary costa* is very thick, leads from the glenoid cavity, and inclines downwards and backwards. At its junction with the base it forms the *inferior angle*, on which is a long, flat surface, which gives origin to the teres major and to a few fibres of the latissimus dorsi muscle; to the upper part of it the long head of the triceps is attached. At the convergence of this and of the superior costa are the neck and the glenoid cavity. The *neck* is that contracted portion which supports the head, and is most distinct externally and inferiorly, but is accurately defined: the coracoid process is attached to the upper surface of its root. The *glenoid cavity*, or the anterior angle, is superficial, oval, broader and deeper below, covered with cartilage, and, in the recent subject, deepened by the fibrous glenoid ligament, which is partly derived from the long tendon of the biceps, which is attached to the upper extremity of the cavity; it is inclined outwards, forwards, and a very little upwards; its aspect, however, varies as the scapula is made to turn in the rotatory motions of the arm. The scapula is composed of two compact laminæ and an intervening cellular tissue; the latter prevails in the processes, in the neck, and inferior angle; in the middle of the fossa there is but little of it, and the compact substance is there thin and transparent. It is developed by several points of ossification, one in the centre of the body, one for each of the

processes, one for the inferior angle, and one for the posterior or vertebral edge. It is articulated to the humerus and clavicle.

The *os humeri* is attached to the scapula above and to the radius and ulna below; is the longest and largest bone in the upper extremity, and presents two extremities and a body or shaft. The *upper* or *scapular extremity* is the larger, and consists of the head, neck, and two tubercles. The *head* is hemispherical, inclined upwards, inwards, and backwards; is smooth, and covered with cartilage for articulating with the glenoid cavity of the scapula. The *neck* is the slightly contracted line, or furrow, around the head; it is rough for the attachment of the capsular ligament, and a little longer below and before than above or behind. The axis of the neck and head forms an obtuse angle with that of the shaft. The *tuberosities* are two, the greater and lesser. The *great* or *external* presents three depressions: to the anterior of these the supra-spinous muscle is attached, to the middle the infra-spinous, and to the inferior or posterior the teres minor. The *internal* or *lesser tuberosity* is also anterior; it is more prominent, and gives insertion to the subscapular tendon. Between these tubercles is the deep groove for the long tendon of the biceps, into the anterior or outer edge of which the tendon of the great pectoral is inserted, and into its posterior or inner, those of the teres major and latissimus dorsi: this groove leads downwards and inwards. Immediately above these tendinous insertions, and below the tuberosities, the bone is circular and contracted in size: this part is named the *surgical neck*, as it is a very frequent seat of fracture. The *body* or *shaft* of the humerus is thick and round above, twisted in the middle, expanded and somewhat triangular below. Its posterior surface is round above and twisted a little inwards; below it looks outwards, and is flat and broad. This surface is covered by and gives attachment to the triceps muscle; a small, vascular foramen may be observed about the centre. The anterior or internal surface is divided for about one-fourth of its length by the bicipital

Fig. 124.*

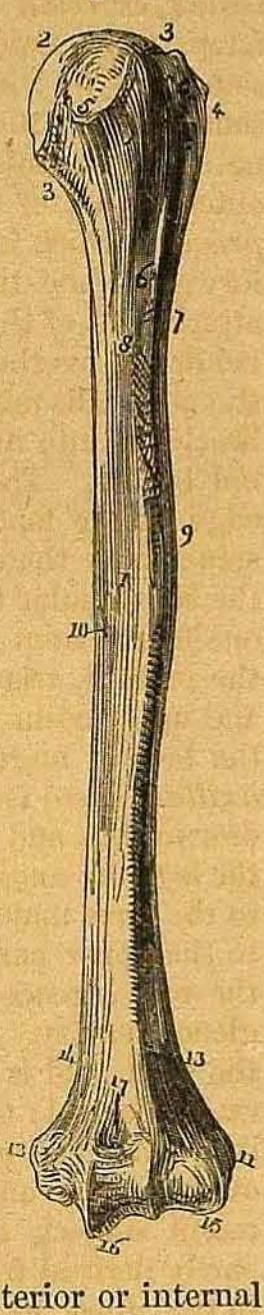

* The anterior surface of the left humerus. 1. The body or shaft. 2. The head. 3. The neck. 4. The great tuberosity. 5. The lesser tuberosity. 6. The bicipital groove. 7. The anterior or outer edge of the bicipital groove. 8. Its posterior or inner edge. 9. The rough surface for the insertion of the deltoid muscle. 10. A foramen for a nutritious artery. 11. The external condyle. 12. The internal condyle. 13. The external condyloid ridge. 14. The internal condyloid ridge. 15. The capitulum or small head for articulation with the radius. 16. The trochlea for articulation with the ulna. 17. The coronoid fossa.

groove into two unequal portions, the internal of which is smooth, and presents near its centre a linear elevation for the insertion of the coraco-brachialis, in the lower part of which is an oblique vascular foramen: the brachial vessels and nerves descend along this surface. The external surface presents a long, rough eminence for the insertion of the deltoid muscle, of a V shape, and situated just below the upper third of the shaft. External to this the bone is grooved obliquely, as if twisted, for the passage of the musculo-spiral nerve and artery. This groove leads from the upper and posterior aspect of the bone at first downwards and outwards, and next downwards and forwards, to the forepart of the external intermuscular ridge. These surfaces of the humerus are separated by two prominent lines, one is external and anterior, the other is internal and posterior: these lines are more distinct below than above; they give attachment to the intermuscular ligaments, and lead down to either condyle. The external is interrupted about the middle by the musculo-spiral groove, but is very prominent below, curved forwards, and gives attachment to the brachiæus anticus, the supinators and extensors, the triceps, and the external intermuscular ligament. On the anterior surface of the humerus there is also a prominent line continued from the anterior edge of the bicipital groove; it is gradually flattened below, and covered by the brachiæus anticus muscle. The *lower extremity* of the humerus is flattened, elongated transversely, and twisted a little forwards. It presents internally the *internal condyle*, which is very prominent, and turned somewhat backwards: this gives attachment to the common tendon of the pronators and flexors and to the internal lateral ligament of the elbow-joint. Externally is the *external condyle*, not so prominent as the internal, and situated lower down; it gives attachment to the external lateral ligament and to the supinator and extensor muscles. Between and below these condyles is a series of articulating eminences and depressions, partly turned forwards; they consist of externally a *small round head*, which articulates with the head of the radius, internal to which is a slight depression corresponding to the margin of the radius. Internal to this is a sharp, semicircular ridge, extending round the lower end of the bone from behind forwards and from without inwards, separating the radius and ulna. Next to this is the *trochlea* for articulation with the ulna; this also leads from behind forwards and from without inwards; its inner border is lower than the outer, and the whole is so much below the level of the small head, and of the outer portion of the articular surface, as to give to the whole bone an oblique direction outwards when its lower end is placed on a horizontal plane. At the anterior extremity of this trochlea is a small depression for the reception of the coronoid process in flexion of the joint; and at the posterior is a large fossa which lodges the olecranon process in the extended state of the forearm. The bone between these depressions is thin and transparent, and sometimes deficient from absorption, in which case the two processes of the ulna nearly approximate, and are locked in the humerus. The humerus, like the femur, is of the compact structure in its body, and of the cellular in its extre-

mities; it contains a large medullary canal, and is developed from eight points of ossification, one for the head, one for each tuberosity, one for the shaft, one for the trochlea, one for the small head, and one for each condyle; the bone consists of three pieces to the age of twenty; the shaft and two epiphyses; the upper epiphysis includes the head and the two tuberosities, with a portion of the bicipital groove, and is separated from the shaft by a well-defined line, which, internally, is immediately below the cartilaginous border of the head, but in the rest of its circumference is below the tubercles; this line is not unfrequently the seat of fracture or separation; it is inferior to the anatomical neck, or the narrow oblique line between the head and tubercles, into which the capsular ligament is inserted; in this line also fracture occasionally occurs; and will be found to be within the capsule, whereas a fracture in the epiphysary line will be extra-capsular, as of course that also of the surgical neck of the bone.

Fig. 125.*

The *ulna* is situated at the inner side of the forearm, forms the principal portion of the elbow, but does not directly enter into the wrist-joint; is longer than the radius at the upper end, but falls a little short of it below; it is divided into the body and two extremities. The *upper extremity* is larger than the lower, and presents two processes and an intervening cavity. The posterior process, or the *olecranon*, is the highest part of the bone; its superior border gives attachment to the triceps extensor: posteriorly it presents a smooth, triangular surface, covered by skin and by a bursa; anteriorly it is concave, and covered with cartilage. The *coronoid process* is anterior and inferior to the preceding; anteriorly it gives insertion to the brachialis anticus muscle, internally to the flexors and pronators and to the internal lateral ligament, and externally it is hollowed out into the *lesser sigmoid cavity*, which receives the border of the head of the radius; this small cavity is oval, its long diameter being from before backwards; it leads superiorly into the *great sigmoid cavity*, which moves on the trochlea of the humerus in flexion and extension of the forearm: this sigmoid cavity resembles the letter C, if viewed in profile; its posterior vertical portion is larger than the anterior, which is horizontal; it is divided by a middle ridge into two lateral portions, of which the internal is the larger; these are each again divided by a transverse furrow, which ends in a notch

* The anterior view of the left ulna. 1. The olecranon process. 2. The great sigmoid cavity. 3. The coronoid process. 4. The lesser sigmoid cavity. 5. The anterior surface of the shaft. 6. The nutritious foramen. 7. The external edge which gives attachment to the interosseous ligament. 8. The small, round head at the carpal extremity of the ulna. 9. The styloid process of the ulna. 10. A depression for the insertion of the interarticular fibro-cartilage.

at either margin: this surface is all covered with cartilage, except the furrow, in which some fatty matter is lodged. The *body* of the ulna is divided into three surfaces by three lines; these surfaces are larger above than below. The anterior is slightly grooved for the flexor profundus, and presents superiorly a vascular foramen directed obliquely upwards. The internal surface is broad and concave above, and covered by muscles; below it is round and subcutaneous. The posterior surface is irregular; it is divided into two portions by a prominent line. Of these the superior and internal is broad, and gives attachment to the anconæus. The inferior and outer portion is long and narrow, and covered by the extensors of the thumb. The anterior edge is round, and gives insertion to the flexor profundus and pronator quadratus; the posterior edge is very distinct above, and gives attachment to an aponeurosis common to the flexor profundus and flexor and extensor carpi ulnaris; the external edge is sharp for the three superior fourths, and gives attachment to the interosseous ligament. The *lower* or *carpal end* of the ulna is small and round, and presents two eminences. The external is named the *head;* is round, and covered with cartilage, and received into the cavity in the inner border of the radius, and is contiguous inferiorly with the fibro-cartilage of the wrist, which separates it from the cuneiform bone and from the carpal articulation. The internal eminence, or the *styloid process*, is more prominent, and on a level with the posterior surface of the bone; it is conical, elongated, and a little everted; it gives attachment to the internal lateral ligament of the wrist. These eminences are separated posteriorly by a groove for the tendon of the extensor carpi ulnaris, and inferiorly by a depression for the insertion of the triangular fibro-cartilage. The ulna is articulated above to the humerus and radius, and below to the radius and inter-articular cartilage: it is developed from three points of ossification, one for the shaft and one for each extremity.

Fig. 126.*

The *radius* is shorter than the ulna by the length of the olecranon. It is situated at the outer and anterior part of the forearm, is larger below than above, is curved about the centre, and is convex outwards and backwards; it is the principal bone in the carpal joint, but only accessory as a rotatory bone in the elbow. It is divided into the body and two extremities; the *upper*

* The anterior surface of the left radius. 1. The head of the bone. 2. The smooth border for articulating with the lesser sigmoid cavity of the ulna and with the annular or coronary ligament. 3. The neck. 4. The tubercle. 5. The body or shaft. 6. The rough surface for the insertion of the pronator teres. 7. The internal edge to which the interosseous ligament is attached. 8. The lower or carpal extremity of the bone. 9. The styloid process of the radius. 10. The surface which receives the lower extremity of the ulna.

or *humeral end* presents a head, neck, and tubercle. The *head* is a circular, superficial cavity; its surface and circumference covered with cartilage, the former to articulate with the small head of the humerus, and the latter with the sigmoid cavity of the ulna and with the annular or coronary ligament. The internal or ulnar portion of the circumference is broader than the external. The *neck* is near an inch long, descends obliquely inwards, is contracted and circular. At its lower and inner extremity where it joins the shaft, is the *tubercle.* This process is directed backwards and inwards; into its inferior and posterior rough surface the tendon of the biceps is inserted: anteriorly it is smooth and covered by a bursa. The *body* or shaft of the radius is somewhat triangular, and presents three surfaces separated by three margins or angles. The anterior surface is broad below, and covered by the pronator quadratus; narrow above, where it gives attachment to the flexor pollicis; about one-third from the head is the orifice of the vascular canal, slanting obliquely upwards. The posterior surface is convex above, and covered by the supinator brevis; concave in the middle for the extensors of the thumb, and convex below. The external surface is round and convex, and presents near the centre a rough surface for the insertion of the pronator teres. Of the angles, or edges, the inner is most distinct; it is sharp, and gives attachment to the interosseous ligament. The lower or *carpal end* of the radius is irregularly square, broader internally than externally; its anterior prominent edge gives attachment to the anterior carpal ligament. Posteriorly it presents three grooves for the extensor tendons. One nearly in the middle line, narrow and oblique, lodges the tendon of the extensor secundi internodii pollicis; the second is at the ulnar side of this, is broad, and transmits the tendons of the extensor communis and indicator; and the third, which is to the radial side of the first, is divided into two for the tendons of the extensor carpi radialis, longus, and brevis. Along the external border is another groove leading downwards and forwards, and divided into two for the extensor ossis metacarpi and primi internodii pollicis. The border between these two last grooves is prolonged down into the *styloid process*, from the point of which the external lateral ligament of the wrist arises. The supinator longus tendon is attached to its base and to the bone above it. On the internal border is an oblong, smooth cavity, to receive the lower end of the ulna. Inferiorly the radius presents an articular surface, divided by a line from before backwards into two unequal portions. The external is large and triangular, and meets the scaphoid bone; the internal is smaller, somewhat square, and meets the lunar bone. The radius, like other long bones, is of a cancellated structure at each extremity, and compact in the centre, where it also contains a medullary canal, which is larger above than below. It is developed from three points of ossification, one for the shaft and one for each extremity.

The *hand* consists of the carpus, metacarpus, and fingers; twenty-seven bones in all.

The *carpus* is composed of eight bones, arranged in two rows. The

first row consists of the scaphoid, lunar, cuneiform, and pisiform; the *second* of the trapezium, trapezoid, magnum, and unciform; enumerating them from the radial to the ulnar side, or from without inwards.

The *scaphoid* or *navicular* is the largest in the upper row, at the radial or outer side of which it is situated. It presents four articular surfaces; it is elongated and convex on the upper or radial surface, adapted to the external depression on the end of the radius. The inferior surface, directed a little outwards and backwards, is triangular, smooth, and concavo-convex, to articulate with the trapezium and trapezoid. Into the posterior narrow surface ligaments are inserted. To the external or radial side the external lateral ligament is attached. The inner or ulnar side presents two smooth, articulating surfaces; one superior, narrow, to articulate with the lunar bone; the other inferior, large, and concave, to articulate with the head of the magnum; it thus meets five bones.

Fig. 127.*

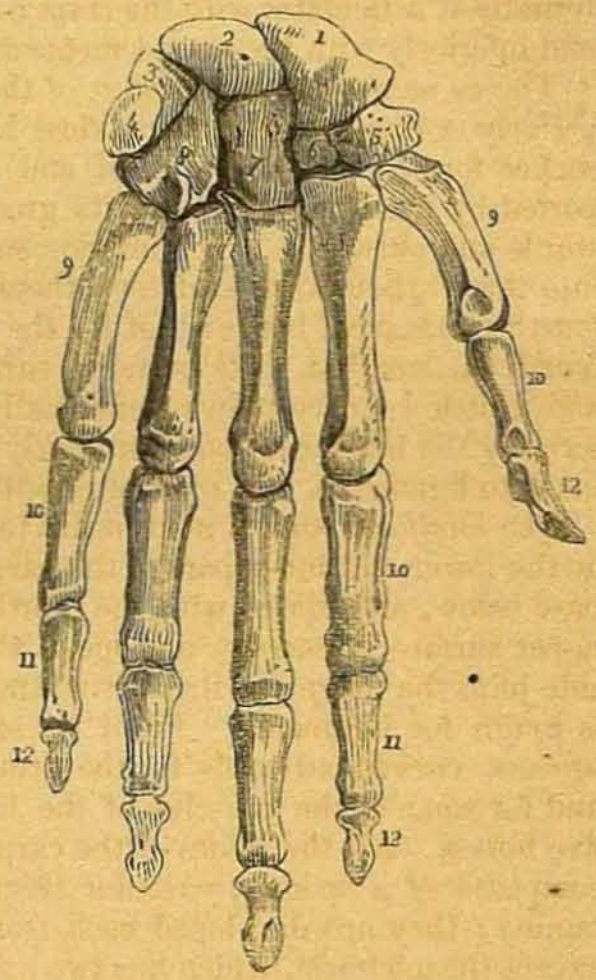

The *lunar* or *semicircular bone* is smaller than the scaphoid. It presents four articulating surfaces; smooth and convex above to meet the radius, concave below to articulate with the magnum and unciform; its ulnar side is flat to meet the cuneiform, and its external to meet the scaphoid; its anterior surface is larger than its posterior, and projects a little into the palmar arch. It is articulated to five bones.

The *cuneiform* or *pyramidal bone.* The base of this wedge-shaped bone looks outwards, and articulates with the lunar; the apex is inwards; it is convex and smooth above to meet the carpal fibrocartilage; concave and smooth below to articulate with the unciform bone; rough posteriorly and internally for ligaments. Anteriorly it presents

* The anterior or palmar surface of the bones of the hand. 1. The scaphoid or navicular bone. 2. The lunar. 3. The cuneiform. 4. The pisiform. 5. The trapezium. 6. The trapezoid. 7. The os magnum. 8. The unciform. 9. 9. The five metacarpal bones. 10. 10. 10. The first row of phalanges, five in number. 11. 11. The second or middle row of phalanges, four in number. 12. 12. 12. The last or ungual phalanges, five in number.

a flat, circular, cartilaginous surface for the pisiform bone. It is articulated to three bones and to the fibro-cartilage.

The *pisiform bone*. This small, pea-shaped bone is the smallest in the carpus, at the upper and inner part of which it is placed ; it is also on a plane anterior to the first row ; it is articulated to the cuneiform bone by a small, circular surface ; its circumference is rough for the attachment of ligaments ; the flexor carpi ulnaris is inserted into it above, and the abductor minimi digiti below.

The *trapezium* is the most external of the second row of the carpus ; it is concave above to meet the scaphoid, below it is convex from behind forwards, and concave transversely, to support the metacarpal bone of the thumb by a pulley-like surface ; anteriorly it is marked with a groove for the tendon of the flexor carpi radialis ; internally it is articulated to the trapezoid, and beneath this by a small surface to the second metacarpal bone. It joins four bones.

The *trapezoid* is of a very irregular shape, and smaller than the trapezium ; above it is smooth and concave to meet the scaphoid ; externally it articulates with the trapezium, internally with the magnum, and inferiorly with the second metacarpal bone. It joins four bones.

The *os magnum* is the largest of the carpal bones. It presents superiorly a round and hemispherical head, which is received into the socket formed by the scaphoid and lunar bones ; this head is supported by a contracted neck ; its greatest convexity is turned backwards and outwards. The inferior surface of the magnum is divided into three articulating surfaces ; these support the second, third, and fourth metacarpal bones : that for the third is the largest, and for the fourth the smallest. Its posterior surface is broad and convex below, and a little concave above ; externally it joins the trapezoid, and internally the unciform ; both anteriorly and posteriorly it gives attachment to ligaments. It articulates with seven bones.

The *unciform bone* is next in size to the os magnum. It is situated at the lower and inner part of the carpus, is rather wedge-shaped, the base below, articulated with the fourth and fifth metacarpal bones ; its upper surface is narrow, and meets the semilunar bone ; its external side joins the magnum, its internal the cuneiform ; its posterior surface is rough for ligaments. From its anterior projects a small hooked process, curved outwards for the attachment of the annular ligament and for some of the muscles of the little finger. It articulates with five bones. All the bones of the carpus, like those of the tarsus, are composed of a spongy, vascular tissue, invested by a thin, compact lamina ; they are developed each from a single point of ossification, except the unciform, which has two : the pisiform is the latest to ossify.

The *metacarpal bones* belong to the class of long bones. They are five in number, are placed nearly parallel to each other, except the first, or that of the thumb, which is on a plane anterior to the others, and is thick and short ; the third is the longest. They are all concave on the palmar surface, convex on the dorsal, and large at each extremity. The *posterior end* is of an irregular figure ; the *anterior* pre-

sents a round head. The *palmar surface* of each is narrow, and presents a median prominent line. The *posterior surface* of the first is convex, but on the second, third, and fourth, it presents a prominent longitudinal line, which bifurcates and forms the sides of a flat, triangular surface, extending for near two-thirds of their length. Into their edges the interossæi muscles are inserted. The dorsal surface of the fifth is divided by an oblique line diagonally; the outer portion is concave, and lodges the fourth interosseous muscle; the inner convex and broad, is covered by the extensor tendon of the little finger. The carpal end or base of the first is concave from before backwards, and convex transversely, to articulate with the trapezium; the base of the second is concave, and articulates with the trapezoid, and presents also externally a small, smooth surface for the trapezium, and internally two smooth surfaces, one for the magnum, the other for the base of the third metacarpal. The base of the third is nearly plane, and rests on the magnum, and presents on either side articulating surfaces for the contiguous

Fig. 128.*

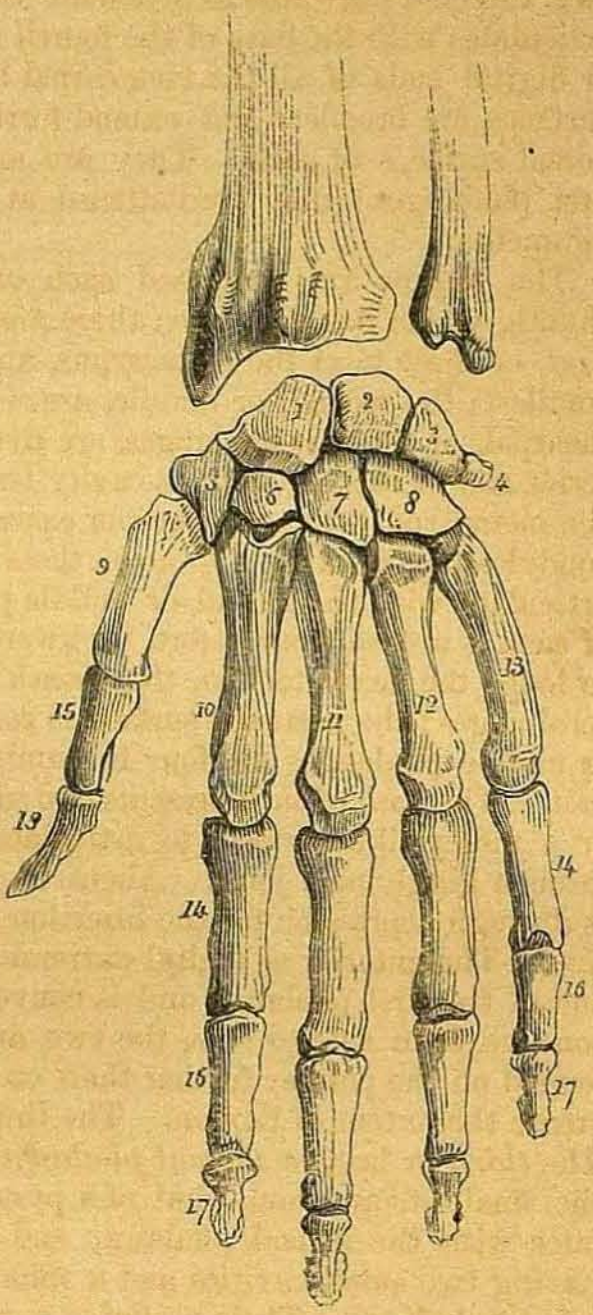

* The posterior or dorsal surface of the bones of the hand, comprising the carpus, metacarpus, and fingers. 1. The scaphoid or navicular bone, articulating with five bones. 2. The lunar or semilunar, articulating with five bones. 3. The cuneiform, articulating with three bones and with the triangular fibro-cartilage. 4. The pisiform, articulating with the cuneiform only. 5. The trapezium, articulating with four bones. 6. The trapezoid, articulating also with four bones. 7. The os magnum, articulating with seven bones. 8. The unciform, articulating with five bones. 9. The first metacarpal bone, articulating by its carpal end with the trapezium only. 10. The second metacarpal bone, articulating by its base with four bones. 11. The third metacarpal bone, articulating by its base with three bones. 12. The fourth metacarpal bone, articulating by its base with four bones. 13. The fifth metacarpal bone, articulating by its base with two bones. 14. 14. The first row of phalanges. 15. The first phalanx of the thumb. 16. 16. The second row of phalanges. 17. 17. The third or ungual phalanges. 18. The last or ungual phalanx of the thumb.

metacarpal bones. The base of the fourth presents two articulating surfaces, one for the magnum and one for the unciform ; on the radial side two, and on the ulnar side one articulating surface for the adjacent metacarpal bones. The base of the fifth presents a concave surface, directed outwards to articulate with the unciform ; its radial side articulates with the base of the fourth metacarpal bone. The anterior or digital ends of all the metacarpal bones are convex ; their smooth surfaces are broader, and extend further on the palmar than on the dorsal surfaces of each. They are articulated with the bases of the first phalanges ; they are flattened at the sides for the attachment of ligaments.

The *fingers* are composed each of three phalanges, except the thumb, which has only two : there are fourteen phalanges in all. The *first*, or those next the metacarpus, are the largest ; the *third* are the smallest; the second, or middle, are of an intermediate size. The metacarpal, or the first phalanges, are five in number. The base or posterior end of each presents a cavity transversely oval for the head of the metacarpal bone ; the anterior extremity of each presents two small condyles separated by a groove ; these are prolonged anteriorly, and articulate with the second or middle phalanx. The anterior surface of each is arched from before backwards, hollowed from side to side to lodge the flexor tendon, the sheath of which is attached to its lateral edges ; the posterior surface is convex and arched. The *second* or middle phalanges are four in number ; they are smaller than the first. The base of each presents two small cavities and a middle ridge, or a pulley-like surface, to articulate with the first, with which it forms a ginglymoid joint. About the centre of their anterior surface is a rough depression for the insertion of the tendon of the flexor sublimis. The anterior or digital extremity of each resembles the anterior end of the first phalanx, and is convex from before backwards, and concave from side to side, the two articulating condyles being prolonged on the palmar further than on the dorsal surface, so as to increase the extent of flexion. The thumb wants this second phalanx. The *third* or last, or *ungual phalanges*, are five in number ; they are the smallest, and somewhat of a pyramidal form. The base articulates with the second phalanx, and presents a pulley-like surface, having two small cavities and a middle ridge, such as the base of the second phalanx. Their posterior surface, convex, supports the nail ; their anterior is rough, and irregularly concave for the attachment of the flexor tendon and ligaments ; its anterior extremity or apex is irregularly tuberculated to support the extremity of the finger. The phalanges in structure resemble metacarpal bones : the last, or the ungual, are more cellular, and have no medullary canal ; they are developed each from two points of ossification, one for the shaft and one for the anterior extremity. The posterior end is continued from the shaft.

On the forepart of the articulation, between the metacarpal bone and the first phalanx of the thumb, there are generally two *sesamoid*

bones, and sometimes one in the corresponding joint of the index finger. These bones, like those in the foot, as well as in other situations, where they are occasionally found, as behind the condyles of the femur, in the heads of the gastrocnemii muscles, &c., do not properly belong to the osseous system; they are rather accessories to the tendons of muscles; they are found in the limbs only, and generally in the direction of flexion. They are developed from cartilage, which is deposited in tendinous or ligamentous structure, and which is very slow to ossify. The patella has some resemblance to bones of this class; it is, however, more perfect, and is placed on the aspect of extension. The sesamoid bones serve to strengthen the articulations to which they are attached; they also increase the power of the muscles, by altering the direction of their tendons and removing them further from the axis of the bone which they are intended to move.

Os Hyoides.—For the description of this bone *see* Dissection of the Larynx, p. 57.

Fig. 129.*

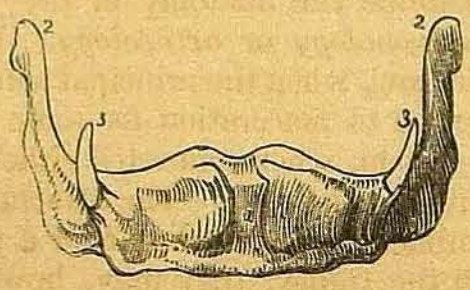

* The anterior view of the os hyoides. 1. The anterior convex surface of the body. 2. 2. The greater cornua. 3. 3. The appendices or lesser cornua.

CHAPTER II.

DISSECTION OF THE JOINTS.

SECTION I.

GENERAL OBSERVATIONS.

WHEN all the muscles, vessels, nerves, &c., have been dissected, the student may examine the anatomy of the joints, the study of which is termed *syndesmology* or *arthrology*. Different sections of these should be made, and, when the principal soft parts are removed, they should be subjected to maceration for some days. The several parts of the osseous system, when connected either by natural or artificial media, constitute the skeleton. The attachment between two or more bones is denominated an articulation or a joint, of which there are great varieties in the frame; they may, however, all be reduced to three classes, the moveable or diarthrosis, the immoveable or synarthrosis, and the mixed or amphiarthrosis.

1. DIARTHROSIS, or the moveable, includes all the perfectly moveable joints, and presents three species, viz.: *enarthrosis*, *arthrodia*, and *ginglymus*. The first resembles the ball and socket, of which the hip and shoulder are the best examples. The second is a modification of the first, the surfaces being nearly plane and the motion more limited. The articulations between the oblique processes of the vertebræ, those between the bodies of the latter and the heads of the ribs, and many others to be noticed hereafter, are examples. The third is the hinge or trochlea, and is more complex, the motion being limited to two directions, forwards and backwards, or flexion and extension, as in the articulations of the elbow and knee, and between the phalanges of the fingers and toes. In these motions the axis of the hinge is tranverse; there are other joints, however, which may be considered ginglymoid, the axis being vertical, like the hinge of a door, as the odontoid process of the second vertebra within the ring formed by the atlas and its transverse ligament, also the head of the radius within the coronary ligament and the lesser sigmoid cavity of the ulna; some, however, consider these as pivot joints, others as arthrodial.

2. SYNARTHROSIS, or the immoveable, includes three species, viz.: *suture*, *gomphosis*, and *schindylesis*. *Suture* is the serrated inter-

locking observable between the bones of the head and face. In most instances the opposed edges are indented like the teeth of a saw; in some few they meet by rather plane surfaces (harmonia), and in others they are scaly, and one overlaps the other (squamous suture). Although the bones are very intimately connected together in these lines, yet there is always a fine membrane interposed, which is continuous with the periosteum on either surface. *Gomphosis* is seen in the connexion between the teeth and their sockets, and *schindylesis* between the vomer and the other parts composing the septum narium.

3. AMPHIARTHROSIS, or the mixed, include those cases in which the bones are connected by an intervening fibrous or fibro-cartilaginous substance, and enjoy very different degrees of mobility, in some being free and obvious, as between the bodies of the vertebræ; in others very much restricted, and almost inappreciable, as in the pubic and ilio-sacral symphisis, and between the different portions of the sternum. In these latter examples the bones are so closely attached and fixed that *symphisis* is arranged by some writers under synarthrosis, or the immoveable articulations. The joints present such variety of form and such modification of structure, in order to effect security and strength, as well as to admit of motion or yielding, in such varied degrees, that many of them exhibit mixed characters, or combine in one the properties of several; hence no arrangement or classification of the articulations can be critically correct.

All the moveable articulations include several structures differing in use and organization, viz., the extremities of two or more bones; these are covered by cartilage; a synovial membrane, covered by a fibrous capsule, or strengthened by accessory ligaments and fascia. Some joints also contain interarticular cartilages and ligaments, also reddish vascular adipose masses. The articular, or incrusting cartilages, adhere almost inseparably to the ends of the bones; they are smooth and elastic, composed of fibres which are placed perpendicular to the bone; they are thickest on the most convex part of the heads of bones and on the circumference of the articular cavities (p. 690).

The *interarticular cartilages*, or *fibro-cartilages*, are very elastic; the fibrous tissue in some of them is very evident. Many of these are attached to the circumference of the cavities forming the *glenoid* or *cotyloid* ligaments, which serve to deepen the cavity and to prevent the hard edges of the bones striking against each other. Some interarticular cartilages are moveable, as in the temporo-maxillary and knee-joints: all these bodies serve either to deepen the cavities, or to attach the bones more closely, or to lessen shocks.

Synovial membranes of joints are very thin sacs, similar to the bursæ, allied also to the great serous membranes, inasmuch as they exhale and absorb a fluid, and are shut bags without any opening; they are, on the whole, however, more vascular and less elastic than the true serous membranes; the synovia also, or the fluid which the former secrete, is a glairy, unctuous-feeling fluid, albuminous and alkaline, and different from the fine, watery exhalation of the latter. Every synovial membrane lines the fibrous capsule or accessory cover-

ings; is thence reflected over the interarticular cartilages or ligaments when present, and over the articular or incrusting cartilages, and in some cases over portions of the bones themselves. On the cartilages the membrane is so fine and delicate as to be incapable of perfect demonstration, except under the influence of maceration or disease. By the assistance of the microscope, however, a fine tesselated epithelium has lately been discovered on the surface of articular cartilage, similar to that on the parietal portion of the membrane. In some articulations the synovial membrane is complicated in its arrangement, being folded round tendons or ligaments, as in the hip and shoulder, or thrown into processes which contain fat and vessels, so as to resemble a vascular or glandular mass. Such exist in the knee and in many other joints, and have been improperly considered glands or follicles by Havers and others.

Ligaments are important appendages to joints, and present great variety as to structure and arrangement; they are principally composed of the white fibrous, but in some situations of the yellow or elastic tissue. The former consists of white, glistening bands or fasciculi, tough, unyielding, and inelastic, the fibres arranged either in parallel lines, as in the lateral and transverse ligaments, or interwoven in every direction, as in the capsular.

SECTION II.

TEMPORO-MAXILLARY ARTICULATIONS.

THESE are examples of double arthrodia; they have also some of the characters of ginglymus, and are, therefore, denominated by some double arthrodial ginglymoid joints. Each condyle of the inferior maxilla, being received into that portion of the glenoid cavity of the temporal bone which is anterior to the fissure, can also move on the transverse root of the zygoma. Each maxillary condyle is transversely oval, and directed inwards and backwards, so that their axes, if produced, would meet posteriorly. The transverse eminence of each zygoma is in a parallel line to each condyle, is convex from before backwards, and concave transversely, and covered by cartilage. Only the anterior portion of each glenoid cavity is articular, and covered by cartilage. The Glasserian fissure which limits it posteriorly is directed transversely inwards and forwards, and, if these fissures be produced, they would meet anteriorly; hence the articular cavity is somewhat triangular, wide externally, narrow internally. These joints are strengthened by an external and internal lateral, an inter and a stylo-maxillary ligament, and by an imperfect but rather strong capsular ligament, which contains an interarticular cartilage and two synovial membranes.

The *external lateral ligament* is short and narrow; it arises from the tubercle at the junction of the two roots of the zygomatic process of the temporal bone, descends obliquely backwards, and is *inserted* narrow into the outer side of the neck of the condyle of the lower jaw: it is covered by the skin and the parotid gland, and it adheres to the capsular ligament, of which it seems to be but a thickened fasciculus.

Fig. 130.*

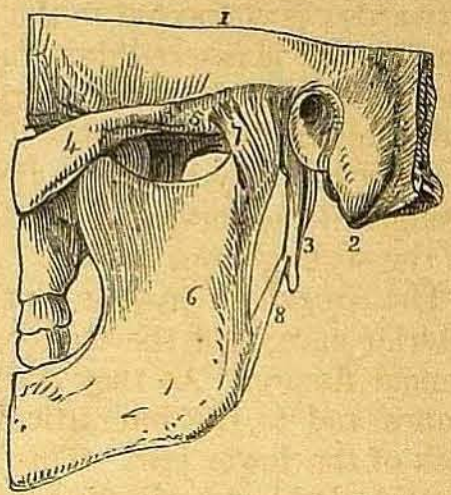

The *internal lateral ligament* is thinner and longer than the external; it *arises* narrow from the spinous process of the sphenoid bone, descends obliquely forwards, and is *inserted* broad into the inner margin of the orifice of the inferior dental canal. Its insertion is pierced by the mylo-hyoid nerve. This aponeurotic band corresponds externally to the capsule and to the external pterygoid muscle above, and lower down to the internal maxillary vessels, and to the dental vessels and nerve which intervene between it and the bone. Its inner surface rests on the internal pterygoid muscle, which it thus bears off from compressing the dental nerve and vessels. It is not properly a ligament to the articulation, although a few of its deep fibres adhere superiorly to the capsule: these latter are by some named *short internal lateral* ligament.

Fig. 131.†

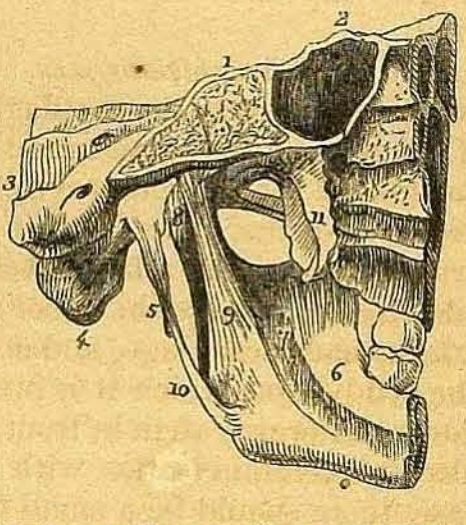

The *intermaxillary ligament* scarcely deserves the name of ligament; it is rather a dense, vertical, aponeurotic band, common to the buccinator and superior constrictor of the pharynx; attached *above* to the external pterygoid process and

* An external view of the temporo-maxillary articulation of the left side. 1. A part of the squamous portion of the temporal bone. 2. The mastoid process of the temporal bone. 3. The styloid process of the temporal bone. 4. The zygomatic arch. 5. The tubercle at the root of the zygoma. 6. The ramus of the lower jaw. 7. The external lateral ligament. 8. The stylo-maxillary ligament.

† An internal view of the temporo-maxillary articulation. 1. A vertical section through the basilar process of the occipital bone, and through the body of the sphenoid bone, shewing (2) a portion of the sphenoidal sinus. 3. The internal surface of the petrous portion of the temporal bone. 4. The mastoid process. 5. The styloid process. 6. The internal surface of the ramus of the lower jaw. 7. The orifice of the inferior dental canal. 8. The internal portion of the capsular ligament. 9. The internal lateral ligament. 10. The stylo-maxillary ligament. 11. The pterygoid process of the left side.

adjacent surface of the superior maxillary bone, and *below* to the root of the coronoid process of the inferior maxilla.

The *stylo-maxillary ligament* is a thin aponeurosis which *arises* from the styloid process of the temporal bone, passes forwards and outwards; is connected to the cervical fascia and to the stylo-glossus muscle, and is *inserted* into the angle of the lower maxilla, between the masseter and internal pterygoid muscles, and between the parotid and submaxillary glands. This ligament, like the last mentioned, does not properly belong to the articulation; it is rather intended to strengthen the cervical fascia and to increase the surface of attachment for the stylo-glossus muscle.

The *capsular ligament* consists of dense fibres which *arise* from the anterior margin of the transverse zygomatic eminence and from the glenoid fissure. As they descend they *adhere* to the synovial membranes and to the interarticular cartilage, and are *inserted* into the neck of the lower jaw. This ligament is covered posteriorly by the parotid gland and adipose substance; externally and internally by the lateral ligaments, and in part by the external pterygoid muscles. It is deficient at the anterior and internal part to admit the insertion of the external pterygoid into the interarticular cartilage and into the neck of the bone; it is wider above than below, and it is prolonged very low down upon the bone behind.

Fig. 132.*

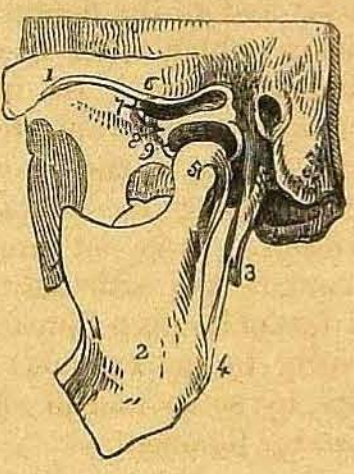

The *synovial membranes*, one superior and larger, covers the cartilaginous surface of the zygomatic eminence and the articular portion of the glenoid cavity, and is reflected over the upper surface of the interarticular cartilage; the other, the lower and smaller, covers the under surface of the interarticular cartilage, and is reflected over the condyle on which it is prolonged lower down posteriorly than in front. These sacs have no communication with each other, unless, as is sometimes the case, there should be a small foramen in the centre of the cartilage.

The *interarticular fibro-cartilage* is transversely oval, thick in its circumference, thin in the centre. Its upper surface is adapted to the articular eminence and to the forepart of the glenoid cavity, being concave before and convex behind, and its lower surface, which is smaller,

* The temporo-maxillary articulation. In this view the external lateral ligament has been removed, the interarticular fibro-cartilage, and two synovial membranes, divided by a vertical section, and the condyle of the lower jaw drawn downwards out of the glenoid cavity, in order to shew the disposition of the internal structures of the joint. 1. The zygomatic arch. 2. The ramus of the lower jaw. 3. The styloid process. 4. The stylo-maxillary ligament. 5. The left condyle of the lower jaw. 6. The outer extremity of the transverse root of the zygoma, or eminentia articularis. 7. The superior synovial membrane. 8. The interarticular fibro-cartilage. 9. The inferior synovial membrane.

fits on the condyle. Some fibres of the external pterygoid are attached to its inner and forepart; the capsular and external lateral ligament also adhere to it: sometimes there is a hole in the centre of it through which the synovial membranes communicate. This cartilage is composed of very close, concentric fibres, which are more distinct at the circumference; it has no direct attachment to bone, as the interarticular cartilages in some joints, and therefore it partakes less of the fibrous structure; it serves to strengthen the articulation, and thus to guard against displacement, by presenting to the condyle a moveable socket, which prevents it slipping off the articular eminence of the temporal bone, on which the condyle rests every time the mouth is fully opened, for this joint presents the rare example of one convex body being occasionally opposed to another: this cartilage also serves to lessen friction in the joint, as well as the effects of pressure and concussion.

The motions of the lower jaw are not very conspicuous at the articulations, but are considerable towards the forepart of the bone. This can be depressed, elevated, moved backwards, forwards, and towards either side. In depression of the chin the condyles, together with the interarticular cartilages, advance and descend a little, so as to rest on the transverse roots of the zygomatic processes; in elevation the condyles are behind these roots in the glenoid depressions; in rotation the condyles move alternately, one being the fixed point for the other; thus, in moving the chin to the right side, the right condyle is fixed in the glenoid cavity, while the left advances and descends a little, and the contrary state occurs in moving the chin towards the left side. These motions occur rapidly and alternately in masticating or grinding the food; they have been explained in the chapter on the muscles (p. 20).

The condyles of the lower jaw are very liable, one or both, to dislocation; this can only occur in the anterior direction. When both condyles are thus displaced, there is a perfect dislocation; when only one condyle, it is a partial dislocation. In the perfect form the mouth is opened, and cannot be closed, as the coronoid process strikes against the malar and maxillary bones; the incisor teeth of the lower jaw are on a plane anterior to those of the upper, and their edges are directed rather forwards. There is also a depression in front of each ear, and the temporal muscles seem elongated; articulation and deglutition are much impaired. When the partial dislocation occurs, the chin is turned a little towards the opposite side, and the other symptoms exist in a less marked degree. Dislocation of this bone, either perfect or partial, is caused by the spasmodic action, not merely of the depressing muscles, but principally of the external pterygoid, assisted by the internal pterygoid and the superficial lamina of the masseter. When the mouth is wide open, we can readily conceive how those muscles, particularly the external pterygoid, can draw forwards the condyles from off the articular eminences of the zygomatic processes into the temporal fossæ, under the zygoma, and place them between this arch and the temporal muscle. In general but little injury is inflicted on any of the ligaments of the articulation; the internal lateral and part

of the capsule may be lacerated; the elevator muscles are tense, also the intermaxillary ligament; the external pterygoid and the depressors are relaxed. Dislocations of this bone cannot occur in the child under four years of age, in consequence of the peculiar form of the jaw, the angle being so obtuse, and the ramus directed so obliquely forwards and downwards.

SECTION III.

ARTICULATION OF THE OCCIPUT WITH THE ATLAS.

This is a double arthrodia, the condyles of the occipital bone being received into the superior oblique processes of the atlas. The former, oval and convex, look downwards and outwards, and converge anteriorly; the latter correspond to these in size and shape, and look upwards and inwards. These joints are secured by capsular ligaments and synovial membranes, which cover the opposed cartilaginous surfaces. The anterior and posterior arches of the atlas, and its transverse processes, are also attached to the occipital bone, by an anterior and posterior and two lateral ligaments.

Fig. 133.*

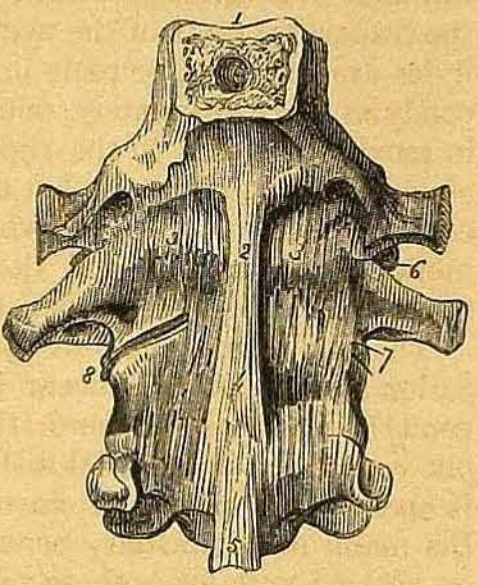

The *capsular ligament* on each side *arises* from the circumference of the condyle, and is *inserted* into that of the glenoid cavity of the atlas. These ligaments are sufficiently loose to allow of slight motion, and are strong anteriorly and externally. The *synovial membranes* line the interior of each capsule, and are reflected over the opposed cartilaginous surfaces of the condyle and the cavity.

Anterior and *posterior occipito-atlantal ligaments arise* from the edges of the foramen magnum, and are *inserted* into the upper border of the atlas, before and behind its oblique processes. The *anterior* consists of two portions, one is superficial, a strong, round fasciculus, extending from the basilar process to the tubercle on the atlas; the deep portion is broad and thin, and passes from the forepart of the foramen magnum to the anterior ring of the atlas; it rests on the odontoid process and its ligaments, and is covered by the recti antici

* An anterior view of the ligaments connecting the occipital bone, the atlas, and the axis. 1. A transverse section of the basilar process of the occipital bone. 2. The anterior round occipito-atlantal ligament. 3. 3. The anterior broad occipito-atlantal ligament. 4. The anterior atlanto-axoid ligament. 5. The commencement of the anterior common vertebral ligament. 6. One of the occipito-atlantal capsular ligaments. 7. One of the atlanto-axoid capsular ligaments. 8. The articulating surfaces of the oblique processes exposed by the removal of the capsular ligament.

minores. The *posterior* is broad, but thin and weak; adheres to the dura mater, and is pierced on either side for the vertebral vessels and suboccipital nerves; it is covered by the posterior lesser recti and inferior obliqui muscles.

The *lateral ligaments* are strong cords extending from the transverse processes of the occipital bone to those of the atlas; they are continuous with the sheaths of the great vessels and nerves at the base of the skull. In these arthrodial articulations no horizontal rotatory motion can occur; flexion and extension, or a forward and backward movement of the head, and a very slight lateral flexion, or what are termed the "nodding motions" of the head, can alone take place.

Fig. 134.*

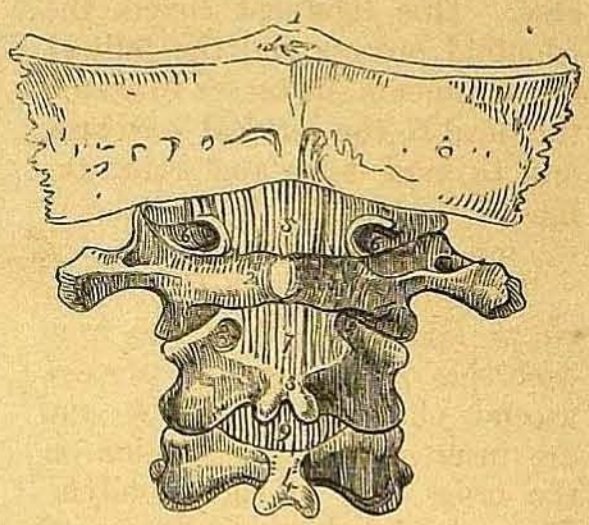

SECTION IV.

ARTICULATION OF THE OCCIPUT WITH THE AXIS OR SECOND VERTEBRA.

The occipital bone, though not in contact with, is yet connected to the axis by the lateral or moderator ligaments, one on each side, and by the apparatus ligamentosus colli in the middle: this may, therefore, be considered as examples of amphiarthrosis or syndesmosis. To expose these ligaments, the laminæ and spinous processes of the four or five superior cervical vertebræ must be removed with the saw immediately behind the oblique processes. The dura mater being next removed from the forepart of the section, we obtain a view of the cuneiform process of the occiput and of the posterior surface of the bodies of the vertebræ covered by ligaments.

The *apparatus ligamentosus*, or middle occipito-axoid ligament, is a thick, flat fasciculus of fibres, which descends from the lower part of the cuneiform process, behind the odontoid process, and is inserted centrally into the superior part of the transverse ligament of the atlas, and below this into the body of the second vertebra, and on either side, very thick, into the bodies of the second, third, and fourth vertebræ.

* A posterior view of the ligaments connecting the occipital bone to the atlas and the atlas to the axis. 1. A portion of the occipital bone. 2. The posterior arch of the atlas. 3. The axis. 4. The third cervical vertebra. 5. The posterior occipito-atlantal ligament. 6. The opening in the posterior ligament for the vertebral vessels and suboccipital nerve. 7. The posterior atlanto-axoid ligament. 8. The lateral aperture in this ligament. 9. The first pair of ligamenta subflava.

On the latter it becomes continuous with the posterior common vertebral ligament; it is common to the occiput, and to the three or four superior cervical vertebræ. The central band is the perpendicular ligament of old writers, and has been described incorrectly as inserted into the point of the odontoid process. This ligament covers the odontoid process and the following ligaments; it serves to attach the head to the cervical vertebræ, and to bind down and secure the lateral ligaments; it also resists too much flexion of the neck.

Fig. 135.*

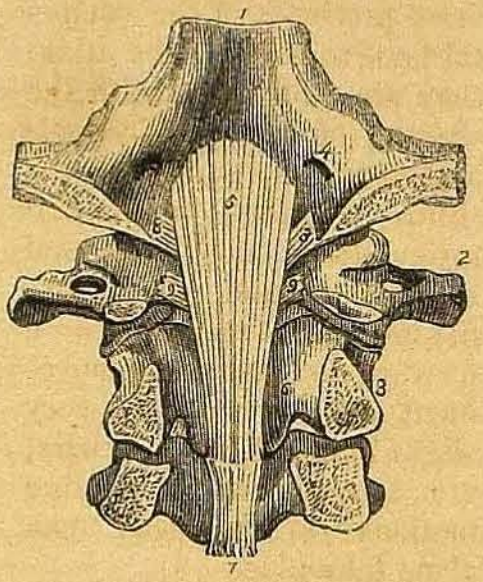

The *lateral* or *moderator*, or *check ligaments*, arise one from each side of the odontoid process, ascend obliquely outwards, and are inserted into a depression on the inner side of each condyle. These short and strong ligaments are covered posteriorly, or towards the canal, by that last described; anteriorly they are covered by cellular tissue and by the anterior occipito-atlantal ligaments. These have little or no influence over flexion or extension, but they check or regulate the degree of rotatory motion between the axis and the atlas. In rotation of the head, the occiput and the atlas form but one system, which rolls on the pivot-like process of the second vertebra or axis. To the point of the odontoid process there is no true ligament attached; a little filamentous tissue only ascends from it to the anterior edge of the foramen magnum. The two check ligaments are usually united by a fasciculus, which passes above the summit of this process.

Fig. 136.†

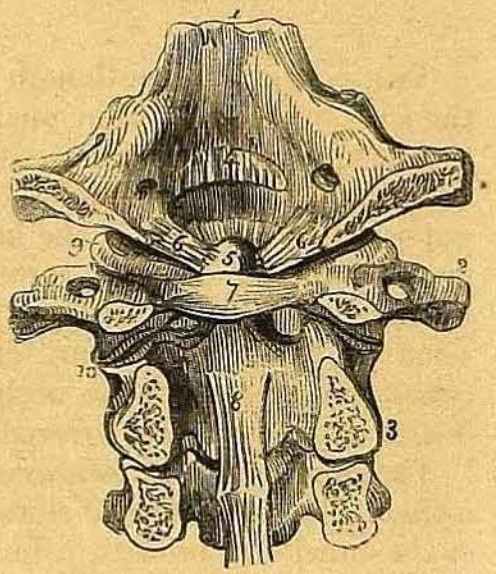

* A posterior or internal view of the occipito-axoid articulation, the back part of the occipital bone and vertebral canal having been removed. 1. The basilar process of the occipital bone. 2. The transverse process of the atlas. 3. The axis. 4. The anterior condyloid foramen. 5. The occipito-axoid ligament, or apparatus ligamentosus. 6. Its insertion into the body of the axis. 7. The commencement of the posterior common vertebral ligament. 8. 8. A portion of the lateral or odontoid ligaments. 9. 9. The extremities of the transverse ligament of the atlas.

† A posterior view of the ligaments connecting the atlas, the axis, and the

SECTION V.

ARTICULATION BETWEEN THE FIRST AND SECOND VERTEBRÆ, OR THE ATLAS AND AXIS.

THESE two vertebræ present three articulations; one in the centre, between the odontoid process and the body of the atlas; and two lateral, between the oblique processes: these may all be considered arthrodial surfaces, the atlas being the recipient for the three, presenting concave, articulating surfaces for each; the central one is vertical and the deepest, the lateral are horizontal and superficial. The central articulation is secured by a transverse ligament and two synovial membranes, and the lateral joints possess the usual capsular and synovial apparatus. These two vertebræ are also connected by an anterior and posterior ligament similar to the occipito-atlantal.

The *transverse ligament* is behind the odontoid process (*see* fig. 136); it describes the fourth of a circle, is thick, broad, and fibro-cartilaginous in the centre; smooth, concave, and polished anteriorly; attached on each side to the inner edge of each oblique process of the atlas, and connected in the centre by a narrow band of the apparatus ligamentosus to the cuneiform process superiorly, and by a broader one to the body of the axis inferiorly, so as to present a cross-like figure so long as these attachments remain. The *synovial membranes* are connected one to the posterior surface of the odontoid process and to the anterior surface of this ligament; the other covers the opposed cartilaginous surfaces of the atlas and of the processus dentatus. By means of this ligament a circular collar is formed, the lower fibres of which form a smaller circle than the superior, which encloses and constricts the base or neck of the axoid process, and binds it to the atlas; while the two synovial sacs are beautiful provisions to admit of the partial rotation of the latter around the former, in which movements the head and atlas may be considered as one solid piece, they not having any independent or separate rotatory motion. The importance of the transverse ligament is great and obvious; hence, when softened and ruptured in disease of this central articulation, death has been instantaneous, the head having fallen forwards, and the odontoid process, projecting backwards, has either compressed or pierced the medulla oblongata.

occipital bone. The posterior part of the occipital bone, together with the posterior arch of the atlas and the laminæ of the axis, have been removed. 1. The basilar process of the occipital bone. 2. The transverse process of the atlas. 3. The axis. 4. The superior portion of the posterior occipito-axoid ligament, or apparatus ligamentosus; the central portion of which has been removed in order to shew the ligaments beneath. 5. The odontoid process of the axis. 6.6. The lateral or odontoid ligaments. 7. The transverse ligament of the atlas. 8. The inferior extremity of the occipito-axoid ligament. 9. Articulation of the condyle of the occipital bone with the glenoid cavity of the atlas. 10. The articulation of the oblique processes of the atlas and axis.

The lateral articulations are secured by *capsular ligaments* and *synovial membranes*, which are sufficiently lax to admit of the necessary rotatory motions. These ligaments are attached to the circumference of the oblique processes, and are lined by loose and well moistened synovial membranes, which are thence reflected on the cartilaginous surfaces of the opposed bones: the vertebral vessels are in contact with these capsules; they sometimes communicate with the synovial membranes of the odontoid process.

The *anterior atlanto-axoid ligament* extends from the tubercle and lower margins of the anterior arch of the atlas to the body of the dentatus; is inserted below the base of the odontoid process; is thick and strong, and continuous with the anterior vertebral ligament (fig. 133).

The *posterior* is thin, broad, and weak; extends from the posterior arch of the atlas to the upper edge of the laminæ of the dentatus; it corresponds in situation to the ligamenta subflava inferiorly, but is thin, membraneous, and non-elastic (fig. 133).

SECTION VI.

THE COMMON ARTICULATIONS OF THE VERTEBRÆ.

The vertebral column consists of a great number of parts, which are so connected as to combine with considerable elasticity and flexibility sufficient strength to support the whole frame, as well as to afford security to the important nervous organ it contains. From the inferior surface of the second cervical to that of the last lumbar vertebra one similar series of ligaments, though somewhat differently modified in the different regions, serves to unite the several vertebræ to each other, and to connect the whole into one upright and powerful column.

The bodies of the vertebræ are connected by amphiarthrosis, the articular processes by arthrodia, and the other processes by syndesmosis. The ligaments are, therefore, classed into two sets: those which unite the bodies and those which unite the processes. The first comprise the anterior and posterior common vertebral ligaments and the intervertebral fibro-cartilages or ligaments; the second set include the capsules and synovial membranes of the oblique processes, the infraspinous or yellow ligaments, or the ligaments of the laminæ or crura of the spinous processes, the interspinous, the supraspinous, and the intertransverse.

The bodies of the vertebræ are united by an anterior, a posterior, and intervertebral ligaments.

The *anterior vertebral ligament* is a strong band of fibres extending from the axis to the sacrum, and adhering to the bones, particularly to their edges and to the intervertebral substances. Some of the fas-

ciculi are very long, others very short, and some of the deep fibres cross obliquely between the bodies of the vertebræ; its lateral fasciculi are separated from the central by foramina, for the passage of the nutrient vessels of the bones. This ligament is narrow in the cervical and superior lumbar regions, broader, thicker, and more distinct in the dorsal and lower lumbar, but in the neck and loins its edges are confounded with the superincumbent and adjacent tendons. Its relations are obvious; it serves to attach the vertebræ, to strengthen the intervertebral ligaments, and to oppose excessive extension of the column.

Fig. 137.*

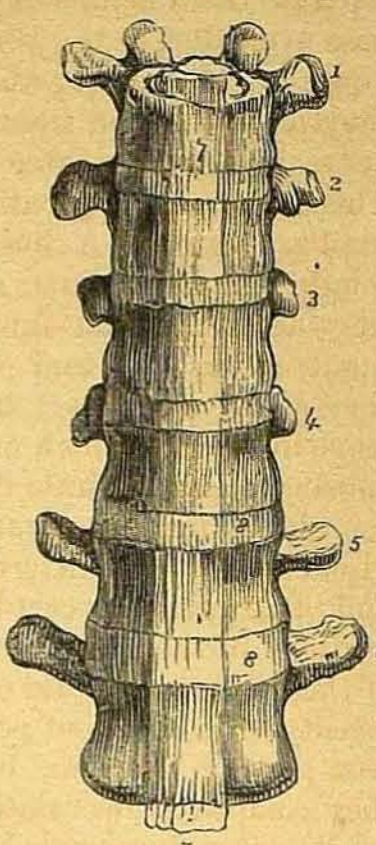

The *posterior vertebral ligament* is partly prolonged from the apparatus ligamentosus; extends down the back part of the bodies of the vertebræ, along the front of the spinal canal. It consists of smooth, glistening fibres, of which the superficial are the longest; is narrow in the dorsal and broad in the cervical region; it adheres more closely to the edges of the vertebræ and to the intervertebral ligaments than to the middle of each vertebra, from which it is separated by vessels, principally veins, which escape from the large foramina on the posterior surface of each vertebra; the dura mater can be easily detached from it, being connected to it by delicate cellular tissue; Its margins present a series of lunated processes, from its being prolonged more laterally on each intervertebral ligament than on the vertebra itself, where it is narrowed. This ligament, like the last, gives strength to the spine; it opposes too much flexion of the column.

Fig. 138.†

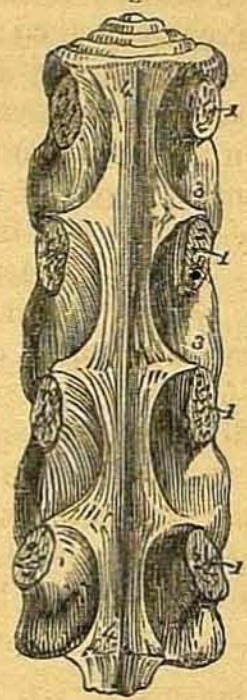

The *intervertebral ligaments*, or *fibro-cartilages*, are placed between the bodies of all the vertebræ, except of the first and second. These substances partake of the fibrous or ligamentous character much more than the cartilaginous; they are united above and below to the flat sur-

* An anterior view of the common articulations of the vertebræ. 1, 2, 3, 4 The transverse processes of the last four dorsal vertebræ. 5, 6. The transverse processes of the first two lumbar vertebræ. 7. 7. The anterior common vertebral ligament. 8. 8. The intervertebral fibro-cartilage.

† A posterior view of the bodies of four dorsal vertebræ, connected together by

faces of the vertebræ in so intimate a manner that maceration alone can separate them completely, and their own strength and cohesion surpass even that of the bones themselves; they are covered and bound down by the anterior and posterior ligaments. In the neck and loins they are thicker in front than behind, and the contrary in the back; hence in a great degree the peculiar curvatures of the spinal column. Their structure is peculiar and complex; it is best examined in the lumbar region. A horizontal section exhibits an arrangement of tough, fibrous laminæ, apparently concentric, yet not exactly so, for they decussate and intersect each other. These laminæ are more numerous in front and on the sides than behind; towards the surface they are very compact and close, but as they pass more inwards they leave interstices which are filled with a soft, pulpy, whitish, semifluid substance, and towards the centre, or rather a little behind that point, the fibrous tissue becomes rather cellular, the areolæ filled with this viscid pulp. The external layers are the strongest and most elastic, and often present a cartilaginous appearance, and in old persons some portions of these are occasionally found ossified. A vertical section of these substances also exhibits the fibrous structure and the different density of its different portions. In this view the fibres are distinctly seen passing from one bone to another in such oblique courses that they completely decussate. In this section also the ligamentous tissue swells out and expands beyond the limit of the bony surfaces, owing partly to the elastic resistance of the external layers being then removed. When these ligaments are subjected to maceration they swell, become very full and tense, and, if cut horizontally, the central fluid portion will be found to rise up like a conical, pulpy pivot. The intervertebral substance is more perfect in the adult than in the very young or very aged; in the latter the pulpy substance is less, and is yellowish and dry, and the whole ligament is diminished in depth and in elasticity; whereas in the very young the fluid portion is thinner and in greater quantity; it is also of a lighter colour, and sometimes presents a rosy tint. At this early age it presents some resemblance to the perfect cup-like cavities filled by fluid between the vertebræ in fish. These ligaments serve to increase the height or length of the spine, without adding much to its weight; to connect most firmly its several component pieces; to complete the spinal canal, also the sockets for the heads of the ribs and the intervertebral foramina; they permit of yielding or flexibility in the column to a great degree, restore the spine to its vertical bearing by their elasticity, which is one of their most remarkable and superior properties; they also lessen the effects of concussion, and prevent shocks being transmitted from the lower limbs to the brain; they constitute the spine a sort of strong,

their ligaments. 1. 1. Sections of the laminæ close to the bodies of the vertebræ, the bony arches and processes having been removed. 2. The conical swelling caused by a horizontal section of the intervertebral fibro-cartilage. 3. 3. The intervertebral fibro-cartilages connecting the bodies of the vertebræ. 4. 4. The posterior common vertebral ligament, presenting a series of lunated processes.

flexible, and elastic spring, in which, while they admit of sufficient yielding in every direction, they at the same time resist too much flexion, extension, lateral, and rotatory motion.

The oblique or articulating processes of the vertebræ are connected by *synovial* membranes and by ligamentous fibres extended irregularly around these, so as to form imperfect capsular ligaments. The synovial membranes are larger and looser in the cervical than in any other region, and smaller and dryer in the dorsal.

The *ligamenta subflava* are situated between the back parts of the plates, or the arches, of the vertebræ; close the intervals between them, and thus complete the back part of the spinal canal. They exist between all the vertebræ from the second to the sacrum; are most distinct in the loins, and are seen best from the interior of the canal. The upper edge of each is attached to the anterior surface of the lamina above, and the lower edge to the upper margin of the lamina below. They are composed of dense, yellow, vertical, and elastic fibres, closely connected together into a plate or lamina, which meets that of the other side in an angle beneath the base of the spinous process: a narrow, vertical, median line separates one from the other. They close the spinal canal posteriorly between the spinous processes, resist flexion of the column, and, by their elasticity, restore it to its erect condition without the expenditure of muscular power. In this respect, as well as in structure, they differ from true ligaments.

Fig. 139.*

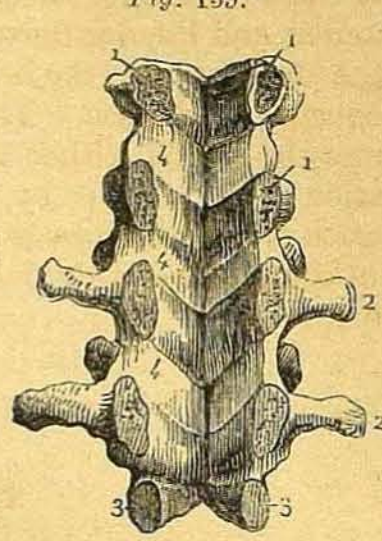

The spinous processes of the vertebræ are also connected to each other by ligamentous bands, termed *supraspinous* and *interspinous* (the ligamenta subflava may be called *infraspinous*).

The *supraspinous ligament* extends in the median line from the occipital bone to the sacrum (fig. 140). The cervical portion is usually considered under a distinct title, *ligamentum nuchæ;* attached above to the occipital protuberance, and below to the last cervical spine; and intermediately, by distinct slips, to all the cervical spines, except that of the atlas. These slips separate the muscles on either side. It is connected to and continuous with the numerous tendons of the extensor muscles; very variable in strength and size, and is rudimental of the remarkable structure in the necks of the large quadrupeds, in whom it is composed of the yellow, elastic, fibrous tissue. The re-

* An internal or anterior view of the laminæ of the vertebræ connected together by their ligaments. 1. 1. Section of the laminæ which have been sawn through their pedicles, and separated from the bodies of the vertebræ. 2. 2. The transverse processes. 3. 3. The oblique or articulating processes. 4. 4. The ligamenta subflava, or yellow elastic ligaments.

mainder of the supraspinous ligament extends from the last, or the prominent cervical spine, to the sacrum; is very thick and strong in the lumbar region and in the interspinous intervals; it is inseparably blended with the extensor tendons. The *interspinous* ligaments are thin, fibrous membranes, placed vertically; attached to the spinous process above and below. They do not exist in the neck, are thin and small in the back, and thick, strong, and square in the loins. The spinal muscles adhere to them on either side (fig. 140).

Between the transverse processes also ligamentous fibres exist, which are named *intertransverse ligaments.* These are thin, fibrous membranes attached to the adjacent muscles; are not distinct in the cervical or superior dorsal region, but are well marked between the lumbar and inferior dorsal vertebræ.

A dislocation of the head from the atlas has been only found in consequence of disease. The first cervical vertebra may be dislocated from the second, either as a consequence of disease or by a violent rotation of the head, or by a fracture of the processus dentatus. Dislocation of one vertebra is extremely rare, and is perhaps never simple, but complicated with violent injury to the bones, ligaments, and muscles.

SECTION VII.

ARTICULATIONS OF THE RIBS.

The true ribs are joined to the vertebræ behind and to the sternum before: the false or the five inferior ribs are only indirectly connected to the latter. Each of the costo-vertebral articulations, with few exceptions, involves two vertebræ and the intermediate substance. The head of each rib presents two slightly convex surfaces, which are received into the depressions on the sides of the bodies of two vertebræ; and the intermediate ridge or angle is connected by ligaments to the intervertebral substance. The tubercle of each rib is also articulated to the concavity on the forepart of the transverse process of the inferior of the two vertebræ, with whose bodies the head of the rib is articulated: thus the posterior end of each rib presents three articulations, two on the head and one on the tubercle; these all belong to the class arthrodia, the vertebræ forming the recipient surfaces. The internal costo-vertebral articulation, or that of the head of the rib, is secured by an anterior or stellate ligament, an interarticular, and two synovial membranes. The tubercle is secured in its socket by a synovial membrane and by an external, a posterior, and an anterior or internal costo-transverse ligament.

First, the *capsular* or *stellate*, or *anterior ligament*, *arises* from the front of the head of the rib, and thence extends over the two synovial membranes in a radiated manner, and is *inserted* by three

bands, one into the side of the vertebra above and below, and the third into the intervertebral substance.

Fig. 140.*

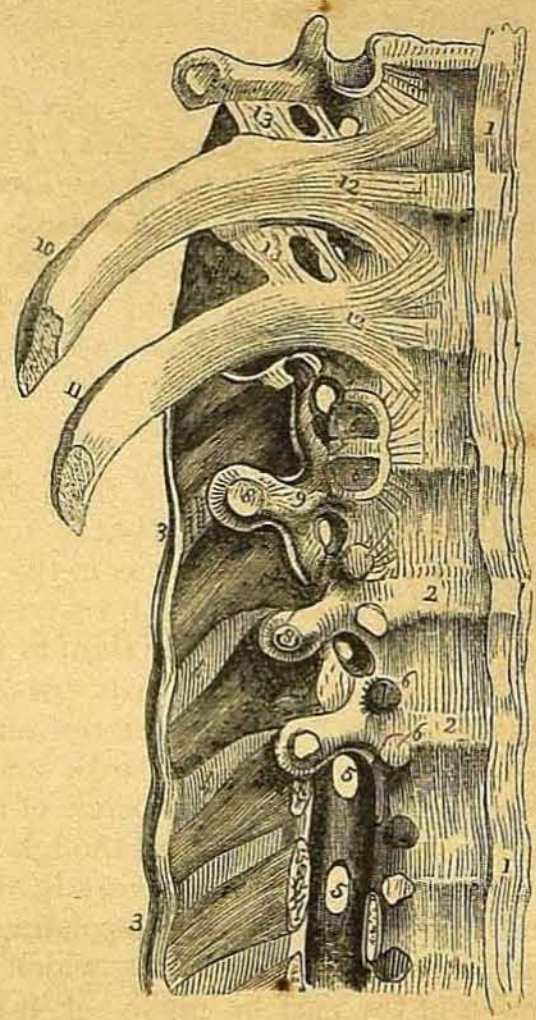

The *interarticular ligament arises* from the projecting ridge on the articular surface of the rib; is short, and somewhat yellowish, and is *inserted* into the cavity in the intervertebral substance into which the angle on the head is received; it separates the two synovial membranes.

The *upper synovial membrane* is smaller than the *lower*, and does not communicate with it. The stellate ligament and the synovial membranes are covered by the pleura, the thoracic ganglions of the sympathetic nerve, and on the right side by the vena azygos. The first, eleventh, and twelfth, have only one synovial membrane, and no interarticular ligament, there being only one articulating surface on their heads, which are joined to only one vertebra each.

The tubercle of each rib presents two surfaces, separated by a ridge. The external is rough for the attachment of ligaments; the internal is convex, and covered with cartilage, and is received into the articulating depression at the summit of the transverse process of the inferior of the two vertebræ, to the bodies of which the head is attached. A synovial membrane and three ligaments secure this articulation.

The *synovial membranes* of these external costo-vertebral joints are more loose and distinct than those of the heads of the ribs. The eleventh and twelfth ribs are not articulated to transverse processes, and have only very slight tubercles.

* A lateral view of the ligaments of the vertebral column and of the articulations of the ribs, with the corresponding vertebræ. The vertebral canal has been laid open inferiorly in order to shew the holes of conjugation. 1. A portion of the anterior common vertebral ligament. 2. 2. The intervertebral fibro-cartilage. 3. 3. The supraspinous ligaments. 4. 4. The interspinous ligaments. 5. 5. The intervertebral holes, or holes of conjugation. 6. 6. The lateral facettes on the bodies of the vertebræ, for articulation with the head of the rib. 7. A portion of the interarticular ligament of the rib inserted into the intervertebral fibro-cartilage. 8. 8. The articular facette on the transverse process of the vertebra, for articulation with the tubercle of the rib. 9. The anterior surface of the transverse process which gives attachment to the middle costo-transverse ligament. 10. 11. The fifth and sixth ribs. 12. 12. The anterior or stellate ligament of the rib. 13. 13. The anterior or internal costo-transverse ligament.

There are three ligaments termed costo-transverse, the posterior, the middle, and the anterior. These secure the connexion of the ribs to

Fig. 141.*

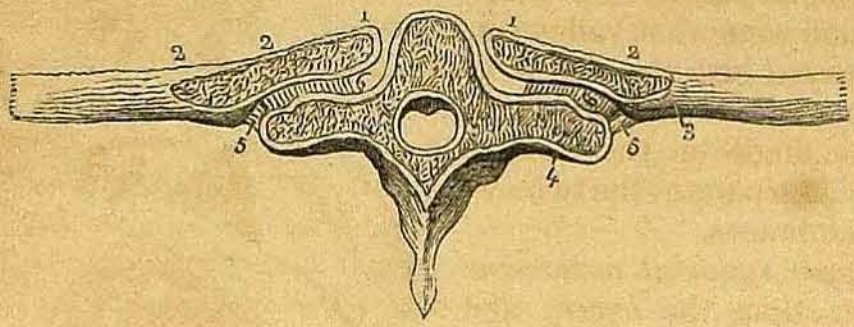

the transverse processes of the vertebræ; the two first connect the rib to its corresponding vertebra or transverse process, but the last connects this transverse process to the rib beneath; thus these three ligaments arise from the one transverse process; two are attached to the corresponding rib, and the third to the rib beneath.

Posterior or *external costo-transverse ligament*, flat, and somewhat square, *arises* from the posterior surface of the extremity of the transverse process; passes outwards, and is *inserted* into the rough, non-articular portion of the tubercle of the corresponding rib. This ligament exists on all the ribs, though very loose on the two last.

The *middle costo-transverse ligament* connects the back part of the rib to the front of the corresponding transverse process; it is a short, thick, interosseous ligament, which cannot be seen until a horizontal section of the part be made, or in the act of forcibly tearing the rib from the transverse process.

Anterior or *internal costo-transverse* is wanting in the first and twelfth ribs; *arises* narrow from the lower border of the transverse process, descends obliquely inwards and forwards, and is *inserted* broad into the crest on the upper edge of the rib beneath. The intercostal vessels and nerves lie upon it. Externally it is continuous with the intercostal aponeurosis; internally it bounds the opening through which the posterior branches of the intercostal nerves and vessels pass (fig. 140). From the double mode of articulation of the ribs but little motion can occur, and that only a slight elevation and depression, with a very little rotation. From the length, however, of the ribs, this motion has a considerable effect anteriorly and laterally in enlarging the thorax. All these ligaments are relaxed during inspiration. Simple dislocations of the vertebral ends of the ribs can never occur.

The cartilages of the ribs, at their costal ends, are convex, and are

* A horizontal section of two ribs and a vertebra, to shew the middle costo-transverse ligament. 1. The head of the rib, separated from the body of the vertebra. 2. The neck of the rib. 3. The tubercle of the rib. 4. The transverse process of the vertebra. 5. A part of the posterior costo-transverse ligament. 6. The middle costo-transverse ligament.

very closely united to the concave surfaces in the extremities of the bones by symphisis, or rather a sort of gomphosis. The sternal ends of the cartilages of the seven true ribs, except the first, are convex, adapted to the hollows in the edge of the sternum. These hollows are covered by cartilage and by synovial membranes; each joint is strengthened by ligamentous bands, which proceed from the cartilage before and behind the articulation, and are expanded upon the sternum, and are named *anterior*, *posterior*, *superior*, and *inferior sterno-costal ligaments*. There is no distinct joint between the first rib and the sternum; the cartilage and bone appear to be continuous; that of the second is sometimes divided into two cavities. The cartilages of the three superior false ribs are connected to that of the last of the true ribs, and the two last are unconnected. Dislocations of the costal or outer ends of the cartilages of the ribs are very rare; they sometimes, however, occur. Those of the sternal end are still more uncommon.

SECTION VIII.

LIGAMENTS OF THE SUPERIOR EXTREMITIES.

THESE comprise, first, the ligaments which connect the clavicle to the sternum; second, those connecting the clavicle to the scapula; third, those proper to the scapula; fourth, those connecting the humerus to the scapula; fifth, those connecting the bones of the elbow-joint, which will be afterwards subdivided; sixth, those of the wrist-joint, together with those of the inferior radio-ulnar; seventh, those of the metacarpus; eighth, those of the phalanges of the fingers.

SECTION IX.

1. STERNO-CLAVICULAR ARTICULATION.

THE articulating end of the clavicle is larger than the surface on the sternum; the former is triangular, the apex behind and below; the latter is rather oblong, slightly convex from before backwards, and concave from within and from above downwards and outwards; it looks outwards, a little backwards, and upwards, and is more on the posterior than the anterior aspect of the bone. The articulating surface on the sternum is extended inferiorly into a smooth depression on the upper surface of the sternal end of the first rib, where it joins its cartilage. This portion is considered by some as a distinct joint (*costo-clavicular*); as, however, its synovial membrane is a part of that which enters into the general articulation, we shall consider the

whole as one. The circumference of the clavicle is rough for ligamentous attachment. Its articulating surface is inclined downwards and

Fig. 142.*

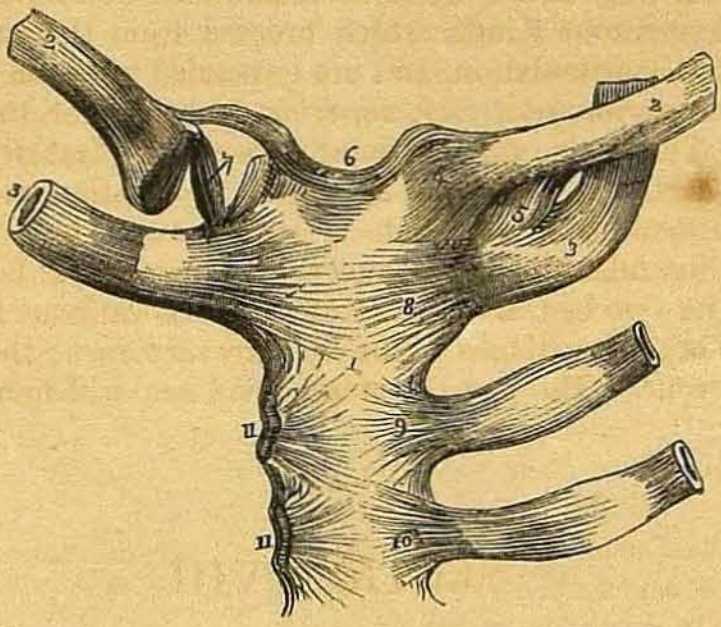

forwards; is uneven, and slightly concave from before backwards, and convex from above downwards. This articulation, which is of the arthrodial species, is secured by an anterior, posterior, inferior, and interclavicular ligament, also by an interarticular cartilage and two synovial membranes.

The *anterior sterno-clavicular ligament arises* narrow from the end of the clavicle, descends inwards, and is *inserted* broad into the fore-part of the sternum; is covered by the skin and by the tendon of the sterno-mastoid muscle; it covers and adheres closely to the synovial membranes and to the interarticular cartilage.

The *posterior ligament* takes a course behind the joint parallel to the preceding; it is narrower and weaker than the last, adheres to the joint, and rests upon the sterno-hyoid muscle. These two ligaments are so expanded over the joint as to resemble a capsular or orbicular ligament.

The *inferior*, or the *costo-clavicular* or *rhomboid ligament*, passes from the lower surface of the sternal end of the clavicle downwards, forwards, and inwards, and is *inserted* into the cartilage of the first rib; it closes the angle between it and the clavicle. The tendon of the subclavius muscle is in front of it; its upper or posterior surface is in

* An anterior view of the ligaments of the sterno-clavicular and sterno-costal articulations. 1. The anterior surface of the sternum. 2. 2. The clavicle. 3, 3. The first rib. 4. The anterior sterno-clavicular ligament. 5. The costo-clavicular or rhomboid ligament. 6. The interclavicular ligament. 7. The interarticular fibro-cartilage. 8, 9, 10. The anterior sterno-costal ligaments of the first three ribs. 11. 11. The depressions in the edge of the sternum for articulation with the costal cartilages.

contact with the subclavian vein. It serves to confine the clavicle in its place, and to resist its dislocation upwards; it also prevents the sterno-mastoid muscle separating the clavicle from the chest.

The *interclavicular ligament* extends from the posterior surface of one clavicle to the other; the deep cervical fascia is attached to its upper concave edge; its lower border is generally attached to the posterior lip of the sternum; it is covered by the integuments, and lies upon the sterno-hyoid muscles. It connects the clavicles to each other and to the sternum; it also protects the soft parts immediately above the latter, and resists the atmospheric pressure at the top of the thorax.

The *interarticular cartilage* is nearly circular; it is thin below, and attached to the sternum and to the cartilage of the first rib; is thick above, and attached to the clavicle; it is very thin, and often perforated in the centre; the sterno-clavicular ligaments adhere to it before and behind; it serves to adapt the two slanting bony surfaces to each other; it also binds them together like a true ligament, at the same time yielding a little to facilitate their motions.

The *synovial membranes* are connected to each surface of this cartilage; they are generally very dry, and the cavity of each is often interrupted by ligamentous bands.

In this articulation the end of the clavicle can move a little upwards, downwards, forwards, and backwards; it also enjoys circumduction. All these motions appear very limited and confined at this joint, but on account of the length of the clavicle they become very considerable at the shoulder. When the sternal end of the clavicle is depressed, the shoulder is raised; when the former is elevated, the latter is depressed; and when the sternal end is directed forwards or backwards, the shoulder is moved in the contrary direction. Of all these motions in this joint, that backwards is the most restricted. Circumduction consists in the combination and succession of these different simple motions, and is more extensive forwards and upwards than downwards and backwards. The shoulder accordingly enjoys it downwards and backwards more freely than forwards or upwards. In these different motions it is easy to perceive the use of the several ligaments, and the manner in which each is affected as to relaxation or tension. The interarticular or fibro-cartilage is of essential surface, not merely as a powerful ligament, but, from its close attachment to the clavicle, it yields, and glides a little along with it, and thus prevents its displacement; it also lessens the influence of pressure and concussion from blows or falls upon the shoulder.

SECTION X.

2. SCAPULO-CLAVICULAR ARTICULATION.

THE oval end of the clavicle is connected to that of the acromion process in a plain, arthrodial joint, which is secured by a *superior* and *inferior acromio-clavicular ligament.* These are attached to the surfaces of each bone, and, as they are united or continuous before and behind the joint, they may be considered as a strong orbicular ligament. In some individuals, particularly among the labouring class,

Fig. 143.*

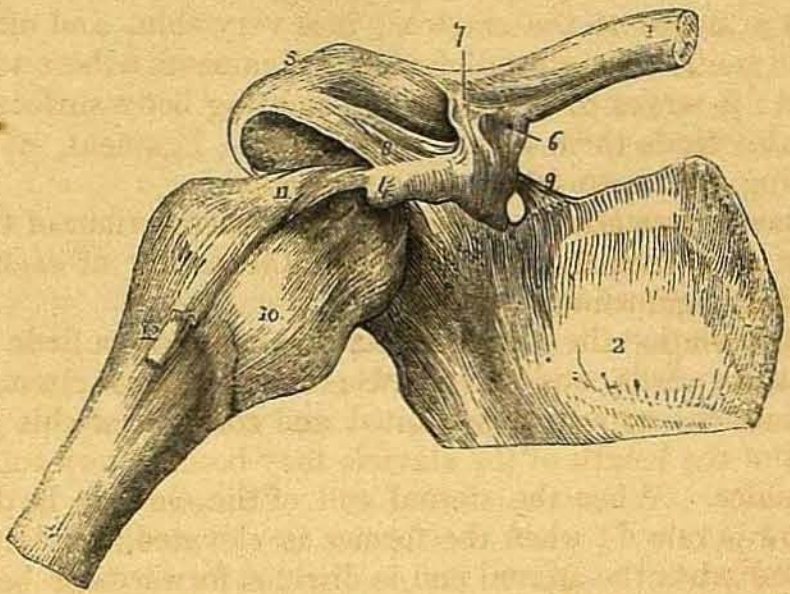

and on the right side, this capsule, though very thick, is loose and free, and allows the two surfaces to glide freely upon each other, and does not even retain them in apposition, the end of the clavicle being on a much higher level than the acromion. The synovial membrane between these bones is sometimes very imperfect, both it and the fibro-cartilage resembling an intervertebral substance. In other cases there are two distinct synovial membranes, separated by a perfect interarticular cartilage; the latter is thicker at the upper part of the joint, and is often confined to that situation. The deltoid and trapezius muscles strengthen this articulation considerably, and adhere very closely to these ligaments. The two following ligaments do not properly belong to this articulation; they are, however, very essential in

* The ligaments of the scapulo-clavicular and humero-scapular articulations. 1. A portion of the clavicle. 2. The upper part of the internal surface of the scapula. 3. The upper part of the humerus. 4. The coracoid process of the scapula. 5. The superior acromio-clavicular ligament. 6. The conoid ligament. 7. The trapezoid ligament. 8. The coraco-acromial or deltoid ligament. 9. The posterior or coracoid ligament. 10. The capsular ligament of the shoulder-joint. 11. The coraco-humeral or accessory ligament. 12. The long tendon of the biceps, passing through the capsular ligament, and descending in the bicipital groove.

connecting the scapula and clavicle; they are about an inch to the inner side of the acromio-clavicular articulation. These are the conoid and trapezoid ligaments.

The *conoid* is the posterior, and the smaller of the two. Its base is attached to a rough, tubercular surface, on the lower and posterior margin of the clavicle; its apex to the base of the coracoid process, in front of the notch in the superior costa of the scapula.

The trapezoid is more anterior and external, it is also broader and stronger, than the conoid; it is about an inch distant from the articulation, and is attached above to an oblique line on the inferior surface of the clavicle; thence it descends obliquely inwards to the upper and internal margin of the coracoid process. These ligaments are united posteriorly and externally; anteriorly they are distinct, the extremity of the subclavian muscle intervening, and sometimes a bursa or synovial sac, which covers a small cartilaginous surface on the coracoid process, and on which the clavicle glides, so as to present a true articulation between these bones.

The *coraco* or *costo-clavicular fascia*, though not a ligament, serves to strengthen the connexion between the clavicle and scapula, as also between both these bones and the first rib. (*See* page 80.) In the acromio and coraco-clavicular articulations the scapula enjoys some motion around the clavicle. At the acromial it glides forwards and backwards, while rotation occurs between the conoid and trapezoid ligaments, the former restraining too much motion forwards, the latter backwards.

The clavicle at its sternal end may be dislocated forwards. Displacement upwards or backwards is too rare to merit any notice. In a perfect dislocation forwards the anterior, posterior, costo-clavicular, and interclavicular ligaments, are ruptured; and occasionally the tendinous expansion of the sterno-cleido-mastoid muscle. At its scapular extremity the clavicle may be displaced either above or below the acromion; the latter case is extremely rare, almost unknown. When the clavicle passes above the acromion, the shoulder inclines inwards, being unsupported by this bone, the extremity of which projects beneath the integuments. The superior, inferior, and some fibres of the coraco-clavicular ligaments, are ruptured. The clavicular portion of the trapezius, by elevating the clavicle, assists in this displacement.

SECTION XI.

3. PROPER LIGAMENTS OF THE SCAPULA.—(*Fig.* 143.)

THESE are two in number, an anterior and posterior.

The *anterior*, or the *deltoid* or *coraco-acromial*, *arises* broad from the coracoid process, passes upwards, and is *inserted* narrow into the

point of the acromial process. This broad, thin, triangular ligament is often deficient or weak in the centre; it is covered by the deltoid muscle and the clavicle, and lies over the large bursa which covers the tendon of the supraspinatus muscle; it completes the protecting arch or vault which the acromion and coracoid processes nearly complete over the shoulder-joint.

The *posterior*, or *coracoid ligament*, *arises* from the superior costa of the scapula, behind the notch; passes forwards, and is *inserted* into the base of the coracoid process: it converts the notch into a foramen. This ligament is sometimes wanting; then the notch is completed into a hole by bone. The suprascapular nerve usually passes beneath this ligament, while the vessels of this name run above it.

To these two some add, as a third proper ligament of the scapula, the *inferior* or *spino-glenoid*, which, however, is very variable as to strength, and often indistinct. It *arises* from the anterior edge of the root of the spine, passes forwards and outwards, and is *inserted* into the upper part of the cervix. Sir A. Cooper conceives that, in fracture of the neck of the scapula, this ligament in some instances serves to suspend the glenoid cavity, and to retain it *in situ*.

SECTION XII.

4. HUMERO-SCAPULAR, OR SHOULDER ARTICULATION.

THIS joint is an enarthrosis, or ball and socket, though in the dry skeleton it appears to be only an arthrodia. The oval cavity on the scapula is much smaller than the round head of the humerus; both are covered by cartilage, which on the latter is thick on the centre, thin on the circumference, and the contrary on the former.

The head of the humerus is retained in the glenoid cavity by the capsular, the coraco-humeral or accessory, and the glenoid ligaments, and a synovial membrane.

The *glenoid ligament* adheres to the margin of the glenoid cavity, and deepens the socket for the head of the humerus; is strong and fibro-cartilaginous, very thick in its adherent edge, but thin in its free margin, and partly continuous with or derived from the long tendon of the biceps, which passes through the joint like an interarticular ligament, and appears to bifurcate at its upper extremity, and to join this ligament; the tendon itself is separated from the cavity by a fine synovial investment; both surfaces of the glenoid ligament are covered by synovial membrane.

The *capsular ligament arises* around the neck of the scapula (fig. 143). Increasing in size, it encircles the head of the humerus, and is *inserted* into its neck, and prolonged on the periosteum; it is dense above and below, thin internally and externally, very loose and long, but the

tendons of the four capsular muscles are identified with it, and to these it is greatly indebted for strength, being almost perfectly covered by them. A small portion, however, inferiorly, and a little internally, that is, between the tendon of the subscapular muscle and that of the long portion of the triceps, is deprived of this support; accordingly, in this situation, although the ligament itself is here rather stronger, dislocations of this joint usually occur. It is covered superiorly by the tendon of the supraspinatus, externally by that of the infraspinatus and teres minor, and internally by the subscapularis. These tendons form a portion of the capsule, and are even partly in contact with the synovial membrane. Inferiorly the long tendon of the triceps adheres to and strengthens it; the deltoid muscle also affords the joint a general support and protection. The apposition of the bones is chiefly owing to the tonic state of the surrounding muscles, as the capsule is too long and large to effect it; hence in paralysis of these muscles the head of the bone falls down, and is partly below the level of the cavity; and in dissection we find, when the muscles have been removed, the bones become considerably separated.

The *coraco-humeral*, or *accessory ligament*, extends obliquely downwards and outwards from the coracoid process to the anterior part of the great tuberosity, where it becomes confounded with the capsule and with the tendon of the supraspinatus muscle.

The *synovial membrane* is reflected over the glenoid surface, around the glenoid ligament; it then lines the fibrous capsule and the tendons of the adjacent muscles, and is next reflected over the head of the humerus; it also lines the bicipital groove by a process of about an inch and a half long, which presents a *cul de sac* inferiorly, and is thence reflected on the tendon, around which it is continued upwards to the summit of the glenoid cavity, so that this cord is not, strictly speaking, within the cavity of the joint. There are often some small, red, fatty masses under this membrane, near the edge of the scapula, and on the neck of the humerus. It frequently presents the appearance of an opening or inflection beneath the coracoid process, above or behind the subscapular tendon; this, however, is merely a communication between the subscapular bursa and the synovial membrane, and the latter is no less a closed sac: a similar communication is also often to be found with the bursa beneath the infraspinatus muscle.

Mr. Flood (Lancet, 1829-30, page 672) has described an *inarticular ligament*, which, he says, "may be easily exposed by cutting through the inferior part of the capsule transversely, and throwing back the arm over the head. You thus expose the interior of the upper part of the capsule, also the biceps tendon. Parallel to the inner edge of the latter this ligament may be felt, and exposed by a little dissection. The tendon of the subscapularis, in passing to its insertion, rests in a notch in the superior and internal part of the edge of the cavity. From the edges of this notch the ligament *arises*, broad and flat, then proceeds along the internal edge of the biceps tendon, and, becoming smaller and rounder, is *inserted* into a distinct

pit in the anatomical neck of the humerus, at the inner edge of the bicipital groove. Its inferior surface is covered by the synovial membrane, and the superior is applied to the fibrous capsule. In its triangular form, its origin at a notch in the articular fossa, and its insertion into a pit, it strongly resembles the 'ligamentum teres' of the hip-joint."

This articulation derives considerable strength and protection from the arch which is formed above it, to nearly the extent of a semicircle, by the coracoid and acromion processes, and by the triangular ligament which unites these. A very large bursa lies beneath this arch and the deltoid muscle, and over the supraspinatus tendon and the superior and anterior regions of the capsule.

The humero-scapular articulation enjoys very free and extensive motion forwards and backwards, analogous to flexion and extension, abduction and adduction, rotation and circumduction. Many of these motions are increased in extent, and at the same time effected with greater facility and safety by the mobility of the scapula on the ribs, and by the yielding and rotation at the acromio and sterno-clavicular joints.

The shoulder-joint, from the great extent of its motions, and form of its articulating surfaces, is more liable to dislocation than any other in the body. This accident may be primary or secondary.

Primary dislocations of the humerus may occur downwards or into the axilla, forwards or under the pectoral muscles, or backwards into the infraspinous fossa. This latter species is extremely rare. A dislocation upwards cannot occur without fracture of the acromion or coracoid process, and therefore cannot be considered among simple dislocations. A primary dislocation, either directly backwards or directly forwards, is not so likely to happen as that downwards, as the strong attachments of the teres minor, supra and infraspinati muscles to the greater tubercle of the humerus, and that of the subscapular to the lesser tubercle, respectively, offer powerful resistance in either of these directions. It is plain, from the construction of this joint, that a dislocation downwards is the most likely to occur; for the lower part of the capsular ligament, being unsupported by muscles, is most weak; and the action of the levator muscles of the shoulder, by rotating the head of the humerus from above down, will bring the head of the bone near to the inferior edge of the glenoid cavity, and thus place it in a situation most favourable for displacement when violence is applied to the extended arm. The greater extent, however, of the glenoid cavity in the vertical direction tends to guard against this accident; also the mobility of the scapula, whereby the glenoid cavity admits of being opposed to the head of the humerus by different muscles; and, above all, by the several muscles and tendons which cover and adhere to the capsule.

When the humerus is dislocated downwards, the head of the bone is found resting on the inferior or sternal costa of the scapula, between the long head of the triceps and subscapularis. The lower portion of the capsular ligament is ruptured, and frequently some of the fibres of the subscapularis. The tendons of the supra and infraspinati mus-

cles, and of the teres minor, are sometimes lacerated, and occasionally the tubercles of the bone are broken. Some of the fibres of the deltoid, pectoralis major, and coraco-brachialis, are also sometimes torn; the long tendon of the biceps usually, but not always, remains unbroken. Independent of external violence, the elevating muscles of the humerus and of the whole arm (if the elbow-joint be fixed), with the pectoralis major, latissimus dorsi, and teres major, may, under certain circumstances, effect the displacement of the bone. The deltoid and supraspinatus muscles are those which most powerfully resist reduction.

When the head of the humerus is dislocated forwards, it lies on the inner side of the neck of the scapula, between it and the second and third ribs; the serratus magnus and subscapularis generally intervene. The internal portion of the capsular ligament, and sometimes the tendon of the subscapularis, are ruptured.

In dislocation of the humerus backwards, the head of the bone lies in immediate contact with the scapula, under the infraspinatus muscle. The humerus is sometimes partially dislocated in cases of paralysis of the deltoid and of the capsular muscles, or in very aged and debilitated persons.

SECTION XIII.

5. HUMERO-CUBITAL ARTICULATION, OR THE ELBOW-JOINT.

Fig. 144.*

IN this, which, as far as the humerus and ulna are concerned, is one of the most perfect ginglymoid articulations, the opposed extremities of the humerus, ulna, and radius, mutually receive each other, and are attached together by an external and internal lateral and by an anterior and posterior ligament. All these ligaments are so closely connected to the surrounding muscles as to be with difficulty separated: there is no distinct capsular ligament, although the aggregate of these might be considered as such.

The *external lateral ligament* is short and flat; *arises* narrow from the external condyle, and is *inserted* broad into the posterior and external part of the annular ligament of the radius. This ligament is confounded with the tendons of the supinator brevis and with those of the extensor muscles.

The *internal lateral arises* narrow from the inner condyle, and is *inserted* in a radiated man-

* An external view of the elbow-joint. 1. The external condyle of the humerus. 2. The ulna. 3. The radius. 4. The olecranon. 5. The anterior ligament. 6. The external lateral ligament. 7. The annular ligament. 8. The *cul de sac* formed by the synovial membrane of the articulation between the radius and the annular ligament.

ner into the inner margin of the great sigmoid cavity of the ulna, between the coronoid and olecranon processes. It is longer and broader than the external, is somewhat triangular, and divides inferiorly into several fasciculi, the anterior of which extend to the coronoid process, and are confounded with the common tendinous origin of the flexor muscles of the forearm; the posterior are inserted into the olecranon process, and are covered by the ulnar nerve, and connected to the adjacent muscles. This ligament adheres to the synovial membrane. The lateral ligaments steady and strengthen this articulation; they also in some measure restrain its motions; the anterior portion of each, particularly of the internal, being tense in extension, the posterior in flexion of the joints. A distinct band of fibres extends from the anterior to the posterior part of the insertion of the internal lateral ligament, or from the coronoid to the olecranon process. In fracture of the latter, the broken piece is often retained in its situation, according to Sir A. Cooper, by this ligament.

Fig. 145.*

The *anterior ligament* consists of thin fibres, which take an irregular direction over the forepart of the joint, some vertically, others obliquely and transversely. They *arise* chiefly from above the internal condyle and the coronoid depression, on the fore-part of the humerus. They thence spread over the synovial membrane and some reddish, fatty matter, which is behind the brachiæus anticus. Some are *inserted* into the annular ligament of the radius, others into the coronoid process, and the remainder are lost on the synovial membrane.

The *posterior ligament* is not so distinct as the anterior, unless the fore-arm be flexed. The fibres chiefly extend in a transverse direction from one condyle and one lateral ligament to the other; they are attached to the synovial membrane, and covered by the triceps and anconæus.

The *synovial membrane* is common to the humero-cubital and cubito-radial articulations. This membrane descends from the forepart of the humerus, behind the anterior ligament and a quantity of reddish, fatty matter which intervenes, to the neck of the radius and annular ligament. Around the former it forms a *cul de sac*, is prolonged into the two sigmoid cavities of the ulna, and thence is

* An internal view of the humero-cubital articulation or elbow-joint. 1. The internal condyle of the humerus. 2. The internal surface of the ulna. 3. Its olecranon process. 4. The radius. 5. Its tubercle. 6. The anterior ligament of the elbow-joint. 7. The internal lateral ligament. 8. The annular ligament. 9. The oblique ligament. 10. The interosseous ligament.

reflected to the lateral ligaments and to the triceps tendon, which leads it to the posterior depression on the humerus; it is then expanded over the articular eminences on the lower end of this bone; it is looser before, and still more so behind, than on the sides, and is also thicker in the former situations than in the latter.

The trochlear form of the articular ends of the humerus and ulna constitute this a very perfect hinge-joint, in which flexion and extension can be freely and safely performed. Extension is complete when the arm and forearm are brought into a straight line; the olecranon is then in contact with the humerus, and prevents it being carried further. Flexion can take place to a greater degree, even until the coronoid process strikes the humerus, or until resisted by the intervening soft parts; in flexion the fore-arm inclines inwards towards the chest and head, in consequence of the oblique direction of the trochlea from behind, and from without forwards and inwards. In these motions the radius may be considered as part of the same system as the ulna, both moving as one bone.

SECTION XIV.

RADIO-ULNAR ARTICULATIONS.

THESE are two, a superior and an inferior; they are both of the arthrodial class. The shafts of the two bones are also connected by the interosseous ligament. In the *superior* the head of the radius is received into the lesser sigmoid cavity of the ulna, and is retained in it by the following ligament.

The *annular ligament* forms about three-fourths of a circle, the lesser sigmoid depression in the ulna completing it, and is nearly a quarter of an inch deep. It *arises* from the anterior, and is *inserted* into the posterior border of the lesser sigmoid cavity of the ulna. The external lateral ligament of the elbow-joint is inserted into its posterior part, and adds to its thickness in that situation; some fibres of the anterior ligament also are attached to it in front. These attachments serve to retain or suspend it around the head of the radius; accordingly, when they are divided, it falls down round the neck of the radius. Its circumference is wider above than below, whereby

Fig. 146.*

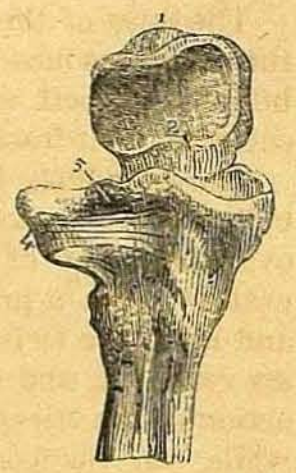

* The superior extremity of the right ulna, with the annular ligament of the superior radio-ulnar articulation. 1. The olecranon process. 2. The great sigmoid cavity. 3. The coronoid process. 4. The annular ligament. 5. The lesser sigmoid cavity.

it exerts some constricting effect upon this bone. This ligament is lined by the synovial membrane of the joint; it encircles the head and neck of the radius in the same manner as the transverse ligament of the atlas confines the odontoid process of the axis. It often presents a cartilaginous structure.

The *oblique ligament* is a small, round, fibrous cord, weak and variable (fig. 145); *arises* from the root of the coronoid process of the ulna, descends obliquely outwards, and is *inserted* into the inner side of the radius below its tubercle. It is on a plane anterior to the interosseous ligament, and in a contrary direction to its fibres. It separates the flexor digitorum sublimis from the supinator radii brevis muscle; it is made tense in supination.

The most frequent dislocation of the elbow-joint is that of both radius and ulna backwards. This accident is sometimes complicated with a fracture of the coronoid process. The relation of the articulating surfaces in the semiflexed position of the arm is such, that if external violence be applied, the coronoid process slips behind the articular pulley of the humerus, and is lodged in the olecranal fossa, while the humerus is thrown forwards on the radius and ulna. The external, internal, and sometimes the annular ligament of the radius, are ruptured, though the accident may occur without injury to any of these parts. Occasionally even the biceps and brachialis internus suffer from the violent projection of the humerus, and the brachial artery has been known to have been ruptured from the same cause. The flexor muscles of the arm, by keeping it bent, and the triceps by its contraction, are the muscles which oppose reduction. The internal condyle of the humerus and the olecranon present two prominent points, which are of great importance in assisting us to detect injuries about the elbow-joint. In the extended position of the arm they are nearly on the same line, and any displacement of the bones will alter the relation of these two prominences.

The form of the bones, the strength of the lateral ligaments, and the numerous muscles surrounding the joint, prevent a complete lateral luxation of both ulna and radius, while a luxation forwards cannot occur without fracture of the olecranon.

The ulna may be dislocated backwards on the os humeri without being accompanied by the radius. The coronoid process is forced over the pulley of the humerus into the posterior fossa, and the olecranon forms a prominent projection at the back part; the forearm and hand are twisted inwards. The annular and oblique ligaments are ruptured, and sometimes a small portion of the interosseous. The action of the triceps will contribute to keep the bone in this position; while, on the contrary, the brachialis internus assists in the reduction.

The radius may be dislocated at its humeral extremity either backwards or forwards; when forced through the back part of the capsular ligament, the result of excessive pronation, it is found to rest above the external condyle of the humerus, supported by the brachial

fascia. The oblique and annular ligaments are torn, and sometimes the superior fibres of the interosseous ligament.

In dislocation of the radius forwards, which seldom occurs, the head of the bone rests above the external condyle of the os humeri, and resists sudden flexion. The oblique and annular ligaments, with a portion of the interosseous ligament, are ruptured in this luxation, as in the former. The biceps muscle becomes shorter by contraction, and thus may resist, though not in any great degree, reduction.

The opposed edges of the shafts of both radius and ulna are connected by a thin aponeurosis, the *interosseal membrane* or *ligament.* It is composed of long fibres, which descend obliquely inwards from the radius to the ulna, others occasionally cross it in a contrary direction; it is wider in the centre than at either end; is deficient above and below, and in many places is perforated by vessels, inferiorly for the anterior interosseous; the posterior pass through an opening at its upper margin, between it and the oblique ligament. It is not made very tense in any position of the limb; it serves to give attachment to muscles.

In the *inferior radio-ulnar articulation*, contrary to the superior, the round head of the ulna is received into the sigmoid cavity of the radius, and retained in it by a loose *synovial membrane*, or the *sacciform ligament*, which is covered before and behind by some ligamentous fibres, forming an imperfect capsule, and passing from the radius to the ulna. This loose sac is above the interarticular fibro-cartilage, and always contains a large quantity of synovia. It is strengthened by *anterior* and *posterior ligaments*, which are thin and membraneous, and pass transversely from the anterior and posterior margins of the sigmoid cavity of the radius to the front and back of the lower end of the ulna and of its styloid process. These can scarcely be considered as true ligaments, but rather as a part of the sacciform capsule.

The *fibro-cartilage* is triangular. It *arises* narrow from the styloid process of the ulna, and is *inserted* broad into the inner edge of the carpal end of the radius, below the depression for the ulna, which bone it separates from the wrist-joint, and from the cuneiform bone. Its anterior and posterior edges are thick, and connected to the ligamentous fibres that pass from the ulna to the radius; its base and centre are thin, and sometimes perforated: then the wrist-joint and this articulation will communicate. This cartilage appears to be a prolongation of the encrusting cartilage of the lower end of the radius; it serves to unite the radius and ulna very securely, while at the same time it allows the former to roll round the latter, as on a pivot; this cartilage also completes the upper part of the ulnar side of the carpal articulation; it is, therefore, both a ligament and an interarticular cartilage. Both the superior and inferior radio-ulnar joints are arthrodial, and the radius enjoys free rotatory motion in each. This rotation is named pronation, when the radius turns over in front of the ulna, and the palm of the hand is directed downwards: the oppo-

site is termed supination. In pronation the head of the radius rolls upon its own axis in the lesser sigmoid cavity of the ulna, its outer border coming forwards, and its inner passing backwards, while the lower end of the radius rolls round the head of the ulna by circumduction, forming an arch of a circle, the centre of which is the ulna, and the arch is the space through which the styloid process of the radius moves. In pronation the latter turns forwards, and in supination backwards; in the former the shaft of the radius crosses in front of that of the ulna, and the interosseous membrane is made somewhat tense; in the latter the two bones become parallel, and the membrane is relaxed.

The carpal extremity of the radius may be dislocated either forwards or backwards. In the first of these accidents this bone is thrown forwards on the scaphoid and os trapezium. The capsular and anterior ligaments alone are ruptured. In the dislocation backwards, the back part of the capsule, the posterior, and sometimes the external lateral ligaments, are ruptured. The bone projects under the skin at the back of the wrist.

The carpal extremity of the ulna may be dislocated forwards or backwards, the latter is more frequent; the accident is obvious, and the dislocation is easily reduced, but there is much difficulty in keeping the bone in its place in consequence of the rupture of the sacciform ligament.

SECTION XV.

6. RADIO-CARPAL ARTICULATIONS, OR THE WRIST-JOINT.

In this ginglymoid arthrodial joint, which is of great transverse extent, the lower end of the radius and the interarticular cartilage form a socket for the scaphoid, lunar, and cuneiform bones; the two former are received into the radius, the latter corresponds to the fibro-cartilage, which separates it from the ulna, and excludes this bone from the joint. The wrist-joint is secured by an external and internal lateral, by a posterior and anterior ligament, and by a synovial membrane.

The *external lateral*, or *radio-carpal ligament*, *arises* from the styloid process of the radius, and is *inserted* into the scaphoid bone. Some fibres extend to the annular ligament and to the os trapezium. The radial vessels cross this ligament.

The *internal lateral*, or *ulna-carpal ligament*, is round and long; *arises* from the styloid process of the ulna, extends obliquely downwards and forwards, and is *inserted* into the cuneiform and pisiform bones.

The *anterior* and *posterior ligaments* descend from the radius and

interarticular cartilage anteriorly and posteriorly, and are *inserted* into the superior row of the carpus. The anterior is strong and tense, the posterior is weaker and looser; its fibres, however, are more distinct; the former is covered by the flexor, the latter by the extensor tendons. These two ligaments, together with the two lateral, may be regarded, and have been described by some, as the capsular ligament.

Fig. 147.*

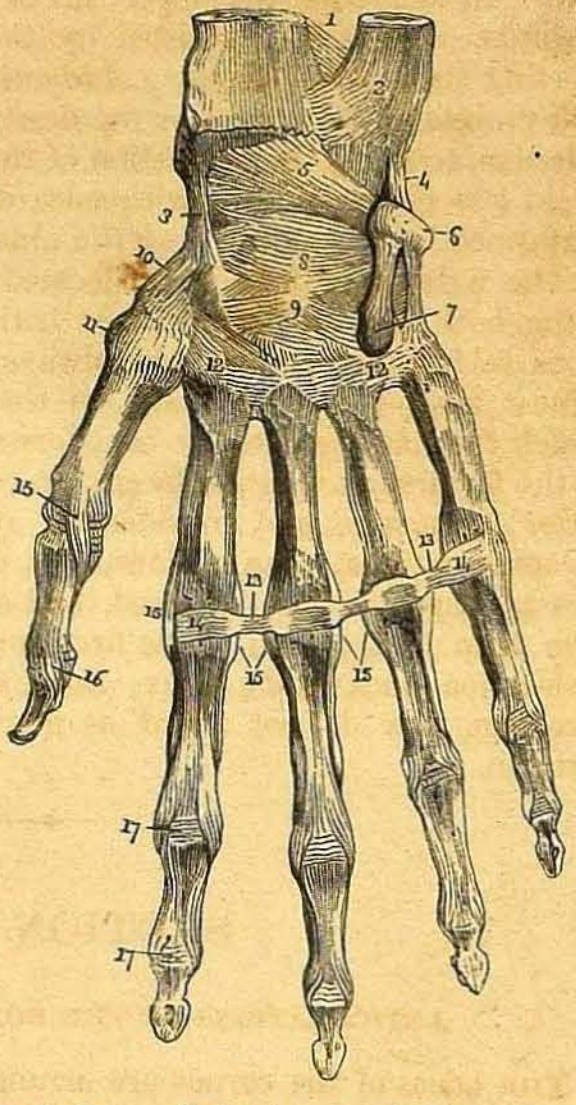

The *synovial membrane* covers the superior row of the carpal bones, is thence reflected to line the ligaments, and is continued over the articular surface of the radius and of the interarticular cartilage. It is very loose, and contains much synovia. When the bones are pressed together, the membrane may be seen projecting through the ligamentous covering, like small vesicles; it sometimes communicates with the radio-ulnar synovial membrane through the interarticular cartilage.

The *carpal articulation* enjoys four motions, flexion, extension, abduction, and adduction, also a slight degree of circumduction. In *flexion* the upper row of the carpus glides backwards in the cavity, and the hand is directed forwards. In *extension* the former rolls forwards, and the latter is brought into a straight line with the forearm,

* An anterior view of the ligaments of the wrist and hand. 1. The lower part of the interosseous membrane. 2. The anterior inferior radio-ulnar ligament. 3. The external lateral ligament of the wrist-joint. 4. The internal lateral ligament. 5. The anterior ligament of the wrist-joint. 6. The pisiform bone and its ligaments, connecting it to the unciform bone, and to the fifth metacarpal bone. 7. The hook-like process of the unciform bone. 8. The palmar ligaments connecting the first row of carpal bones. 9. The palmar ligaments connecting the second row of bones. 10. The external lateral ligament of the articulation between these two rows of carpal bones. 11. The capsular ligament of the first carpo-metacarpal articulation. 12. 12. The palmar carpo-metacarpal ligaments. 13. 13. The transverse ligaments connecting the heads of the metacarpal bones together. 14. 14. The anterior ligament of the metacarpo-phalangeal articulation. 15. 15. The lateral ligaments of the same articulation. 16. The anterior and external lateral ligament of the phalangeal articulation of the thumb. 17. 17. The anterior and lateral ligaments of the index finger; the same are seen upon the other fingers.

and can even be carried backwards, so as to form nearly a right angle with the forearm. This might be termed flexion backwards, and is much more extensive than true flexion, in consequence of the articular surfaces of the carpal bones being prolonged further behind than before. In *abduction* the upper end of the carpus moves transversely inwards, and is soon resisted by the styloid process of the radius meeting the scaphoid bone. *Adduction* is less restricted, as the styloid process of the ulna does not descend so low as that of the radius. *Circumduction* is the succession of these several motions, but is rendered less necessary in consequence of the pronation and supination performed by the radius upon the ulna.

The wrist-joint may be dislocated either by the radius and ulna being both thrown forwards, or both backwards. Lateral dislocations seldom occur, and are always partial. These displacements almost always occur by falls on the ground, or other violence, by which the hand is forcibly bent forwards or backwards on the bones of the forearm; extensive laceration of the capsular, anterior, or posterior ligaments, and considerable synovial effusion and swelling, accompany them. The tendons, also, of the flexor and extensor muscles are more or less displaced, and some of them may be ruptured. The form of the arch of the first range of carpal bones favours the dislocation backwards, since, from their greater convexity in this direction, they do not afford as much support to the bones of the forearm.

SECTION XVI.

ARTICULATIONS OF THE BONES OF THE CARPUS.

THE bones of the carpus are arranged in two rows; three in the superior, in front of which is the pisiform bone; and four in the inferior. Between these rows a certain degree of motion takes place, but between the individual bones in each row there is little or none, except the head of the os magnum and its socket, which is an arthrodial joint; all the others are arthrodial and amphiarthrodial. The proper bones of the first row are the scaphoid, lunar, and cuneiform. These are connected in the following manner:

First. *Interosseous ligaments.*—These are short, compact, and dense tissues, placed between the upper borders of the scaphoid and lunar, and lunar and cuneiform; they range on a level with the carpal convexity of these bones, and are covered by the synovial membrane of the carpus.

Second and third. The *dorsal* and *palmar ligaments* are composed of strong bands, which pass in different directions from one to another. The palmar are stronger and tighter than the dorsal (fig. 147).

The pisiform bone, which is the smallest bone of the carpus, does

not properly belong to either row; it is articulated to the forepart of the cuneiform only by a flat surface, which is furnished with a loose synovial membrane. Two strong ligaments also connect it, one to the cuneiform bone, and the other to the fifth metacarpal bone. The tendon of the flexor carpi ulnaris and the muscles of the little finger also serve to retain it in its situation, and to attach it to the annular ligament and palmar fascia.

The four bones of the second row of the carpus, like those of the first, are connected together by interosseous substance and by dor-

Fig. 148.*

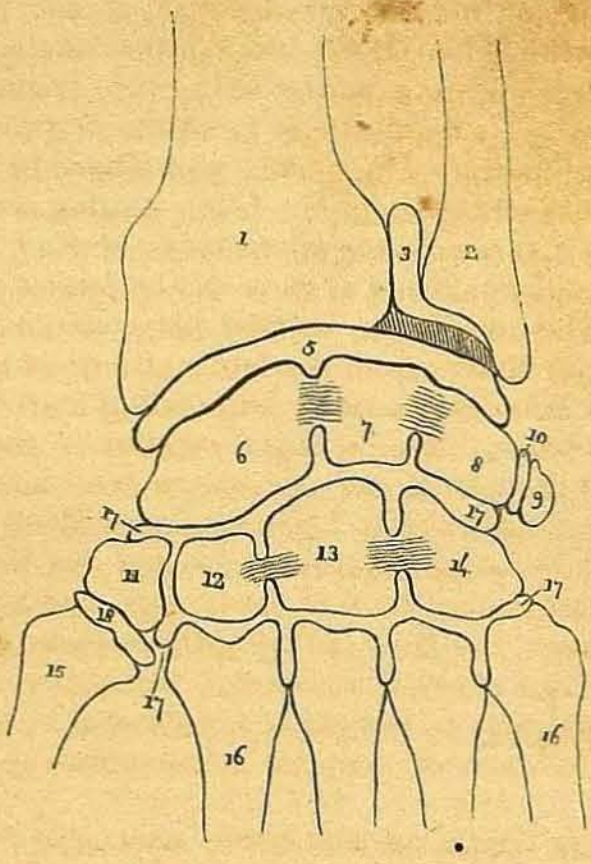

sal and palmar bands, which run in every direction. There is no interosseous substance between the trapezium and trapezoid. The

* A diagram representing the lower extremities of the radius and ulna, the bones of the carpus, the superior extremities of the metacarpal bones, and the disposition of the synovial membranes which separate them. 1. The lower extremity of the radius. 2. The lower extremity of the ulna. 3. The sacciform membrane. 4. The interarticular fibro-cartilage. 5. The synovial membrane of the radio-carpal articulation, or wrist-joint. 6. The scaphoid bone. 7. The lunar bone. 8. The cuneiform. 9. The pisiform. 10. A distinct synovial membrane between the pisiform and cuneiform bones. 11. The trapezium. 12. The trapezoid. 13. The os magnum. 14. The unciform. 15. The superior extremity of the metacarpal bone of the thumb. 16. 16. The superior extremities of the other metacarpal bones. 17. 17. The large synovial membrane which lines nearly all the joints of the carpus; it is separated from the synovial membrane of the wrist-joint by the two interosseous ligaments connecting the scaphoid, lunar, and cuneiform bones. 18. A distinct synovial membrane between the trapezium and metacarpal bone of the thumb. Five separate synovial membranes are thus exhibited in the above diagram, and numbered 3, 5, 10, 17, and 18.

second row is articulated to the first by an enarthrosis in the centre and an arthrodia at either side; the central joint is between the round head of the magnum and the cavity of the scaphoid and lunar bones; the lateral arthrodiæ are between the scaphoid and cuneiform bones above, and the trapezium, the trapezoid, and unciform below. These two rows are attached by strong lateral and by anterior and posterior ligaments; the former seem continuations of the lateral ligaments of the wrist, the latter pass from the circumference of one row to that of the other; the aggregate might be considered as a capsular ligament.

The *synovial membrane* between the first and second row is very loose and distinct, and may be considered as common to almost all the joints of the carpus; it lines the inferior surface of the upper row, and sends two processes upwards, one at either side of the lunar bone as high as the interosseous ligaments. From the first row it is reflected on the anterior and posterior ligaments, and thence to the second row, and is very distinct on the magnum, being continued round its neck; it also sends down three prolongations between the four bones of the second row; the most external of these is continuous with the carpo-metacarpal synovial membrane, or that between the second row and the four metacarpal bones: from the latter also there are four prolongations extended between the latter articulating surfaces on the heads of the metacarpal bones. This synovial membrane, therefore, is common to almost all the carpal and metacarpal articulations; there are, however, some excepted; thus between the pisiform and unciform there is a distinct synovial membrane, another also between the trapezium and the metacarpal bone of the thumb, and sometimes also a distinct one between the third and fourth metacarpal bones. The continuity of this one synovial membrane through so many articulations, and its contiguity to the other membranes in this region, are well exemplified in cases of synovial inflammation or disease of the carpus.

The bones of the carpus are also firmly connected to each other by the *annular ligament*, which is a strong and compound fibrous structure; *inserted* externally into the trapezium and scaphoid, and internally into the cuneiform, unciform, and base of the pisiform bones; it preserves the arched form of the carpus, and completes the ring for the passage of the flexor tendons, median nerve, and carpal bursa.

Although the carpus consists of so many joints, yet it enjoys but little motion in any of these, and the principal use of this complex structure is to effect security or strength, to allow of slight yielding, and, above all, to lessen the effects of concussion, which is broken or scattered by so many articulations. There is no appreciable motion between the individual bones in each row, but the lower row can move beneath the upper in consequence of the enarthrosis of the magnum and the arthrodiæ on either side of it. This motion is either forwards or backwards; the former or flexion is more obvious than the latter.

The close connexion of the bones of the carpus, and the numerous ligaments spread in all directions over the back and front of the hand, present powerful obstacles to complete dislocations of any of these bones. The only one at all likely to occur is that of the head of the os magnum backwards from the depression in the semilunar and scaphoid bones. Here the quantity of motion is greatest, and the joint is very weak and loose in some feeble persons; however, this luxation is generally incomplete.

SECTION XVII.

THE ARTICULATIONS BETWEEN THE CARPUS AND METACARPUS.

The five metacarpal bones present two series of articulations, the posterior or carpo-metacarpal, and the anterior or metacarpo-phalangeal. In the carpo-metacarpal series the carpal ends of the four internal metacarpal are joined to the lower row of the carpus, by nearly plane surfaces, and are secured before and behind by transverse and oblique fibrous bands, which cover the synovial membranes, and pass in different directions, and are named *dorsal*, *palmar*, and *interosseous*. The synovial membrane, between the trapezium and the metacarpal bone of the thumb, is distinct from the rest, and this joint possesses a *capsular ligament*, the pulley-like surfaces of the bones admitting of very free motion, adduction, abduction, flexion, extension, and slight rotation. The other carpo-metacarpal joints are also furnished with synovial membranes, which are prolonged from that between the first and the second row of the carpus, except in the case of the third and fourth, which sometimes possess a distinct sac. The second metacarpal bone is articulated to the trapezium, trapezoid, magnum, and to the third metacarpal bone; the third to the magnum and to the second and fourth metacarpal bones; the fourth to the magnum, unciform, and to the third and fifth metacarpal bones; the fifth to the unciform and to the fourth metacarpal bone. In these articulations there is very little motion beyond a mere yielding between the surfaces, except in that between the trapezium and first metacarpal bone, where free and varied motion is permitted. Between the fifth and the unciform bone, also, considerable motion can occur, flexion, extension, abduction, and adduction, but no rotation. The anterior or digital extremities of the metacarpal bones are not in contact, but are connected together by a strong transverse band of ligamentous fibres.

The dislocations of the metacarpal bones from the carpus seldom occur, except in the case of the first metacarpal bone, which may be dislocated from its articulation with the trapezium forwards or backwards. In the backward luxation the carpal extremity of the bone is driven through the posterior part of the capsular ligament. The lateral ligaments may or may not be ruptured. The flexor ossis metacarpi and

flexor brevis and longus, with the adductor, offer great resistance to reduction when delayed for any time. In the dislocation forwards the metacarpal bone is thrown between the trapezium and the root of the second metacarpal bone; the thumb is bent back, and cannot be flexed: the external lateral ligament is in this case more likely to be torn than in the former. The extensors of the thumb are the muscles which offer resistance to reduction of this dislocation.

SECTION XVIII.

ARTICULATIONS BETWEEN THE METACARPUS AND THE PHALANGES.

THESE arthrodial joints are furnished with capsular ligaments and synovial membranes. The sockets do not receive the entire head of each bone, the latter being much larger, particularly on their posterior aspect. The *capsules* are weak and lax behind, strong on the sides, like distinct lateral ligaments, and very close and compact in front, often with somewhat of a cartilaginous structure. In the thumb this ligament lodges the sesamoid tubercles; in this finger also this articulation differs from that in the other fingers, in possessing but little motion in any direction except that of flexion and extension, whereas the others possess also the power of adduction, abduction, and slight rotation. These articulations are much strengthened by the tendons of the flexors, extensors, lumbricales, and interossei muscles; the four internal are also secured by strong *transverse* ligaments passing from one to the other.

The first phalanx of the thumb is the only joint of this series very liable to dislocation; it is frequently dislocated backwards from the head of the metacarpal bone. The lateral ligaments remain uninjured, and become very tense. This dislocation is interesting from the great difficulty of reducing it when neglected even for a short time. The phalanges of the other fingers may be dislocated either backwards or forwards; these accidents are obvious, and, when recent, easily admit of reduction.

The ginglymoid articulations of the phalanges are secured by *synovial membranes* and by very strong *lateral* and *anterior ligaments.* Posteriorly the synovial membranes are only partially covered by the extensor tendons; but anteriorly they are perfectly protected by the flexor tendons and their sheaths.

SECTION XIX.

ARTICULATION BETWEEN THE PELVIS AND THE SPINE.—LIGAMENTS OF THE PELVIS.

The last lumbar vertebra is joined to the sacrum in the same manner as the other vertebræ are joined to each other by an intervertebral, anterior and posterior, yellow, supra and interspinous, synovial membranes, and capsular ligaments. The intervertebral ligament is remarkably thick, particularly in front. This connexion is also strengthened by the *lumbo-sacral ligament*, a strong, short, thick,

Fig. 149.*

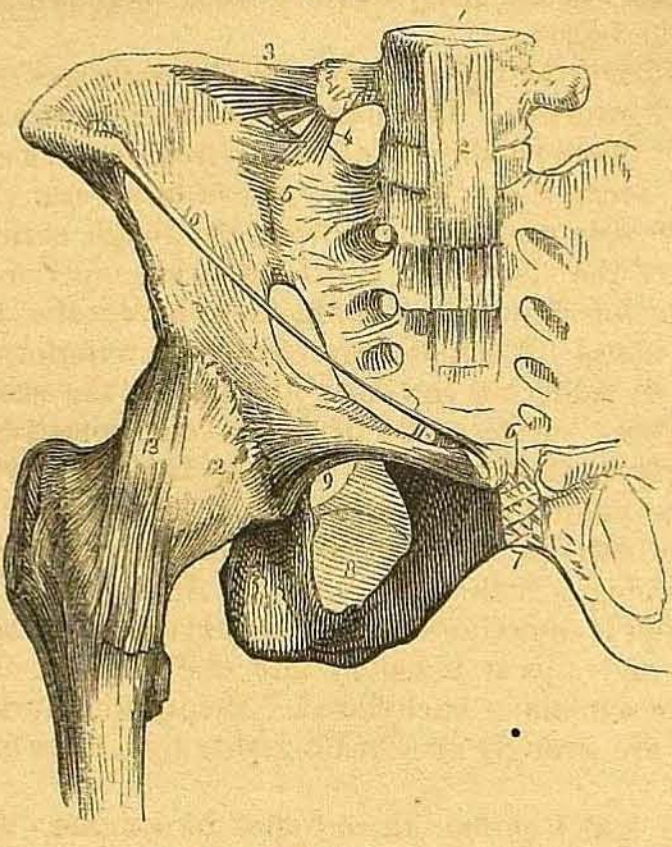

fibrous band, extending from the transverse process of the last lumbar vertebra to the posterior part of the base of the sacrum, where it is continuous with the ligaments of the sacro-iliac synchondrosis.

The two last lumbar vertebræ are connected to the ilium by the *ilio-lumbar ligament*. This is of a triangular form, and sometimes

* An anterior view of the ligaments of the pelvis and of the hip-joint. 1. The last lumbar vertebra. 2. The lower part of the anterior common vertebral ligament, extending downwards over the front of the sacrum. 3. The ilio-lumbar ligament. 4. The lumbo-sacral or sacro-vertebral ligament. 5. The anterior sacro-iliac ligaments. 6. The anterior pubic ligament. 7. The inferior pubic or sub-pubic ligament. 8. The obturator ligament or membrane. 9. The opening in the obturator ligament for the passage of the obturator vessels and nerve. 10. Poupart's ligament. 11. Gimbernaut's ligament. 12. The capsular ligament of the hip-joint. 13. The ilio-femoral or accessory ligament.

divided into two; it *arises* from the transverse processes of the fifth and fourth lumbar vertebræ and from the back part of the sacrum, proceeds horizontally outwards, and is *inserted* into the posterior superior spine of the ilium and into the crest of this bone, in front of that process.

The several bones of the pelvis are connected together by syndesmosis and synchondrosis; they present no perfect or true joints, but belong to the class of amphiarthrosis. The pelvic articulations are the sacro-coccygeal, sacro-iliac, sacro-sciatic, and pubic.

The sacrum and coccyx are joined by a thin *anterior* and a thick *posterior sacro-coccygean ligament;* also by a thin, intervertebral *fibro-cartilage*, which latter is very variable. It is usually more perfect, and allows of more motion backwards and forwards, in the female than in the male; occasionally in the former there is a small synovial sac between the bones.

The sacro-iliac articulation, or synchondrosis, is secured by anterior and posterior ligaments. The *anterior sacro-iliac ligament* is thin, and consists of fibres passing transversely from one bone to the other. The *posterior sacro-iliac ligament* consists of several thick fasciculi passing transversely and obliquely from the rough surface of the sacrum to that of the ilium and to its posterior superior spine. The *sacro-iliac synchondrosis*, or *symphysis*, connects the auricular surfaces of these bones. Each is covered in this anterior portion by a lamina of closely adhering cartilage, thicker on the sacrum than on the ilium. These surfaces are irregular, and sometimes present a lubricated surface, as if furnished with an imperfect synovial membrane. In the child this connexion is looser, also in the pregnant female; and in both cases a synovial membrane is more distinctly developed, containing a little reddish fluid. In the adult male a soft, yellowish matter is sometimes found to intervene, and the surfaces are very uneven, and appear indented into one another. In the aged these bones are sometimes anchylosed. Behind the auricular surface the two bones are strongly attached together by a mass of interosseous fibres.

The sacrum and ischium, though not in contact, are connected together on either side by the two following very strong and important ligaments.

The *posterior* or *great sacro-sciatic ligament* arises broad from the lower and back part of the posterior inferior spine of the ilium and from the back part of the sacrum and coccyx; descends obliquely outwards, becomes narrow and thick, and is *inserted* again broad into the lower and inner edge of the tuber ischii, and by a falciform process continued forwards into the ramus of the ischium, to which the obturator fascia is attached, and which serves to conduct, support, and protect the internal pudic vessels and nerves. It is covered posteriorly by the glutæus maximus, some fibres of which arise from it; it is perforated by small vessels, and rests upon the anterior sacro-sciatic ligament. By its upper border it converts the lesser sciatic

notch into a foramen, and by its lower it completes the posterior and lateral boundary of the lower or perinæal opening of the pelvis on each side.

The *anterior* or *lesser sacro-sciatic ligament* crosses in front of the former; is triangular, and very thin; *arises* broad from the side of the sacrum and coccyx, passes outwards, and is *inserted* narrow into the spine of the ischium. Its origin is intermingled with the fibres of the former, which are behind it; its anterior or pelvic surface is covered by the coccygeus muscle; it separates the two sciatic foramina. These four ligaments are situated at the lower and back part of the pelvis; they serve to attach the sacrum and ossa coccygis to the ossa innominata; they also assist in forming the parietes of the pelvis, and by

Fig. 150.*

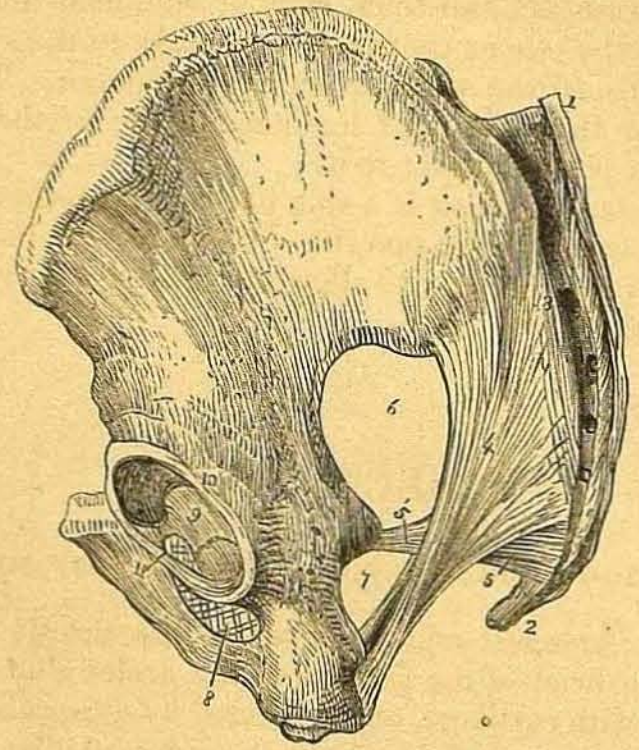

their decussation they constitute the two openings on each side known by the names of the greater and lesser sacro-sciatic notches, the larger and superior of which transmits the glutæal nerves and vessels, the pyriform muscle, and the sciatic and pudic nerves and vessels; the inferior or lesser transmits the internal obturator tendon and the internal pudic vessels and nerves.

Pubic symphysis connects the vertically oval surfaces of the ossa

* A lateral view of the ligaments of the pelvis and hip-joint. 1. The lower part of the supraspinous ligament of the vertebræ descending over the median tubercles on the back of the sacrum. 2. The posterior sacro-coccygean ligament. 3. The sacro-spinous or oblique sacro-iliac ligament. 4. The posterior or great sacro-sciatic ligament. 5. The anterior or lesser sacro-sciatic ligament. 6. The great sacro-sciatic foramen. 7. The lesser sacro-sciatic foramen. 8. The obturator ligament. 9. The cotyloid cavity or acetabulum. 10. The cotyloid ligament. 11. The transverse ligament which converts the inferior notch of the acetabulum into a foramen.

pubis, which are covered by cartilage and by a fibro-cartilage analogous to the intervertebral. It consists of several concentric laminæ; some of these are oblique, and intersect others; some are continued all round; others are deficient behind; and they are all thicker above and before than below and behind. In the centre there is often a pulp, or a viscid fluid; and sometimes a small and imperfect synovial membrane and cavity intervenes between the bones posteriorly. The symphysis is covered in front by a thick, laminated, and fibrous tissue (anterior pubic ligament), the fasciculi of which run in different and decussating courses. Superiorly and posteriorly, in like manner, it is strengthened by ligamentous fasciculi (*superior* and *posterior pubic ligaments*). The posterior is thin, and often rendered very convex towards the pelvis by the prominence of the edges of the bones in that direction. Beneath the symphysis is the *subpubic ligament*, which consists of a compact and thick band of semilunar fibres passing from one ramus to the other; connected superiorly to the symphysis; inferiorly it rounds off the angle or arch of the pubes. The interosseous membrane, or the triangular ligament of the urethra, is inferior to this, and on a plane anterior to it.

The *obturator ligament* is a thin fibrous membrane, but not a true ligament, adhering to the margin of the obturator hole, except superiorly, where it is deficient, to allow the obturator nerve and vessels to pass out obliquely.

SECTION XX.

ILIO-FEMORAL ARTICULATION, OR HIP-JOINT.

THIS is the strongest and most perfect enarthrosis in the system; it includes the head of the femur and the acetabulum, both of which are encrusted with cartilage, and is secured by a capsular and an accessory ligament, a synovial membrane, an interarticular, cotyloid, and a transverse ligament. The cartilage on the head of the femur is thickest on its most convex portion, but is deficient a little below its centre, where there is a depression for the insertion of the interarticular ligament. On the surface of the acetabulum it is thicker towards the circumference, and is altogether absent in a considerable space extending from the notch to the centre. The former lodges the origin of the interarticular ligament, the latter a mass of articular fat and several blood-vessels.

The *ilio-femoral capsular ligament* (fig. 149) is the strongest in the body; is analogous to that of the shoulder-joint, but not so loose, neither are the surrounding tendons so identified with it. There is a large bursa on its anterior surface, between it and the tendon of the psoas; in some rare cases this communicates with the cavity of the joint. Another bursa is placed more externally between the great

trochanter and the glutæus maximus: there are also several others connected to the surrounding tendons. It *arises* from the os innominatum by a very strong attachment, which extends from half an inch to an inch and a half beyond the brim of the cavity; anteriorly from the inferior spine of the ilium, from the body of this bone, and from the ilio-pubal eminence; superiorly or externally from the ilium, extending to some distance above the prominent border of the acetabulum; posteriorly as far upwards as to a line leading from the outer part of the ilium to the spine of the ischium; inferiorly from the ischium, external to its tuberosity; internally from the outer border of the thyroid foramen, and from the cotyloid and transverse ligament of the notch. The fibres form a dense and compact tissue, strong, tough, inelastic, and unyielding. The superficial fibres have mostly an obliquely vertical course, but the deeper interlace in every direction. The capsule passes downwards and outwards, encloses the cotyloid ligament, but does not adhere to it except at the notch; enlarges opposite the head of the femur, then becomes flattened and contracted to embrace the cervix, the greater part but not the whole of which it encloses. It is *inserted* superiorly and externally into the root of the neck, internal to the digital fossa of the great trochanter; anteriorly into the anterior intertrochanteric ridge and into the forepart of the neck above this line; internally and inferiorly it descends near to the root of the lesser trochanter, and is inserted into the rough surface above it; posteriorly it does not descend so low as in front, and is inserted into the neck about a quarter of an inch above the posterior intertrochanteric ridge. These insertions are partly into the bone, and are partly prolonged into the periosteum both inferiorly and superiorly. In the latter direction several distinct fibrous cords are observable, on the anterior and inferior surface particularly, passing upwards in the periosteum, beneath the synovial membrane. These cords are variable, and in some instances are very much developed;

Fig. 151.*

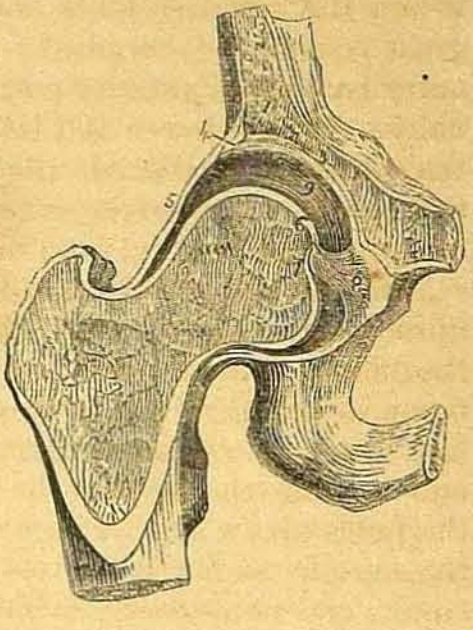

* Ilio-femoral articulation. In this view a vertical section has been carried through the hip-joint, and the head of the femur drawn out of the acetabulum, in order to shew the relation of the various structures of the articulation. 1. A vertical section of the os ilium, passing through the cotyloid cavity or acetabulum. 2. A vertical section passing through the head, neck, and great trochanter of the femur. 3. A section of the acetabulum and its cartilage of incrustation. 4. A section of the cotyloid ligament. 5. The capsular ligament. 6. A section of the cartilage of incrustation on the head of the femur. 7. The insertion of the interarticular ligament, or ligamentum teres, into the head of the femur. 8. The ligamentum teres. 9. The cavity of the synovial membrane.

they have been named *retinacula*. The capsule extends further down in front than behind, and is stronger above and before than in other situations; it is tense on all sides, except internally and inferiorly, where it is rather loose, and thereby admits of the more easy abduction of the thigh. It presents very different degrees of strength and thickness in different parts, these properties being imparted to it where the greatest force and pressure are to be applied, and where great resistance is required; thus it is very thick above, also in the outer part of its anterior portion, and is thinner posteriorly and internally. At the lower and internal part it is so thin in children, and the fibres so scattered, that the synovial membrane can be seen through it. It derives considerable increase in strength from the adjacent tendons, and from accessory bands, particularly the following.

Accessory or *ilio-femoral* ligament (fig. 149) is a strong and thick fibrous band, incorporated with the capsular, *arising* from and around the inferior spinous process of the ilium; it descends obliquely inwards, becomes broader, and is *inserted* into the anterior intertrochanteric line, near to the lesser trochanter; it strengthens the capsule anteriorly, and opposes the head of the femur in extension of the thigh. From the pubis also a smaller accessory band descends on the inner side of the capsule, as far as the root of the lesser trochanter; between these bands, and immediately behind the psoas and iliac muscles, the forepart of the capsule is thin, and occasionally presents a round foramen, which leads into the bursa, placed between it and these tendons. The capsule and the articulation generally derive most important additional security from the surrounding muscles and tendons; anteriorly from the psoas and iliac, externally and superiorly from the rectus, particularly its long outer head, which, arising from the dorsum of the acetabulum, bends around its upper to its forepart; externally or superiorly the glutæus minimus, also, adheres closely to the capsule; posteriorly the quadratus femoris, pyriformis, gemini and obturator internus, and internally the obturator externus and pectinæus.

The *synovial membrane* is exposed by dividing the capsular ligament, whose internal surface it lines to a great extent; it is continued from the head of the femur around the neck near to its base, but not so far as the fibrous capsule; on the neck it is loose in some parts, and thrown into little folds or wrinkles which adhere to strong fibrous bands, the thickened portions of periosteum or retinacula before noticed, which extend from the head along the neck. From the latter the synovial membrane is reflected to the capsule, along which it is conducted to the outer circumference of the acetabulum; it then covers both surfaces of the cotyloid ligament, lines the acetabulum, covers and adheres to the fatty mass at the bottom of this cavity, and is then reflected along the interarticular ligament to the head of the femur.

The *articular fatty mass* has a peculiar reddish and often a dark appearance; it fills the rough surface in the acetabulum, and is confined in its place by the synovial membrane and by a number of

decussating tendinous bands. It receives a great number of blood-vessels and nerves, chiefly from the obturator, through the notch; there are also small, red, fatty masses around the neck of the femur, and one at the insertion of the interarticular ligament in the head of bone.

The *cotyloid ligament* (fig. 150) is the fibro-cartilaginous lip which deepens the acetabulum, and at the same time narrows its orifice, so as to hold the head of the femur, even after the capsular ligament and all the muscles have been divided; and it fits so tightly around it, that the head appears to be retained in the socket partly by atmospheric pressure. It is composed of strong circular fibres; these pass deep into the notches in the border of the acetabulum, and thereby level off all irregularities; its attached border is very thick, in some places nearly a quarter of an inch; its free margin, which inclines inwards or centrally, is thin and sharp; a vertical section of it, therefore, presents a triangle, the base upon the bone; it is covered on each surface by the synovial membrane; it is very thick and deep superiorly and posteriorly; its fibres adhere intimately to the bony margin, but are not continuous with the encrusting cartilage of the cavity; a distinct fissured line divides them. It adheres intimately to each cornu of the cotyloid notch, and is distinct from the ligament of the latter. It serves to deepen the acetabulum, and to level the irregularities in its margin, also to prevent the neck of the femur striking against the latter.

Transverse ligament consists of ligamentous bands, which pass across the notch in the border of the acetabulum; some pass from the pubis to the ischium, others decussate these and pass from ischium to pubis. It completes the margin of the cavity, and leaves sufficient space above and behind it for the passage of vessels and nerves to the cotyloid fat.

Interarticular ligament, or *ligamentum teres*, is about an inch and a half in length; it consists of fine ligamentous fibres covered rather loosely by synovial membrane. Though called round, it is rather of a triangular yet tapering form, the base attached to the notch and, by the synovial membrane, to the depression in the acetabulum; the apex to the head of the femur. It *arises* by two flat bands, the superior of which is the smaller, from the margins of the cotyloid notch, these soon unite and are enveloped by the synovial membrane; it then runs upwards, backwards, and outwards, contracting in size, between the articular fatty mass and the head of the bone, into the depression on which it is *inserted*. This ligament is very variable as to size and strength; is rarely wanting in man, but is absent in some animals; it serves to conduct blood-vessels from the acetabulum to the head and neck of the femur, which, from its position in respect to the shaft of the bone, may require a nutritious supply from this source: some consider it may also limit too much abduction of the thigh.

This joint enjoys free motion in every direction: flexion, extension, abduction, adduction, rotation, and circumduction. In *flexion* the

head and neck move round the same imaginary axis, the anterior portion of the capsule is relaxed, and the posterior is made tense, in proportion as the flexion increases. In *extension* the head of the femur projects against the forepart of the capsule, and is supported by the accessory ligament and by the psoas and iliac tendon; too much extension is prevented by the neck of the femur meeting the posterior border of the acetabulum. In *abduction* the head of the bone presses the lower and inner part of the capsule, which is rather loose and yielding, and the limb can be separated from the median line to a considerable extent. In *adduction* the head of the bone moves a little outwards into the deepest part of the cavity, and the thighs are approximated; if the thigh be a little flexed, this motion can be increased so as to cross the limbs. In *circumduction* there is a succession and combination of the preceding simple motions, and the limb describes a cone, the apex of which is in the articular cavity. In *rotation* the great trochanter moves in an arch of a circle, forwards in rotation inwards, backwards in rotation outwards; the centre of this circle is in the joint, and its radius is the axis of the head and neck: rotation outwards is more free and extensive, on account of the aspect of the head and the direction of the neck, and the number of muscles which contribute to it; it is also the natural state of the limb, so that even at rest the toes are directed outwards.

The depth of the acetabulum, the strength of its capsular ligament, together with the surrounding muscles, all seem well adapted to prevent luxation: such accidents, however, not unfrequently occur. This joint is not so liable to dislocation as that of the shoulder, for several reasons: in the first place, its motions are much more limited in extent; second, the glenoid cavity affords little mechanical security, while the cotyloid, on the contrary, permits the head of the femur to sink into it; third, the oblique direction of the head of the thigh-bone presents an additional obstacle; fourth, the capsular ligament of this joint is much stronger and shorter than that of the shoulder, and it is further protected by very strong accessory fibres and by several muscles.

This joint may be dislocated in four directions; backwards and upwards on the dorsum of the ilium; backwards on the ischiatic notch; forwards and upwards on the pubis; and forwards and downwards, or inwards, on the foramen obturatorium.

The situation of the trochanter major is a point of great importance in discriminating accidents about the hip-joint, and its relation to some other prominent points should kept in mind; in the erect position of the body, the superior part of the trochanter is nearly on a level with the crest of the pubis; the distance between the anterior superior spine of the ilium and the trochanter major is less than from this projection to the os pubis, or from the os pubis to the anterior superior spine. Lines connecting these three points will form nearly a right-angled triangle, of which the longest side is the line connecting the superior spine to the pubis, and the shortest, that which joins the spine to the trochanter. In dislocation upwards or backwards the

trochanter is brought nearer the superior anterior spine of the ilium, but is much less prominent than natural; in the luxation backward it is removed from the body of the pubis, and is also less prominent than natural; in the dislocation into the obturator foramen, the distance between the trochanter major and the body of the pubis is lessened, while that between this process and the anterior superior spine is greater than usual.

In dislocation *upwards* and *backwards*, which is the most frequent, the head of the bone rests on the dorsum of the ilium, the upper part of the capsular ligament is ruptured, and the accessory and round ligaments are torn: the limb is shortened about two inches, and is inverted and more or less fixed. In rotation inwards the head of the femur is pressed against the back part of the capsular ligament, and if the rotation be carried far, a considerable portion of the bone is outside the cotyloid cavity; hence the species of dislocation now described is most likely to occur when rotation inwards is accompanied by external violence, that is, by the individual falling or receiving a blow when the knee and foot are turned inwards. When this dislocation has occurred the three glutæi muscles are those principally concerned in keeping the head of the bone fixed on the dorsum of the ilium; but when the limb has been extended and the head of the bone is sufficiently raised to pass over the edge of the acetabulum, the psoas and iliacus, with the obturator externus and pectinalis, will assist to bring it into the proper situation. Although in common cases of dislocation we may presume, from the rapid recovery of the patient, that no other injury is done to the joint than what has been already described, yet the dissection of a case of luxation upwards and backwards has been published, in which the gemini, pyriformis, obturators, and quadratus femoris, were completely torn across: there was also laceration of some fibres of the pectinalis.

In the dislocation backwards, and which is also a little upwards, or that into the ischiatic notch, the head of the bone rests on the pyriformis muscle, and between it and the sciatic ligaments, the limb is a little shortened, it is also inverted, but much less so than in the dislocation on the dorsum of the ilium. This dislocation, also, is most likely to happen, the force being applied when the thigh is rotated inwards and flexed.

When the femur is dislocated forwards on the obturator foramen, the capsular ligament and the internal accessory fibres are lacerated; the ligamentum teres is, according to Sir A. Cooper, always ruptured; the limb is lengthened from one to two inches; the knee is advanced and abducted with slight eversion; the great trochanter is much less prominent than usual.

In dislocation upwards and forwards the head of the bone rests on the ramus of the pubis, under Poupart's ligament, where it may be plainly felt; the limb is shortened, slightly flexed, and everted.

A calculation has been made, that out of twenty dislocations of the hip-joint, twelve take place on the dorsum ilii, five on the ischiatic notch, two on the foramen ovale, and one on the pubis.

SECTION XXI.

FEMORO-TIBIAL ARTICULATION OF THE KNEE-JOINT.

The condyles of the femur, the head of the tibia, and the patella, enter into this arthrodial ginglymoid articulation; the fibula is only remotely connected with it. The ligaments which secure it may be classed into those external and those internal to the synovial membrane, although strictly they are all external to it. The *external ligaments* are the ligamentum patellæ, ligamentum posticum, and the internal and external lateral ligaments. The *internal* are the two crucial, the two interarticular fibro-cartilages, the transverse, and certain folds of the synovial membrane.

Fig. 152.*

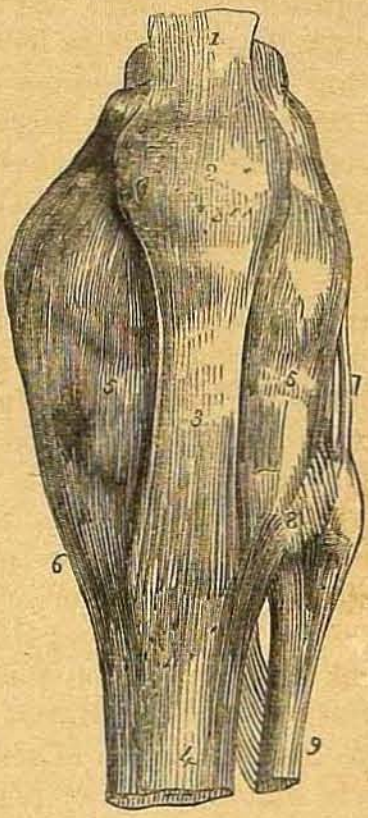

Several bursæ are in its vicinity; three are placed on its anterior aspect; these may be named the superior, middle, and inferior. The first and last are deep-seated; the second is *subcutaneous* on the patella, and partially covered by an imperfect fascia; its cavity is frequently intersected by tendinous bands. The *superior bursa* is on the forepart of the femur, behind the extensor tendons, and surrounded by fat; it is very thin, and in some cases only a distinct sac; it usually communicates with the cavity of the joint so freely as to appear as a *cul de sac* of the synovial membrane itself, a mere circular constriction marking the separation. To this bursa, or to the synovial membrane, some muscular fibres are attached (page 368). The *inferior bursa* is small and delicate; is situated between the tubercle of the tibia and the ligament of the patella. There are various other small bursæ connected to the adjacent tendons. Although there is no regular capsular ligament to this joint, yet its place is in a great degree supplied by the fascia lata and by the aponeuroses from the vasti and the other lateral muscles and tendons, which give it a very perfect covering. On the outer side of the joint the fascia lata is very strong and tense, extending as a broad ligament from the vastus externus and from the outer condyle of the

* An anterior view of the ligaments of the femoro-tibial articulation or knee-joint. 1. A portion of the tendon of the quadriceps extensor muscle of the leg. 2. The patella. 3. The ligamentum patellæ. 4. The tibia. 5. 5. The synovial membrane. 6. A part of the internal lateral ligament. 7. The long external lateral ligament. 8. The anterior superior tibio-fibular ligament. 9. The fibula.

femur, to the anterior border of the tibia, and to the aponeurosis of the leg. On the posterior aspect is the aponeurotic expansion from the semimembranosus tendon. In the centre, and at either side, the femoral condyles are covered by a strong fibrous tissue, which is supported by the constant pressure and action of the heads of the gastrocnemii ; the latter also are sometimes strengthened by sesamoid tubercles. The bony surfaces which compose this joint have been already described. These are covered in the usual way with a compact cartilage. On the femur this extends much higher on the condyles in front than behind, and does not at all cover the sides ; on the tibia it is thicker in the centre than at the circumference, contrary to the general condition in arthrodial surfaces. This apparent anomaly, however, is removed by attending to the position of the semilunar cartilages, which deepen the border of these cavities so considerably.

The *ligamentum patellæ* consists of strong, parallel, glistening, tendinous fibres, which *arise* broad from the inferior angle and from the anterior surface of the patella, descend obliquely outwards and backwards, and are *inserted* narrow into the tubercle of the tibia, a little below the small bursa which lies behind this ligament. This ligament is principally a continuation of the extensor tendon, in which the patella was developed at first in the form of cartilage, in the same manner as the sesamoid bones are ; it is about two inches long, and narrower in the centre than at either end ; is covered by the skin and fascia lata, and bound down by the latter so as to be concave towards the surface ; it lies upon a quantity of soft adeps and upon the small inferior bursa.

Fig. 153.*

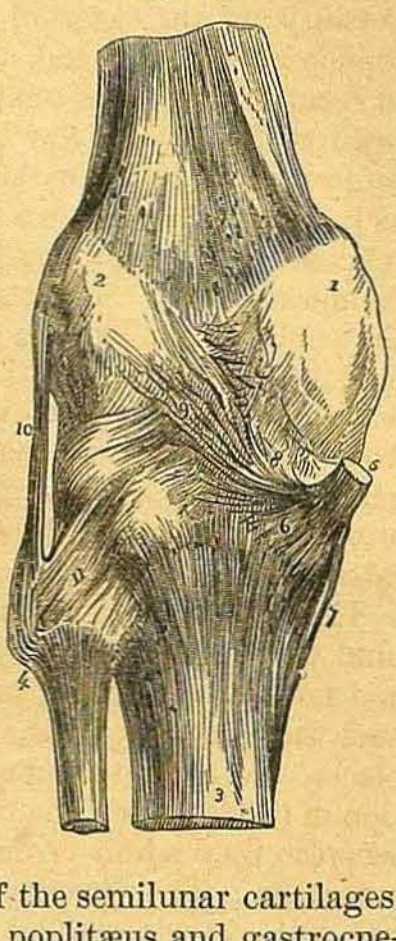

The *posterior ligament* has been noticed in the dissection of the semi-membranosus muscle, from the tendon of which this quadrilateral ligament principally *arises ;* it ascends obliquely from behind the inner condyle of the tibia to the external condyle of the femur ; it separates the gastrocnemii and plantaris from the synovial membrane, is also connected to the borders of the semilunar cartilages, and is strengthened by some fibres from the poplitæus and gastrocne-

* A posterior view of the ligaments of the knee-joint. 1. The internal condyle of the femur. 2. The external condyle. 3. The posterior surface of the tibia. 4. The head of the fibula. 5. The tendon of the semi-membranosus muscle cut short. 6. The inferior or descending process of this tendon. 7. The process of the same tendon which passes forwards and inwards beneath the internal lateral ligament. 8. The process which passes upwards and outwards to assist in forming 9. The ligamentum posticum of Winslow. 10. The long external lateral ligament. 11. The posterior superior tibio-fibular ligament.

mii tendons. The poplitæal vessels are behind it, and a quantity of adipose substance and the synovial membrane are in front of it. The azygos articular vessels perforate it by several foramina. It is made very tense and resisting in extension of the leg; in flexion it is relaxed and drawn a little backwards, and thereby the synovial membrane and the adipose substance are drawn out of the angle of the joint. (*See* page 381.)

The *internal lateral ligament*, flat, and broader in the centre than at either end, *arises* from the back part of the tuberosity on the inner condyle of the femur, below the insertion of the tendon of the adductor magnus; descends obliquely forwards, is about three inches long, and is *inserted* into the internal condyle of the tibia; it is closely applied to the synovial membrane and to the semilunar cartilage. The tendon of the semi-membranosus, and some articular vessels, separate it near its insertion from the tibia, and it is covered by the aponeurotic expansion of the gracilis, sartorius, and semi-tendinosus, a bursa being interposed.

The *external lateral ligament arises* from the back part of the tuberosity on the external condyle, above the fossa, for the poplitæal tendon; is thick, round, and smooth; descends, inclining backwards, in front of the biceps tendon, and is *inserted* into the outer side of the head of the fibula, the biceps tendon sometimes enclosing it in its bifurcation. In the extended state of the limb it inclines backwards as it descends, and is in a tense condition; in flexion it is vertical and relaxed. This ligament has little or no connexion to the synovial membrane, or to the external cartilage, being separated from these by the poplitæus tendon, the articular vessels, and a portion of the biceps tendon. There is sometimes a fibrous fasciculus more deeply seated, which is named *short* or *deep external lateral ligament;* it *arises* from the condyle more posteriorly, and near to the outer head of the gastrocnemius, adheres to the semilunar cartilage, and is *inserted* into the back part of the fibula. A portion of the biceps tendon separates these ligaments.

The external and internal lateral ligaments are situated a little behind the centre of the articulation; hence they are relaxed in flexion, and tense and resisting in extension of the limb; they serve to connect the bones together, to confine the semilunar cartilages in their places, and to prevent any lateral displacement; they also resist rotation of the femur on the tibia inwards, but admit of rotation outwards, whereas they admit of the tibia or the leg rotating inwards, but not outwards. The direction of the ligamentum patellæ, and of the internal and external lateral ligaments, favours rotation of the tibia inwards more than outwards; rotation of the leg, however, in the latter direction, is more extensive, in the semiflexed position, than in the former, on account of the peculiar arrangement of the crucial ligaments. To see the internal ligaments, separate the extensor tendons from the patella, and open the synovial membrane above and behind the latter.

The *synovial membrane* of the knee is the largest membrane of this class in the body. We may trace it through its whole extent, as it

presents one continuous surface. Open it by a transverse incision above, and a vertical one on each side of the patella; allow the latter to fall down everted towards the tibia. From the lower extremity of the extensor tendon the membrane passes back to the forepart of the femur, about two inches above the condyles, and a little higher above the outer than the inner. Where the bursa and synovial membrane communicate freely, and form but one membrane, the upper end of the *cul de sac* will be found in the extended state of the limb three inches above the trochlea; it is then continued over the latter and over the condyles, and covers their sides, although deficient of cartilaginous incrustation; it ascends higher on the internal side of the inner condyle than of the outer; posteriorly it is also continued above the inner to a greater height. From the back part of the femur it is reflected on the head of the gastrocnemii on each side, and on the posterior ligament in the centre, but partly separated from it by fat. From the depression between the condyles, but rather from the external, a fold of this membrane descends obliquely forwards and inwards to the mass of articular fat at the lower and anterior part of the joint; this is termed the ligamentum mucosum. It is also continued from the femur along the crucial ligaments to the head of the tibia. From the lateral parts of the joint it is continued to the upper surface of the semilunar cartilages, turns round their sharp, thin edge to their lower surface, and thence to the upper surface of the tibia, where it meets the reflec

Fig. 154.*

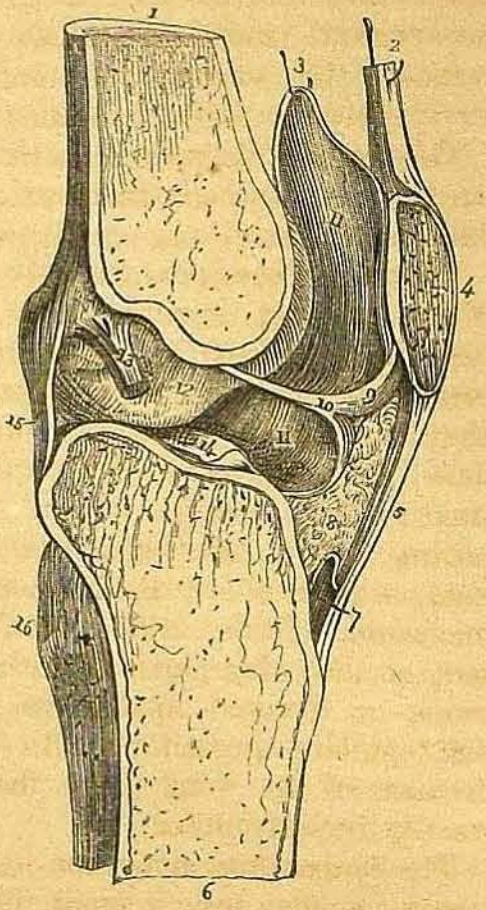

* A vertical section of the knee-joint in its antero-posterior diameter, in order to exhibit the arrangement of the synovial membrane and the position of the ligamentum mucosum. 1. A section of the lower extremity of the femur. 2. The tendon of the extensor muscles of the leg. 3. The pouch of synovial membrane between the extensor tendons and the front of the lower extremity of the femur. 4. The patella. 5. The ligamentum patellæ. 6. A vertical section of the tibia. 7. A bursa situated between the ligamentum patellæ and tubercle of the tibia. 8. The mass of fat behind the ligamentum patellæ. 9. The synovial membrane passing downwards from the patella over the mass of fat to the tibia, and reflected upwards and backwards to form 10. The ligamentum mucosum or adipose ligament. 11. 11. The cavity of the synovial membrane. 12. The external condyle of the femur. 13. The superior extremity of the anterior crucial ligament. 14. A portion of the external semilunar fibro-cartilage; its section presenting a triangular form. 15. The posterior ligament of the joint. 16. The superior extremity of the fibula.

tions which have descended along the crucial ligaments. From the tibia it is continued anteriorly to the mass of soft adeps, which it covers, and where it joins the ligamentum mucosum; it then passes to the posterior and upper part of the ligamentum patellæ; and, lastly, it covers the back part of the patella, at the upper border of which we commenced its description, and lines the vasti muscles at either side, beneath which, particularly the internal, it is much dilated. These lateral dilatations or pouches, especially the inner one, are often very conspicuous in articular effusion. As the poplitæal tendon is continued from the outer condyle, a process of this membrane is reflected round three-fourths of it, as far as the head of the fibula, and touches the synovial membrane of the tibio-peronæal articulation. In some instances the synovial membranes of these two articulations, though very generally distinct, communicate.

Fig. 155.*

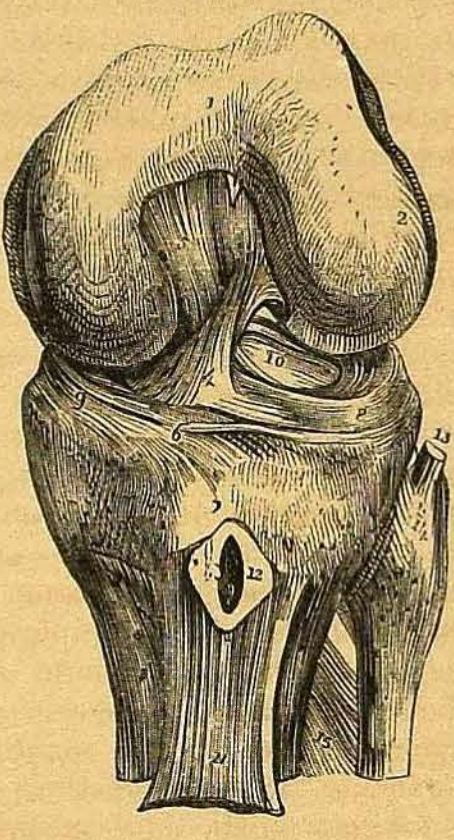

The internal ligaments in this joint are the alar, mucous, transverse, crucial, and the semilunar cartilages.

The *alar ligaments* are only folds of the synovial membrane, in some measure produced by the displacement and eversion of the patella; they are one on either side of this bone; the internal is the most distinct; they diverge above, and, uniting below, are lost in the fatty mass on either side of the ligamentum mucosum. These folds often present, as also other parts of this membrane, a fringed appearance, like fine epiploic appendices. In some diseases of the joint these become greatly hypertrophied.

The *ligamentum mucosum*, or *adiposum*, is also only a small fold or tubular process of the same membrane, of a conical form, arising broad from the fatty substance be-

* The left knee-joint laid open in front; the femur is flexed upon the tibia and the ligamentum patellæ turned down, in order to expose the interior of the articulation. 1. The lower extremity of the femur covered with cartilage. 2. The external condyle. 3. The internal condyle. 4. The anterior crucial ligament. 5. The posterior crucial ligament. 6. The transverse ligament. 7. Portion of the ligamentum mucosum. 8. The external semilunar fibro-cartilage. 9. The internal semilunar fibro-cartilage. 10. The superior surface of the head of the tibia. 11. The posterior surface of the ligamentum patellæ which has been turned down. 12. The bursa, situated between the ligamentum patellæ and the tubercle of the tibia; it has been laid open. 13. A portion of the external lateral ligament of the knee-joint. 14. The anterior superior tibio-fibular ligament. 15. The interosseous membrane of the leg, deficient above for the passage of the anterior tibial artery.

hind the ligamentum patellæ; it passes backwards, upwards, and a little outwards, and is inserted into the notch between the condyles; it serves to regulate the position of the adipose mass, to keep it opposite the condyloid notch, and thus to preserve a more even surface.

The *articular adipose mass* is constantly present in this joint. It presents a conical form, the base resting on the forepart of the upper surface of the tibia, above the inferior bursa, and behind the ligamentum patellæ and the point of this bone, in front of the synovial membrane, which is thus pushed upwards and backwards into the joint. From the apex of the mass the mucous fold proceeds to the condyloid notch, thus suspending or retaining the fat towards this space, and thereby filling up and levelling the irregularities of the surrounding surfaces. Towards the back part of the joint, also, as well as superiorly, beneath the extensor tendon, there is a considerable quantity of fat, even in thin and emaciated subjects, attached to the membrane and to the adjacent structures, not, however, projecting into the cavity, as the mass anteriorly and inferiorly.

The *transverse ligament* extends between and is attached to the anterior convex portions of the two semilunar cartilages, and above the fatty substance before alluded to; it serves to retain the adipose mass in its situation, and to prevent its receding into the cavity of the joint; it also in some measure secures the semilunar cartilages in their proper situation.

The *crucial ligaments* are the most important of the interarticular ligaments. They are two strong, shining, twisted, fibrous cords, which pass from the notch in the femur to the median line of the head of the tibia; they are very close to each other about the centre of the joint, but thence they separate, crossing each other as they pass to their respective attachments. When viewed anteriorly or posteriorly, this decussation resembles the letter X; they cross also in the lateral view, and therefore present the X form whether seen laterally or before or behind. The origin of the anterior is behind that of the posterior, and its insertion is before that of the latter; therefore they cross when viewed in profile. And, again, the origin of the anterior is external to that of the posterior, while its insertion is internal to that of the latter, therefore they cross also when viewed from before or behind. To see the ligaments distinctly, the patella must be thrown completely down, the ligamentum mucosum divided, also the lateral and posterior ligaments, and the synovial membrane dissected from these fibrous cords; for although they appear within the cavity of the joint they are really without and behind it, and in the latter aspect the membrane can easily be detached from them at its reflections without its cavity being opened.

The *anterior, horizontal*, or *external crucial ligament*, *arises* from the inner and posterior part of the external condyle; descends obliquely forwards and inwards, and is *inserted* near the forepart of the head of the tibia, in front of the spine, where it also joins the anterior cornu of the internal semilunar cartilage. This ligament is

smaller than the posterior; it is best seen from the front, and when the joint is flexed.

The *posterior*, *internal*, or *perpendicular crucial ligament*, *arises* from the outer and forepart of the internal condyle; descends nearly vertically, but inclining backwards, and is *inserted* partly into the external semilunar cartilage, and partly into the depression on the back of the tibia, behind its median spine. This ligament is larger than the anterior; its origin is seen anteriorly behind the ligamentum mucosum; its insertion is broad, and is best seen posteriorly when the joint is extended and the ligament of Winslow and a quantity of fat removed.

The crucial ligaments serve to attach the femur to the tibia; they steady the one bone upon the other, and strengthen the back part of the joint in the same manner as the patella does in front; they also tend to prevent any lateral displacement; they are both made tense, and become more twisted, and therefore more resistant in rotation of the tibia inwards, but are relaxed and somewhat separate in rotation of it outwards. In extension they are both very tense, especially the posterior; in flexion the anterior is so, but in a less degree; in fine, they resist too great rotation inwards, also excessive extension or flexion, but they admit of rotation outwards. The posterior ligament also, by its attachment to the external semilunar cartilage, serves to retain or restore this cartilage to its place, as in rotation of the leg outwards the cartilage is allowed to yield or move backwards. If the crucial ligaments be divided the femur may be detached, and the twisted structure of the former can be seen. The semilunar cartilages and their ligaments may be next examined.

The *semilunar cartilages* are placed upon the articular surfaces of the tibia. The convex margin of each is thick, and connected by its edges to the synovial membrane, and between these to the external ligaments and fascia. This latter aponeurotic attachment has been called the *coronary ligament* of each cartilage. The internal concave margin has a sharp edge, which is free in the cavity of the joint. Each cartilage presents two surfaces; a superior, which is concave and oblique, adapted to the condyles, and an inferior, which is nearly flat, and rests upon the head of the tibia. The anterior and posterior extremities of each are fibrous, and fixed to the head of the tibia, before and behind its middle protuberance: these insertions are termed the *oblique ligaments*. The two cartilages are united in front by the transverse ligament. The *external cartilage* is more circular, and more moveable than the internal; it covers the greater part of the external cavity of the tibia; its convex border is loosely connected to the edge of the tibia and to the surrounding ligaments; its extremities or cornua approximate, and are inserted into the depressions before and behind the central spine of the tibia. The poplitæus tendon, and its synovial sheath, are contiguous to the convex border posteriorly, and sometimes groove it. To the same border anteriorly the transverse ligament is attached, which passes across to join the internal

cartilage. Its anterior cornu sends some fibres to mingle with the anterior crucial ligament; its posterior cornu is not only inserted into the depression on the tibial spine, but is also connected to the posterior crucial ligament by a distinct and strong fasciculus. The *internal* is a segment of an oval figure; its anterior extremity is narrow, and attached to the head of the tibia in front of the spine; it is also connected to the anterior crucial ligament; its posterior extremity is broader, and its cornu is inserted behind the spine and behind the insertion of the external cartilage; its convex border is attached to the internal lateral ligament; its concave edge is very thin, and its upper surface is not so broad as that of the external cartilage, therefore the internal glenoid cavity of the tibia is larger than the outer. The median line of the tibia presents the insertion of these several parts in the following order from before backwards. First, the anterior cornu of the internal semilunar cartilage; secondly, the insertion of the anterior crucial ligament; thirdly, the anterior cornu of the external cartilage; the insertion of the anterior crucial ligament is intimately connected to the anterior cornua of both cartilages, particularly of the internal; fourthly, the posterior cornu of the external cartilage, only separated from its anterior by a portion of the insertion of the anterior crucial ligament; fifthly, the posterior cornu of the internal cartilage; and, sixthly, the insertion of the posterior crucial ligament. The semilunar cartilages are composed of concentric fibres, longer externally than internally. The central portions appear truly cartilaginous, but the extremities are distinctly fibrous; they serve to deepen the articular surfaces of the tibia, and thus to retain the condyles of the femur; they must also lessen the effects of concussion in the joint, and in the limb generally; the mobility of the external one also favours rotation of the leg and thigh outwards; in the latter motion the outer condyle of the femur glides a little backwards, the condyle of the tibia being bevelled off posteriorly, so that the external cartilage is enabled to accompany the femur, and thus to secure and facilitate its motion.

Fig. 156.*

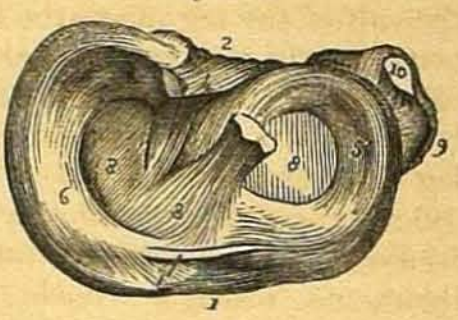

This joint enjoys flexion and extension in a very perfect manner, and also, when it is semiflexed, a slight degree of rotation. In these motions the patella is nearly fixed, the trochlea of the femur moves behind it, and its distance from the tibia remains almost uniformly the same; it only serves, therefore, to protect the joint in front, and to

* The superior extremities of the tibia and fibula as seen from above. 1. The anterior surface of the tibia. 2. The posterior surface. 3. Part of the anterior crucial ligament. 4. Part of the posterior crucial ligament. 5. The external semilunar fibro-cartilage. 6. The internal semilunar fibro-cartilage. 7. The transverse ligament. 8. 8. Cartilage of incrustation on the head of the tibia. 9. The head of the fibula. 10. Portion of the external lateral ligament of the knee-joint.

support the body in the kneeling posture, and may be considered as a sort of sesamoid appendix to the common tendon of the extensor muscles. When the limb is flexed it is prominent, and steadily fixed on the anterior angle of the joint; but when extended it is moveable, and sinks a little downwards and backwards, unless elevated by the rectus and vasti muscles. In flexion the glenoid cavities of the tibia, with the semilunar cartilages, come a little forward beneath the femur, and the latter turns on the former in such a manner that its trochlea looks rather upwards instead of forwards; and the condyles, which, during extension, were prominent posteriorly, are now directed downwards, and lodged in the tibial depressions; most of the ligaments of the joint are relaxed, except the anterior or ligamentum patellæ, which is stretched in proportion as the flexion is increased, and thereby the patella is fixed on the forepart of the joint, and cannot be moved to either side. This motion can be carried to a great extent, even until the calf of the leg meets the back of the thigh, and both form a very acute angle convex forwards. If flexion be forced too far in the dissected joint, the crucial ligaments, particularly the anterior, will become tense and resistant; when the joint is only semiflexed, the leg can be rotated slightly inwards and outwards; the internal condyle of the tibia moving only as on a pivot, while the external glides forwards or backwards; rotation inwards is resisted by the crucial ligaments, which are made tense and more twisted, whereas in rotation outwards their decussation or twisting is rather unfolded. In this state the opposed surfaces of the tibia and femur can be separated to a considerable distance. The efficiency, therefore, of these ligaments depends on their being retained in a twisted state, and this is secured by the poplitæus muscle, which, in the erect position, has a constant tendency to rotate the femur outwards, and thereby to increase the decussation and tension of the crucial ligaments. The mobility of the external cartilage backwards, and the form of the outer head of the tibia, facilitate rotation outwards, and the principal muscles contribute to it. In extension the tibial cavities glide backwards, and the condyles of the femur also turn in the same direction, and are prominent posteriorly, where they are supported and opposed by the heads of the gastrocnemii. All the ligaments, especially the posterior, crucial, and the ligament of Winslow, are made tense, except the ligamentum patella, which is quite relaxed, and the patella is moveable to either side. The strength and tension of the ligaments are so powerful, that it is totally impossible to carry the extension beyond the straight line, or to bend the joint forwards; when the extensor muscles act strongly, they raise the patella into the upper and deepest part of the trochlea, and its upper half is superior to it.

Dislocation of the patella may take place either upwards, inwards, or outwards; the latter is the more frequent form. A dislocation upwards could not occur without rupture of the inferior ligament of the patella, which is so strong that frequently, in violent action of the

extensor muscles, the patella itself snaps across before this ligament gives way. When the knee is much bent dislocation in either direction cannot take place; the extent of the articulating surfaces of the femur, and the force with which the patella is pressed in between the condyles, prevent such a displacement. The dislocation outwards is more frequent, probably for the following reason: the rectus femoris descends obliquely inwards; the ligamentum patellæ, which is only a continuation of the extensor tendon, descends obliquely outwards; the tubercle of the tibia is nearly perpendicularly opposite to the inferior spinous process of the ilium; therefore, the extensor muscle and the ligament form an angle convex inwards at the patella, and concave outwards. The position most favourable to this luxation is when the knee is slightly bent and inclined inwards; if, at that time, the extensor muscles act with sudden force, they tend to straighten the angular line just mentioned, and in doing so to jerk the patella off the trochlea to its outer side. When complete luxation of the patella outwards has taken place, the patella rests over the external condyle of the femur, in which place it is fixed by the rectus, crureus, and vasti muscles; hence the necessity for bending the thigh on the pelvis in attempting the reduction, in order to relax these muscles as much as possible. The extent of the synovial membrane permits this displacement to occur without any rupture of it. Dislocation of the patella inwards is more rare, but in other respects is so similar in its nature to the outward luxation that it does not require any notice.

The tibia may be dislocated from the femur in four directions, backwards, forwards, or to either side; the two former, particularly that backwards, may be complete; the latter are incomplete. There is no joint in the body so well supported by ligaments as that of the knee: on the sides we have the lateral ligaments; in front the ligament of the patella and the tendinous insertion of the extensor muscles; behind the posterior ligament of Winslow; and centrally the strong crucial ligaments and the spine of the tibia rising into the condyloid notch. Additional ligamentous bands are also occasionally seen. When the tibia is completely dislocated backwards into the ham, the ligamentous attachments of the patella, either above or below, must give way, and the leg is shortened. The crucial and posterior ligaments are also torn. The flexor muscles of the leg, which are attached to the tibia, will contribute to keep the bone in the luxated position. Complete forward dislocations of the tibia have occurred, but they are very rare; in such case all the ligaments of the joint must give way, and the heads of the gastrocnemii and popliteus muscles would also, probably, suffer.

The semilunar cartilages are sometimes displaced, particularly the internal one; it usually arises from a sudden twist of the knee inwards, and in persons whose knee-joints are distended from frequent injury or chronic rheumatism: but little is known of the true pathology of this injury.

SECTION XXII.

SUPERIOR TIBIO-FIBULAR ARTICULATION.

THIS is a very plane arthrodia, the surface of the tibia being slightly convex, and looking downwards and outwards, to meet the head of the fibula, which looks upwards and inwards. The tibio-fibular articulations can scarcely admit of any comparison with the radio-ulnar, though analogous to them in position; but little motion occurring in the former, and very free motion in the latter. This articulation is secured by a distinct *synovial membrane*, which, as has been before mentioned, sometimes communicates with that of the knee-joint; there is also a distinct *anterior* and *posterior ligament*, the anterior is the stronger of the two, each composed of strong fibres passing from the tibia obliquely downwards and outwards to the fibula. The external lateral ligament and the tendon of the biceps still further secure this joint, in which the fibula enjoys a very obvious motion forwards, backwards, and a little upwards: these motions, though to a small extent, yet permit the outer ankle, and, of course, the whole foot, to move more freely outwards.

Luxation of the upper head of the fibula is usually the consequence of disease; for the application of a force sufficient to dislocate the bone is much more likely to break it. The action of the biceps flexor, the only muscle inserted into the fibula, could not alone produce this accident. When the head of the fibula is thrown back, the anterior ligament and the accessory fibres from the tendon of the biceps, with the synovial capsule, are ruptured. Boyer mentions a case in which the whole fibula was driven directly upwards in consequence of a dislocation outwards of the ankle.

The shafts of these two bones are connected by the interosseous membrane, which consists of aponeurotic fibres descending obliquely from the tibia to the fibula; there is a large deficiency in it above, for the passage of the anterior tibial vessels; inferiorly it becomes very narrow, as the bones are nearer to each than above; the anterior peroneal vessels pass through it about two inches above the ankle; the tibialis anticus and the extensors of the foot cover it in front, and the flexors behind.

SECTION XXIII.

INFERIOR TIBIO-FIBULAR ARTICULATION.

THIS articulation is an amphiarthrosis; the inferior extremity of the fibula is convex and received into a depression on the tibia; both

surfaces are rough superiorly and covered by cartilage inferiorly, and are connected together by a strong *anterior* and *posterior* ligament, which are each of a triangular form, the base below attached to the fibula; thence they pass upwards and inwards to be inserted into the tibia. The *anterior* is covered by the peroneus tertius muscle, the aponeurosis of the leg, and the skin, and rests upon the inferior interosseous ligament; its lower border assists in deepening the anterior border of the ankle articulation, and is composed of glistening parallel fasciculi, which are usually divided by blood-vessels into a superior and inferior set. The *posterior* is similar to the anterior in direction, but of less transverse extent, and consists of a superior and inferior portion; the latter runs more transversely across the back of the ankle-joint and is attached to the two malleoli; it assists in deepening the margin of the cavity for the head of the astragalus, and is covered by the long and short peroneal tendons. The synovial membrane is only a small *cul de sac* continued from that of the ankle-joint. Above this is the *interosseous ligament*, composed of short and strong fibres which fasten the bones very closely and firmly together. The anterior and posterior ligaments not only connect the tibia and fibula to each other, but they also strengthen the ankle-joint, and assist in forming the socket for the astragalus; very little motion occurs in this joint, beyond a little yielding of one surface against the other.

SECTION XXIV.

ARTICULATION OF THE ANKLE.

This is the most perfect ginglymoid joint in the body, excepting that between the ulna and humerus. A deep, mortise-like cavity, with an antero-posterior ridge, is formed by the lower surface of the tibia and by the two malleoli; the latter deepen the cavity considerably at each side; the tibio-fibular ligaments also, particularly the posterior, complete the margins before and behind. The tibia is the principal bone in this cavity; the fibula forms little more than its outer wall; this, however, though narrow, passes down very low, and affords it considerable defence in this aspect. The internal malleolus is not so long or deep, but is broader, and extends more forwards than the outer ankle; hence the foot inclines outwards more freely than inwards. The upper or trochlear surface of the astragalus corresponds to this cavity, is slightly concave from side to side, and very convex from before backwards; its external margin is more elevated than the internal, and the superior articular surface is continuous with the lateral ones, of which the outer is much larger than the inner. This joint is secured by very strong lateral ligaments, and also by a synovial membrane and an anterior ligament. There is no perfect posterior liga-

ment, but the lower border of the posterior tibio-peroneal ligament extends to a variable depth upon this aspect of the joint.

Fig. 157.*

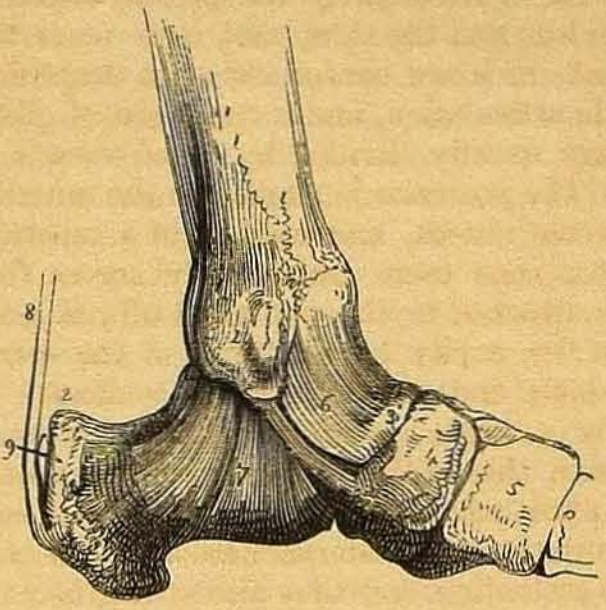

The *internal lateral* or *deltoid ligament* is very dense; it *arises* from the internal malleolus, descends in a radiated manner, and is *inserted* into the astragalus, os naviculare, and calcis. The superficial and anterior fibres are long and thin, and extend to the os calcis and to the calceo-scaphoid ligament. The deeper and posterior fibres are

Fig. 158.†

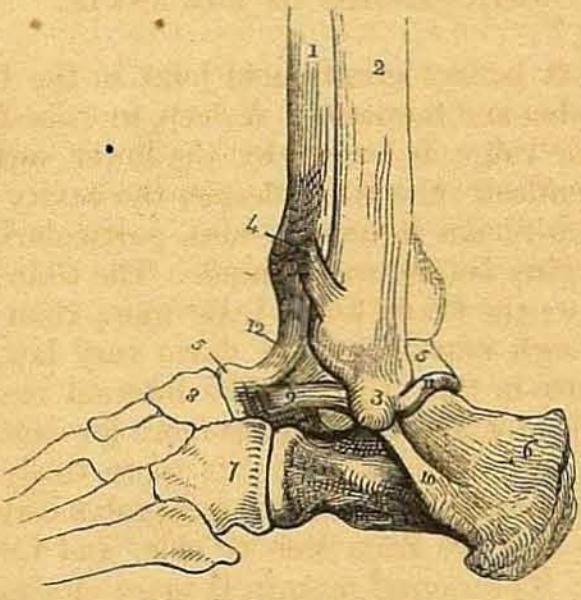

* An internal view of the ankle-joint. 1. The internal malleolus. 2. The os calcis. 3. A part of the astragalus. 4. The os naviculare or scaphoid bone. 5. The internal cuneiform bone. 6. The anterior ligament of the ankle-joint. 7. The internal lateral or deltoid ligament. 8. The tendo Achillis. 9. A bursa situated between this tendon and the posterior tuberosity of the os calcis.

† An external view of the ankle-joint. 1. The tibia. 2. The fibula. 3. Its external malleolus. 4. The anterior inferior tibio-fibular ligament. 5. 5. The

shorter, but much stronger, and often fibro-cartilaginous. In flexion the posterior fibres are tense, in extension the anterior. This ligament is close to the synovial membrane of the joint, and has equally closely connected to it the synovial and tendinous sheaths of the tibialis posticus, and of the flexor tendons which wind around it, and which give additional strength to this region of the joint.

The *external lateral ligaments* are three, a posterior, middle, and anterior. They all *arise* from the external malleolus, and are *inserted* into the astragalus or os calcis. The *posterior* is very strong and tense, and deep-seated; it passes obliquely backwards and inwards to the ridge on the back of the astragalus, which separates the ankle-joint from the articulation of the astragalus to the os calcis, and on the outer edge of the groove for the flexor pollicis longus tendon; its course is nearly horizontal; its superior border is continued some way on the synovial membrane of the ankle to the tibia; it not only secures the ankle articulation, but it also binds the fibula inwards towards the tibia; it is not much altered by the motion of the joint. The *middle* is round and long, like a tendon; descends almost vertically, but a little backwards; and is *inserted* into the os calcis. It is supported by the peroneal tendons; it is made tense in flexion and is relaxed in extension. The *anterior* is short and broad, passes forwards and downwards, and is *inserted* into the upper and outer part of the astragalus. These three ligaments attach the fibula so closely to the tarsus that any violent divellent force can fracture the lower extremity of that bone more easily than separate it from the ankle-joint.

Fig. 159.*

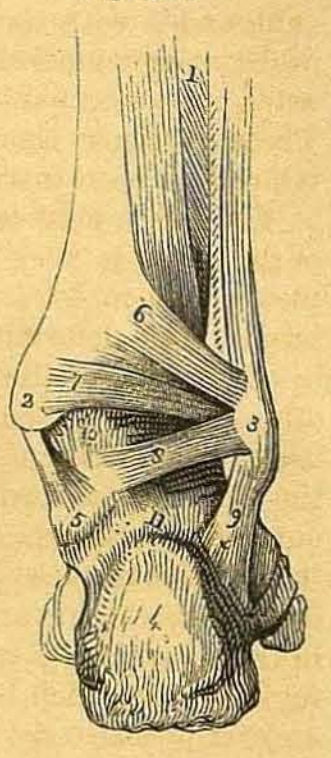

The *anterior* or *tibio-tarsal ligament* of the ankle is thin and membraneous, and often indistinct. It *arises* from the anterior edge of the tibia and tibio-peroneal ligament, and is *inserted* into the upper and outer part of the astragalus; is covered by the tibialis anticus, peroneus tertius, and the extensor tendons of the toes, and by the anterior tibial vessels and nerves, and is separated from the synovial membrane by adipose substance.

The synovial membrane is large and loose before and behind; it always contains some

astragalus. 6. The external surface of the os calcis. 7. The cuboid bone. 8. The os naviculare. 9. The anterior fasciculus of the external lateral ligament. 10. Its middle fasciculus. 11. Its posterior fasciculus. 12. The anterior ligament of the ankle-joint.

* A posterior view of the inferior tibio-fibular and ankle-joints. 1. The lower part of the interosseous membrane. 2. The internal malleolus. 3. The external malleolus. 4. The posterior surface of the os calcis. 5. The posterior part of the astragalus. 6. The posterior inferior tibio-fibular ligament. 7. The posterior transverse ligament. 8. The posterior fasciculus of the external lateral ligament. 9. The middle fasciculus of the external lateral ligament. 10. The synovial membrane of the ankle-joint. 11. The posterior ligament connecting the astragalus and os calcis.

fluid; it lines the articular surface of the tibia and of the two malleoli, and ascends a little way between the tibia and fibula. It covers the superior and lateral articular surfaces of the astragalus, and is prolonged a little way on the upper surface of its neck; it is looser anteriorly than in any other direction, to admit of more free extension. Almost the only motions in this joint are flexion and extension; the latter is more free than the former; both can be carried to a considerable extent, but particularly extension: an excess of either motion is resisted by the opposed bony edges coming into contact, and by the tension of the tendons and ligaments. When the joint is flexed, as when we stand in the erect posture, or when it is even more flexed, as when we bend the body forward, there is scarcely any lateral motion whatever; but when the ankle-joint is extended, even to a slight degree, as in walking, the head of the astragalus being less locked in the socket, a slight lateral motion can occur to either side, but chiefly to the outer, in consequence of the outer malleolus being on a posterior plane to the internal. In this outward lateral motion the fibula recedes a little, and rises vertically: this latter motion is of great use, and is obvious if the superior articular head of the bone be examined at the time.

This lateral or slight rotatory motion at the ankle-joint is not to be confounded with the general abduction and adduction enjoyed by the different articulations in the tarsus, particularly by that between the astragalus and navicular bones, where even a slight rotation exists. These motions, though different from, yet materially add to that which has been just alluded to in the ankle-joint itself.

The ankle-joint is the frequent seat of injury: the lower extremity of the fibula is very liable to fracture, and the tibia to luxation, complete or incomplete. When any such accidents occur, the foot suffers proportional deformity and displacement. Such displacements ought, in conformity to the language applied to the corresponding injuries in other joints, be denominated luxations of the foot, whereas writers usually notice the upper bone or bones engaged in the injury. Thus the tibia is described as liable to partial or perfect dislocation inwards, outwards, forwards, and backwards; it might be more correct to describe each of these injuries as perfect or imperfect dislocations of the foot outwards, inwards, backwards, and forwards. When the tibia is luxated *internally*, which is by far the most frequent accident in this region, and which is almost always accompanied with, and indeed in a great measure the consequence of, a fracture of the lower end of the fibula, the internal malleolus projects on the inner side of the astragalus and os calcis, the outer side of the foot and malleolus look upwards, and the sole of the foot is directed somewhat outwards, so that the leg has no longer its proper bearing on the foot, the axis of the former inclining inwards, whilst the foot is twisted outwards; the synovial membrane is ruptured, and in many cases there is laceration of the deltoid and anterior ligaments of the tibia, and of the posterior transverse band from the tibia to the fibula. After the accident has taken

place, the contraction of the gastrocnemii, solæi, and especially of the peronæi muscles, which rotate the foot outwards, and draw it upwards, sometimes offer much resistance to reduction: this, however, is usually overcome by placing these muscles in a relaxed position.

If the tibia be dislocated *outwards*, the astragalus is forced outwards below the external malleolus, which latter projects considerably; the foot is turned inwards, the sole looking upwards; and the internal malleolus is sunk in a deep hollow. In this accident the malleolus internus must be broken off obliquely; the deltoid ligament is not ruptured; the fibula is usually broken, but, if not, the external lateral, anterior, and posterior ligaments of this bone are lacerated.

In the dislocation *forwards*, the fibula and malleolus internus are broken; the tibia rests on the anterior part of the astragalus and on the os naviculare; the posterior part of the deltoid ligament, and the transverse band from the tibia to the fibula, are ruptured. Dislocation forwards is an accident of rare occurrence; it cannot happen when the foot is flexed on the tibia, for then the tibia sinks down on the back part of the astragalus, and nothing but considerable force could raise it over the upper portion of the bone, which, in this position, extends like a bridge before it: it can only occur when the ankle is forcibly and suddenly extended. In this luxation the foot is lengthened behind, and shortened in front, and presents a considerable projection in the latter situation, caused by the tibia and the several tendons it supports.

Luxation *backwards* is even still more rare. Were such an accident to take place, all the tibial ligaments would be broken, and the fibula, most probably, fractured. There is no very accurate account of a well-authenticated case of this accident on record; indeed it is difficult even to conceive how it could possibly occur.—(*See* Todd's Encyc. of Anat., art. "Ankle-joint," by R. Adams.)

SECTION XXV.

ARTICULATIONS OF THE BONES OF THE TARSUS.

THE seven bones of the tarsus are connected in such a close and firm manner as to admit of but little motion between any two, except at the articulation between the astragalus and the scaphoid, which is somewhat analogous to that of the os magnum in the carpus.

The *astragalus* rests on the os calcis by two arthrodial surfaces. The posterior articulating surface of the astragalus is concave, external, and larger than the anterior or internal, which is convex: a deep groove, leading forwards and outwards, separates these two joints. These two bones are connected by a strong *interosseous ligament*, which arises from the groove in the astragalus, between the two articular surfaces, and is inserted into that on the os calcis. The fibres

run in different directions, and are intermingled with fatty substance. There are also two *synovial membranes*. The *posterior* is confined to these two bones, and larger and looser than the *anterior*, which is continuous with the synovial membrane, between the astragalus and the scaphoid. These synovial membranes are strengthened by strong accessory bands on either side. The lateral ligaments of the ankle-joint also serve to attach these bones more closely, and the tendons of the tibialis posticus and of the long flexors support the connexion on the inner side.

Fig. 160.*

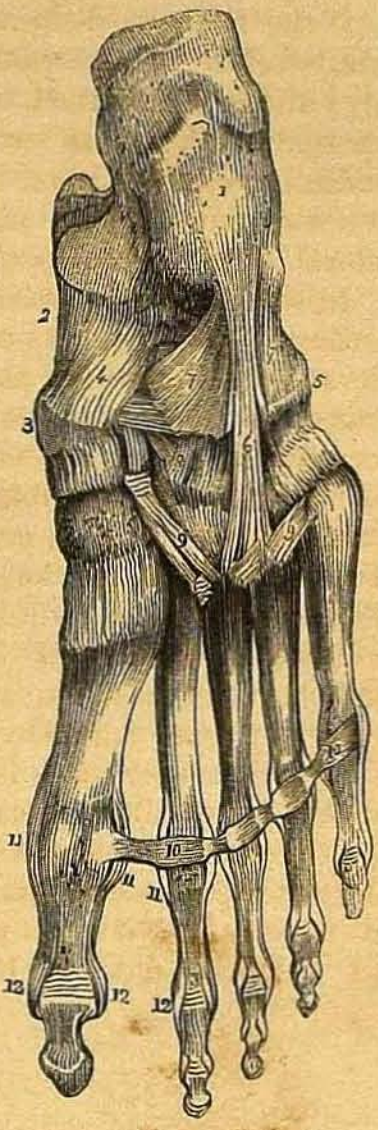

The united astragalus and os calcis form the first segment or row of the tarsus, and are connected to the scaphoid and cuboid bones, which form the posterior face of the second row. Between these two rows a considerable degree of motion prevails, and partial amputation of the foot can be performed in this line by separating these articulations.

The anterior end, or the head of the astragalus, is of an oval form, the long axis directed from above downwards, and from without inwards, and is larger than the glenoid surface in the scaphoid bone, below which it projects considerably: this concave surface, together with the strong fibro-cartilaginous calceo-scaphoid ligament and a small portion of the os calcis, complete the socket for the astragalus. This joint approaches to the class of enarthrosis, and possesses very free motion, on which the mobility of the tarsus and toes greatly depends; it is furnished with a synovial membrane, which is covered superiorly by the following ligament: *superior astragalo-scaphoid;* this consists of strong, but short fibres, which extend from the neck of the astragalus to the margin of the scaphoid bone, and are covered by the extensor digitorum brevis. Below this joint is the *inferior calceo-*

* The ligaments of the sole, or plantar surface of the foot: 1. The inferior surface of the os calcis. 2. A part of the astragalus. 3. The inferior surface of the scaphoid or navicular bone. 4. The calcaneo-scaphoid ligament. 5. The cuboid bone. 6. The long or superficial fasciculus of the calcaneo-cuboid ligament. 7. 7. The short or deep fasciculus of the calcaneo-cuboid ligament. 8. Plantar ligaments connecting the other bones of the tarsus. 9. 9. Plantar tarso-metatarsal ligaments. 10. 10. The transverse metatarsal ligament. 11. 11. The lateral ligaments of the metatarso-phalangeal articulations. 12. 12. The lateral ligaments of the phalangeal articulations.

scaphoid ligament, which extends from the anterior inferior part of the os calcis to the lower surface of the scaphoid. This powerful ligament, or rather fibro-cartilage, supports the head of the astragalus, and is itself much strengthened by the tendon of the tibialis posticus, which winds round beneath it. This tendon also, or this ligament, usually contains a sesamoid tubercle, or a sort of cartilaginous patella, in this place. This ligament supports the great weight of the body, while its elasticity lessens the effects of those concussions to which the limbs are necessarily liable in violent exercise. This joint is also strengthened by another strong ligament, placed superiorly and externally in a deep hollow external to the astragalus, and named *superior calceo-scaphoid.* It extends from the inner and anterior extremity of the os calcis to the outer border and surface of the scaphoid. The synovial membrane of this joint is continuous with that on the anterior and inferior surface of the astragalus.

Simple as well as compound dislocations not unfrequently occur in this articulation, the head of the astragalus being usually thrown forwards so as to form a prominence on the instep. The reduction is in general attended with great difficulty, and occasionally has been found impracticable: in some instances the bone has been completely turned round, so that its lower concave surface has held a firm hold of the end of the tibia.

The *scaphoid bone* is articulated to all the tarsal bones; to the astragalus behind, to the three cuneiform bones before, and to the cuboid externally, and indirectly to the os calcis by the strong inferior calceo-scaphoid ligament just described.

The *cuboid bone* is articulated with the os calcis behind, with the fifth and fourth metatarsal bones before, and internally with the scaphoid and external cuneiform bones. The calceo-cuboid and astragalo-scaphoid articulations are on a transverse level, the line of which is occasionally selected for amputation in disease or injury of the foot or toes. The articular surface of the os calcis is concave from above downwards, while that of the cuboid is concave transversely; the joint is strengthened by superior and inferior ligaments. The *superior*, or *dorsal calceo-cuboid ligaments*, consist of broad, but thin and short fibres, which are close to the synovial membrane, and are covered by the tendon of the peroneus tertius.

The *inferior calceo-cuboid ligaments* are very distinct; they are long, thick, and very strong, and can be divided into superficial and deep laminæ, of a bright, shining appearance; they arise from the under surface of the os calcis, pass forwards, and are *inserted* into the cuboid bone, into the sheath for the long peroneal tendon, and into the base of the third and fourth metatarsal bones.

The cuboid is connected to the scaphoid by an *interosseous* substance and by *dorsal* and *plantar scapheo-cuboid ligaments*, whose fibres are transverse and oblique. The two bones, also, usually meet by small articular surfaces covered with cartilage, and furnished with a synovial membrane; the latter, however, is sometimes wanting.

The cuboid is connected to the external, or third cuneiform bone, by dorsal, plantar, and interosseous ligaments, and by a synovial membrane, which is in some cases perfect or distinct; in others it communicates with that between the scaphoid and cuneiform bones.

The anterior surface of the scaphoid presents three articular facettes, for the reception of the posterior ends of the *three cuneiform bones.* These facettes are of a triangular form, the bases of the two external are above, that of the internal is below, and a large synovial membrane is common to these three cuneo-scaphoid articulations, also to those between the cuneiform bones themselves, and to those between the bases of the second and third metatarsal bones and the two external cuneiform bones; it also sometimes communicates with the scapheo-cuboid membrane. The three cuneiform bones are connected to the scaphoid by *dorsal ligaments* and by flat bands, transverse and oblique; also by very strong transverse plantar ligaments, which are strengthened by an expansion from the tibialis posticus tendon.

Dislocations of any of the other articulations of the tarsus are very rare, except in very severe accidents, and where complicated injuries are inflicted on the foot; cases, however, are on record of simple dislocation of the cuboid bone from the os calcis, also of the internal cuneiform bone from the navicular in a direction upwards and inwards.

SECTION XXVI.

TARSO-METATARSAL ARTICULATIONS.

The three internal metatarsal bones are joined to the three cuneiform, and the fourth and fifth metatarsal to the cuboid. The tarso-metatarsal articular range presents a slight waving line from without inwards and forwards; but the second metatarsal bone extends further back than the others. This line is sometimes selected for amputation. But little motion exists in any of these amphiarthrodial articulations; they are furnished with synovial membranes and transverse dorsal and plantar bands. The first metatarsal is articulated to the internal cuneiform bone, and possesses a distinct synovial membrane; the second metatarsal is articulated to the three cuneiform, resting on the middle, and wedged in between the internal and external. The third metatarsal bone is articulated to the third cuneiform; and one synovial membrane, continued from the large cuneo-scaphoid and from between the cuneiform bones, is common to these two tarso-metatarsal joints. The fourth and fifth metatarsal bones are connected to the cuboid by a common synovial membrane. All these synovial membranes are prolonged between the bases of the metatarsal bones themselves, as in the metacarpus. The tarso-metatarsal range of articulations is secured by strong transverse ligaments, dorsal and plantar, and by interosseous fibres.

The *metatarso-phalangeal articulations* are arthrodial, and furnished with synovial membranes, protected by dorsal, plantar, and lateral ligaments. The *plantar* or inferior are very thick and fibro-cartilaginous, assist in forming the articular cavity in each joint, and are intimately connected to the sheaths for the flexor tendons. These ligaments are connected to each other by strong transverse fasciculi. The *dorsal ligaments* are weak and thin, but the extensor tendons supply their deficiency. The lateral ligaments are short, strong fasciculi, passing from behind forwards and downwards on each side of this joint. The first or internal metatarso-phalangeal joint is very large and strong, and is rather of the trochlear form ; its inferior ligament is very dense and strong, and usually contains two sesamoid bones.

The *phalanges* of all the toes form ginglymoid joints, and are articulated to each other by synovial membranes and by lateral ligaments, as are those of the fingers, and therefore they do not require any elaborate or distinct description.

The phalanges of the toes are but rarely dislocated, either from each other or from the metatarsal bones : the most frequent accident of this is a dislocation of the first phalanx of the great toe from the metatarsal bone.

APPENDIX.

DIRECTIONS FOR MAKING DRIED PREPARATIONS OF THE ARTERIES AND VEINS.

Although in every anatomical school competent persons are retained for the purpose of injecting arteries and veins, still the student may wish to do it for himself, or he may be placed in such situations that he cannot command any kind of assistance; to him, more particularly, the few remarks which we purpose making on the method of injecting and of preserving arterial preparations, may be considered applicable.

Injections are of two kinds, coarse and fine; there are many descriptions of coarse injections; with the fine we have nothing to do, as it is used by anatomists only for the purpose of imitating the natural vascularity which membranes and other structures lose after death. Coarse injections may be employed either hot or cold: formerly the hot injection was the only one used, but now the cold one is very frequently employed. As much of the success of the injection depends on the state of the subject, great care should be observed in the choice; if possible a young and thin one should always be employed, as the arteries in old subjects are so often ossified and inelastic, that we can never be certain that they will not burst from the force employed, and extravasate the injection between the muscles and into the different cavities: another objection to the use of old subjects is, that the constant oozing of oily matter from preparations made of them renders them filthy, and almost useless, particularly in warm weather; however, some old subjects may be filled with the cold (or paint) injection, if care be taken not to use too much force. When the student has made up his mind to employ the hot injection, it may be useful to him to follow a few rules. In the first place, the pipe should be tied so firmly in the opening into the vessel, that there will be no possibility of its slipping out; secondly, the nozzle of the syringe should always be introduced into the pipe, for the purpose of exhausting the artery of air or coagulated blood; this being done, the stopcock should be immediately turned; and lastly, particular care should be taken that the syringe, pipe, and stopcock, are free and in good order.

To inject with the hot injection, it is necessary that the subject should be thoroughly heated; this is best done by opening the cavities of the thorax and abdomen, and filling them with water of a temperature that the hand can bear; the body at the same time should be immersed in water of the same temperature, taking care to exclude atmospheric air as much as possible. The process of heating should be carried on until the subject has acquired a temperature resembling the natural heat of the living body. While this is going on, the injection should be particularly attended to, as the materials are very inflammable, and if care be not taken, or much heat be employed, there will be danger of burning the chimney or house; heat, slowly applied, will melt the injection without any admixture of air, or endangering the loss of colour, which strong heat would certainly effect. When the subject and injection are sufficiently heated, the latter should be sucked up twice or thrice, so as to mix it well with the colouring matter, which always falls to the bottom. Before the syringe is introduced into the pipe, it should be held up and the piston pressed till the injection appears, by which any air that may be in the syringe will be permitted to escape. Taking the wings of the pipe into the left hand, the syringe is to be introduced, and the piston is to be pushed down slowly and gradually with the right hand, until the syringe is emptied; this action is to be repeated, till we feel resistance made to the further passage of the fluid in the arteries; if, after this resistance is felt, any further force be used, there will be great danger of rupturing the arteries and producing extravasation. As soon as we are satisfied that the body is injected, it should be put in cold water, where it should remain for a few hours. Either of the following hot injections may be used:

Wax, ℥xvi.
Resin, ℥viii.
Turpentine Varnish, ℥viii.
Chinese Vermilion, ℥i.

This makes a very handsome injection, but it is liable to the inconvenience of melting in warm weather, and in this way producing a flattened appearance in blood-vessels. A much cheaper and better injection, for common purposes, than the above has been employed. It is made of,

Tallow, 2lbs.
Magnesia Usta, ℥ss.
Chinese Vermilion, ℥i.

This possesses all the advantages of the wax injection without any of its inconveniences; it is as transparent nearly as the wax, never melts in the hottest weather, and is not disposed to crack. If this injection be used very hot, an extremity may be injected without having been previously heated; but this should never be done except by persons skilled in the art of injecting.

If we wish to trace the minute branches of arteries and examine their various communications, there are no injections better adapted for common purposes than that of tallow and red lead well mixed and heated, or the *cold paint injection*; if the latter be well thrown in, the minutest arteries, for instance the ciliary, will be injected. It is made of—

White lead, well ground, 2lbs.
Turpentine Varnish, ʒxii.
Drying Oil, ℥vi.

The lead is intimately mixed with the varnish, and then the oil is to be added; they are all to be well mixed up together, to the consistence of cream, and in this state it is to be thrown into the arteries; the same precautions, with regard to the exclusion of air from the syringe, and the degree of force to be used, are to be observed in this as well as in the hot injection. Arteries are always injected from the aorta or some other large trunk; while veins are injected differently. In making preparations of veins, it is necessary to inject them from the extreme branches towards the trunks, on account of the direction of the valves; for instance, the veins of the arm are to be injected from a small branch on the back of the hand, and those of the leg and thigh from some branch on the dorsum of the foot. Previously to the injection being made, it is necessary that the veins should be well washed out with warm water, to remove the coagula of blood which they generally contain. If the veins of the arm are to be injected, an opening should be made in the subclavian vein, to allow the warm water and coagula to pass out; when this has happened, a ligature, previously applied, is to be firmly tied round the vessel, which will prevent the injection from flowing out; the same rule applies to the injection of veins in the lower extremity. The veins of the head and neck are generally injected from the superior longitudinal sinus. It is scarcely necessary to mention that veins are filled with blue fluid, and the arteries with white or red; for the blue injection smalt blue is usually employed. To inject the arteries a transverse cut is to be made in the aorta, as close to its origin from the heart as possible. Care must be taken that the extremity of the pipe does not project so far as to pass into the innominata, or one of the vessels arising from the left side of the arch, as this would give only partial injection. The nozzle of the pipe being carefully inserted into the opening of the vessel, two pieces of twine are to be introduced under the vessel; one of these is to be firmly tied round the artery, this will embrace the nozzle of the pipe; its loose extremities, when the knot is firmly tied, are to be fixed to the wings of the pipe, in order to prevent any chance of its slipping out of the vessel. The other ligature is to remain loose under the vessel, beyond the nozzle of the pipe about one inch. After injection is thrown in, this ligature is also to be firmly tied round the vessel, leaving the pipe clear; the use of it is, that the injection may not return back when the pipe is removed from the

aorta. This precaution is more particularly necessary when the paint injection is used. In inserting a pipe into a small artery or vein, some difficulty may arise in the introduction, from the pipe being larger than the calibre of the vessel; in this case the point of a scissors should be introduced into the vessel, and gradual dilatation produced by slowly opening its blades. When the injection has remained sufficiently long to set well in the vessels, dissection may be commenced, and here it is a rule which should be invariably followed, that the dissection be completed in as short a time as is consistent with a proper display of the vessels, for many preparations are lost in consequence of the part first dissected becoming spoiled before the remainder is prepared for drying. Particular care should be taken to remove all the cellular substance from the coats of the vessels; if this be not done, the preparation will always have a dirty appearance. The fatty matter is likewise to be removed, but no muscle is to be taken away or pushed from its situation unless perfectly unavoidable. The student should always remember that the utility of a dried preparation consists in its preserving, as far as possible, the natural relation of parts; on this account, the use of pieces of stick or other substances, to separate the muscles and exhibit the course of the vessels, unless absolutely necessary, is to be condemned. One side of the subject ought to be appropriated to the exhibition of the superficial vessels, the other may be used for the deep-seated. When the dissection is completed, the extremity, or whatever portion of the body it may be, should be hung up in a dry and airy situation (but not exposed to the sun) until the muscles acquire firmness, and no exudation appears on the surface. The preparation, now fit for use, is to be brushed over with copal or mastich varnish, which makes the vessels more distinct, and materially assists in its future preservation.

LAENNEC'S DIVISION OF THE REGIONS OF THE THORAX.

THE chest of a healthy person, when slightly struck, ought to yield over its whole extent a clear and distinct sound. The character of the sound derived from percussion is different in the different parts of the chest; on which account it has been divided by Laennec into fifteen regions, twelve of which are double.

1. *Subclavian Region.*—This includes merely that portion of the chest covered by the clavicle. When struck about the middle or sternal extremity, this bone yields a clear sound, but its humeral extremity gives rather a dull sound. A knowledge of the morbid or natural sounds of the chest in this region is of great importance; for from it are usually derived the first signs of the development of tubercles in the lungs, which are often found in the upper and back part of the left lung, even where they exist in no other part of the chest.

2. *Anterior-superior Region.*—This is bounded by the clavicle above, and by the fourth rib (inclusive) below. The sound, though clear, is somewhat less so than over the sternal end of the clavicle.

3. *Mammary Region.*—This begins below the fourth rib, and terminates with the eighth. In the female, the mammary gland, in the male, the inferior edge of the pectoralis major, prevents this region from yielding as good a sound as the anterior-superior region.

4. *Submammary Region.*—This extends from the eighth to the cartilaginous border of the false ribs. On the right side the sound is often dull, caused by the size of the liver; while on the left, the sound is frequently more clear than natural, which is attributed to the presence of the stomach distended with gas.

Sternal Regions: 5. Superior, 6. Middle, and 7. Inferior. The sound is as clear over the whole extent of the sternum, as on the sternal end of the clavicle. However, the inferior region sometimes yields a duller sound, in consequence of the accumulation of fat about the heart.

8. *Axillary Region.*—This extends from the axilla to the fourth rib inclusive. The sound here is naturally clear.

9. *Lateral Region.*—This is bounded by the fourth rib above, and terminates with the eighth. The sound is always good on the left side; on the right side it is altered frequently by the liver rising higher than usual, and compressing the right lung.

10. *Inferior lateral Region.*—This is bounded above by the eighth rib, and terminates at the border of the false ribs. This region also, on account of the liver, yields often a completely dull sound on the right side, while, on the contrary, the left, for reasons before mentioned, gives a clearer sound than natural, even where there be effusion of fluid into the pleura, or where the inferior portion of the left lung be obstructed.

11. *Acromial Region.*—This is comprehended between the clavicle, the upper edge of the trapezius, the head of the humerus, and the lower part of the neck. The soft parts interposed in this place prevent all sound from percussion.

12. *Upper scapular Region.*—This corresponds to the supraspinous fossa of the scapula, and yields hardly any sound on account of the muscle which fills it. The spine of the scapula, which forms the inferior boundary of this region, sometimes yields a faint sound when the arms are strongly compressed across.

13. *Lower scapular Region.*—This corresponds to the infraspinous portion of the scapula. It yields no sound on percussion, because this portion of the scaplua is covered by the infraspinous muscle.

14. *Interscapular Region.*—This includes the space between the dorsal edge of the scapula and the spine, when the arms are crossed on the breast. The muscles of this region necessarily render every sound dull; sometimes, however, in thin persons, it gives a low but distinct sound, if the head be bent and the arms crossed in order to make tense the trapezius and rhomboidei muscles. The spine in this region gives a good sound; as, likewise, that portion of the chest included between the superior dorsal angle of the scapula and the first dorsal vertebra.

15. *Inferior dorsal Region.*—This begins at the level of the inferior angle of the scapula, terminating at the twelfth dorsal vertebra. Percussion of this region should be made in a transverse direction, on the angle of the ribs; in the upper part, the sound is sufficiently good; in the lower it is slight, or often does not exist, especially on the right side, from the presence of the liver; on the left side it frequently gives an unnaturally clear sound, on account of the distended state of the stomach.

OPENING THE CRANIUM, THORAX, AND ABDOMEN.

The operation of opening the cranium with the hammer, as described in a former part of this work, requires less labour and time than that done with a saw, and ought always to be preferred, except in cases where there is a wish to preserve the skull, or in private houses, where the feelings of the relatives are likely to be offended by the noise made with the hammer. When the saw is used, the head is to be placed on a block, the cut is to be carried round in the same direction, and the same precautions observed as described in using the hammer; if much caution be not used, the saw is very likely to lacerate the substance of the brain, owing to the inequality of thickness of the bone. In cases, however, where the head is to be opened for examination into the causes of death, without an intention of pursuing the dissection further, a different mode is generally practised; this is done by making an incision, by the introduction of the point of a knife under the scalp, commencing at one ear, and carried over the vertex to the other; in this way we avoid cutting the hair, which in a female might be troublesome, and the flaps made by the dissection of the scalp, being reflected over the face and neck, prevent those parts from being soiled.

For the purpose of examining the morbid appearances after death in the thorax and abdomen, these cavities are generally opened at the same time; an incision carried down from the top of the sternum, and ending at the symphysis pubis, dividing the integuments, muscles, and peritonæum, will bring the latter cavity into view; next, let the skin and muscles covering the front of the thorax be turned back, which will expose the cartilages connecting the ribs with the sternum; immediately at their point of connexion with the bone, the cartilages are to be cut; in doing this some caution is to be used; if not, the viscera will sometimes be wounded by the point of the knife slipping down further than is intended. Holding the knife horizontally between the thumb and the middle finger, while the forefinger is placed on the back of the instrument as a guide, will always obviate this inconvenience.

In some old subjects, where the cartilages of the ribs are in some degree ossified, they will not yield to the knife, and here a saw is to be employed. All the cartilages, except those of the first ribs, being divided, the sternum may now be raised like the lid of a box, and a

very convenient hinge is made by cutting the articulation of the first joint of the sternum on the inside, directly opposite the second rib: by following this rule the figure of the thorax will be preserved, after the examination is completed, and a view sufficiently extensive for common purposes be obtained of its contents. The practice of making a crucial incision, for the purpose of examining the contents of the abdomen, should always be condemned, and should never supersede the longitudinal, as a view sufficiently extensive for every purpose is obtained by the latter; while the escape of fluids, and the unsightly appearances of the seams produced by the former method, are entirely prevented.

The urinary and generative organs may be removed from the body for examination through the pelvis; and if the integuments in the perinæum, and some of the external organs, be left uninjured, and the several outlets secured, any portion which is interesting as presenting diseased appearances, or which may be required for more accurate examination, may be removed without the external appearance of the body being much disfigured, and without a protusion of any of the remaining viscera.

INDEX.

	Page.
Abdomen . . .	226
deep muscles of . .	290
dissection of . .	184
vessels and nerves of .	280
Abdominal aorta . 282.	419
aponeurosis, anterior .	188
fascia, deep . .	185
fascia, superficial .	184
lymphatic glands .	449
muscles . . .	186
regions . . .	226
ring, external . .	191
ring, internal . .	205
viscera, dissection of .	226
walls, nerves in the .	214
Abducentes nerves, . 527.	533
Abductor indicis muscle .	180
minimi digiti muscle .	178
minimi digiti pedis .	397
oculi . . .	628
pollicis muscle . .	177
pollicis longus muscle	174
pollicis pedis . .	396
Aberration, chromatic .	664
from parallax . .	663
from sphericity . .	663
Absorbent system . .	446
Accelerator urinæ muscle .	309
Accessorii musculi (dorsal)	143
Accessorius muscle . .	398
Accessorius nervus . 528.	546
Acervulus . . .	486
Acetabulum . . .	766
Achilles, tendon of . .	391
Acini of Malpighi . .	269
Acromial thoracic artery .	415
Acromion process . .	786
Adipose tissue . . .	598
tissue, medullary .	599
Adductor brevis muscle .	369
longus muscle . .	369
magnus muscle . .	370
minimi digiti muscle .	178
oculi muscle . .	627
pollicis muscle . .	178
pollicis pedis . .	399
Alæ vespertilionis . .	351
Alar, cartilages of nose .	601
ligaments . .	849
Albugineal membrane of the eye . . .	629
Alimentary canal . .	238
Alveolar process . .	739
Ammonis cornu . .	485
Amphiarthrosis . .	800
Ampullæ of the mammary gland . . .	76
of semicircular canals .	681
Amygdala, or tonsil . .	52
Anal fascia . . 307.	319
Anal region . . .	307
Anastomotica magna artery of thigh . .	426
Anastomotica artery of arm	417
Anconæus muscle . .	173
Andersch, ganglion of .	543
Angular processes of frontal bone . . .	720
Ankle, external . .	780
internal . . .	778

Page.
Ankle-joint 856
joint, dislocation of . 859
Annular ligament of ankle, anterior . . . 384
ligament of ankle, external . . . 384
ligament of ankle, internal . . . 384
ligaments of the wrist . 162
protuberance . . 491
Annulus ovalis . . . 111
Anterior auris muscle . 5
mediastinum . . 86
Anticubital fossa . . 162
Antihelix 666
Antiprostatic glands . . 312
Antitragus . . . 667
Antitragicus muscle . . 668
Antrum highmorianum . 738
pylori . . . 240
Anus 305
Aorta 405
abdominal . . 282. 419
arch of . . 120. 406
ascending . . . 407
descending . . 407
great sinus of . . 120
opening of . . 118
thoracic . . 91. 418
transverse . . 407
Aortic sinuses . . . 407
Aponeurosis, abdominal, anterior . . . 188
brachial . . . 149
cervical . . . 135
dorsal . . . 141
epicranial . . . 2
of the fascia lata . 185
femoral . . . 362
lumbar . . . 135
pharyngeal . . 46
temporal . . . 17
Apparatus, lachrymal . 622
ligamentosus . . 806
Appendices epiploicæ . 236. 258
Appendix, auricular, left . 116
auricular, right . . 110

Page.
Appendix to the ileum . 248
vermiformis . . 249
Aqua Cotunnii . . 683
Aqua Morgagni . . 659
Aqueduct of the cochlea . 683
of Fallopius . . 726
of Sylvius . . 488
of the vestibule . . 680
Aqueous humour . . 658
humour, membrane of 647. 658
Arachnoid canal . . 466
membrane, cranial . 464
membrane, pathology of the . . . 522
membrane, spinal . 505
Arantii corpora . 114. 119
Arbor vitæ cerebelli . . 499
Arbor vitæ uterina . . 354
Arch of the aorta . . 120
femoral or crural 192. 222
palmar superficial . 417
palmar deep . . 418
superciliary . . 719
Arches of the palate . 49, 50
of pubis . . . 765
Arciform fibres . . 502
Areola 75
Areolar tissue . . . 597
Arm, dissection of . . 149
muscles of . . . 155
Arterial tendinous zone 114. 118
Arteriosus ductus . . 116
Arteries,—general anatomy 403
structure of . . 405
acromial thoracic . 415
anastomotica of arm . 417
anastomotica magna of thigh . . . 426
angular . . . 409
aorta . . . 405
aorta, abdominal 282. 419
aorta, thoracic . . 418
articular of knee . 426
auricular, anterior . 410
auricular, posterior . 410
axillary . . 84. 415

Page.

ARTERIES—*continued.*

azygos, articular . 426
basilar . . 414. 520
brachial . . 159. 416
bronchial . . . 418
buccal . . . 411
callosa . . . 413
capsular . . . 421
carotid, common right 39. 408
carotid, common left 39. 408
carotid, external 39. 408
carotid, internal 411. 520
carpi radialis, dorsal . 418
carpi ulnaris, dorsal . 417
caudal . . . 421
centralis retinæ . . 412
cerebellar, inferior . 520
cerebellar, superior 414. 520
cerebral, anterior 413. 520
cerebral, inferior . 414
cerebral, middle . 413. 520
cerebral, posterior 414. 520
cervicalis, ascendens . 415
cervicalis, profunda . 415
cervicalis, superficialis 415
ciliary, long . . 412
ciliary, posterior . 412
circumflex, anterior . 416
circumflex, external . 425
circumflex ilii, deep 213. 424
circumflex ilii, superficial 425
circumflex, internal . 425
circumflex, posterior . 416
cæliac axis . . 419
colica dextra . 280. 420
colica media . 280. 420
colica sinistra . 281. 421
comes nervi phrenici . 415
communicans cerebri, anterior . 413. 520
communicans cerebri, posterior . 412. 520
coronary . . 121, 122
coronary, left . . 408
coronary, right . . 408
coronary of lips, inferior 409

Page.

ARTERIES—*continued.*

coronary of lips, superior 409
coronary, orifices of . 119
corporis bulbosi . 423
corporis cavernosi . 423
cystic . . 280. 420
dental, inferior . . 411
dental, superior . . 411
digital, of the foot . 427
digital, of the hand . 417
dorsalis carpi radialis . 418
dorsalis carpi ulnaris . 417
dorsalis linguæ . . 409
dorsalis penis . . 423
dorsalis pollicis manus 418
epigastric, internal 209. 213. 424
epigastric, superficial . 425
ethmoidal . . . 412
external carotid . 39. 408
facial . . 21. 409
femoral . . 371. 424
frontal . . . 412
gastric . . 280. 419
gastro-duodenalis 280. 420
gastro-epiploica dextra 280. 420
gastro-epiploica sinistra 280. 420
glandular . . . 409
glutæal . . . 423
hæmorrhoidal, external 423
hæmorrhoidal, middle 423
hæmorrhoidal, superior 281. 421
helecine . . . 341
hepatic . 270. 280. 420
hyoidean, inferior . 409
hyoidean, superior . 409
hypogastric . . 422
ileo-colic . . 280. 420
iliac, common . 282. 421
iliac, external . 282. 424
iliac, internal . 282. 422
ilio-lumbar . . 422
infraorbital . . 411
inguinal . . . 425

Page.

Arteries—*continued.*

innominata . . 408
intercostal . . . 419
intercostal, anterior . 415
intercostal, superior . 415
internal carotid 39. 411. 520
internal maxillary 22. 410
interosseal . . 417
interosseal, anterior . 417
interosseal, posterior . 417
labial, inferior . . 409
lachrymal . . 412
laryngeal . . . 409
lateralis nasi . . 409
lingual . . . 409
lumbar . . 282. 421
malleolar . . . 426
mammary, internal . 415
masseteric . . . 411
maxillary, external . 409
maxillary, internal 22. 410
mediastinal . . 415
meningea media . 410
mesenteric, inferior 280. 421
mesenteric, superior 280. 420
metatarsal . . 426
muscular . . . 409
nasal . . 411, 412
obturator . . . 423
occipital . . . 409
œsophageal . . 418
ophthalmic . 412. 636
palatine, inferior . 409
palatine, superior . 411
palmaris profunda . 418
palmaris superficialis . 417
palpebral . . . 412
pancreatic . . . 280
pancreatico-duodenalis 280. 420
perforating of thigh . 425
pericardiac . . 415
perinæal . . . 423
perinæal, transverse . 423
peroneal . . . 427
peroneal, anterior . 427
peroneal, posterior . 427

Page.

Arteries—*continued.*

pharyngeal ascending . 410
phrenic . . 282. 419
plantar, external . 427
plantar, internal . 427
pollicis magna . . 418
pollicis pedis . . 426
popliteal . . . 426
profunda femoris . 425
profunda, inferior . 417
profunda, superior . 416
pterygoid . . . 411
pudic, internal . . 423
pudic, superficial . 425
pulmonary . . 115
pulmonary, orifice of . 114
pyloric, inferior . . 420
pyloric, superior 280. 420
radial . . 182. 418
radialis indicis . . 418
radial, recurrent . 418
ranine . . 409
renal .. . 282. 421
sacral, lateral . . 422
sacral, middle . 282. 421
scapular, posterior . 415
sciatic . . . 423
sigmoid . . 281. 421
spermatic . . 282. 421
spinal, anterior . 414. 520
spinal, posterior . 414. 520
splenic . . 280. 420
stylo-mastoid . . 410
subclavian . 39. 413
sublingual . . 409
submental . . 409
subscapular . . 416
superficialis volæ . 418
supraorbital . . 412
suprascapular . . 415
tarsal . . . 426
temporal . . 22. 410
temporal, anterior . 410
temporal, deep . . 411
temporal, middle . 410
temporal, posterior . 410
thoracica-acromialis . 415

Page.
ARTERIES—*continued.*
thoracic, long . 416
thoracic, superior . 416
thyroid axis . . 414
thyroid, inferior . . 415
thyroid, superior . 409
tibial, anterior . 389. 426
tibial, posterior . . 427
tibial, recurrent . 426
tonsillitic . . 409
transversalis colli . 415
transversalis faciei 21. 410
transversalis humeri . 415
transversalis perinæi . 423
ulnar . 182. 417
ulnar, recurrent anterior 417
ulnar, recurrent posterior . . . 417
umbilical . . 422. 443
uterine . . . 423
vaginal . . . 423
vasa brevia . . 420
vertebral . . 414. 519
vesical . . . 423
vidian . . . 411
Arthrodia . . . 799
Arthrology . . . 799
Articular arteries (knee) . 426
ARTICULATIONS . . 799
ankle . . . 856
atlanto-axoid . . 808
carpal 831
carpo-metacarpal . 834
costo-clavicular . 816
costo-vertebral . 813
femoro-tibial . . 845
humero-cubital . . 824
humero-scapular . 821
ilio-femoral . . 839
of the larynx . . 61
metacarpo-phalangeal 835
metatarso-phalangeal 864
occipito-atlantal . 805
occipito-axoid . . 806
pelvic . . . 837
phalangeal of the foot 864
phalangeal of hand . 835

Page.
ARTICULATIONS—*continued.*
radio-carpal . . 829
radio-ulnar . . 826
sacro-iliac . . 837
sacro-coccygean . 837
sacro-vertebral . . 836
scapulo-clavicular . 819
sterno-clavicular . 816
tarsal . . . 860
tarso-metatarsal . . 863
temporo-maxillary . 801
tibio-fibular, inferior . 855
tibio-fibular, superior . 855
vertebral, common . 809
Arytenoid cartilages . 59
Arytenoideus muscle . 64
Ascendens colli nerve . 15
Astragalus . . . 781
Atlanto-axoid articulation . 808
Atlas 703
Atrabiliary body . . 288
Attollens aurem muscle . 4
Attrahens aurem muscle . 5
Auditory nerve 528. 543. 685
process, external . 723
Aureum punctum . . 656
Auricle, or external ear . 666
of the heart, left . 116
of the heart, right . 110
muscular fibres of . 126
Auriculæ transversus muscle 668
Auricular appendix, left . 116
appendix, right . . 110
arteries, anterior . 410
artery, posterior . 410
Auricularis magnus nerve . 549
muscle . . . 173
Auricular nerve . 538. 544
nerves, posterior . 542
Auricular veins . . 430
Auriculo-ventricular opening, left . . . 117
Auriculo-ventricular opening, right . . 112
Axilla, dissection of . . 83
lymphatic vesssels and glands of . 84. 448

Page.
Axillary artery . 84. 415
nerves . . . 553
vein . . 83. 436
Axis 704
cæliac . . 280. 419
of cochlea . . . 681
thyroid . . . 414
Azygos articular artery . 426
process of sphenoid bone 729
uvulæ muscle . . 52
vein, major . 91. 282. 434
vein, minor . . 434
vein, superior . . 435

Back, muscles of . . 134
Base of the brain . . 477
Basement membrane . . 267
Basilar artery . . 414. 520
plexus . . . 544
process of occipital bone 714
sinus . . . 464
Basilic vein . 150. 161. 436
Basi-vertebral veins . . 505
Beaumont's observations on digestion . . 244. 246
Bell's muscles of the ureters . . . 328
Bertin, spongy bones of . 729
Biceps muscle . . . 150
flexor cruris muscle . 380
Bichat, canal of . . 466
Bladder, gall . . . 272
urinary . . . 321
coats of . . . 325
ligaments of, false . 322
ligaments of, true . 324
regions of . . . 324
pathology of the . 330
Body, pineal . . . 486
pituitary . . . 479
BONES, chemical composition 693
development . . 697
general observations on 688
number of . . . 689
physical properties . 693
structure of . . 695
astragalus . . 781

Page.
BONES—*continued.*
atlas . . . 703
auditory . . . 676
axis . . . 704
calcis . . . 782
carpal . . . 793
clavicle . . . 785
coccyx . . . 712
costæ . . . 755
cranial . . . 712
cuboid . . . 783
cuneiform of carpus . 794
cuneiform (tarsi) internal . . . 783
cuneiform (tarsi) middle . . . 783
cuneiform (tarsi) external . . . 783
ethmoid . . . 726
facial . . . 736
femur . . . 772
fibula . . . 779
frontal . . . 718
humerus . . . 789
hyoides . . 57. 798
ilium . . . 762
incus . . . 677
innominatum . . 765
irregular . . . 695
ischium . . . 764
lachrymal . . 741
lenticular of ear . 677
long 694
lunar . . . 794
magnum . . . 795
malar . . . 737
malleus . . . 677
maxillary, inferior . 742
maxillary, superior . 737
metacarpal . . 795
metatarsal . . 784
nasal . . . 741
navicular of carpus . 794
navicular of tarsus . 783
occipital . . . 713
orbicular of ear . . 677
palate . . . 739

Page.

BONES—*continued.*
- parietal . . . 716
- patella . . . 776
- pelvic . . . 761
- phalanges manus . 797
- phalanges pedis . 784
- pisiform . . . 795
- planum of ethmoid . 728
- pubis . . . 764
- pyramidal of carpus . 794
- radius . . . 792
- ribs 755
- sacrum . . . 709
- scaphoid of carpus . 794
- scaphoid of tarsus . 783
- scapula . . . 786
- semilunar . . . 794
- sesamoid . . 785. 797
- sphenoid . . . 729
- spongy . . . 727
- spongy of sphenoid bone 729
- stapes . . . 677
- sternum . . . 753
- tarsal . . . 780
- temporal . . . 722
- tibia 776
- trapezium . . . 795
- trapezoid . . . 795
- triquetra . . . 717
- turbinated, inferior . 741
- turbinated, middle . 720
- turbinated, superior . 728
- turbinated, of the sphenoid . . . 729
- ulna 791
- unciform . . . 795
- unguis . . . 741
- vertebræ . . . 699
- vertebræ, cervical . 702
- vertebræ, dorsal . 701
- vertebræ, lumbar . 701
- vomer . . . 742
- Wormian . . . 717

Bowman's researches on the kidney . . . 285
Brachialis anticus muscle . 157
Brachial aponeurosis . . 149

Page.

Brachial artery . 159. 416
- nerve . . . 555
- plexus . 42. 84. 551. 159

Brain, ... 455
- convolutions of . . 474
- dissection of, from below . . . 513
- membranes of . . 455
- motions of . . 468
- pathology of the . 522
- structure of . 472. 513
- vessels of . . 519

Broad ligaments of the uterus 351
Bronchial arteries . . 418
- glands . . 99. 450
- tubes . . . 102

Bruit musculaire . . 131
Brun, glands of . . 256
Buccal artery . . 411
- nerve . . . 538

Buccinator muscle . . 11
Bulb, artery of . . 423
- of the corpus spongiosum . . . 343
- of olfactory nerve . 524

Burn's ligament . . 216
Bursa, carpal . . . 163

Cæcum 249
- structure of . . 258

Calamus scriptorius . . 498
Calcaneum . . . 782
Calyces of the kidney . 286
Calyciform papillæ . . 609
Camper's fascia . . 185
Canal, alimentary . . 238
- of Bichat . . . 466
- of Fontana . . 651
- godroné . . . 662
- Haversian . . 696
- inguinal . . 206
- lachrymal . . 623
- of Nuck . . . 352
- of Petit . . . 662
- semicircular . . 681
- spermatic . . 206

Canine fossa . . . 737

	Page.
Canine teeth	745
Canthi, palpebral	616
Capillary system	404
Capsule of Glisson	267
of aqueous humour	647
supra-renal	288
Capsular arteries	421
ligament of the jaw	803
veins	439
Caput gallinaginis	344
coli	249
Cardia	240
Cardiac ganglion	580
muscles, actions of	130
nerves,	123. 545
nerve, inferior	579, 580
nerve, middle or great	578, 579
nerve, superior	578, 579
plexus	123
plexus, anterior	580
plexus, great	580
plexus, posterior	580
veins	122, 123
Carneæ columnæ	112. 117
Carotid arteries, right and left, common	39. 408
artery, external	39. 408
artery, internal	39. 411. 520
plexus, internal	577
Carpal bones, dislocations of	834
bursa	163
Carpo-metacarpal articulations	834
Carpus, bones of	793
Cartilage	690. 800
chemical composition	693
development	692
structure of	691
arytenoid	59
costal	758
cricoid	59
cuneiform	61
interarticular	800
interarticular of the clavicle	818
interarticular of the jaw	803
Cartilage, interarticular scapulo-clavicular	819
interarticular of the wrist	828
of the nose	600
palpebral	619
semilunar	851
tarsal	619
thyroid	58
xiphoid	754
Caruncula lachrymalis	617. 620
Carunculæ myrtiformes	349
Casserian ganglion	527
Cauda equina	507
Caudal artery	421
Cava vena, inferior	438
superior	433
Cavernous plexus	577
sinus	463
Cells, ethmoid	728
mastoid	675
Cellular tissue	597
Centrum ovale magnum	480
ovale minus	480
Cephalic vein	149. 161. 435
Cerebellum	492
function of	518
Cerebellar artery, inferior	414. 520
artery, superior	414. 520
Cerebral artery, anterior	413. 520
artery, communicating anterior	413
artery, communicating posterior	412
artery, middle	413. 520
artery, posterior	414. 520
granulations	462
nerves, dissection of	530
nerves, origins of	523
Cerebro-spinal axis	456
Cerebrum, dissection of	473
inferior surface of	477
lobes of	477
Cerumen	670
Ceruminous glands	594. 670
Cervical aponeurosis	135

Page.

Cervical artery, ascending . 415
artery, superficialis . 415
artery, profunda . 415
fascia, deep . . 27
fascia, superficial . 27
ganglions . . . 576
ganglion, inferior 41. 578
ganglion, middle 41. 578
ganglion, superior 41. 576
glands . . . 448
nerves, spinal . 41. 548
plexus . . 41. 549
plexus posterior . . 551
Cervicalis ascendens muscle 143
descendens muscle . 143
Cervico-facial nerve . . 542
thoracic septum . 28
Chamber of the eye, anterior 658
of the eye, posterior . 658
Check ligaments . . 807
Cheeks 42
Chiasma 524
Chordæ tendineæ . 113. 117
vocales . . . 62
Chorion 592
Choroid coat of the eye . 647
membrane . . . 485
plexus . . . 483
plexus of the fourth ventricle . 469. 496
plexus of lateral ventricles 470
plexus of the third ventricle . . . 486
Chromatic aberration . 664
Cilia 618
Ciliary artery, long . . 412
artery, posterior . 412
disk . . . 652. 661
ligament . . . 650
nerves . . 533, 534
processes . . . 651
Circle of Willis 414. 519, 520
Circular sinus . . . 464
Circulation, adult . 110. 403
fœtal 440
Circumflex artery, anterior 416
artery, external . . 425

Page.

Circumflex artery, internal . 425
artery, posterior . 416
ilii artery, deep . 213. 424
ilii artery, superficial . 425
nerve 554
Clavicle, ... 785
dislocations of . . 820
Clinoid processes of sphenoid 730
Clitoris 347
Cochlea 681
Cochlear nerve . . . 685
Coccygeal ganglion . 575. 584
Coccyx 712
Cœliac axis . . 280. 419
plexus . . 92. 281
Colic artery, left . 281. 421
artery, middle . 280. 420
artery, right . 280. 420
omentum . . . 236
Colles's fascia . . . 194
Colon 251
structure of . . 258
Colouring matter of skin . 591
Columella . . . 672
Column, vertebral . . 706
Columnæ carneæ . 112. 117
vaginæ . . . 351
Commissure, cerebro-cerebellar . . . 499
of the cerebellum, great 491
of the cerebrum, anterior 489
of the cerebrum, posterior 489
of the cerebrum, great inferior . . . 485
of the cerebrum, great superior . . 481
intercerebral . . 499
optic . . . 524
soft 488
spinal, anterior . . 508
spinal, posterior . . 508
superior longitudinal . 475
Communicans noni nerve . 550
peronei nerve . . 571
tibialis nerve . 383. 573
Communicating nerve, lumbar . . . 567

	Page.
Complexus muscle . .	144
Compressor nasi muscle .	8
penis muscle . .	308
urethræ muscle . .	314
urethræ transversus .	315
venæ dorsalis penis muscle . . .	310
Conarium . . .	486
Concha	668
Conglobate glands . .	447
Coni vasculosi . . .	335
Conjoined tendons . .	195
Conjunctiva . . .	620
structure of . .	621
Conoid ligament . .	820
Constrictor iridis . .	654
isthmi faucium muscle	52
pharyngis inferior muscle	46
pharyngis medius muscle	47
pharyngis superior muscle	48
Conus arteriosus . .	114
Converging fibres . .	514
Convolution, hem-like .	474
Coraco-brachialis muscle .	155
clavicular fascia . .	820
clavicular ligament .	80
Cord, spermatic . .	336
spermatic, tunica vaginalis of . . .	206
Corda tympani nerve 536. 541.	676
Cordæ Willisii . . .	462
Cordiform tendon of diaphragm . . .	294
Cornea	645
elastic . . .	647
Cornicula Santorini . .	60
Cornu Ammonis . .	485
Cornua of the vestibule .	680
of the lateral ventricles	482
Corona ciliaris . . .	661
Corona glandis . . .	343
Coronal suture . . .	732
Coronary arteries, orifices of	119
arteries . 121, 122.	408
arteries of lips . .	409
Coronary ligament of the liver . . .	264
Coronary ligament of the knee	851
plexuses . . 123.	580
sinus . . .	112
valve . . .	112
vein	122
Coronoid process of lower jaw-bone . .	743
process of ulna . .	791
Corpora albicantia . .	480
Arantii . . 114.	119
cavernosa penis . .	340
mammillaria . .	480
olivaria . . 501.	516
Pacchioni . . .	462
pisiformia . . .	480
pyramidalia . 501.	515
quadrigemina . .	490
restiformia . . 502.	515
striata . . .	482
Corpus callosum . .	481
cavernosum . .	340
cavernosum, artery of	423
dentatum . . .	499
denticulatum . .	485
fimbriatum . 356.	485
geniculatum externum	487
geniculatum internum	487
Highmorianum . .	334
luteum . . .	357
pampiniforme . .	337
psalloides . . .	484
rhomboideum . .	499
spongiosum urethræ .	343
striatum . . .	482
Corpuscles of Malphigi .	285
of Pacini . . .	557
Corrugator supercilii muscle	8
Costæ	755
Costal cartilages . .	758
Costo-clavicular articulation	816
clavicular fascia . .	820
coracoid ligament .	80
sternal ligaments .	816
transverse ligaments .	815
Cotunnii aqua . . .	683
Cotunnius, nerve of . .	536
Cotyloid cavity . . .	766

Page.
Cotyloid ligament . . 842
Cowper's glands . . 312
Cranial sinuses . . . 461
Cranium 712
Cremaster muscle . . 195
Cribriform fascia . 217. 363
plate of ethmoid bone . 726
Cricoid cartilage . . 59
Crico-arytenoideus lateralis
muscle . . . 64
arytenoideus posticus
muscle . . . 64
thyroid ligament . 62
thyroideus muscle . 63
Crista galli . . . 727
Crura cerebelli . . . 500
cerebri . 480. 489. 516
of diaphragm . . 294
penis . . . 340
Cruræus muscle . . 368
Crural arch . . 192. 222
hernia . . . 214
nerve, anterior . . 563
nerve, posterior . . 570
ring 223
septum . . 212. 219
Crusta petrosa . . . 747
Crystalline humour, or lens 658
Cuboid bone . . . 783
Cuneiform bone of carpus . 794
bones of tarsus . . 783
cartilages . . . 61
Cupola 682
Cutaneous nerve of arm, external . . . 555
nerve of arm, internal 554
nerve of arm, lesser . 555
nerves of back, inferior 559
nerves of back, superior 559
nerves of the leg, external . . . 571
nerves of the leg, internal . . . 565
nerves of the leg, posterior . . 573
nerve of thigh, posterior 569
Cuticle 589

Page.
Cutis vera . . . 592
Cystic artery . . 280. 420
duct 272

Dartos 331
Decussating fasciculi . . 501
Deglutition, stages of . 53
Deltoid ligament of the ankle 857
ligament of the scapula . . . 820
muscle . . . 150
nerve . . . 554
Demours, membrane of . 646
Dental artery, inferior . 411
arteries, superior . 411
nerves, anterior . . 537
nerve, inferior . . 538
nerves, posterior . 537
nerves, superior . . 537
pulp 748
Dentine 747
Depressor anguli oris muscle 10
labii inferioris muscle . 10
labii superioris alæque
nasi muscle . . 10
oculi muscle . . 628
Dermis 592
Descendens colli nerve . 547
Descendens noni nerve 410. 547
Desipimenta testis . . 334
Detrusor urinæ . . 325
Diaphragm . . . 290
openings in . . 295
Diarthrosis . . . 799
Diastole 130
Digastricus muscle . . 33
Digastric nerve . . . 542
region . . . 34
Digestive organs . . 238
Digital arteries of the foot . 427
arteries of the hand . 417
cavity . . . 482
nerves of fingers . 556
nerves of toes . . 574
Dimensions of pelvis (Meckel) 771
Diploe 695
Diploic veins . . . 430

Page.
Disk, ciliary . . 652. 661
Dislocations of the ankle . 859
of carpal bones . . 834
of the clavicle . . 820
of elbow-joint . . 827
of fibula, head of . 855
of the hip-joint . . 843
of the humerus . . 823
of inferior radio ulnar joint . . . 829
of the knee-joint . 854
of lower jaw . 21. 804
of the metacarpal bones from the carpus . 834
of the patella . . 853
of the phalanges of the foot . . . 864
of the ribs . . 816
of semilunar cartilages 854
of the tarsal bones . 863
of thumb . . 835
of the vertebræ . . 813
of the wrist . . 831
Diverging fibres . . 514
Diverticulum ilei . . 248
Dorsal aponeurosis . . 141
nerves . . . 558
nerve, first . . 560
nerves of the foot . 571
Dorsalis carpi radialis artery 418
carpi ulnaris artery . 417
carpi ulnaris nerve . 557
linguæ artery . . 409
pollicis manus artery . 418
Dorso-lumbar nerve . . 560
Duct, cystic . . . 272
hepatic . . . 271
lachrymal . 617. 623
lymphatic, right . 454
nasal . . . 624
of the pancreas . . 279
of parotid gland . 14
of the prostate . . 339
of submaxillary gland 35
thoracic . 91. 283. 452
of Wharton . . 35
Ductus arteriosus . 116. 443

Page.
Ductus choledochus communis . . 271
ejaculatorius communis 336, 337
venosus . . . 442
Duodenum . . . 246
structure of . . 254
Dura mater, artery of, middle .410
mater, cranial . . 457
mater, pathology of the 521
mater, spinal . . 504

Ear, anatomy of . . 665
external . . . 666
internal . . . 679
middle . . . 670
muscles of . . 4, 5
external, muscles of . 668
Eighth pair of nerves 40. 528 543
Ejaculator seminis muscle . 309
Ejaculatory duct . . 336
Elastic cornea . . . 647
Elbow-joint . . . 824
dislocations of . . 827
Eminence, ilio-pectinæal . 763
jugular . . . 715
Eminentia pyramidalis . 681
Emulgent veins . . 439
Enamel 746
Enarthrosis . . . 799
Encephalon . . . 456
Endocarde . . . 121
Endolymph . . . 684
Epicranial aponeurosis . 2
Epidermis . . . 589
Epididymis . . . 335
Epigastric artery, deep or internal . 209. 213. 424
artery, superficial . 425
region . . . 226
Epiglottic gland . . 61
Epiglottis . . . 60
Epithelium . . 260. 591
Erectile tissue . . . 340
Erector clitoridis muscle . 349
penis muscle . . 308
Ethmoid bone . . . 726

	Page.
Ethmoid cells . . .	728
Ethmoidal artery . .	412
suture . . .	732
Eustachian tube . 49.	675
valve . . 111.	442
Excito-motor function .	510
Expiration . . .	299
External carotid artery 15. 21. 39.	408
jugular vein . . 15.	26
Extensor carpi radialis brevis muscle . .	172
carpi radialis longus muscle . . .	117
carpi ulnaris muscle .	172
digitorum brevis pedis	388
digitorum communis muscle . . .	172
digitorum longus pedis muscle . . .	387
indicis muscle . .	175
minimi digiti muscle .	173
ossis metacarpi pollicis muscle . . .	174
pollicis proprius pedis muscle . .	387
pollicis major muscle .	175
pollicis minor muscle .	174
primi internodii pollicis muscle . . .	174
secundi internodii pollicis muscle . . .	175
Extremity, inferior, dissection of . . .	361
superior, dissection of .	148
Eye	640
brows . . .	616
chambers of . .	642
coats of . . .	641
globe of . . .	640
humours of . .	641
lashes . . .	618
lids	616
motions of . 630.	633
Face, bones of . .	736
muscles of . .	6
Face, vessels and nerves of	21
Facial artery . . .	409
artery, transverse .	410
nerve . 527. 540.	686
vein . . 21.	430
Falciform ligament of liver .	263
process of fascia lata 217.	363
process of great sacro-sciatic ligament .	837
Fallopian tubes . . .	356
Fallopii hiatus . . .	726
Fallopius, aqueduct of .	726
ligament of . .	192
Falx cerebelli . . .	461
cerebri . . .	458
Fascia, abdominal, deep .	185
abdominal, superficial .	184
anal . . 307.	319
Camper's . . .	185
cervical, deep . .	27
cervical, superficial .	27
Colles's . . .	194
costo-clavicular .	820
costo-coracoid . 80.	820
cribriform . 217.	363
dentata . . .	485
of the forearm . .	162
iliaca . . .	220
infraspinous . .	148
infundibuliform .	205
intercolumnar . .	192
ischio-rectal . 307.	319
lata . . 216.	362
lata, aponeurosis of .	185
of the leg . .	384
lumbar . . 135.	198
obturator . . 308.	319
ocular . . .	628
palmar . . .	163
pelvic . . .	319
perinæal, deep . 307.	311
perinæal, middle .	307
perinæal, superficial .	306
plantar . . .	385
prevertebral . .	28
propria of femoral hernia . . 212.	219

Page.

Fascia, propria of inguinal hernia . . . 207
rectal . . 314. 320
recto-vesical . 312. 320
Scarpa's . . . 185
semilunar . . . 156
spermatic . . 192. 332
subpleural . . 89
subscapular . . 149
supraspinous . . 148
temporal . . . 17
transversalis . . 203
triangular . . 194
vesical . . . 320
Fat 598
Faucium isthmus . 42. 49
Femoral aponeurosis . . 362
arch 192
artery . . 371. 424
hernia . . . 214
hernia, coverings of . 224
hernia, fascia propria of 212. 219
hernia, mode of descent of 224
ring 223
vein 437
vessels, sheath of, anterior . . 205. 222
vessels, sheath of, posterior . . . 221
Femur 772
Fenestra cochleæ . . 675
ovalis . . . 674
rotunda . . . 675
vestibuli . . . 674
Ferrein, tubes of . . 285
Fibro-cartilage . . 690. 800
interarticular of the clavicle . . . 818
interarticular of the jaw 803
interarticular, scapulo-clavicular . . 819
interarticular of the wrist 828
intervertebral . . 810
of the nose . . 600
semilunar . . 851

Page.

Fibula 779
Filamentous tissue . . 597
Fimbriæ of Fallopian tubes 356
Fingers, bones of . . 797
Fissures, Glaserian . . 723
of the liver . . 265
purse-like, of cerebellum 492
of Sylvius . . . 478
transverse, of cerebrum 470
Flexor brevis minimi digiti muscle . . . 178
brevis minimi digiti pedis . . . 400
carpi radialis muscle . 165
carpi ulnaris muscle . 166
digitorum brevis pedis 397
digitorum longus pedis 394
digitorum profundus perforans muscle . 168
digitorum sublimis perforatus muscle . 166
ossis metacarpi pollicis muscle . . . 177
pollicis brevis muscle . 177
pollicis longus muscle 169
pollicis pedis brevis . 399
pollicis pedis longus . 395
tendons, sheaths for . 167
Flocculus . . . 494
Flood's ligament . . 822
Fluid of Scarpa . . 684
Fluid, subarachnoid . . 467
subarachnoid, spinal . 506
Fœtal circulation . . 440
Follicles, hair . . . 596
of Lieberkühn . . 256
Meibomian . 594. 619
Fontana, canal of . . 651
Fontanelle . . . 717
Foot, bones of . . . 780
dissection of . . 396
Foramen cæcum . 607. 609
commune anterius . 485
commune posterius . 488
incisivum . . . 739
lacerum orbitale . 731

Page.

Foramen magnum . . 714
  obturator . . . 767
  ovale . . 111. 442
  rotundum cochleæ . 675
  of Soemerring . . 656
  thyroid . . . 767
  of Winslow . . 236
Foramina Thebesii . . 112
Forearm, dissection of . 160
  fascia of . . . 162
Fornix 484
Fossa, anticubital . . 162
  canine . . . 737
  innominata . . 666
  myrtiform . . 739
  navicular of ear . . 666
  navicularis urethræ . 344
  ovalis . . . 111
  scaphoid of ear . . 666
Fovea elliptica . . . 681
  hemispherica . . 680
Fourchette . . . 347
Frænum epiglottidis . . 63
  linguæ . . . 43
  of the lips . . 43
  præputii . . . 339
Frontal artery . . . 412
  bone . . . 718
  nerve . . 22. 533
  sinuses . . . 721
  vein 430
Function, excito-motor . . 510

Galen, veins of . . 470. 485
Galeni vena, heart . . 123
Gall-bladder . . . 272
  pathology of the . 277
Ganglia, dissection of the . 574
  structure of . . 585
  of Andersch . . 543
  Arnold's . . . 539
  cardiac . . . 580
  carotid . . . 577
  Casserian . . . 527
  of cerebellum . . 499
  of the cerebrum, anterior . . . 483

Page.

Ganglia of the cerebrum, great posterior . 487
  of the cerebrum, superior . . . 483
  cervical . . . 576
  cervical, inferior 41. 578
  cervical, middle . 41. 578
  cervical, superior 41. 576
  coccygæal . 575. 584
  impar . . 575. 584
  jugular . . . 543
  lenticular . . . 534
  lumbar . . . 583
  Meckel's . . . 535
  naso-palatine . . 536
  olivary . . . 501
  ophthalmic . . 534
  otic 539
  petrous . . . 543
  pneumogastric, inferior 544
  pneumogastric, superior 544
  of Ribes . . . 521
  sacral . . . 584
  semilunar, abdominis 91. 281. 582
  spheno-palatine . . 535
  submaxillary . . 536
  thoracic . . . 581
Gastric artery . . 280. 419
  plexus . . . 582
Gastro-colic, or great omentum . . . 234
  duodenalis artery 280. 420
  epiploica dextra artery 280. 420
  sinistra artery . 280. 420
  hepatic, or lesser omentum . . . 234
Gastrocnemius muscle . 390
Gemellus muscle, inferior . 377
  muscle, superior . 377
Generative organs, female . 347
  organs, female, pathology of the . . 358
  organs, male . . 331
  organs, male, pathology of the . . . 345

	Page.
Genio-hyo-glossi muscles 37.	607
hyoideus muscle	35
Genito-crural nerve	563
Germinal spot (Wagner)	357
vesicle (Purkinjie)	357
Gimbernaut's ligament	193
Ginglymus	799
Glands, arrangement of	13
aggregate	256
antiprostatic	312
axillary	448
Brunner's	256
ceruminous 594.	670
cervical	448
conglobate	447
conglomerate	13
of Cowper	312
duodenal	256
epiglottic	61
gastric	244
of Harder	621
of Havers	801
inguinal	449
inguinal, deep-seated lymphatic	362
inguinal, superficial lymphatic	362
lachrymal	622
lingual	609
lymphatic	447
lymphatic, abdominal	449
lymphatic, inguinal	216
lymphatic thoracic	449
mammary	74
Meibomian 594.	619
odoriferous	595
parotid	14
parotid, pathology of	16
pelvic	449
Peyer's	256
pineal	486
pituitary	479
prostate	338
salivary	12
sebaceous	594
solitary	256
sublingual	36

	Page.
Glands, submaxillary	34
sudoriferous	594
thymus	445
thyroid	32
vulvo-vaginal	348
Glandulæ agminatæ	256
Brunneri	256
odoriferæ	340
Pacchioni	462
Peyeri	256
solitariæ, or sparsæ	256
Tysoni	340
Glans clitoridis	348
penis	343
Glasserian fissure	723
Glenoid cavity of scapula	788
cavity of temporal bone	723
ligament	821
Glisson, capsule of	267
Globe of the eye, dissection of	640
Globus, epididymis major	335
epididymis minor	335
Glosso-epiglottic ligament	60
pharyngeal nerve 40. 528.	543
Glottis, opening of the 49.	67
Glutæal artery	423
nerve, inferior	569
nerve, superior	567
Glutæus maximus muscle	374
medius muscle	376
minimus muscle	376
Gomphosis	800
Graafian vesicles	357
Gracilis muscle	368
Gubernacula dentium	749
Gums	42
Gustatory nerve 40.	539
Guthrie's muscles	315
Habenæ of pineal body	486
Hæmorrhoidal arteries, external	423
arteries, middle	423
artery, superior 281.	421
plexus	583

	Page.
Hairs	596
Hamular process of sphenoid bone	731
Hamulus laminæ spiralis	682
Hand, bones of	793
characters of	175
dissection of	160
muscles of	175
Harder, gland of	621
Harmonia	800
Haunch bone	765
Haversian canals	696
glands	801
Head, bones of	712
external parts of	1
Hearing, organ of	665
sense of	665
Heart	107
Heart's action, frequency of	132
Heart, auricle of, left	116
auricle of, right	110
cavities of	110
muscular tissue of	124
nerves of	123
pathology of the	132
position of	108
sounds of	131
surfaces of	108
tissues entering into the composition of	120
ventricle of, left	117
ventricle of, right	112
Helecine arteries	341
Helicis major muscle	668
minor muscle	668
Helicotrema	683
Helix	666
Hepatic artery	270. 280. 420
ducts	271
plexus	582
veins	270. 439
Hernia, congenital	333
femoral, or crural	214
femoral, coverings of	224
femoral, fascia propria of	212. 219
femoral, mode of descent of	224
Hernia, inguinal direct	209
inguinal direct inferior	210
inguinal direct superior	210
inguinal oblique	207
umbilical	190
ventro-inguinal	209
Herophili torcular	464
Hey's ligament	217
Hiatus Fallopii	726
Highmore, antrum of	738
Hilton's muscle	65
Hilus of kidney	284
of spleen	277
Hip-joint	839
joint, dislocations of	843
muscles of	374
Hippocampus major	485
minor	485
Hirundinis nidus	497
Horner's muscle	8
Houston's muscles	310
Humerus, dislocation of	823
Humeri os	789
Humour, of the eye, aqueous	658
aqueous, capsule of	647
of the eye, crystalline	658
of the eye, vitreous	661
Hyaloid body	661
capsule or membrane	661
Hydrocephalus externus	522
internus	522
Hymen	349
Hyo-epiglottic ligament	60
glossal ligament	606
glossus muscle	37. 607
pharyngeus muscle	47
thyroid ligaments	61
Hyoid bone	57. 798
Hypochondriac regions	226
Hypogastric artery	422
plexus	584
region	226
Ileo-cæcal valve	250
colic artery	280. 420
colic valve	250
Ileum	247

Page.
Ileum, diverticulum of . 248
structure of . . 254
Iliac arteries, common 421. 282
artery, external . 424. 282
artery, internal . 422. 282
fascia . . . 220
fossæ . . . 763
regions . . . 226
vein, common . 282. 438
vein, external . 282. 437
vein, internal . 282. 438
Iliacus internus muscle . 303
Ilio-femoral articulation . 839
lumbar artery . . 422
pectinæal eminence . 763
pectinæal line . . 763
scrotal nerve . . 562
Ilium 762
Incisor teeth . . . 745
Incisuræ Santorini . . 669
Incus 677
Indicator muscle . . 175
Inferior extremities, dissection of . . . 361
maxillary nerve . 537
Infraclavicular nerves . 553
Infraorbital nerve . 23. 537
orbital artery . . 411
spinous fascia . . 148
spinous ligaments . 812
spinatus muscle . 152
trochleator nerve . 533
Infundibula of the kidney . 287
Infundibuliform fascia . 205
Infundibulum . . 479. 488
Infundibulum cochleæ . 682
of ethmoid bone . . 728
Infundibulum of right ventricle . . . 114
Ingrassius, wing of . . 730
Inguinal arteries . . 425
canal . . . 206
glands . . . 449
hernia congenital . 333
hernia direct . . 209
hernia, direct inferior . 210
hernia, direct superior . 210

Page.
Inguinal hernia, oblique . 207
lymphatic glands . 216
lymphatic glands, deep 362
lymphatic glands, superficial . . 362
pouches . 209. 212. 228
region . 215. 227
ring, external . . 191
ring, internal . . 205
Inguino-cutaneous nerves . 562
Innominata artery . . 408
Innominatæ venæ . 98. 433
Inspiration . . . 298
Interarticular cartilage of the clavicle . . 818
fibro-cartilage of the jaw . . . 803
fibro-cartilage of the wrist . . . 828
Intercolumnar fascia . . 192
Intercostal arteries . . 419
artery, superior . . 415
muscles . . . 82
nerves . . . 559
veins . . . 435
Intercosto-humeral nerves . 560
Intercrural lamina . . 480
Intermaxillary ligament 11. 802
Intermuscular ligaments . 149
Internal maxillary artery 22. 410
Interosseal artery . . 417
artery, anterior . . 417
artery, posterior . 417
nerve of arm, anterior . 556
nerve of arm, posterior. 558
nerve of leg . . 572
Interossei muscles of the hand . . . 179
pedis inferiores muscles 400
pedis superiores muscles . . . 401
Interspinales muscles . . 145
Interspinous ligaments . 813
Intertransversales muscles . 145
Intertransverse ligaments . 813
Intervertebral fibro-cartilages . . . 810

	Page.
Intestinal canal	240
canal, pathology of the	262
coats of	253
glands of	256
Iris	652
Ischio-bulbosus muscle	310
Ischio-rectal fascia	307. 319
region	307
Ischium	764
Island of Reil	475. 479
Isthmus faucium	42
Iter ad quartum ventriculum	488
Itinera dentium	749
Ivory	747
Jacob's membrane	656
Jacobson's nerve	543
Jaw, lower	742
lower, dislocations of	21. 804
lower, motions of	20. 804
Jejunum	247
structure of	254
Joints	799
ankle	856
atlanto-axoid	808
carpal	831
carpo-metacarpal	834
costo-clavicular	816
costo-vertebral	813
elbow	824
femoro-tibial	845
hip	839
humero-cubital	824
humero-scapular	821
ilio-femoral	839
jaw, lower	801
knee	845
metacarpo-phalangeal	835
metatarso-phalangeal	864
occipito-atlantal	805
occipito-axoid	806
pelvic	837
phalangeal of the foot	864
phalangeal of the hand	835
radio-carpal	829
radio-ulnar	826

	Page.
Joints, sacro-coccygean	837
sacro-iliac	837
sacro-vertebral	836
scapulo-clavicular	819
shoulder	821
sterno-clavicular	816
tarsal	860
tarso-metatarsal	863
tibio-fibular, inferior	855
tibio-fibular, superior	855
vertebral	809
wrist	829
Jugular eminence	715
ganglion	543
vein, anterior	432
vein, external	15. 431
vein, internal	40. 432
Kidney	283
pathology of the	289
Kiernan's researches on the liver	268
Knee-joint	845
Labia majora	347
minora	347
Labial artery	409
Labyrinth	679
membraneous	683
Lachrymal apparatus	622
artery	412
bone	741
canals	617. 623
caruncle	617. 620
ducts	617. 623
gland	622
nerve	532
papilla	617
puncta	617. 623
sac	624
Lacteals	446
Lacuna magna urethræ	345
Lacus lachrymalis	617
Lambdoid suture	732
Lamina cornea	483
cribrosa oculi	644
intercrural	480

Page.
Lamina serosa retinæ . . 656
spiralis . . . 682
vasculosa retinæ . 657
Laryngeal artery . . 409
nerves . . . 68
nerve, inferior . 41. 545
nerve, recurrent . 545
nerve, superior . . 545
Larynx 57
articulations of . . 61
pathology of the . 70
ventricle of . . 68
Lateral sinuses . . . 463
Latissimus colli muscle . 26
dorsi muscle . . 138
Laxator tympani, major . 678
tympani, minor . . 679
Leg, dissection of . . 383
Lens, crystalline . . 658
Lenticular ganglion . . 534
Levator anguli oris muscle . 9
anguli scapulæ muscle 140
ani muscle . . . 313
glandulæ thyroideæ muscle . . . 32
labii inferioris muscle . 10
labii superioris alæque nasi muscle . . 9
menti muscle . . 10
oculi muscle . . 627
palati muscle . . 51
palpebræ superioris muscle . . . 625
Levatores costarum muscles. 82
urethræ muscles . 314
Lieberkühn, follicles of . 256
Lieutand, septum of . 113. 118
Ligaments . . . 801
accessory, of the hip-joint . . . 841
accessory, of the shoulder . . . 822
acromio-clavicular, inferior . . . 819
acromio-clavicular, superior . . . 819
adipose . . . 849

Page
Ligaments—*continued.*
alar . . . 849
annular, of ankle, anterior . . . 384
annular, of ankle, external . . . 384
annular, of ankle, internal . . . 384
annular, of the radius . 826
annular, of the wrist 162. 833
arcuatum, externum . 293
arcuatum, internum . 293
astragalo-scaphoid . 861
atlanto-axoid, anterior 809
atlanto-axoid, posterior 809
auricular . . . 668
of bladder, false . . 322
of bladder, true . . 324
Burn's . . . 216
calceo-astragaloid . 860
calceo-cuboid, inferior 862
calceo-cuboid, superior 862
calceo-scaphoid, inferior 861
calceo-scaphoid, superior . . . 862
capsular, atlanto-axoid 809
capsular, of the hip . 839
capsular, of the jaw . 803
capsular, occipito-atlantal . . . 805
capsular, of the rib . 813
capsular, of the shoulder 821
capsular, of the thumb 834
carpo-metacarpal, dorsal . . . 834
carpo-metacarpal, interosseous . . 834
carpo-metacarpal, palmar . . . 834
carpus, dorsal . . 831
carpus, interosseous . 831
carpus, palmar . . 831
check . . . 807
ciliary . . . 650
conoid . . . 820
coraco-acromial . 80. 820
coraco-clavicular 80. 820

Page.

LIGAMENTS—*continued.*
coraco-humeral . . 822
coracoid . . . 821
coronary, of the knee . 851
coronary, of the liver . 264
costo-clavicular . . 817
costo-coracoid . 80. 820
costo-transverse, anterior . . . 815
costo-transverse, middle . . . 815
costo-transverse, posterior . . . 815
costo-vertebral, anterior . . . 813
cotyloid . . . 842
crico-thyroid . . 62
crucial, anterior . 850
crucial, posterior . 851
cuneo-scaphoid . 863
deltoid of the ankle . 857
deltoid of the scapula . 820
denticulatum . . 506
falciform, of liver . 263
Fallopius' . . . 192
Gimbernaut's . . 193
glenoid . . . 821
glosso-epiglottic . . 60
Hey's . . . 217
hyo-epiglottic . . 60
hyo-glossal . . 606
hyo-thyroid . . 61
ilio-femoral . . 841
ilio-lumbar . . 836
infraspinous . . 812
interarticular, of the hip 842
interarticular, of the ribs . . . 814
interarticular, of shoulder 822
interclavicular . . 818
intermaxillary . 11. 802
intermuscular . . 149
interosseous astragalo-calcaneoid . . 860
interosseous, of the carpus 831
interosseous radio-ulnar 828
interosseous tibio-fibular 855

Page.

LIGAMENTS—*continued.*
interosseous tibio-fibular, inferior . . 856
interspinous . . 813
intertransverse . . 813
intervertebral . . 810
lateral, of the ankle . 857
lateral, of the elbow . 824
lateral, of the jaw . 802
lateral, of the knee . 847
lateral occipito-atlantal 806
lateral, of phalanges, foot . . . 864
lateral, of phalanges, hand . . . 835
lateral, of the wrist . 829
latum pulmonis . . 89
of the liver . . 263
lumbo-sacral . . 836
metacarpo-phalangeal . 835
metatarso-phalangeal . 864
moderator . . . 807
mucosum . . . 849
nuchæ . . 134. 812
oblique . . . 827
oblique, of the knee . 851
obturator . . . 839
occipito-atlantal, anterior 805
occipito-atlantal, posterior . . . 806
occipito-axoid, middle 806
odontoid . . . 807
of the ovary . 352. 356
palmar of the carpus . 831
patellæ . . . 846
phalangeal, of the foot 864
phalangeal, of the hand 835
plantar, of the tarsus . 862
posterior, of the elbow 825
posterior, of the wrist . 829
posticum, of Winslow . 846
Poupart's . . . 192
pterygo-maxillary . 11
pubic . . . 317
pubic, anterior . . 839
pubic, posterior . . 839
pubic, superior . . 839

Page.

LIGAMENTS—*continued.*
recto-coccygeal . . 305
recto-uterine . . 353
rhomboid . . . 817
sacciform . . . 828
sacro-coccygean, anterior . . . 837
sacro-coccygean, posterior . . . 837
sacro-iliac, anterior . 837
sacro-iliac, posterior . 837
sacro-sciatic, anterior . 838
sacro-sciatic, posterior 837
scapheo-cuboid . . 862
spino-glenoid . . 821
stellate . . . 813
sterno-clavicular, anterior . . . 817
sterno-clavicular, posterior . . . 817
sterno-costal, anterior . 816
sterno-costal, inferior . 816
sterno-costal, posterior 816
sterno-costal, superior . 816
stylo-maxillary . . 803
subflava . . . 812
subpubic . . . 839
supraspinous . . 812
suspensory, of the liver 263
suspensory, of the penis 340
tarsal . . . 860
of the tarsi, broad . 619
tarso-metatarsal . . 863
teres, of the hip . . 842
teres, of liver . . 263
thyro-arytenoid . . 62
thyro-epiglottic . . 61
thyro-hyoid . . 61
tibio-fibular, inferior anterior . . . 856
tibio-fibular, inferior posterior . . . 856
tibio-fibular, superior anterior . . . 855
tibio-fibular, superior posterior . . . 855
tibio-tarsal . . 858

Page.

LIGAMENTS—*continued.*
transverse, of the acetabulum . . . 842
transverse, of the atlas 808
transverse, of the knee 850
transverse, of the scapula 821
trapezoid . . . 820
triangular, of urethra . 311
uterus of the, broad . 351
uterus of the, round . 352
vertebral, anterior common . . . 809
vertebral, posterior common . . . 810
vesico-uterine . . 353
of Winslow . . 382
Linea alba . . . 189
ilio-pectinæa . . 763
Lineæ semilunares . . 190
transversæ . 191. 201
Lingual glands . . . 609
Lingual nerve . . . 41
papillæ . . . 609
plexus . . . 611
veins . . . 431
Linguales muscles . 38. 608
Lips 43
Liquor Cotunnii . . 683
Morgagni . . . 659
Scarpæ . . . 684
Liver 263
coats of . . . 267
ligaments of . . 263
lobes of . . . 265
pathology of the . 274
structure of the . . 268
Lobes of the cerebellum . 493
of the cerebellum, amygdaloid . . . 494
of the cerebellum, digastric . . . 494
of the cerebellum, flocculus . . . 494
of the cerebellum, gracilis . . . 494
of the cerebellum, inferior posterior . 494

Page.
Lobes of the cerebellum, median . . . 495
of the cerebellum, median inferior . 493. 496
of the cerebellum, median superior . . 493
of the cerebellum, pneumogastric . . 494
of the cerebellum, semilunar . . . 494
of the cerebellum, superior anterior . 494
of the cerebellum, superior posterior . 494
of the cerebellum, tonsillitic . . 494
of the cerebrum . . 477
of the liver . . 265
Lobules of the testis . . 335
Lobulus auris . . . 668
caudatus . . . 265
quadratus . . . 265
Spigelii . . . 265
Locus niger . . 489. 516
perforatus . 480. 488
Longissimus dorsi muscle . 143
Longitudinal sinus, inferior 462
sinus, superior . . 461
Longus colli muscle . . 72
Lower jaw . . . 742
jaw, dislocation of 21. 804
jaw, motions of . 20. 804
Loweri tuberculum . . 111
Lumbar aponeurosis . . 135
arteries . . 282. 421
fascia . . 135. 198
ganglions of the sympathetic . . . 583
meso-colons . 235, 236
nerves . . . 561
plexus . . . 562
regions . . . 226
veins . . . 439
Lumbo-aortic plexus . . 584
sacral nerve . . 567
Lumbricales muscles . . 169
pedis . . . 398

Page.
Lunar bone . . . 794
Lungs 92
Lunula 595
Lymphatic glands and vessels . . . 446
abdominal . . 449
axillary . . . 448
brachial . . . 448
bronchial . . 450
cervical . . . 448
cranial . . . 453
head and face . . 448
inguinal . . . 449
intestinal . . 449. 451
lacteals . . . 451
liver . . . 451
lower extremity . 450
lumbar . . 449. 451
lungs . . . 450
mesenteric . 449. 451
pelvic . . . 449
spleen . . . 449
stomach . . . 449
upper extremity . 448
Lyra . . . 481. 484

Macula cribrosa . . 680
Malar bone . . . 737
nerves . . . 537
Malleolar arteries . . 426
Malleolus, external . . 780
internal . . . 778
Malleus 677
Malpighian corpuscles . 285
Mammary artery, internal . 415
gland . . . 75
Mammæ 74
pathology of the . . 77
Manubrium of sternum . 753
Masseter muscle . . 16
Masseteric arteries . . 411
nerves . . . 538
Mastoid cells . . 675. 723
process . . . 723
Matrix of the nail . . 595
Maxillary artery, external . 409
artery, internal . 22. 410

Page

Maxillary bone, inferior . 742
bone, superior . . 737
nerve, inferior . . 537
nerve, superior . . 535
vein, internal . . 431
Measurements, of the parts concerned in inguinal and femoral hernia 225. 226
Meatus auditorius, externus 669
auditorius, internus . 679
urinarius, female . 348
urinarius, male . . 342
Meatuses of the nares . 603
Meckel's ganglion . . 535
Median basilic vein . 161. 436
cephalic vein . 161. 436
nerve . . 183. 555
vein . . . 161. 436
Mediastinum, anterior . 86
middle . . . 90
posterior . . . 90
testis . . . 334
Medulla, of bones . . 695
oblongata . . 500
spinalis . . . 507
Meibomian glands . 594. 619
Membrana flaccida . . 673
Jacobi . . . 656
pupillaris . . . 654
Ruyschiana . 648, 649
tympani . . . 671
tympani, structure of . 673
Membrane, albugineal, of eye 629
of the aqueous humour 658
arachnoid, cranial . 464
arachnoid, spinal . 505
basement . . . 261
of brain . . . 455
choroid, of brain . . 485
choroid, of eye . . 647
of Demours . . 646
hyaloid . . . 661
interosseous, radio-ulnar 828
interosseous, tibio-fibular . . . 855
of the labyrinth . 683

Page.

Membrane, mucous . . 259
papillary, of skin . 593
pituitary . . . 603
Schneiderian . . 603
synovial . . . 800
Membraneous labyrinth . 683
portion of the urethra 342. 344
semicircular canals . 684
Meningea media, artery . 410
Mental nerve . . 23. 538
Mental process . . . 742
Mesenteric artery, inferior 280. 421
artery, superior . 280. 420
glands . . . 449
plexus, inferior . . 583
plexus, superior . 583
Mesentery . . . 236
Meso-cæcum . . . 237
Meso-cephale . . . 490
Meso-colons, lumbar 235, 236
Meso-colon, transverse . 235
Meso-rectum . . . 237
Metacarpal bones . . 795
Metacarpo-phalangeal articulations . . 833
Metatarsal arteries . . 426
Metatarsus, bones of . . 784
Middle mediastinum . . 90
Mitral valves . . . 117
Moderator ligaments . . 807
Modiolus 681
Molar teeth . . . 745
Mons Veneris . . . 347
Morgagni, liquor of . . 659
sinus of, pharyngeal . 48
sinuses of . . 114. 118
Morsus diaboli . . . 356
Motor tracts . . . 509
uvulæ muscle . . 52
Motores oculorum nerves 524. 531
Mouth, dissection of . . 42
Mucous membrane . . 259
MUSCLES of the Abdomen 186
abductor indicis . . 180
abductor minimi digiti 178

Page.

MUSCLES—*continued.*
abductor minimi digiti pedis 397
abductor pollicis . 177
abductor pollicis longus 174
abductor pollicis pedis 396
abductor oculi . . 628
accelerator urinæ . 309
accessorii (dorsal) . 143
accessorius . . 398
adductor brevis . . 369
adductor longus . 369
adductor magnus . 370
adductor minimi digiti 178
adductor oculi . . 627
adductor pollicis . 178
adductor pollicis pedis 399
anconæus . . . 173
anterior, auris . . 5
antitragicus . . 668
aryteno-epiglottici . 65
arytenoideus . . 64
attollens aurem . 4
attrahens aurem . 5
auriculæ transversus . 668
auricularis . . 173
azygos uvulæ . . 52
of the back . . 134
Bell's, of the ureters . 328
biceps . . . 155
biceps flexor cruris . 380
brachialis anticus . 157
buccinator . . 11
caninus . . . 9
cardiac, actions of . 130
cervicalis ascendens . 143
cervicalis descendens . 143
circumflexus palati . 51
coccygeus . . . 317
complexus . . 144
compressores nasi . 8
compressores penis . 308
compressores urethræ . 314
compressores urethræ transversi . . 315
compressores venæ dorsalis penis . . 310

Page.

MUSCLES—*continued.*
constrictor iridis . 654
constrictor isthmi faucium . . . 52
constrictor pharyngis, inferior . . . 46
constrictor pharyngis medius . . . 47
constrictor pharyngis, superior . . 48
coraco-brachialis . 155
corrugator supercilii . 8
cremaster . . . 195
crico-arytenoideus lateralis . . . 64
crico-arytenoideus posticus . . . 64
crico-thyroideus . 63
cruræus . . . 368
deltoides . . . 150
depressor anguli oris . 10
depressor labii inferioris 10
depressor labii superioris alæque nasi . 10
depressor oculi . . 628
detrusor urinæ . . 325
diaphragm . . 290
digastricus . . 33
of the ear . . . 4, 5
ejaculator seminis . 309
erector clitoridis . 349
erector penis . . 308
extensor carpi radialis brevis . . 172
extensor carpi radialis longus . . . 171
extensor carpi ulnaris 172
extensor digitorum brevis pedis . . 388
extensor digitorum communis . . . 172
extensor digitorum longus pedis . . . 387
extensor indicis . . 175
extensor minimi digiti 173
extensor ossis metacarpi pollicis . . . 174

Page.

MUSCLES—*continued.*
extensor pollicis major 175
extensor pollicis minor 174
extensor pollicis proprius pedis . . 387
extensor primi internodii pollicis . . 174
extensor secundi internodii pollicis . . 175
of the face . . 6
flexor brevis minimi digiti . . . 178
flexor brevis minimi digiti pedis . . 400
flexor carpi radialis . 165
flexor carpi ulnaris . 166
flexor digitorum accessorius . . . 398
flexor digitorum brevis pedis . . . 397
flexor digitorum longus pedis . . . 394
flexor digitorum profundus perforans . 168
flexor digitorum sublimis perforatus . 166
flexor ossis metacarpi pollicis . . . 177
flexor pollicis brevis . 177
flexor pollicis brevis pedis . . . 399
flexor pollicis longus . 169
flexor pollicis longus pedis . . . 395
gastrocnemius . . 390
gemellus inferior . 377
gemellus superior . 377
genio-hyo-glossi 37. 607
genio-hyoideus . . 35
glutæus maximus . 374
glutæus medius . . 376
glutæus minimus . 376
gracilis . . . 368
helicis major . . 668
helicis minor . . 668
of hip . . . 374
hyo-glossi . 37. 607

Page.

MUSCLES—*continued.*
hyo-pharyngeus . 47
iliacus internus . . 303
indicator . . . 175
infraspinatus . . 152
intercostales . . 82
interossei manus, posteriores . . . 180
interossei palmar . 179
interossei pedis inferiores . . . 400
interossei pedis superiores . . . 401
interspinales . . 145
intertransversales . 145
ischio-bulbosus . . 310
latissimus colli . . 26
latissimus dorsi . . 138
laxator tympani major . . . 678
laxator tympani minor 679
levator anguli oris . 9
levator anguli scapulæ 140
levator ani . . 313
levator glandulæ thyroideæ . . . 32
levator labii inferioris . 10
levator labii superioris alæque nasi . . 9
levator menti . . 10
levator oculi . . 627
levator palati . . 51
levator palpebræ superioris . . . 625
levator urethræ . . 314
levatores costarum . 82
linguales . . 38. 608
longissimus dorsi . 143
longus colli . . 72
lumbricales manus . 169
lumbricales pedis . 398
masseter . . . 16
motor uvulæ . . 52
multifidus spinæ . 145
mylo-hyoideus . . 35
obliquus abdominis externus . . . 188

MUSCLES—*continued.*	Page.
obliquus abdominis internus	194
obliquus capitis, inferior	146
obliquus capitis, superior	146
obliquus oculi, inferior	632
obliquus oculi, superior	632
obturator externus	379
obturator internus	377
occipito frontalis	2
omo-hyoideus	31
opponens minimi digiti	178
opponens pollicis	177
orbicularis oris	11
orbicularis palpebrarum	6. 618
palato-glossus	52. 608
palato-pharyngeus	52
palmaris brevis	164
palmaris longus	166
pectinæus	369
pectoralis major	77
pectoralis minor	79
peroneus brevis	389
peroneus longus	388
peroneus tertius	388
plantaris	391
platysma myoides	26
poplitæus	393
pronator quadratus	170
pronator radii teres	165
psoas magnus	301
psoas parvus	300
pterygoideus externus	20
pterygoideus internus	19
pyramidalis abdominis	202
pyramidalis nasi	8
pyriformis	376
quadratus femoris	378
quadratus lumborum	300
quadratus menti	10
quadriceps extensor cruris	367
rectus abdominis	200

MUSCLES—*continued.*	Page.
rectus capitis anticus major	72
rectus capitis anticus minor	72
rectus capitis lateralis	72
rectus capitis posticus major	145
rectus capitis posticus minor	146
rectus femoris	366
rectus oculi externus	628
rectus oculi inferior	628
rectus oculi internus	627
rectus oculi superior	627
retrahens aurem	5
rhomboideus major	140
rhomboideus minor	139
risorius Santorini	26
sacro-lumbalis	143
sartorius	365
scalenus anticus	72
scalenus medius	73
scalenus posticus	73
semimembranosus	381
semispinalis colli	144
semispinalis dorsi	144
semitendinosus	381
serratus magnus	80
serratus posticus inferior	140
serratus posticus superior	140
solæus	392
sphincter ani externus	305
sphincter ani internus	306
sphincter iridis	654
sphincter oculi	6. 618
sphincter oris	11
sphincter vaginæ	349
sphincter vesicæ	326
spinalis colli	144
spinalis dorsi	143
splenius capitis	141
splenius colli	141
stapedius	678
sterno-cleido-mastoideus	28

Page.

MUSCLES—*continued.*
sterno-costalis . . 82
sterno-hyoideus . . 31
sterno-thyroideus . 31
stylo-glossus . 38. 607
stylo-hyoideus . . 38
stylo-pharyngeus 38. 47
subclavius . . 80
subcruræus . . 368
subscapularis . . 153
superior auris . . 4
supinator radii brevis . 174
supinator radii longus 171
supraspinatus . . 151
supraspinous . . 145
suspensorius testis . 195
temporalis . . 16
tensor palati . . 51
tensor tarsi . . 8
tensor tympani . . 678
tensor vaginæ femoris 364
teres major . . 154
teres minor . . 152
thyro-arytenoideus . 63
thyro-epiglottic . 65
thyro-hyoideus . . 63
tibialis anticus . . 386
tibialis posticus . . 395
trachelo-mastoideus . 144
tragicus . . . 668
transversalis abdominis 196
transversalis colli . 143
transversalis pedis . 399
transversalis perinæi . 310
transversus auriculæ . 668
trapezius . . . 137
triangularis oris . . 10
triangularis sterni . 82
triceps adductor femoris . . . 369
triceps extensor cubiti . 157
trochleator . . 632
tympani laxator major 678
tympani laxator minor 679
tympani tensor . . 678
vastus externus . . 367
vastus internus . . 367

Page.

MUSCLES—*continued.*
zygomaticus major . 9
zygomaticus minor . 9
Muscular artery . . 409
fibres of auricles of the heart . . . 126
fibres of ventricles of the heart . . 127
tissue of the heart . 124
Musculi papillares . 112. 117
pectinati . . 111
Musculo-cutaneous nerve of arm . . . 555
of leg . . . 571
of lumbar plexus inferior . . . 563
Musculo-cutaneous nerve of lumbar plexus, middle . . . 562
superior . . . 562
Musculo-spiral nerve . 183. 558
Mylo-hyoideus muscle . 35
Mylo-hyoid nerve . . 538
Myopia 664
Myrtiform fossa . . 739

Naboth, ovula of . . 354
Nails 595
Nares 602
Nares, posterior . . 49
Nasal artery . . 411, 412
bones . . . 741
cartilages, or fibro-cartilages . . . 600
duct . . . 624
fossæ . . . 602
lamella of ethmoid bone 727
nerve . . . 533
process of superior maxillary bone . . 737
spine . . . 719
Naso-palatine ganglion . 536
Naso-palatine nerve . . 536
Nates cerebri . . . 490
Navicular bone of carpus . 794
bone of tarsus . . 783
fossa . . . 666

Page.

Neck, deep muscles of . . 71
 dissection of . . 24
 triangles of . . 29
 vessels and nerves of . 39

NERVES of abdomen . . 280
 abducentes . 527. 533
 accessorius . 528. 546
 anterior crural . . 563
 anterior thoracic . 553
 anterior tibial . . 572
 ascendens colli . . 15
 auditory . 528. 543. 685
 auricular, or temporo-auricular . . 538
 auricular . . . 544
 auricular, posterior . 542
 auricularis magnus . 549
 axillary . . . 553
 brachial . . 84. 555
 buccal . . . 538
 cardiac . . 123. 545
 cardiac, great . 578, 579
 cardiac, inferior . 579, 580
 cardiac, middle . 578, 579
 cardiac, superior . 578, 579
 cerebral, dissection of . 530
 cerebral, origins of . 523
 cervical, spinal . 41. 548
 cervico-facial . . 542
 ciliary . . 533, 534
 circumflex . . 554
 cochlear . . . 685
 communicans noni . 550
 communicans peronæi 571
 communicans tibialis 383. 573
 communicating, lumbar 567
 corda tympani 536. 541. 676
 Cotunnii . . . 536
 crural, anterior . . 563
 crural, posterior . . 570
 cutaneous, of arm, external . . . 555
 cutaneous, of arm, internal . . . 554
 cutaneous, of arm, internal, lesser . . 555

Page.

NERVES—*continued.*
 cutaneous of back, inferior . . . 559
 cutaneous of back, superior . . . 559
 cutaneous, of the leg, external . . 571
 cutaneous, of the leg, internal . . 565
 cutaneous, of the leg, posterior . . 572
 cutaneous, of thigh, anterior . . . 564
 cutaneous of thigh, posterior . . . 562
 deltoid . . . 554
 dental, anterior . . 537
 dental, inferior . . 538
 dental, posterior . 537
 descendens, colli . . 547
 descendens, noni 41. 547
 digastric . . . 542
 digital, of fingers . 556
 digital, of toes . . 574
 dorsal . . . 558
 dorsal, first . . 560
 dorsalis carpi ulnaris . 557
 dorsalis pedis . . 571
 dorso-lumbar . . 560
 eighth pair 40. 528. 543
 external respiratory . 552
 facial . 527. 540. 686
 fifth pair . . 525. 532
 first pair . . 523. 530
 fourth pair . 525. 532
 frontal . . 22. 533
 genito-crural . . 563
 glosso-pharyngeal 40. 528. 543
 glutæal, inferior . . 569
 glutæal, superior . 567
 gustatory . . 40. 539
 of the heart . . 123
 ilio-scrotal . . 562
 inferior laryngeal . 545
 inferior maxillary . 537
 infraclavicular . . 553

Page.

NERVES—*continued.*
infraorbital . 23. 537
infratrochleator . . 533
inguino-cutaneous . 562
intercostal . . 559
intercosto-humeral . 560
internal cutaneous of arm 554
internal cutaneous, of arm, lesser . . 555
internal respiratory . 550
interosseal, of arm, anterior 556
interosseal, of arm, posterior 558
interosseal, of leg . 572
Jacobson's . . . 543
lachrymal . . . 532
laryngeal, functions of 68
laryngeal, inferior 41. 545
laryngeal, superior . 545
lingual . 41. 528. 547
lumbar . . . 561
lumbo-sacral . . 567
malar . . . 537
masseteric . . . 538
maxillary, inferior . 537
maxillary, superior . 535
median . . 183. 555
mental . . 23. 538
molles . . . 577
motores oculorum 524. 531
musculo-cutaneous, of arm 555
musculo-cutaneous, of leg 571
musculo-cutaneous lumbar, inferior . . 563
musculo-cutaneous lumbar, middle . . 562
musculo-cutaneous lumbar, superior . . 562
musculo-spiral . 183. 558
mylo-hyoid . . 538
nasal . . . 533
naso-palatine . . 536
ninth pair . 41. 528. 547

Page.

NERVES—*continued.*
obturator . . . 566
obturator, accessory . 566
occipitalis, major . 551
occipitalis, minor . 549
œsophageal . . 546
olfactory . . 523. 530
ophthalmic . . 532
optic . 524. 530. 637
orbital . . . 537
orbital, functions of the 637
palatine . . . 535
palmar, deep . . 557
palmar, superficial . 557
par vagum . 528. 543
pathetici . . 525. 532
pelvic . . . 568
perforans Casserii . 555
perinæal . . . 569
peroneal . . 390. 571
petrosal, external . 541
petrosal, superficial . 539
petrosal, superior . 536
pharyngeal . . 545
phrenic . 42. 99. 550
plantar, external . 574
plantar, internal . 574
pneumogastric 40. 528. 544
poplitæal, external . 571
poplitæal, internal . 572
portio dura 15. 22. 527. 540. 686
portio mollis 528. 543. 685
posterior crural . . 570
posterior thoracic . 552
posterior tibial . . 573
pterygoid . . . 538
pudic . . . 569
pulmonary . . 546
radial . . 183. 558
recurrent laryngeal 41. 545
respiratory, external . 552
respiratory, of face . 542
respiratory, internal . 550
respiratory, of neck . 547
sacral . . . 567
saphenous, external . 573

Page.

Nerves—*continued.*
saphenous, long, or inferior . . . 565
saphenous, short, or superior . . . 564
sciatic, great . . 570
sciatic, lesser . . 569
second pair 524. 530. 637
seventh pair . 527. 540
sixth pair . . 527. 533
spheno-palatine . . 535
spinal accessory 40. 528. 546
spinal, dissection of . 548
spinal, origins of . 511
spinal, functions of . 512
splanchnic, great 91. 581
splanchnic, lesser 92. 581
stylo-hyoid . . 542
submastoid . . 542
suboccipital . . 548
suboccipital, anterior division . . . 548
suboccipital, posterior division . . . 550
subscapular . . 554
superficialis colli 15. 549
superficialis cordis 578, 579
superior laryngeal . 545
superior maxillary . 535
supraclavicular . 549. 552
supraorbital . . 533
suprascapular . . 553
supratrochleator . 533
sympathetic 41. 282. 574
tarsal . . . 571
temporal . . . 537
temporal, deep . . 537
temporo-auricular 15. 538
temporo-facial . . 542
third pair . . 524. 531
thoracic, anterior . 553
thoracic, posterior . 552
tibial, anterior . . 572
tibial, posterior . 402. 573
trifacial . . 525. 532
trigemini . . 525. 532
trochleatores . 525. 532

Page.

Nerves—*continued.*
tympanic . . 541. 543
ulnar . . 183. 556
vagus . . 528. 544
vestibular . . . 685
Vidian . . . 536
of Wrisberg 150. 555. 560
Nervous system . . 455
Neurine, grey . . . 472
white . . . 472
Nidus hirundinis . . 497
Ninth pair of nerves 41. 528. 547
Nipple 75
Nodulus 496
Nose, anatomy of . . 599
cartilages of . . 600
Nuchæ ligamentum . . 134
Nuck's canal . . . 352
Nymphæ 347
Obliquus abdominis externus muscle . . 188
abdominis internus muscle . . . 194
capitis inferior muscle . 146
capitis superior muscle 146
oculi, inferior . . 632
oculi, superior . . 632
Obturator artery . . 423
fascia . . 308. 319
foramen . . . 767
muscle, externus . 379
muscle, internus . . 377
nerve . . . 566
nerve, accessory . 566
Occipital artery . . 409
bone . . . 713
sinuses . . . 464
veins . . . 430
Occipitalis major nerve . 551
minor nerve . . 549
Occipito-atlantal articulation 805
Occipito-axoid articulation 806
Occipito-frontalis muscle . 2
Ocular fascia . . . 628
Oculo-palpebral space . 621
Odontoid ligaments . . 807
process . . . 704

	Page.
Odoriferous glands	595
Œsophageal arteries	418
nerves	546
plexus	91. 546
Œsophagus	56. 90. 104
pathology of the	56
Olecranon	791
Olfactory bulb	524
lobes	524
nerves	523. 530
Olivary ganglion	501
process of sphenoid bone	730
tracts	516
Olive-shaped bodies	501. 516
Omentum, colic	236
great or gastro-colic	234
lesser or gastro-hepatic	234
pathology of the	262
sac of	235
splenic	236
Omo-hyoideus muscle	31
Ophthalmic artery	412. 636
ganglion	534
nerve	532
vein	431. 636
Opponens minimi digiti muscle	178
pollicis muscle	177
Optic commissure	524
lobes	491
nerves	524. 530. 637
thalami	487
tract	524
Optics	662
Orbicular bone	677
Orbicularis oris muscle	11
palpebrarum muscle	6. 618
Orbital muscles, actions of	630. 633
nerves	537
nerves, functions of the	637
plate of superior maxillary bone	737
plexus	531
processes of frontal bone	721
Orbits	613
angles of	615
apex of	614
axes of	615
base of	614
dissection of	531
foramina in	615
walls of	614
Organ of hearing	665
of smell	599
of taste	605
of touch	586
of vision	612
Organs of sense	586
Orifice of the thorax, upper	98
Orifices of the thorax	86
Os hyoides	57
innominatum	765
planum	728
uteri, or os tincæ	353
Ossa Wormea or triquetra	717
Osseous system, anatomy of	688
tissue	696
Ossicula auditus	676
Ossification, process of	697
Ostium abdominale	356
externum	353
internum	353
uterinum	356
Otic ganglion	539
Otoconia	684
Otolithi	684
Ourlet, or hem-like convolution	474
Ovaria	356
Ovarian ligament	352. 356
veins	439
Oviducts of Fallopius	356
Ovula Graafiana	357
of Naboth	354
Ovum	357
Pacchionii glandulæ	462
Pacinian corpuscles	557
Palate bone	739
dissection of the	50
pillars or arches of	49, 50

Page.

Palate, soft . . 42. 50
Palatine artery, inferior . 409
artery, superior . . 411
nerves . . . 535
Palato-glossus muscle 52. 608
pharyngeus muscle . 52
Palmar fascia . . . 163
nerve, deep . . 557
nerve, superficial . 557
Palmaris brevis muscle . 164
longus muscle . . 166
profunda artery . . 418
superficialis artery . 417
Palpebræ . . . 616
Palpebral arteries . . 412
canthi . . . 616
cartilages . . . 619
fissure . . . 616
Pancreas 279
pathology of the . 279
Pancreatic arteries . . 280
duct 279
Pancreatico-duodenalis artery . . 280. 420
Panniculus carnosus . . 589
Papillæ, button-shaped . 609
calyciformes . . 609
circumvallate . . 609
conical . . . 610
dental . . . 748
filiform . . . 610
of fingers . . . 593
fungiformes . . 610
of the kidney . . 286
lachrymal . . 617
of the nail . . 595
of the tongue . . 609
Papillary membrane of skin 593
Par vagum nerve 40. 528. 543
Parallax, aberration from . 663
Parietal bone . . . 716
Parotid gland . . . 14
Parotid gland, pathology of 16
Parotidean plexus . 15. 542
region . . . 34
Parotidis socia . . . 14
Patella 776

Page.

Patella, dislocations of . 853
Pathetic nerves . . 525. 532
Pathology of the arachnoid membrane . . 522
of the bladder . . 330
of the brain . . 522
of the dura mater . 521
of the gall-bladder . 277
of the generative organs, female . . 358
of the generative organs, male . . 345
of the heart . . 132
of the intestinal tube . 262
of the kidney . . 289
of the larynx . . 70
of the liver . . 274
of the lungs . . 97
of the mammary gland 77
of the œsophagus . 56
of the omentum . 262
of the palate . . 55
of the pancreas . . 279
of the parotid gland . 16
of the pericardium . 107
of the peritonæum . 262
of the pharynx . . 56
of the pia mater . 522
of the pleuræ . . 97
of the prostate gland . 345
of the scalp . . 4
of the spleen . . 278
of the stomach . . 262
of the submaxillary gland . . . 35
of the testicle . . 345
of the thyroid body . 33
of the tongue . . 44
of the tonsil . . 56
of the trachea . . 70
of the urethra, male . 346
of the uvula . . 56
Pectinæus muscle . . 369
Pectoralis major muscle . 77
minor muscle . . 79
Peduncles of the cerebellum, inferior . . 502

	Page.
Peduncles of pineal body	486
Pelvic cavity, dissection of	318
fascia	319
glands	449
nerves	568
Pelvis, bones of	761
dimensions of	771
false	769
female	770
general observations	767
of the kidney	287
true	769
Penis	339
dorsal artery of	423
Perforans Casserii nerve	555
Perforated plate of brain, external	479
plate of brain, middle	480
Perforating arteries of thigh	425
Pericardium	105
pathology of the	107
perforations of fibrous layer of	106
Perilymph	683
Perinæal artery	423
artery, transverse	423
fascia, deep	307. 311
fascia, middle	307
fascia, superficial	306
Perinæum, male	303
Peritonæum	229
external surface of	228
pathology of the	262
Peroneal artery	427
artery, anterior	427
artery, posterior	427
nerve	390. 571
Peroneus brevis muscle	389
longus muscle	388
tertius muscle	388
Perspiration	587
Pes anserinus	15. 22. 542
hippocampi	485
Petit, canal of	662
Petrosal nerve, external	541
nerve, superficial	539
nerve, superior	536
Petrosal sinuses	464
Petrous ganglion	543
Peyer, glands of	256
Phalangeal articulations of the foot	864
articulations of the hand	835
Pharyngeal aponeurosis	46
artery, ascending	410
nerve	545
plexus	543. 545
Pharynx, dissection of	45
openings into	49
pathology of the	56
Phrenic arteries	282. 419
nerve	42. 99. 550
plexus	582
veins, inferior	439
Pia mater, cranial	468
mater, pathology of the	522
mater, spinal	507
Pigmentum nigrum	649
Pillars of the fornix	484
of the palate	49, 50
Pineal body	486
Pinna	666
Pisiform bodies	480
bone	795
Pituitary body	479
membrane	603
Plantar artery, external	427
artery, internal	427
fascia	385
nerve, external	574
nerve, internal	574
Plantaris muscle	391
Platysma myoides muscle	26
Pleura costalis	87
fibrous layer of	89
pulmonalis	87
Pleuræ	87
pathology of the	97
Plexus, basilar	544
brachial	42. 84. 159. 551
cardiac	123
cardiac, anterior	580
cardiac, great	580
cardiac, posterior	580

	Page.
Plexus, carotid, internal	577
cavernous	577
cervical, anterior	41. 549
cervical, posterior	551
choroid	483
choroid of the fourth ventricle	496
choroid of lateral ventricles	470
choroid of the third ventricle	486
cœliac	92. 281
coronary	123. 580
gastric	582
gulæ	546
hæmorrhoidal	583
hepatic	582
hypogastric	584
lingual	611
lumbar	562
lumbo-aortic	584
mesenteric, inferior	583
mesenteric, superior	583
œsophageal	91. 546
orbital	531
parotidæan	15. 542
pharyngeal	543. 545
phrenic	582
pulmonary, anterior	546
pulmonary, posterior	546
renal	287. 583
sacral	568
solar	92. 281. 582
spermatic	583
splenic	583
submaxillary	536. 539
suprarenal	582
tonsillitic	544
tympanic	686
vertebral	579
Plica semilunaris	620
Pneumogastric ganglion, inferior	544
ganglion, superior	544
lobe	494
nerve	40. 528. 544
Pomum Adami	58

	Page.
Pons Tarini	480
Varolii	491
Popliteal artery	426
nerve, external	571
nerve, internal	572
region	382
vein	437
Poplitæus muscle	393
Pores	590
Portal vein	269. 281
Portio dura nerve	15. 22. 527. 540. 686
mollis nerve	528. 543. 685
Porus opticus	644. 655
Posterior auris muscle	5
mediastinum	90
Pouches, inguinal	209. 212
Poupart's ligament	192
Prelumbo-thoracic vein	434
Prepuce	339
Presbyopia	665
Prevertebral fascia	28
Process, acromion	786
alveolar	739
auditory, external	723
azygos, of sphenoid bone	729
basilar	714
ciliary	651
clinoid, of sphenoid bone	730
coronoid, of lower jaw	743
coronoid, of ulna	791
hamular, of sphenoid bone	731
mastoid	723
nasal, of superior maxillary bone	737
odontoid	704
olecranon, of ulna	791
olivary, of sphenoid bone	730
orbital, of frontal bone	721
pterygoid	731
of Rau	677
styloid, of temporal bone	724
vaginal, of temporal bone	724

Page.
Process, vermiform, inferior 493. 496
vermiform, superior 493. 495
zygomatic, of temporal bone . . . 722
Processus a cerebello ad testes . . 490. 499
Profunda artery, inferior . 417
artery, superior . . 416
femoris artery . . 425
Promontory . . . 675
of sacrum . . . 709
Pronator quadratus muscle 170
radii teres muscle . 165
Prostate gland . . . 338
gland, pathology of the 345
Prostatic sinuses . . 344
veins . . . 438
portion of the urethra 342. 344
Protuberance, cerebral . 491
occipital . . 713
Psalterium . . 481. 484
Psoas magnus muscle . 301
Psoas parvus muscle . . 300
Pterygoid arteries . . 411
nerves . . . 538
process . . . 731
Pterygoideus externus muscle . . . 20
internus muscle . 19
Pterygo-maxillary ligament 11
Pubic ligament . . 317
region . . . 226
symphysis . . 838
Pubis, bone of . . . 764
Pudic artery, internal . 423
arteries, superficial . 425
nerve . . . 569
Pulmonary artery . . 115
artery, orifice of . 114
nerves . . . 546
plexus, anterior . 546
plexus, posterior . 546
sinuses . . . 114
veins . . . 427
Puncta lachrymalia . 617. 623
Pupil 652

Page.
Pupillary membrane . 654
Pyloric artery, inferior . 420
artery, superior . . 420
valve . . . 243
Pylorus 240
Pyramid of the cerebellum . 496
of the medulla oblongata, anterior 501. 515
of the medulla oblongata, posterior 502. 515
(in the tympanum) . 675
of vertebral column . 708
Pyramidal bone of carpus . 794
Pyramidalis muscle . . 202
nasi muscle . . 8
Pyriformis muscle . . 376

Radial artery . . 182. 418
artery, recurrent . 418
nerve . . 183. 558
Radialis indicis artery . 418
Radio-ulnar articulations . 826
Radius 792
Rami of lower jaw . . 743
Ramus of ischium . . 764
Ramus of pubis . . 764
Ranine arteries . . 409
vein . . . 431
Raphe corporis callosi . 481
of the perinæum . 305
Rau, process of . . 677
Receptaculum chyli . 283. 452
Rectal fascia . . 314. 320
Recto-bulbar region . . 321
Recto-coccygeal ligament . 305
Recto-uterine ligaments . 353
Recto-vesical fascia . 312. 320
Rectum 252
structure of . . 258
Rectus abdominis muscle . 200
capitis anticus major muscle . . . 72
capitis anticus minor muscle . . 72
capitis lateralis muscle 72
capitis posticus major muscle . . . 145

	Page.
Rectus capitis posticus minor muscle	146
femoris muscle	366
oculi, externus	628
oculi, inferior	628
oculi, internus	627
oculi, superior	627
Recurrent laryngeal nerve	41
Reflex power	510
Region, anal	307
digastric	34
inguinal	215
ischio-rectal	307
parotidæan	34
popliteal	382
recto-bulbar	321
subclavicular	79
sublingual	36
submaxillary	34
urethral	307
Regions of the abdomen	226
of the bladder	324
Reil, island of	475. 479
Renal arteries	282. 421
capsule	288
plexus	287. 583
veins	439
Respiration	298
Respiratory nerve, external	552
nerve, internal	550
tracts	509
Restiform bodies	502. 515
Rete testis	335
Retina	655
central artery of	412
Retinacula of the hip-joint	841
Retrahens aurem muscle	5
Rhomboid ligament	817
Rhomboideus major muscle	140
minor muscle	139
Ribs	755
articulations of	813
dislocations of	816
Ribes, ganglion of	521
Rima glottidis	62. 67
Ring, abdominal, external	191
abdominal, internal	205

	Page.
Ring, femoral or crural	223
inguinal, external	191
inguinal, internal	205
Roots of the lungs	93
Rostrum of sphenoid bone	729
Rotula	776
Round ligament of the uterus	352
Ruysch, membrane of	648. 649
Sac, lachrymal	624
Sacciform ligament	828
Sacculus laryngis	68
vestibuli	684
Sacral artery, lateral	422
artery, middle	282. 421
ganglions	584
nerves	567
plexus	568
Sacro-lumbalis muscle	143
Sacro-sciatic ligament, great	837
ligament, lesser	838
Sacrum	709
Sagittal suture	732
Salivary glands	12
Salvatella vein	161. 436
Santorini cornicula	60
incisuræ	669
musculus risorius	26
Saphena vein	216
vein, external	437. 384
vein, internal	437. 361
Saphenic opening	216. 363
Saphenous nerve, external	573
long, or inferior	565
short or superior	564
Sartorius muscle	365
Scala tympani	683
vestibuli	683
Scalenus anticus muscle	72
medius muscle	73
posticus muscle	73
Scalp	1
Scalp, pathology of	4
Scaphoid bone of carpus	794
bone of tarsus	783
fossa	666
Scapula	786

	Page.
Scapular artery, posterior	415
artery, superior	415
Scapulo-clavicular articulation	819
Scarpa, fascia of	185
fluid of	684
Schindylesis	800
Schneiderian membrane	603
Sciatic artery	423
nerve, great	570
nerve, lesser	569
Sclerotic coat of the eye	642
Scrobiculus cordis	226
Scrotum	331
Sebaceous glands	594
Sella Turcica	729
Semicircular canals	681
canals, membraneous	684
Semilunar bone	794
cartilages	851
fascia	156
ganglion	91. 281. 582
valves	114
Semimembranosus muscle	381
Semispinalis colli muscle	144
spinalis dorsi muscle	144
Semitendinosus muscle	381
Sense of hearing	665
of sight	612
of smell	604
of tact	587. 594
of taste	605. 611
of touch	586. 594
of vision	662
Sensitive tracts	509
Septum auricularum	111
cervico-thoracic	28
crurale	212. 219
of Lieutand	113. 118
lucidum	481
pectiniforme	340
scroti	332
ventriculorum	112. 117
Serratus magnus muscle	80
posticus inferior muscle	140
posticus superior muscle	140
Sesamoid bones of foot	785

	Page.
Sesamoid bones of hand	797
Sheath of the femoral vessels	205. 221
of flexor tendons	167
of the rectus abdominis	200
Shoulder, dissection of	148
joint	821
joint, dislocations of	823
Sight, sense of	612. 662
Sigmoid artery	281. 421
cavities of ulna	791
flexure of colon	252
notch of lower jaw	743
valves	114
Sinus, aortic, great	120. 407
aortic, lesser	407
basilar	464
of the bulb	344
cavernous	463
circular	464
coronary	112
frontal	721
lateral	463
longitudinal, inferior	462
longitudinal, superior	461
of Morgagni	48. 114. 118
occipital	464
palpebral	620
petrosal, inferior	464
petrosal, superior	464
pocularis	344
of the porta	281
prostatic	344
sphenoid	729
straight	463
transverse	464
uterine	355
of Valsalva	114. 118
venosus, of the heart, left	116
venosus, of the heart, right	110
vertebral	505
Skeleton	688
Skin, anatomy of	586
colouring matter of	591
Skull	712

Page.

Skull, base of . . . 735
regions of . . . 733
Smell, organ of . . 599
sense of . . . 604
Socia parotidis . . . 14
Soemerring, spot of . . 656
Soemerring's levator glandulæ . . . 32
Solæus muscle . . . 392
Solar plexus . 92. 281. 582
Soft palate . . 42. 50
Sounds of the heart . . 131
Space, oculo-palpebral . 621
subarachnoid . . 465
subarachnoid, spinal . 506
Spermatic arteries . 282. 421
canal . . . 206
cord 336
fascia . . 192. 332
region . . . 227
veins . . . 439
Sphenoid bone . . . 729
sinuses . . . 729
Sphenoidal folds of dura mater . . . 461
suture . . . 732
Spheno-palatine ganglion . 535
nerve . . . 535
Spherical aberration . . 663
Sphincter ani, externus . 305
ani, internus . . 306
iridis . . . 654
oculi muscle . 6. 618
oris muscle . . 11
vaginæ muscle . . 349
vesicæ muscle . . 326
Spigelian lobe of liver . 265
Spigot 496
Spinal accessory nerve 40. 528. 546
arteries, anterior . 414
arteries, posterior . 414
bulb . . . 500
commissure, anterior . 508
commissure, posterior 508
cord 507
cord, arteries of, anterior 520

Page.

Spinal cord, arteries of, posterior . . . 520
cord, grey neurine of . 510
cord, structure of . 509
nerves . . . 548
nerves, cervical 41. 548
nerves, dorsal . . 558
nerves, functions of . 512
nerves, lumbar . . 561
nerves, origins of . 511
nerves, sacral . . 567
ventricle . . . 511
Spinalis colli muscle . . 144
dorsi muscle . . 143
Splanchnic nerves . . 91
nerve, great . . 581
nerve, lesser . . 581
Spleen 277
pathology of the . 278
Splenic artery . . 280. 420
omentum . . . 236
plexus . . . 583
Splenius capitis muscle . 141
colli muscle . . 141
Spongy portion of the urethra . . 342. 344
Spot, germinal (Wagner) . 357
Squamous suture . . 733
Stapedius muscle . . 678
Stapes 677
Stellate ligament . . 813
Steno's duct . . . 14
Sterno-clavicular articulation . . . 816
Sterno-cleido mastoideus muscle . . . 28
Sterno-costal ligaments . 816
Sterno-costalis muscle . 82
Sterno-hyoideus muscle . 31
Sterno-thyroideus muscle . 31
Sternum 753
Stomach 240
coats of . . . 241
pathology of . . 262
vessels and nerves of . 244
Straight sinus . . . 463
Stylo-glossus muscle 38. 607

	Page.
Stylo-hyoideus muscle .	38
Stylo-hyoid nerve . .	542
Stylo-mastoid artery .	410
Stylo-maxillary ligament .	803
Stylo-pharyngeus muscle	38. 47
Styloid process of temporal bone . . .	724
Subarachnoid fluid . .	467
fluid, spinal . .	506
space . . .	465
space, spinal . .	506
Subclavian arteries .	39. 413
vein . .	40. 436
Subclavicular region . .	79
Subclavius muscle . .	80
Sublingual artery . .	409
gland . . .	36
region . . .	36
Submastoid nerve . .	542
Submaxillary ganglion .	536
gland . . .	34
gland, pathology of .	35
region . . .	34
Submental artery . .	409
Suboccipital nerve . .	548
nerve, anterior division	548
nerve, posterior division	550
Subperitonæal cellular tissue . . .	219
Subscapular artery . .	416
muscle . .	153
nerves . . .	554
Succus intestinalis . .	253
Sudoriferous glands . .	594
Supercilia . . .	616
Superciliary arch . .	719
Superficial fasciæ . .	598
Superficialis colli nerve	15. 549
cordis nerve .	578, 579
volæ artery . .	418
Superior auris muscle .	4
maxillary nerve .	535
pyloric artery . .	280
vena cava . . .	98
Supinator radii brevis muscle . . .	174
radii longus muscle .	171

	Page.
Supraclavicular nerves	549. 552
Supraorbital artery . .	412
nerve . . .	533
Suprarenal capsule . .	288
plexus . . .	582
Suprascapular artery .	415
nerve . . .	553
Supraspinatus muscle .	151
Supraspinous fascia . .	148
ligament . . .	812
muscles . . .	145
Supratrochleator nerve .	533
Suspensorius testis muscle	195
Suspensory ligament of the liver . . .	263
ligament of the penis .	340
Sutures . . .	732. 799
coronal . . .	732
ethmoidal . .	732
frontal . . .	732
lambdoid . . .	732
sagittal . . .	732
sphenoidal . .	732
squamous . .	733
Swallow's nest . . .	497
Sweat	587
Sweat glands . . .	594
Sylvius, aqueduct of .	488
fissure of . . .	478
Sympathetic nerves 41. 282.	574
Symphysis . . .	800
pubis . .	765. 838
Synarthrosis . . .	799
Syndesmology . . .	799
Synovial membrane . .	800
membrane of ankle-joint . . .	858
membrane, atlanto-axoid . . .	808
membranes, carpal .	833
membranes, carpo-metacarpal . . .	834
membrane, costo-vertebral . . .	814
membrane, femoro-tibial	847
membrane, humero-cubital . . .	825

	Page.
Synovial membrane, humero-scapular	822
membrane, ilio-femoral	841
membranes of the jaw	803
membrane, radio-carpal	830
membranes, scapulo-clavicular	819
membranes, sterno-clavicular	818
System, nervous	455
osseous	688
vascular	403
Systemic veins	428
Systole	130
Tact, sense of	587. 594
Tænia hippocampi	485
semicircularis	483
Tapetum	650
Tarini pons	480
Tarsal arteries	426
cartilages	619
nerves	571
Tarsus, bones of	780
broad ligaments of	619
Taste, organ of	605
sense of	605. 611
Tears	623
Teeth	744
development of	748
structure of	746
Temporal aponeurosis	17
arteries, deep	411
artery	22. 410
artery, anterior	410
artery, middle	410
artery, posterior	410
bones	722
fascia	17
muscle	17
nerves	537
nerves, deep	537
ridge	720
vein	430
Temporo-auricular nerve	15. 538
Temporo-facial nerve	542

	Page.
Temporo-maxillary articulation	801
Temporo-maxillary vein	431
Tendo Achillis	391
oculi	6. 618
palpebrarum	6. 618
Tendon, cordiform, of diaphragm	294
Tendons, conjoined	195
Tensor palati muscle	51
tarsi muscle	8
tympani muscle	678
vaginæ femoris muscle	364
Tentorium cerebelli	460
Teres major muscle	154
minor muscle	152
Testes	331
cerebri	490
Testicle, pathology of the	345
Thalami optici	487
Thebesius, foramina of	112
valve of	112
Theca vertebralis	504
Thigh, muscles of	361
Thoracic aorta	91. 418
artery, long	416
artery, superior	416
duct	91. 283. 452
ganglions of the sympathetic	581
lymphatic glands	449
nerves, anterior	553
nerve, posterior	552
Thorax, boundaries of	86
dissection of	74. 85
parts passing through base of	105
parts passing through upper orifice of	98
skeleton of	753. 759
upper orifice of	98
Thumb, muscles of	177
Thymus body	445
Thyro-arytenoid ligaments	62
Thyro-arytenoideus muscle	63
Thyro-epiglottic ligament	61
Thyro-epiglottic muscles	65

Page.

Thyro-hyoid ligaments . 61
Thyro-hyoideus muscle . 63
Thyroid artery, inferior . 415
artery, superior . . 409
axis . . . 414
body . . . 32
body, pathology of . 33
cartilage . . . 58
foramen . . . 767
veins . . . 433
Tibia 776
Tibia, dislocations of from the femur . . 854
Tibial artery, anterior 389. 426
artery, posterior . 427
artery, recurrent . 426
nerve, anterior . . 572
nerve, posterior 402. 573
Tibialis anticus muscle . 386
posticus muscle . 395
Tissue, adipose . . 598
adipose medullary . 599
areolar . . . 597
cellular . . . 597
filamentous . . 597
osseous . . . 696
Toes, bones of . . 784
Tongue 43
anatomy of . . 605
pathology of the . 44
Tonsil, or amygdala . . 52
pathology of the . 56
Tonsillitic artery . . 409
plexus . . . 544
Torcular Herophili . . 464
Touch, organ of . . 586
sense of . . 586. 594
Trabeculæ . . . 340
Trachea 99
pathology of the . 70
structure of . . 100
Tracheal veins . . . 433
Trachelo-mastoideus muscle 144
Tract, motor . . . 509
olivary . . . 516
respiratory . . 509
sensitive . . . 509

Page.

Tractus opticus . . 524
Tragicus muscle . . 668
Tragus 666
Transversalis abdominis muscle 196
colli artery . . 415
colli muscle . . 143
fascia . . . 203
perinæi muscle . . 310
pedis muscle . . 399
Transverse facial artery . 21
fissure of cerebrum . 470
ligament of the atlas . 808
meso-colon . . 235
sinus . . . 464
Trapezium bone . . 795
Trapezius muscle . . 137
Trapezoid bone . . 795
ligament . . . 820
Triangles of the neck . 29
Triangular fascia . . 194
ligament of the urethra 311
Triangularis oris muscle . 10
sterni muscle . . 82
Triceps adductor femoris muscle . . . 369
Triceps extensor cubiti muscle 157
Tricuspid valves . . 113
Trifacial nerves . 525. 532
Trigeminal nerves . 525. 532
Trigone 328
Trochanters of femur . 774
Trochleator muscle . . 632
Trochleatores nerves . 525. 532
Tube of the cochlea . . 681
Eustachian . . 675
of Fallopius . . 356
Tuber cinereum . . 479
Tubercula quadrigemina . 490
Tuberculum Loweri . . 111
Tubes of Ferrien . . 285
lactiferous . . 75
Tubuli recti . . . 335
seminiferi . . . 335
uriniferi . . . 285
Tubulus centralis modioli . 682
Tufts of Malpighi . . 285

	Page.
Tunica albuginea oculi .	627
albuginea testis .	334
communis . .	332
erythroides . .	332
sclerotica . . .	642
serosa Jacobi . .	656
vaginalis scroti . .	333
vaginalis of the spermatic cord . 206.	337
vaginalis oculi . .	629
vaginalis testis . .	333
vasculosa retinæ .	657
vasculosa testis . .	334
Turbinated bones . .	727
bones, inferior . .	741
bones of the sphenoid .	729
Tutamina oculi . .	613
Tympanic nerve . 541.	543
plexus . . .	686
Tympanum . . 670.	674
Tyrrell's fascia . . 312.	320
Tyson's glands . . .	340
Ulna	791
Ulnar artery . . 182.	417
artery, recurrent anterior	417
artery, recurrent posterior . . .	417
nerve . . 183.	556
Umbilical arteries . 422.	443
region . . .	226
vein . . .	442
Umbilicus	190
Unciform bone . . .	795
Urachus . . 212.	323
Ureter	288
Urethra, female . .	348
male	342
male, pathology of the	346
triangular ligament of	311
Urethral region . .	307
Uterine arteries . .	423
sinuses . . .	355
veins . . .	438
Uterus	352
Uvea	653

	Page.
Uvula cerebelli . .	496
palati . . .	50
pathology of the .	56
vesicæ . . .	329
Vagina . . . 349.	351
Vaginal arteries . .	423
process of temporal bone	724
veins . . .	438
Vagus nerve . . 528.	544
Valley	492
Valsalva, sinuses of . 114.	118
Valve, coronary . .	112
of Eustachius . 111.	442
of foramen ovale .	443
ileo-cæcal . . .	250
ileo-colic . . .	250
mitral . . .	117
pyloric . . .	243
semilunar . . .	114
sigmoid . . .	114
of Thebesius . .	112
tricuspid . . .	113
of Vieussens . 490.	499
Valves of veins . .	429
Valvulæ conniventes .	255
Varolii pons . . .	491
Vas deferens . . .	336
efferens . . .	285
Vasa brevia . . 280.	420
efferentia testis . .	335
lactea . . .	451
lymphatica efferentia .	447
lymphatica inferentia	447
vorticosa . . .	648
Vascular system, anatomy of	403
Vasculum aberrans . .	336
Vastus externus muscle .	367
internus muscle . .	367
VEINS	427
structure of . .	429
auricular . . .	430
axillary . . 83.	436
azygos, major 91. 282.	434
azygos, minor . .	434
azygos, superior .	435
basilic . 150. 161.	436

Page.

VEINS—*continued.*
basi-vertebral . . 505
capsular . . . 439
cardiac . . . 122
cava, inferior . . 438
cava, superior . . 433
cavernosæ . . 438
cephalic . 149. 161. 435
cerebellar . . 463
cerebral . . . 462
coronary . . . 122
diploic . . . 430
dorsalis penis . . 438
emulgent . . . 439
facial . . 21. 430
femoral . . . 437
frontal . . . 430
Galeni . . 470. 485
Galeni (heart) . . 123
gastric . . . 245
hepatic . . 270. 439
iliac, common . 282. 438
iliac, external . 282. 437
iliac, internal . 282. 438
innominatæ . 98. 433
intercostal . . 435
jugular, anterior . 432
jugular, external 15. 26. 431
jugular, internal 40. 432
lingual . . . 431
maxillary, internal . 431
median . . 161. 436
median basilic . 161. 436
median cephalic 161. 436
mesenteric, inferior . 281
mesenteric, superior . 281
occipital . . . 430
ophthalmic . 431. 636
ovarian . . . 439
phrenic, inferior . 439
popliteal . . . 437
portal . . 269. 281
prelumbo-thoracic . 434
profunda femoris . 437
prostatic . . . 438
pulmonary . . 427

Page.

VEINS—*continued.*
ranine . . . 431
renal . . . 439
salvatella . . 161. 436
saphena, external 384. 437
saphena, internal 216. 361. 437
spermatic . . . 439
spinal . . . 505
splenic . . 269. 281
subclavian . 40. 436
superior cava . . 98
systemic . . . 428
temporal . . . 430
temporo-maxillary . 431
thyroid . . . 433
tracheal . . . 433
umbilical . . . 442
uterine . . . 438
vaginal . . . 438
vertebral . . . 433
vesical . . . 438
Velum interpositum . 470. 485
medullary, inferior . 495
medullary, superior 490. 495. 499
pendulum palati 42. 50
vesicæ . . . 328
Vena cava, inferior or ascending . 282. 438
cava, superior . 98. 433
Galeni (heart) . . 123
portæ . . 269. 281
Venæ comites . . . 429
Galeni . . . 485
vorticosæ . . . 648
Ventricles of the brain, fifth 481
of the brain, fourth . 497
of the brain, lateral . 482
of the brain, third . 488
of the heart, left . 117
of the heart, muscular fibres of . . 127
of the heart, right . 112
of the larynx . . 68
spinal . . . 511
of vestibule . . 684

	Page.
Ventro-inguinal hernia .	209
Vermiform appendix .	249
process, inferior 493.	496
process, superior 493.	495
Vertebræ	699
cervical	702
common articulations of	809
dislocations of . .	813
dorsal	701
lumbar	701
Vertebral arteries . 414.	519
column	706
column, pyramids of .	708
sinuses	505
veins	433
Verumontanum . .	344
Vesica urinaria . .	321
Vesical arteries . .	423
fascia	320
veins	438
Vesicles, germinal (Purkinjie)	357
Graafian	357
Vesico-uterine ligaments .	353
Vesiculæ seminales . .	337
Vestibular nerve . .	685
ventricle . .	684
Vestibule	680
Vibrissæ	600
Vidian artery	411
nerve	536
Vieussens, valve of . 490.	499
Villi	257
Vision, organs of . .	612
sense of	662
Vitreous humour . .	661
Vomer	742
Vulva	347
Vulvo-vaginal glands .	348
Wagner, germinal spot of .	357
Whartonian duct . .	35
Willis, circle of 414. 519.	520
Willisii cordæ . . .	462
Wilson's muscles . .	314
Wing of Ingrassius . .	730
Winslow, foramen of .	236
ligamentum posticum of . . 382.	846
Wormian bones . . .	717
Wrisberg, nerves of 150. 555.	560
Wrist-joint	829
Wrist-joint, dislocations of	831
Zinn, ligament or tendon of	627
zonula of . . .	661

THE END.